2nd Edition

# THE Eclectic Approach TO CHIROPRACTIC

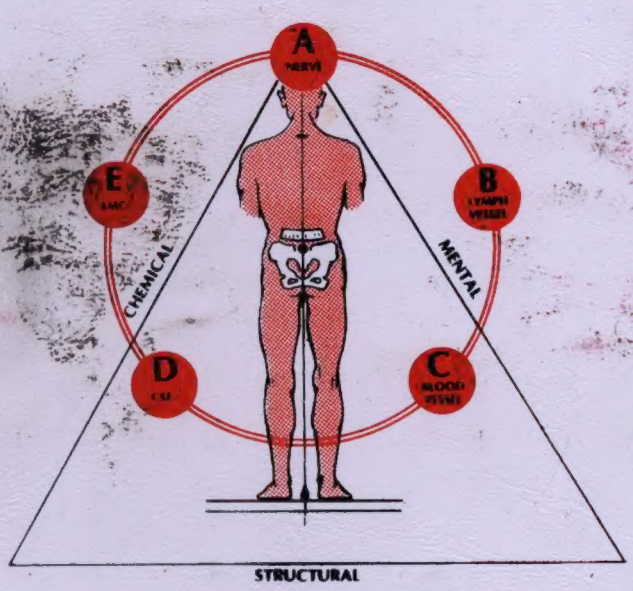


BY

FRED STONER, D.C.

STONER

# THE *Eclectic Approach* TO CHIROPRACTIC

FLS PUBLISHING

# THE ECLECTIC APPROACH TO CHIROPRACTIC

# THE ECLECTIC APPROACH TO CHIROPRACTIC

BY

FRED STONER, D.C.

Illustrated by Benjamin F. Hoffman, III

Published by F.L.S. Publishing Co.

Las Vegas, Nevada

© 1975, Fred Stoner, D.C.

Second Edition © May, 1976, Fred Stoner, D.C.

SECOND EDITION
COPYRIGHT © FRED STONER, D.C. 1975
ALL RIGHTS RESERVED

NO PART OF THIS PUBLICATION MAY BE REPRODUCED, STORED IN RETRIEVAL SYSTEM, OR TRANSMITTED, IN ANY FORM OR BY ANY MEANS, ELECTRONIC, MECHANICAL, PHOTOCOPYING, RECORDING OR OTHERWISE, WITHOUT THE PRIOR PERMISSION OF THE COPYRIGHT OWNER. WORLD RIGHTS RESERVED UNDER INTERNATIONAL & PAN-AMERICAN CONVENTION.

FIRST EDITION COPYRIGHT NUMBER - A718977
REGISTERED IN THE LIBRARY OF CONGRESS
FIRST PRINTING — JUNE, 1975
SECOND PRINTING — OCTOBER, 1975
SECOND EDITION REVISED — MAY, 1976

PRINTED IN THE
UNITED STATES OF AMERICA

**DEDICATED**

**TO**

**MACHELLE AND DAVID**

May you both one day know the joy
and personal satisfaction that
only service to others can bring.

# ACKNOWLEDGEMENTS

## FIRST EDITION

I would like to pay tribute to the following Chiropractic researchers who have made outstanding contributions to the science of Chiropractic:

Major De Jarnette, D.C., C. S. Gonstead, D.C., John Grostic, D.C., Raymond Nimmo, D.C., Burl Pettibon, D.C., Robert Ridler, D.C., and Richard Van Rumpt, D.C.

The author would also like to recognize a group of dedicated Chiropractic educators. These doctors have devoted their lives to improving the quality of education in the Chiropractic profession.

Dr. Carl S. Cleveland, Jr., President, Cleveland Chiropractic College of Kansas City.
Dr. Carl S. Cleveland, Sr., President, Cleveland Chiropractic College of Los Angeles.
Dr. William N. Coggins, President, Logan College of Chiropractic.
Dr. George A. Dunn, President, Western States Chiropractic College.
Dr. W. D. Harper, President, Texas Chiropractic College.
Dr. George Haynes, President, Los Angeles College of Chiropractic.
Dr. Joseph Janse, President, National College of Chiropractic.
Dr. Ernest G. Napolitano, President, Columbia Institute of Chiropractic.
Dr. David D. Palmer, President, Palmer College of Chiropractic.
Dr. John B. Wolfe, President, Northwestern College of Chiropractic.

Needless to say, I am deeply grateful to Dr. George Goodheart for allowing me to utilize his research and development of Applied Chiropractic Kinesiological Diagnosis and Technique.

Also, I am indebted to my artist, Benny Hoffman, for his constant cooperation and excellent artwork, Bob Patrick for his creative photography, Dr. Armand Gilbo, Dr. Phillip Round, Dr. Alan Beardall, Dr. George Goodheart, and Diana Stanga for their assistance in proofing the manuscript, and Dr. John Thie for his advice and guidance.

I would like to give a special thanks to my personal secretary, Bonna Hartmann, for her endless dedication in assisting me with the secretarial aspect of preparing this text.

As you might imagine, my wife, Mary, and children, Machelle and David, deserve a gold medal for their patience and understanding during the long months consumed by the creation of this text.

Last, but by no means least, I would like to thank my wonderful patients who have always been an inspiration to me.

Fred Stoner, D.C.

## SECOND EDITION

I would personally like to thank the following doctors for their recommendations and contributions to the following chapters of the second edition:

Walter Schmitt, D.C., Chapters I, II, VIII
Chester Chin, D.C., D.C.M., Chapter II
J. V. Durlacher, D.C., Chapter IV
Ivan Mindlin, M.D., F.A.C.S., Chapter V
Lonnie Hammargren, M.A., M.S., M.D., Chapter VI
William Donald Kelley, B.A., D.D.S., M.S., F.I.C.A.N., Chapter X

Once again, I am indebted to my artist, Benny Hoffman, to Bob Patrick for his photography, to Dick Ingraham for editing the text, to my associates, Dr. Armand Gilbo and Dr. Phillip W. Round, to my office manager, Diana M. Stanga, and to Dr. George Goodheart for the privilege of using his research data.

Lastly, I would like to thank my wife and children for their continued love and support.

Fred Stoner, D.C.

# ABOUT THE AUTHOR



Fred Stoner, D.C. was born in Texas in 1943 and raised in Albuquerque, New Mexico. He attended Palmer Junior College and received a D.C. degree from the Palmer College of Chiropractic in 1965. He has done postgraduate work at the Los Angeles College of Chiropractic in the field of orthopedics.

Dr. Stoner is President of the Nevada State Board of Chiropractic Examiners, President of Fred Stoner Chiropractic Offices, Ltd., President of the Stoner Chiropractic Research Foundation, Inc., a member of the Board of Directors of Touch for Health, a member of the International College of Chiropractic Kinesiologists, an approved Kinesiological Instructor of the International College of Chiropractic Kinesiologists and a member of the Knights of the Chiropractic Round Table.

The author began practice in Las Vegas, Nevada in January, 1968 in one small room; and within five years, his practice expanded, necessitating office space in excess of 4,000 square feet. He has a staff of 12 doctors and C.A.'s and one of the most modern Chiropractic offices in the United States. Patients come to Dr. Stoner from twenty different states and three foreign countries for treatment. Jim Parker, D.C., Ph.C., President of the Parker Chiropractic Research Foundation, stated, "Fred Stoner is the man of the decade."

The author has lectured in numerous state and county Chiropractic associations and societies, as well as various colleges and schools. He presently teaches Applied Chiropractic Kinesiological Diagnosis and Technique at the Stoner Chiropractic Research Foundation, Inc. seminars in Las Vegas.

All correspondence to the author may be sent to: The Stoner Chiropractic Research Foundation, Inc., P.O. Box 15208, Las Vegas, Nevada 89109.

# PREFACE

Before you begin to study the contents of this book, it would be appropriate to take one moment and review our Chiropractic heritage.

Never forget that many Chiropractors have gone to jail for the privilege of practicing Chiropractic. In fact, it was just last year that three Chiropractors were jailed in the State of Louisiana for practicing medicine without a license because Chiropractic was not recognized in that State. The Chiropractors of the past were so busy literally fighting for their professional lives, that they had little time to be the healers, teachers and researchers they had dreamed of becoming.

Great strides have been made in the science of Chiropractic since that eventful day in 1895 when Dr. Daniel David Palmer discovered what we now know as the science of Chiropractic. It is said that his son, B. J. Palmer, is credited with developing Chiropractic. I seriously question, however, whether one person can be credited with the complete development of a science. Would it not be wiser to say that B. J. Palmer was the custodian of Chiropractic for about 40 years?

During the mid 50's and through the 60's, Dr. Jim Parker introduced an essential ingredient to the total success of Chiropractic. He taught Chiropractors not only to believe in Chiropractic, but also in themselves.

In the mid 60's, a Detroit Chiropractor by the name of Dr. George Goodheart accidently stumbled upon an extraordinary phenomenon. This discovery led him to become one for the world's greatest scientific researchers of the 20th Century. Dr. Goodheart has not only founded and developed what we now know as Applied Chiropractic Kinesiological Diagnosis and Technique, but he has also made outstanding contributions to the fields of nutrition and acupuncture. He is the first American to contribute to the science of acupuncture and the only man with a new scientific development in acupuncture over the last 1,000 years. George, as he is fondly called by his friends, has advanced neurological diagnosis to the point that it has limitless potential through the vehicle of "Therapy Localization."

Through Applied Chiropractic Kinesiological Diagnosis and Technique, Dr. Goodheart has made Chiropractors all over the world realize that our philosophy is correct as espoused by Dr. B. J. Palmer. However, he has also made us realize that we have been maintaining a 65-year-old love affair with the bones, while preaching a holistic approach to health.

The Chiropractic achievements of the past must always be respected, but nothing ever remains the same. Chiropractic should not be practiced today in the same manner as it was in the 30's or during B. J.'s era. To keep Chiropractic pure is honorable, but to retard its growth is unforgivable. Not only is it our responsibility to learn from the past, but we must contribute to the future.

The welfare of our patients and the trust they have in our ability to help them obligates each and every Chiropractor to keep abreast of all scientific developments. This does not mean that we must practice all branches of science, but we must utilize those developments which relate to Chiropractic. A Chiropractor must never let his perspective become narrowed, his thirst for knowledge quenched or his curiosity for the unknown restrained.

I hope that this textbook will not only provide a continuing reference for the fundamentals of Chiropractic but will also motivate the Chiropractor to fulfill his mission as a healer, teacher and research scientist.

One point should always be crystal clear. We must do everything we can to get sick and suffering people well as fast as possible — naturally, through Chiropractic.

# TABLE OF CONTENTS

PAGE

ACKNOWLEDGMENTS ..... vi

PREFACE ..... ix

CHAPTER I APPLIED CHIROPRACTIC KINESIOLOGICAL DIAGNOSIS AND TECHNIQUE
- Birth of Applied Chiropractic Kinesiological Diagnosis and Technique ..... 1
- Postural Patterns ..... 2
- Muscle Testing ..... 8
- Testing Muscles in Various Positions ..... 8
- K-27 and the Umbilical Contact ..... 8
- Intervertebral Foramen (I.V.F.) ..... 9
- Cranial and Sacral Respiratory Movement ..... 10
- Therapy Localization Technique ..... 12
- Transference ..... 13
- Challenge Technique ..... 13
- Temporal-Sphenoidal Line (T.S. Line) ..... 14
- Neurovascular Receptors ..... 16
- Neurolymphatic Receptors ..... 19
- Nutrition and Applied Kinesiological Diagnosis and Technique ..... 22
- Origin and Insertion Technique ..... 28
- Golgi Tendon Apparatus and Spindle Cell Mechanism ..... 29
- Reactive Muscle Testing ..... 29
- Points on the Mastoid ..... 30
- Cranial Pump Technique ..... 31
- Cranial Faults ..... 32
- Cranial Stress Centers ..... 48
- Emotional Patterns ..... 51
- Lovett Brother ..... 52
- Applied Chiropractic Kinesiological Diagnosis and Technique for Spinal and Pelvic Subluxations and Fixations
  - Respiratory Spinal and Pelvic Correction Technique ..... 54
  - Spinal Fixation ..... 54
  - Fixation Chart ..... 55
  - Therapy Localization ..... 55
  - Gravitational Fixation ..... 56
  - Occipital Fixation and Subluxation ..... 56
  - Occiput-Atlas Rocker Mechanism ..... 57
  - Cervical Fixation Discussion ..... 57
  - Atlas-Occiput Rocker Mechanism ..... 58
  - Atlas, Axis and 3rd Cervical Fixation ..... 58
  - Lower Cervical Fixation ..... 58
  - Dorsal and Lumbar Fixation ..... 58
  - Upper Dorsal Rib Fixation ..... 58
  - Anterior Dorsal and Levator Costalis Technique ..... 59
  - Sacrum Balance ..... 59
  - Sacrum Fixation ..... 60
  - Sacral Wobble Fault ..... 60
  - Pelvic Faults ..... 60
  - Category III ..... 60
  - Category II ..... 60
  - Category I ..... 61
  - Cranial Torque Lesion ..... 62
  - Iliac Movements on Respiration ..... 63
  - Unusual Therapy Localization Techniques ..... 64
  - Clavicle Subluxation or Fixation ..... 64
  - Applied Kinesiological Reflex Points ..... 64

**CHAPTER II** ACU-THERAPY **PAGE**
Introduction ..... 67
Meridians ..... 68
Meridian Energy Flow ..... 71
Yin and Yang ..... 72
The Five Elements ..... 73
Creation Cycle ..... 73
KO or Destruction Cycle ..... 74
Emotions and the Five Elements ..... 76
Creation and Destruction Cycle Together ..... 76
Principles of the Five Elements ..... 76
Laws of Acu-Therapy ..... 78
Mother-Son Law ..... 78
Pulses • Husband-Wife Law (Law of Endanger) ..... 78
Therapy Localizing the Pulses ..... 79
Midday-Midnight Law ..... 80
Categories of Meridian Points
Alarm Points ..... 81
Points of Tonification ..... 82
Points of Sedation ..... 83
Connecting Points ..... 84
Command Points ..... 85
Associated Points ..... 86
Running Meridians ..... 86
Nature of Energy ..... 86
Figure Eight Energy ..... 88
Method of Correction ..... 88
Practical Use of Acu-Therapy ..... 88
How One Form of Energy Enters the Body ..... 90
Treatment of Conception and Governing Vessels ..... 90
If More Than Three Meridians are Imbalanced ..... 90
Meridian Points, Elements and Classifications ..... 91

**CHAPTER III** AURICULOTHERAPY
History and General Information ..... 103
Methods of Treatment ..... 105
Type of Energy ..... 108

**CHAPTER IV** MUSCLES, STRUCTURAL FAULTS AND CORRECTION
Grading of Muscle Strength ..... 109
Abdominals
External Abdominal Oblique ..... 110
Internal Abdominal Oblique ..... 112
Rectus Abdominis ..... 114
Transversus Abdominis ..... 116
Adductors
Brevis ..... 118
Longus ..... 120
Magnus ..... 122
Pectineus ..... 124
Anconeus ..... 126
Biceps Brachii ..... 128
Brachioradialis ..... 130
Coracobrachialis ..... 132
Deltoids ..... 134
Diaphragm ..... 136
Gastrocnemius ..... 138

PAGE


Gluteus Maximus ..... 140
Gluteus Medius ..... 142
Gluteus Minimus ..... 144
Gracilis ..... 146
Hamstrings
  Biceps Femoris (Lateral) ..... 148
  Semimembranosus (Medial) ..... 150
  Semitendinosus (Medial) ..... 152
Iliacus ..... 154
Infraspinatus ..... 156
Latissimus Dorsi ..... 158
Levator Ani ..... 160
Levator Scapulae ..... 162
Masseters ..... 164
Neck Extensors
  Splenius Capitis and Splenius Cervicis ..... 166
Neck Flexors
  Scalenus Anterior ..... 168
  Scalenus Medius ..... 170
  Scalenus Posterior ..... 172
  Sternocleidomastoid ..... 174
Pectoralis Major Clavicular ..... 176
Pectoralis Major Sternal ..... 178
Peroneus
  Brevis ..... 180
  Longus ..... 182
  Tertius ..... 184
Piriformis ..... 186
Popliteus ..... 188
Psoas Major ..... 190
Pterygoid
  External ..... 192
  Internal ..... 194
Quadratus Lumborum ..... 196
Quadriceps
  Vastus Intermedius ..... 198
  Vastus Lateralis ..... 200
  Vastus Medialis ..... 202
  Rectus Femoris ..... 204
Rhomboids
  Major ..... 206
  Minor ..... 208
Sacrospinalis
  Erector Spinae
    Iliocostalis Cervicis ..... 210
    Iliocostalis Lumborum ..... 210
    Iliocostalis Thoracis ..... 210
    Longissimus Capitis ..... 212
    Longissimus Cervicis ..... 212
    Longissimus Thoracis ..... 212
    Spinalis Capitis ..... 214
    Spinalis Cervicis ..... 214
    Spinalis Thoracis ..... 214
  Transversospinalis
    Multifidus ..... 216
    Rotatores ..... 216
    Semispinalis Capitis ..... 216

PAGE

Semispinalis Cervicis ..... 216
Semispinalis Thoracis ..... 216
Sartorius ..... 220
Serratus (Anterior) ..... 222
Soleus ..... 224
Subclavius ..... 226
Subscapularis ..... 228
Supraspinatus ..... 230
Temporalis ..... 232
Tensor Fascia Lata ..... 234
Teres Major ..... 236
Teres Minor ..... 238
Tibialis (Anterior) ..... 240
Tibialis (Posterior) ..... 242
Trapezius (Middle and Lower) ..... 244
Trapezius (Upper) ..... 246
Triceps Brachii ..... 248

**CHAPTER V** ORTHOPEDICS
General Tests ..... 252
Neurovascular Tests ..... 260
Malingering Tests ..... 263
Ranges of Motion ..... 265

**CHAPTER VI** NEUROLOGY
Introduction ..... 273
General Cerebral Function ..... 274
Specific Cerebral Function ..... 275
Cranial Nerve Examination ..... 276
The Cerebellum ..... 281
Pyramidal System ..... 282
Extrapyramidal System (Basal Ganglia) ..... 282
Tracts of the Spinal Cord ..... 283
Sensory System ..... 285
Motor System ..... 286
Reflexes ..... 287
Upper and Lower Motor Neuron Lesions ..... 292
Gaits ..... 294

**CHAPTER VII** CLINICAL LABORATORY
Introduction ..... 295
Common Clinical Laboratory Abbreviations ..... 295
Hematology ..... 296
Urinalysis ..... 301
Biochemistry ..... 304
Serology ..... 313
Endocrinology ..... 314
Toxicology ..... 316
Cultures and Sensitivities ..... 317
Diseases and Laboratory Findings ..... 318
Laboratory Surveys by Symptoms ..... 324

**CHAPTER VIII** COMMON DISORDERS AND TREATMENT TECHNIQUES
Ileocecal Valve Syndrome ..... 325
Ileocecal Valve Challenge and Correction ..... 326
Postural Hypotension and Functional Hypoadrenia ..... 327
Allergy Technique ..... 328

PAGE

Hiatal Hernia ..... 329
Gait Receptor Faults ..... 330
Heel and Sole Lifts ..... 331
Reflex Points Found on the Soles of the Feet ..... 331
Hand Receptors ..... 334
Carpal Tunnel Syndrome ..... 336
Tarsal Tunnel Syndrome ..... 337
Hand-Arm-Shoulder Pain ..... 338
Knee Joint Problems ..... 340
Cross Crawl Technique ..... 341
Cellular Memory ..... 342
Vivaxis ..... 343

**CHAPTER IX** STRUCTURAL EXERCISES

Low Back ..... 346
Neck ..... 350
Hip ..... 351
Shoulder ..... 351
Knee ..... 352
Ankle ..... 352
Elbow ..... 352
Varicose Vein ..... 353
Wrist ..... 354
Finger ..... 354
Hernia ..... 354
Chest Expansion (Lung) ..... 355
Postural Drainage ..... 355

**CHAPTER X** DIETS

Allergy ..... 370
Nutritional Anemia ..... 358
Arthritis ..... 359
Bland ..... 362
Low Cholesterol ..... 363
Detoxification ..... 364
Cleansing and General Health ..... 368
Hypoglycemic ..... 369
High Protein, Sinus or Allergy ..... 370
Soft Food (Liquid) ..... 371
Low Purine ..... 372
Low Sodium (Salt) ..... 373
Low Sugar ..... 374
General Weight Reduction, #1 ..... 375
General Weight Reduction, #2 ..... 376

**CHAPTER XI** ORGAN DETOXIFICATION

Liver and Gallbladder ..... 377
Kidney ..... 378
Lungs ..... 378
Colon ..... 378
Coffee Retention Enema ..... 378
Purge ..... 379
Alkalizing Punch ..... 379
Fasting ..... 380

PAGE

**CHAPTER XII** OTHER COMMON DISORDERS AND TREATMENT TECHNIQUES
Temporomandibular Joint Disturbances ..... 381
Nasal Respiratory Technique ..... 382
Umbilical-Coccygeal Contact ..... 383
Temporal Tap ..... 383
Biofeedback and Neurovascular Treatment ..... 384
Stress Factors in Neck and Back Pain ..... 385
Shock Absorb vs. Shock Transmit ..... 386
Psoas — Diaphragm Technique ..... 386
Pre and Post Ganglionic Technique ..... 387
Location of Vortices ..... 387
Costovertebral Respiratory Technique ..... 389

**CHAPTER XIII** NERVE ROOT AND DISC SYNDROMES
Clinical Findings in a Nerve Root and Disc Syndrome ..... 391
Clinical Findings in a Fifth Cervical Ruptured Disc ..... 392
Clinical Findings in a Sixth Cervical Ruptured Disc ..... 393
Nerve Root Syndromes ..... 394
Sixth Cervical Nerve Root Syndrome ..... 394
Seventh Cervical Nerve Root Syndrome ..... 395
Eighth Cervical Nerve Root Syndrome ..... 396
Dorsal Nerve Root Syndrome ..... 396
Lumbar Disc Syndromes ..... 397
L-4 Ruptured Disc ..... 399
L-5 Ruptured Disc ..... 400
S-1 Syndrome ..... 401
S-2 Syndrome ..... 402

**BIBLIOGRAPHY** ..... 403

**INDEX** ..... 405

# CHAPTER I

## BIRTH OF APPLIED CHIROPRACTIC KINESIOLOGICAL DIAGNOSIS AND TECHNIQUE

Why is it that some people are successful when others have tried and failed? What quality distinguishes an achiever from a person who simply occupies time and space? What enables some people to learn and subsequently grow and expand, while others who have the same ability to learn, fail to even try? Who was it or what was it that said we are all born equal?

What quality did Edison possess which prompted him to research the idea that electricity could be put into a bulb, and eventually brought about his success? Why didn't Franklin decide it was much too cold and windy to fly a kite in a thunderstorm? What drove Harvey to maintain his research on blood flowing through the veins and arteries in the face of ridicule and exile by his fellow scientists? Why didn't D. D. Palmer simply pass over the idea that there might be a relationship between Harvey Lillard's protrusion on the back of his neck and his deafness?

We have all had earth-shattering experiences which could potentially form a bright new tomorrow. However, most of us simply ignore these experiences and allow time to tick away while tomorrow melts into the humdrum of yesterday.

I would like to tell you a story about a Chiropractor who began his life as a John Doe and eventually became an Edison. This man routinely practiced a science, an art and a philosophy for 20 years. He was never totally satisfied with the existing techniques and constantly wondered if there was a better way.

One day, a patient presented himself to this doctor with a chief complaint of an inability to move his left arm with any degree of forward thrust. The doctor, realizing that this was not the usual stiff neck or sore lower back problem, was interested. When examining the patient, the doctor noted that if the patient would lean against the wall, the scapula would protrude from the posterior aspect of the chest wall. Having never seen this particular protruding scapula problem before, the doctor decided to experiment a little and test the strength of the anterior serratus muscle, which tested weak. When testing the muscle, he used the method outlined in a muscle testing book which a grateful colleague had recently given him. Upon palpating the muscle bilaterally, it appeared normal in structure and no irregularities were evident. However, upon closer observation and palpation of the structure, the doctor felt small but discreet palpable nodules on the rib at the insertion of the serratus anterior. These nodules were distinctly painful to moderate pressure and were not present on the unaffected side. In attempting to discover if these areas might possibly be "trigger areas," he applied relatively heavy pressure in an intermittent, kneading fashion on the origin of the serratus anterior. As a result, the muscle regained practically 70 per cent of its functioning ability in a matter of two or three minutes. This resumption of function maintained itself following treatment and did not require further treatment. Follow-up on this particular patient, almost two months later, showed that this recovery maintained itself.

This accidental discovery resulted in the doctor's insatiable thirst for knowledge regarding muscles and their function, testing, isolation, etc. After he had read all the available literature, he soon realized the material dealt strictly with the hypertonic muscle or the muscle in contraction or spasm. There was virtually no research on the hypotonic muscle. He realized then that the patient with the anterior serratus problem had a hypotonic condition, rather than a hypertonic condition. In his practice and in dealing with hundreds of various cases, he was quick to observe that for every hypertonicity, there was a hypotonicity on the opposite side. He found that by eliminating the hypotonicity through Applied Chiropractic Kinesiological Diagnosis and Technique, the hypertonicity was immediately corrected.

Since there was no available material on the hypotonic muscle, and treatment of the hypertonic muscle was very unsuccessful, the doctor began to question the logic of his predecessors. This doctor's inquiring mind and his philosophical background gave rise to the question, "If structure controls function, what controls structure?" Could it be that muscles move bones — bones don't move muscles? These initial questions gave rise to the birth of Applied Chiropractic Kinesiological Diagnosis and Technique.

This man could very easily have remained an unsatisfied, unfulfilled Chiropractor. He might have spent the rest of his days waiting for someone else to come up with a better way. However, because he questioned the status quo, found it to be unacceptable and had the audacity and tenacity to change it, untold thousands have benefited from the application of the principles set forth in this text.

For those of you who do not know this man, I consider it an honor to be able to introduce you to the Father of Applied Chiropractic Kinesiological Diagnosis and Technique, Dr. George Goodheart, D.C.

# POSTURAL PATTERNS

There is no question that muscles do contract and go into spasm. Many patients have problems involving apparent muscle spasms, such as iliopsoas spasm, trapezius spasm, etc. However, when patients are examined for obvious muscle spasm, an amazing fact is learned. Through bilateral muscle testing, it has been found that an overwhelming majority of these patients have muscle weakness rather than primary muscle spasm, and it is this weakness which then causes the opposing or contralateral muscle to contract. Therefore, the contracted muscle is a secondary effect of the primary muscle weakness.

A reciprocal relationship exists between muscles, i.e., when the biceps contracts, the triceps normally relaxes. However, an abnormal reciprocal relationship can also occur between muscles with a detrimental effect.

After examining thousands of patients, we have learned that the body has a language. This language is an interpretation of the hypertonic and hypotonic muscles. Body language does not lie, and through this language, the body tries to communicate its problematic state.

The following drawing illustrates the normal tonicity of muscular structures. One can easily see how hypotonicity of one muscular structure would result in a contracture of the opposing muscular structure, resulting in distortion of the body's balance and subsequent formation of body language.

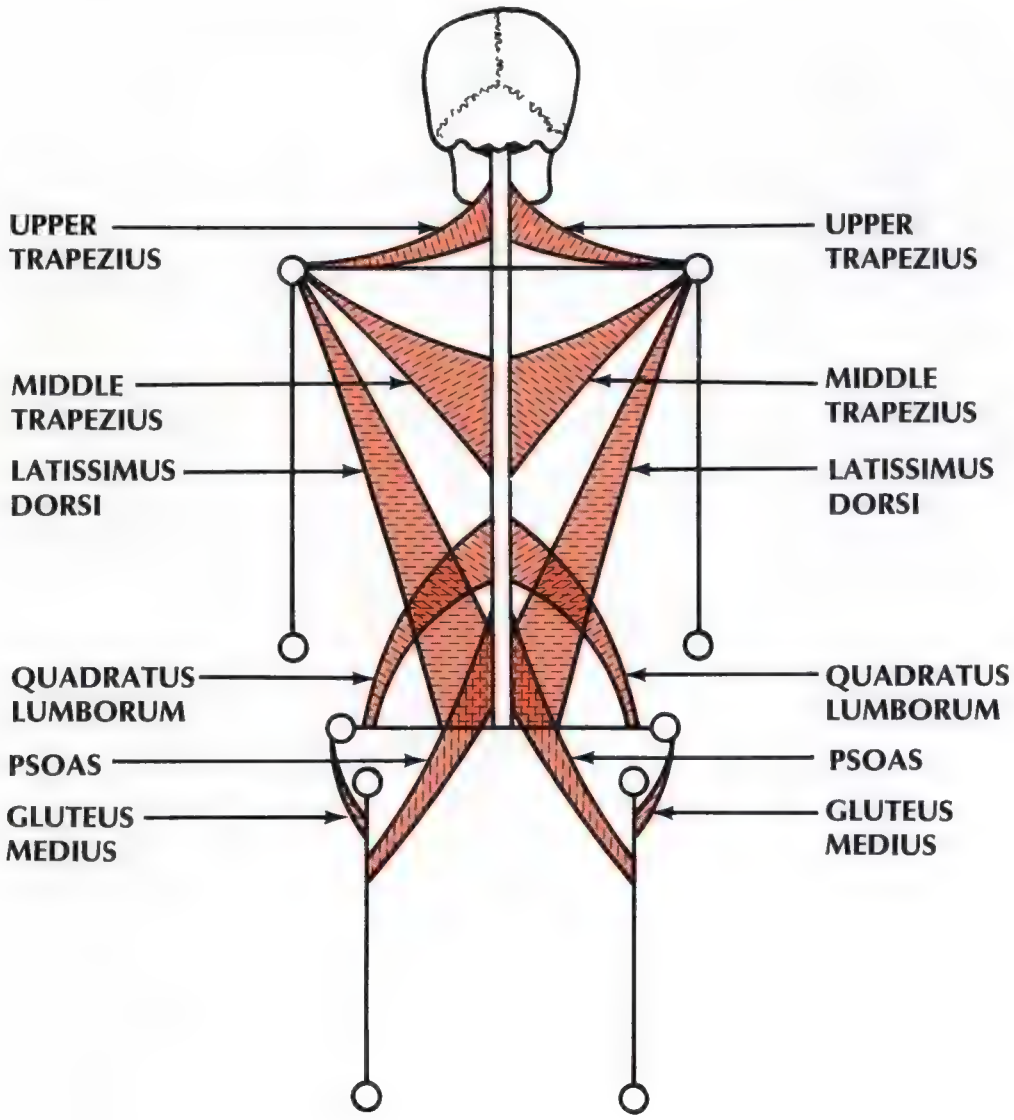

The following muscles, when found individually weak by standard muscle testing procedures, will cause the right iliac crest to be elevated relative to the left iliac crest (posterior to anterior view).

**PSOAS**
**(ON RIGHT)**

**GLUTEUS MEDIUS**
**GLUTEUS MINIMUS**
**(ON RIGHT)**

**GLUTEUS MAXIMUS**
**(ON RIGHT)**



**TENSOR FASCIA LATA**
**(ON RIGHT)**

**ADDUCTORS**
**(ON LEFT)**

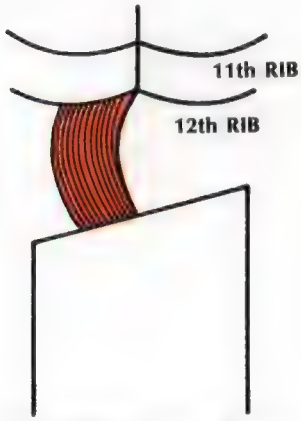


**QUADRATUS LUMBORUM**
**(ON LEFT)**

**RECTUS ABDOMINIS**
**(ON LEFT)**

**TRANSVERSE ABDOMINIS**
**(ON LEFT)**



**SACROSPINALIS**
**(ON LEFT)**

The following muscles, when found individually weak by standard muscle testing procedures, will cause the RIGHT shoulder to be elevated relative to the left shoulder and/or the RIGHT arm and hand to be rotated with the palm facing medially or posteriorly, rather than the normal position of rest midway between the two.

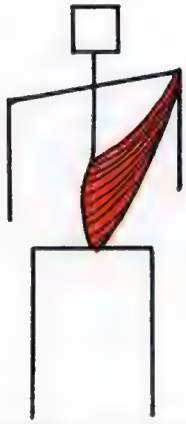

**LATISSIMUS DORSI**
**(ON RIGHT)**
**(NOTE: LOW BACK SCOLIOSIS)**

**LOWER TRAPEZIUS**
**(ON RIGHT)**
**(NOTE: THORACIC SCOLIOSIS)**

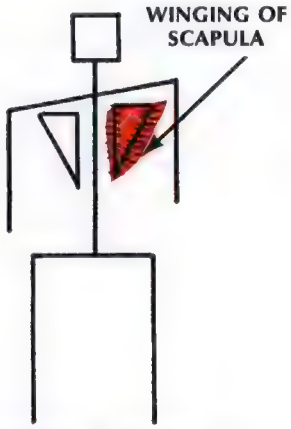


**ANTERIOR SERRATUS**
**(ON RIGHT)**

**UPPER TRAPEZIUS**
**(ON LEFT)**

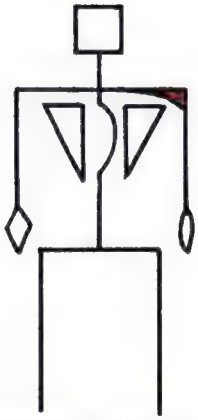

**PECTORALIS MAJOR CLAVICULAR**
**(ON RIGHT)**
(NOTE: CONTRACTED RHOMBOID AND THORACIC SCOLIOSIS)



**PECTORALIS MAJOR STERNAL**
**(ON RIGHT)**
(NOTE: CONTRACTED RHOMBOID AND THORACIC SCOLIOSIS)

**SUBSCAPULARIS**
**(ON RIGHT)**

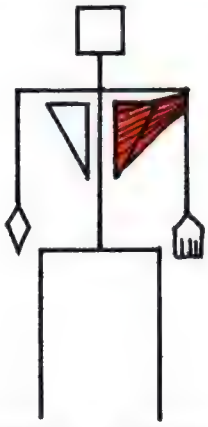

**TERES MINOR AND INFRASPINATUS**
**(ON RIGHT)**



**LEVATOR SCAPULAE**
**(ON RIGHT)**

The following diagrams illustrate commonly seen multiple muscle weakness patterns from a posterior to anterior view and from a superior to inferior view.

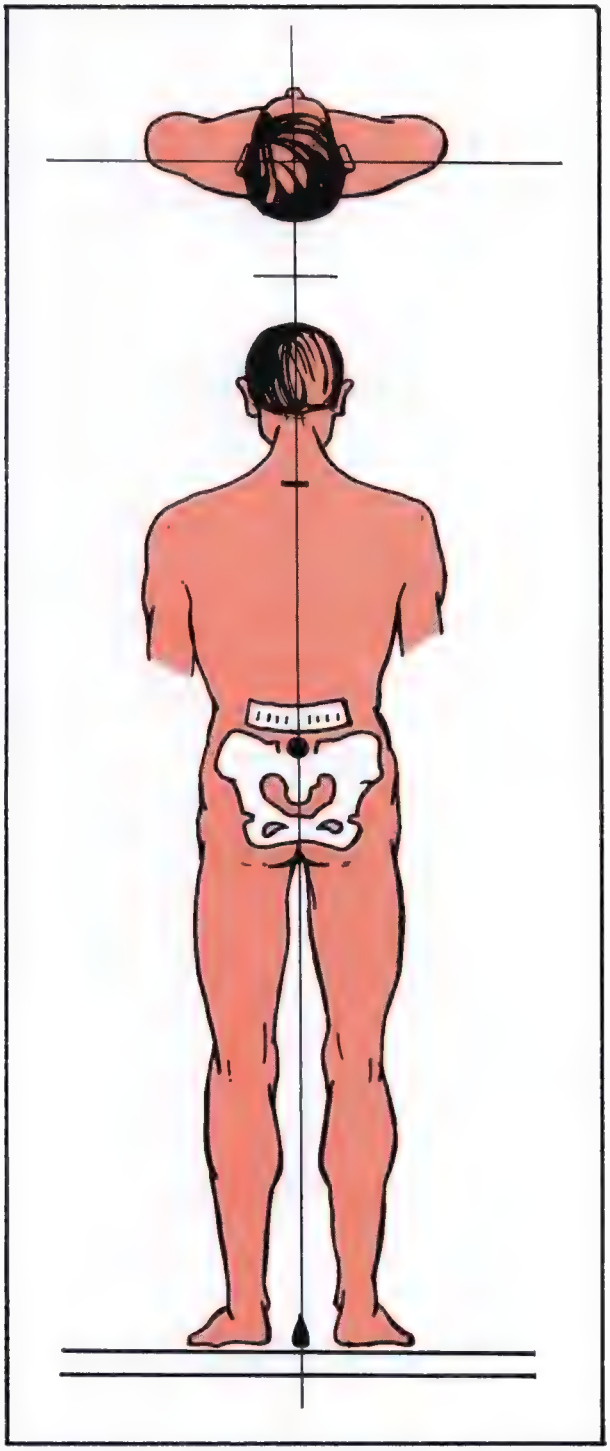

**NORMAL AND BALANCED POSTURE**

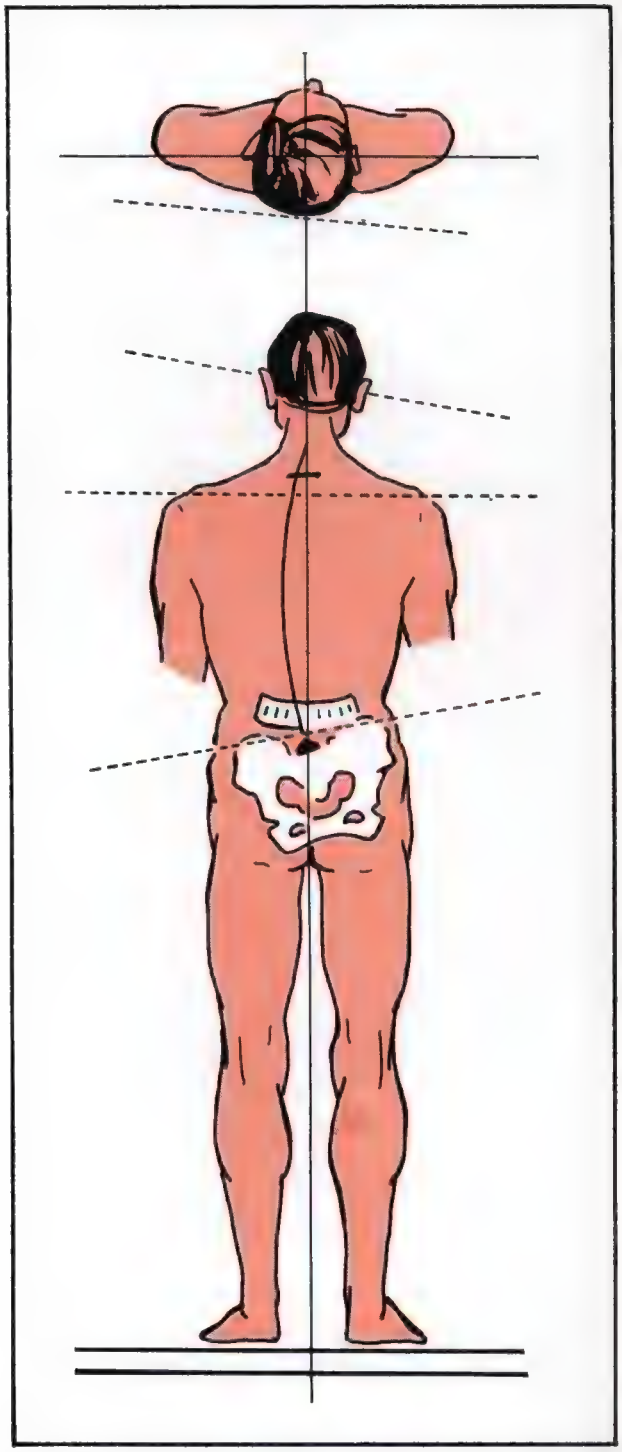

This illustration depicts weakness of the left splenius, right rhomboid, left psoas and left quadratus lumborum muscles.

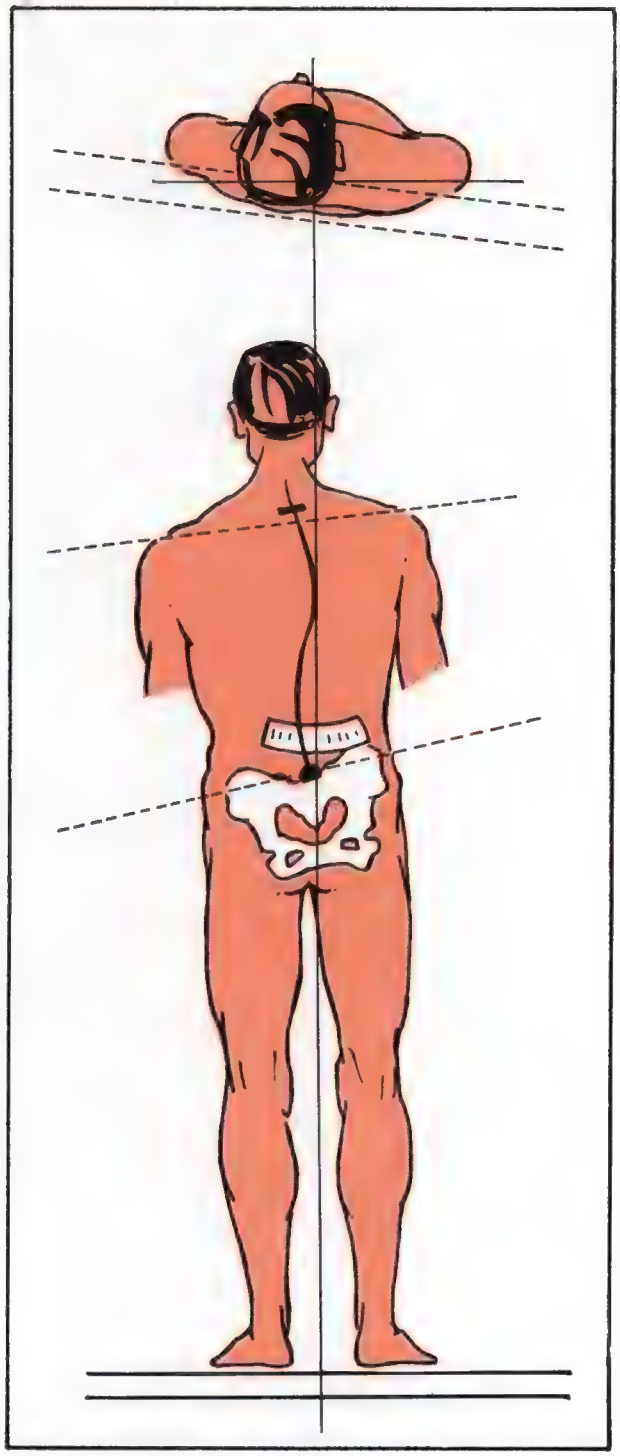

This illustration depicts weakness of the right latissimus dorsi, right splenius, left trapezius and right deltoid muscles.

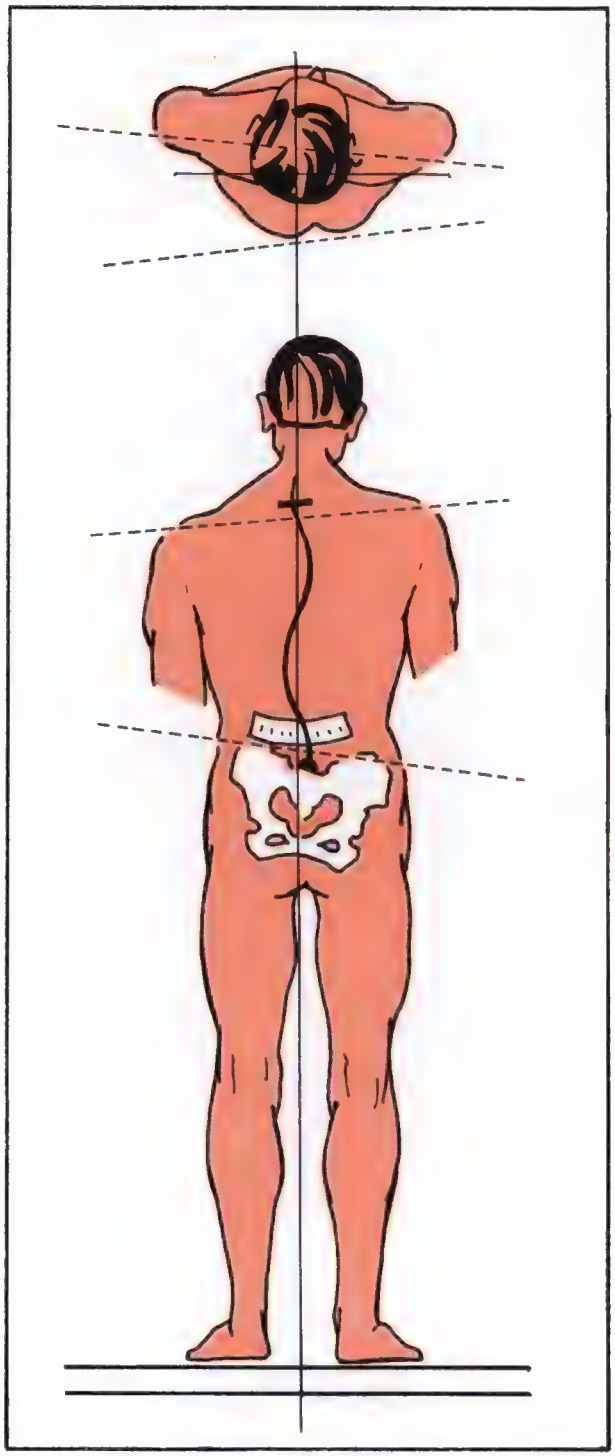

This illustration depicts weakness of the right quadratus lumborum, right psoas and right latissimus dorsi muscles.

Learn to quickly recognize these postural distortions in your patients at a glance, as they will serve as invaluable diagnostic tools and save you time and energy in determining the location of the muscular weaknesses.

# POSTURE MAY INDICATE A WEAKNESS[1]

| POSTURAL DEVIATION | POSSIBLE MUSCLE WEAKNESS |
|---|---|
| Ears not level: | Neck Muscles, Rhomboids, Sacrospinalis, Psoas, Gluteus Medius, Upper Trapezius. |
| Shoulders not level: | Latissimus Dorsi, Neck Muscles, Gluteus Medius, Upper Trapezius, Deltoids. |
| Hips not level: | Psoas, Adductors, Gluteus Medius. |
| Shoulders rotated: | Levator Scapulae, Latissimus Dorsi. |
| Head level but rotated: | Rhomboids, Abdominals, Trapezius, Sacrospinalis. |
| Pelvis twisted: | Psoas, Fascia Lata, Sartorius, Abdominals. |
| Hands rotated medially: | Teres Minor, Psoas. |
| Hand held away from the body: | Gluteus Medius. |
| Lordosis, belly hanging out or sway back: | Abdominals, Piriformis, Psoas. |
| Kyphosis, belly curved in or back curved out: | Sacrospinalis, Psoas. |
| Genu Varum, bowed legs: | Adductors, Fascia Lata, Gluteus Medius. |
| Genu Valgum, knock-knees: | Gracilis, Sartorius. |
| Knees hyperextended (knee pushed too far back): | Popliteus, Gastrocnemius, Quadriceps. |
| Forward lean: | Soleus. |
| Scoliosis, sideways curve of back: | Abdominals, Sacrospinalis, Latissimus Dorsi |
| Pes-Planus, ankle pronated or flat feet: | Psoas, Anterior Tibial. |
| Foot turned in (pigeon-toed): | Psoas. |
| Foot turned out: | Adductors, Hamstrings, Peroneus, Psoas, Gracilis. |
| Ankle supinated (bowed out): | Peroneus. |
| Difficulty placing hands behind back: | Trapezius, Upper Trapezius, Teres Major, Anterior Deltoid. |
| Difficulty raising arm: | Serratus Anterior, Rhomboids, Levator Scapulae, Deltoids, Abdominals, Supraspinatus, Teres Minor, Pectoralis Major Clavicular. |

[1]John F. Thie with Mary Marks, *Touch for Health* (California, 1973), p. 102.

# MUSCLE TESTING

Muscle testing is the most frequent diagnostic indicator used in Applied Chiropractic Kinesiological Diagnosis and Technique to locate disturbances or imbalances within the body. Muscle testing may also be used to determine the functional integrity of the muscle itself and its associated organ.

When using muscle testing as an indicator in therapy localization, challenge or nutrition, any muscle may be used as an "indicator muscle" or test muscle as long as it is conveniently located and tested in a position which is practical for the patient.

The technique of muscle testing demands the examiner's acute attention to every detail. Only one muscle should be tested at a time; and, therefore, the examiner must take great care to isolate each muscle. Also, the patient must be warned not to recruit allied muscles when resisting the examiner, as this will negate the test results.

Before an indicator muscle can be used as a diagnostic tool in therapy localization, challenge or nutrition, the examiner should test the muscle to determine its original status. For example, it is important to know if the muscle originally tested strong or weak in order to have a criterion for comparison.

One must use extreme caution in muscle testing to avoid creating stretch injuries or muscle cramping. The muscle being tested should never be overpowered. The object of muscle testing is to determine if the muscle tests strong and locks.

Muscle testing, although simple in principle, requires experience in its interpretation. No two patients test identically; but with experience, the examiner will be able to immediately determine if the muscle locks and, thus, avoid overworking the patient and fatiguing the muscle.

Accurate records should be maintained on muscle testing and treatment for each patient. Often, a patient will have recurring weakness in the same muscles, so accurate record keeping will enable the doctor to quickly test those muscles which were previously involved when the patient returns on subsequent visits.

Muscle testing is used throughout this textbook as a diagnostic tool. For specific instructions on how to perform the test for each muscle, see Chapter 4.

# TESTING MUSCLES IN VARIOUS POSITIONS

Many times patients will require examination in different positions if they have been chronically ill, have had recurrent faults or respond slowly to treatment. For example, the psoas often tests strong in a supine position, but when the patient is in a weight-bearing position, it may immediately become weak. To test the psoas in an erect, weight-bearing position, have the patient lean back against the adjusting table while it is in a vertical position and test the psoas in the usual fashion.

This position change is most frequently required for these patients when examining the psoas, cranial faults, the piriformis or carpal tunnel syndromes. If you are examing the patient's cranial faults in a horizontal position, try the vertical position, or if you are examining the piriformis in a prone position, try testing it in the prone position with the patient halfway on his knees. You might examine the carpal tunnel syndrome when the patient is in a vertical position if you originally examined him in the supine position.

Position change may be utilized to verify correction of recurrent problems or to uncover faults which originally tested negative in a prior position.

# K-27 AND THE UMBILICAL CONTACT

Occasionally, a patient will have a high right occiput but show muscle weakness on the left, or he may have a high shoulder and high hip on one side and the gluteus medius will test weak on the opposite side. The existence of such paradoxical muscle patterns may indicate the patient is "switched" or demonstrates weakness, signs or symptoms on the side of the body which is opposite to the fault. Therefore, treatment must be performed at K-27 and at the umbilical contact and the patient should be cross crawled.

K-27 is an acupuncture point located bilaterally at the junction of the first rib, sternum and clavicle. The umbilical contact is located immediately lateral to the umbilicus bilaterally and is the common neurolymphatic center for the lower body. K-27 and the umbilical neurolymphatic is treated simultaneously using both hands with soft-tissue manipulation in a rotary fashion for approximately 30 seconds per contact.

Stimulation of K-27 and the umbilical contact should be made routinely on all patients to prevent switching, as switching can confuse one's analysis of the patient. If this fails to correct the weakness, reactive muscle testing may be indicated.

K-27 alternates the flow of energy to one side of the body as opposed to the other, especially in flexion and extension of the lumbar spine. Fred Illie, D.C. has proven conclusively that flexion is necessary for rotation and rotation is necessary for flexion in the lumbar spine. Dr. Goodheart feels that K-27 literally functions as an alternator which sends impulses to one side of the lumbar spine and then the other, thus allowing a countertorque to take place.

A second form of switching has now been revealed. (See Umbilical-Coccygeal Contact.)

# INTERVERTEBRAL FORAMEN (I.V.F.)

The spine and the five elements which compose the intervertebral foramen are affected by all diseases. Likewise, these structures or elements can cause disease if they should become blocked or impinged in any way.

The following illustration represents man as an equilateral triangle with one side of the triangle being mental, one side being chemical and the base being structural. The five elements of the intervertebral foramen compose a circle which unites each of the sides of the triangle.

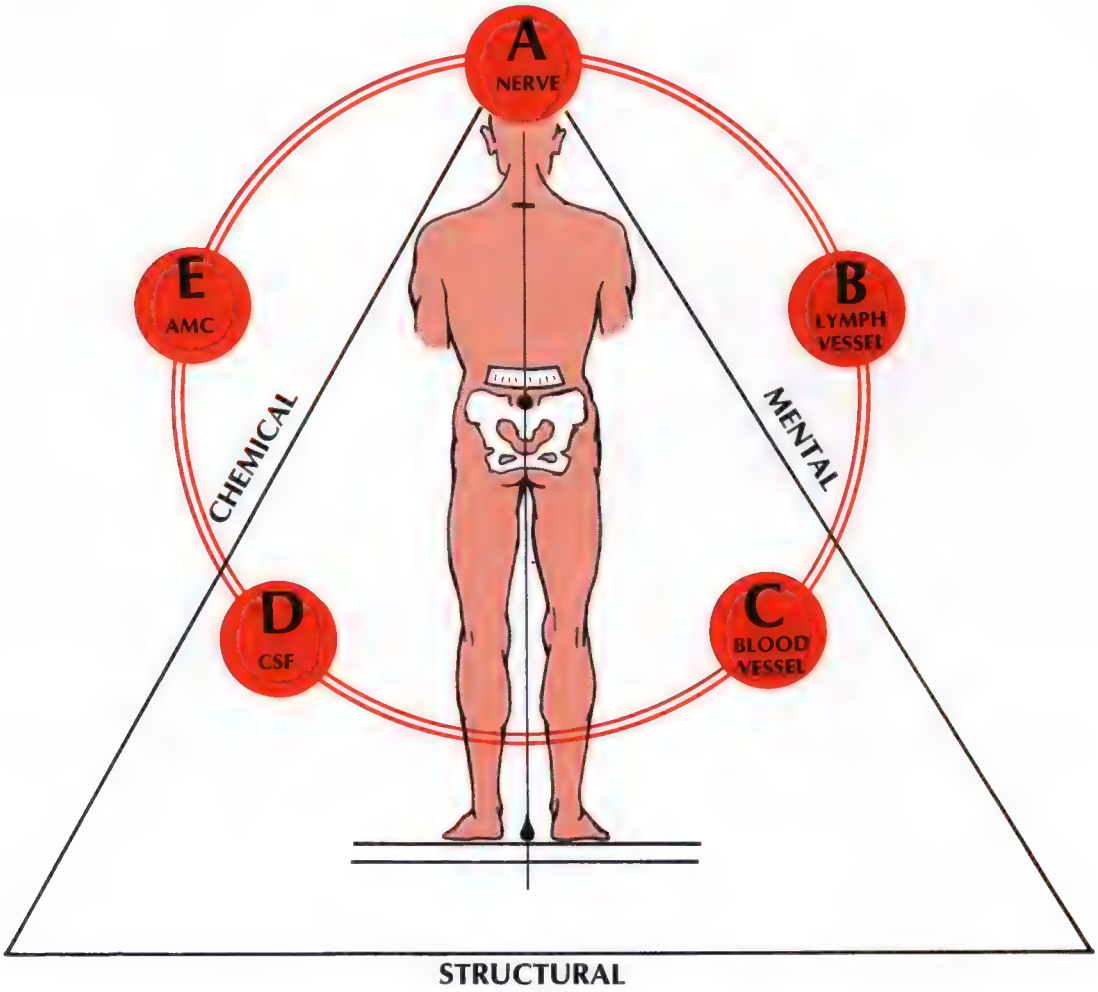


Listed below are the five elements of the intervertebral foramen and the various Applied Chiropractic Kinesiological Diagnostic Methods and Techniques which are associated with each element.

**A. NERVE**
1. Respiration
2. Nutrition
3. Golgi Tendon Apparatus
4. Spindle Cell Mechanism
5. Challenge Technique
6. Therapy Localization

**B. LYMPH VESSEL**
1. Neurolymphatic Receptor

**C. BLOOD VESSEL**
1. Neurovascular Receptor
2. Cranial Stress Center

**D. CEREBRAL SPINAL FLUID**
1. Respiratory Assistance
2. Challenge Technique

**E. ACUPUNCTURE MERIDIAN CONNECTOR**
1. Alarm Point
2. Point of Tonification
3. Point of Sedation
4. Command Point
5. Connecting Point

# CRANIAL AND SACRAL RESPIRATORY MOVEMENT

The importance of proper flow of the cerebral spinal fluid cannot be overemphasized. The cerebral spinal fluid flows basically from the choroid plexus, down and around the spinal cord and into the sacral water bed for reabsorption. Fluctuations in the volume or rhythm of the cerebral spinal fluid can change the heart rate and respiration. Since the dural envelope is inelastic and nonexpandable, the cerebral spinal fluid pressure varies directly with the venous pressure, and the venous pressure changes according to the cardiac rate and respiration. The very presence of cerebral spinal fluid acts as a buffer for the cord and brain, which is essential for body function. An intimate relationship exists between the cerebral spinal fluid and the lymphatic system, and cerebral spinal fluid contains secretions from the pituitary gland. Cerebral spinal fluid does not circulate in the ordinary sense of the word. After its movement down the cord via the subarachnoid space, most of the cerebral spinal fluid is absorbed through the paccionian bodies (arachnoid granulations) into the venous sinuses, after circulating around the brain. Some of that which flows down the brain stem and spinal cord escapes out along the cranial and spinal perineural spaces and, most importantly, through the hollow collagen fibers of the fascia into the lymphatic system.

The respiratory movements of the bones of the skull assist in a pumping action to circulate the cerebral spinal fluid. Many symptoms can occur from interference with the minute movements of the articulations of the bones of the skull. When the cranium fails to move in its normal respiratory pattern, it will result in altering the flow of the cerebral spinal fluid, which will cause a change in the general lymphatic flow and result in a breakdown of lymphatic function and drainage.

The occiput, the sphenoid, the ethmoid, the mandible, the hyoid, the vomer and the sacrum all rotate about a transverse axis and, as such, flex forward and extend backward with each inspiration and expiration. The remaining bones of the skull, which are midline structures, either externally rotate or internally rotate. The respiratory cycle is a flexion of the midline bones with an associated external rotation of the peripheral bones with a reversed cycle accompanying exhalation.

After one has found a weak muscle based upon T.S. Line palpation, postural index, body language, or simply by testing the muscle, one must then find the phase of respiration which will assist in strengthening the muscle. The following phases of respiration should be tested in the order specified until the phase of respiration which strengthens the muscle is located, except in forced inspiration challenge and forced expiration challenge which will result in a strong indicator muscle becoming weak.

| DESCRIPTION OF RESPIRATION | NAME OF PHASE IF FOUND EFFECTIVE |
|---|---|
| 1. Ask the patient to take a deep breath and hold it. | Inspiration Assist |
| 2. Ask the patient to force more air into his lungs and hold it.* | Forced Inspiration Challenge* |
| 3. Ask the patient to let one-half of the breath out and hold it. | Half Breath Out Assist |
| 4. Ask the patient to let out all the air and hold. | Expiration Assist |
| 5. Ask the patient to force all the air out of his lungs and hold.** | Forced Expiration Challenge** |
| 6. Ask the patient to take one-half of a breath in and hold it. | Half Breath In Assist |

*Forced inspiration challenge is actually a hidden expiration-assist fault because the correction is on expiration but the muscle weakness is exhibited on forced inspiration.

**Likewise, forced expiration challenge is actually a hidden inspiration-assist fault and is corrected on inspiration, but the fault is found on forced expiration which results in muscle weakness if the fault is extant. This order should be utilized to determine the patient's base of respiration.

Usually, the inspiration assist or the expiration assist will result in strengthening the muscle.

Taking a deep breath literally brings the occiput and mastoid portion of the temporal bone forward or anterior, thus improving the rate of the cerebral spinal fluid flow.

A weak muscle which is strengthened on expiration indicates the mastoid portion of the temporal bone and occiput must be moved backward in order to attain a better rate of cerebral spinal fluid flow.

It appears the pumping action needed to move the cerebral spinal fluid requires the valve to be totally open, and this is evidenced by the subsequent and immediate increase in muscle strength of any muscle which is found to be weak. This "totally open" position is the purpose behind utilizing the respiratory assist and is the method of finding out the patient's phase of respiration. The pumping action appears to open the valve on inspiration and close the valve on expiration. Imagine the cranial bones and articulations as gears and the point of neutral being respiratory zero or midpoint between inspiration and expiration. If the gears are in respiratory neutral on one side of the cranium and locked forward or backward on the opposite side, one can imagine the pressure and distortion placed on the valve and the subsequent effect it would have on the flow of the cerebral spinal fluid.

Proof of cranial bone movement is easy and can be demonstrated to anyone, anywhere. All one must do is find the phase of respiration which assists in correction of the hypotonic muscle via Applied Chiropractic Kinesiological Diagnosis. Then, apply the appropriate Applied Chiropractic Kinesiological Technique to correct the cranial fault, improve the cerebral spinal fluid flow and, in turn, correct the weak muscle. Once the weak muscle has been retested and found to be strong simply reverse the above procedure and the muscle will become weak, once again, when retested. For example, if inspiration assist helped the muscle gain strength, simply press the mastoid portion of the temporal bone forward on inspiration to strengthen it, and push the mastoid backward on expiration to weaken the muscle.

The occiput and the sacrum parallel one another in that the sacrum also has a respiratory function. As the sphenoid bones flex forward with inspiration, there is an accompanying forward movement of the sacrum. This sacral movement is produced by the lifting of the dura which helps perpetuate the pumping action produced by the cranial bone movement.

If the sacrum is rotated or tipped, it can cause an impairment of the flow of the cerebral spinal fluid and also cause cranial articular malposition. Cranial articular malposition and altered cerebral spinal fluid flow can also cause sacral malposition. However, the fault usually occurs first in the cranium and then affects the sacrum. There is no connection of any consequence below the 2nd or 3rd cervical unit of the dura until it reaches the level of the 2nd sacral segment. The end result is a rotation of the sacrum with the base moving posterior and the sacral apex moving anterior or toward the symphysis.

Respiration initiates skull bone movement as well as movement of the sacrum, and any interference with these vital interrelationships can cause physical problems with disease manifestations.

In order to check the position of the sacrum, put the patient in a prone position and therapy localize the sacrum while testing a hamstring. If there is a weakness of the hamstring muscle, direct the patient to take a deep breath and retest the hamstring. If this does not correct the weakness, ask the patient to exhale and retest the hamstring. Increased strength will be noted either on inspiration or expiration. If the muscle strengthened on inspiration, the sacral tip or apex must be adjusted lightly forward. If, on the other hand, expiration improved the muscle strength, a basic contact under the sacral apex on the side of weakness with the thumb of one hand and anterior pressure on the sacral base with the opposite hand is required. The contact under the sacral apex should be held constant for approximately 1 to 1½ minutes while the other hand places pressure 4 to 5 times on the sacral base on expiration. Retest the muscle to verify correction. (See Category I.)

The reason the correction is in the direction which appears to be opposite of the normal respiratory cranial motion is to exaggerate the lesion, thus allowing the rebound phenomenon of the body to correct the lesion properly.

# THERAPY LOCALIZATION TECHNIQUE

## (Dedicated to the beloved memory of Kitty Goodheart)

Therapy localization is the most marvelous diagnostic localizing technique developed in the history of Chiropractic. Consistent with all great findings, this technique is basically simple and parallels the following examples in concept:

1) If the skin is cut, the body immediately initiates processes which result in healing the cut. How does the body know it is cut or where it is cut? How does it know what to do about it?
2) Everybody knows that an apple is different than a steak, but how does the body know when to secrete a different digestive enzyme for each different food? We don't tell it, but it knows.
3) A newborn baby immediately begins a sucking motion when it is placed near its mother's breast. Having had no prior conditioning to the stimulus of food or its mother's breast, how does it know to make a sucking motion with its mouth?

Each of these physiological responses have been scientifically recognized, studied and eventually categorized as "innate responses." Likewise, therapy localization is considered an innate response whereby the patient's body tells the doctor where it has a fault. After all, who would know better than the patient's body?

D. D. Palmer made the following statement in "The Chiropractic Adjustor" published in 1914: "Too much or not enough nerve energy is disease." When there is too much of this "nerve energy," the body kicks out the circuit breakers, such as the neurolymphatics, the neurovasculars, cerebral spinal fluid, acupuncture meridian connector or the nerve. The original structural subluxation at any level causes an increase in function, which then produces a facilitation at that level of the spinal cord. The body then attempts to reduce this avalanche of impulses created by the subluxation and the body innately protects the circuitry by turning off the circuit breakers, which reduces the avalanche of impulses. On the other hand, when there is a fixation of a vertebral segment in any area, a fixation of the skull, sacrum and/or the iliac structures, there is insufficient movement. Normally, movement of these structures touches the nerves and stimulates body function. However, when there is a lack of movement, there is a lack of function, which may result in the too little "nerve energy" about which Palmer spoke. D. D. Palmer further emphasized the point by stating, "The cause of most disease is an oversupply of nerve force. Most diseases are because of too much energy and not because the nerve force is shut off."

We, as Chiropractors, are not dealing simply with bones, nerves and muscles, but rather energy patterns which can be interrupted by muscles, bones and energy blockages. Therapy localization can be used to determine whether the patient is suffering from too little or too much energy.

To use therapy localization, ask the patient to place his hand or hands lightly over the area in question and retest the muscle. If there is a lack of energy at that point, a weak muscle will become strong. This increase in strength is the result of increased energy to the deficient area derived from the hand. If there is too much energy at the therapy localized point, a strong muscle will become weak. The weakening of the muscle is the result of overactivity or facilitation and the additional energy derived from the hand magnifies this condition. Excess energy at a therapy localized point will cause the circuitry to overload and result in blowing out the muscle (causing it to become spontaneously weak). It is always better to therapy localize with both hands over the area in question when possible.

Therapy localization will indicate the presence of a fault in the patient's body, but it will not tell you what is wrong. Usually, challenge must be utilized following therapy localization in order to determine which Applied Chiropractic Kinesiological Technique is required to correct the fault or blockage.

If a patient does not therapy localize effectively, two factors may be involved:

1) The patient may need more water (pure) for the purpose of increasing conduction.
2) If a patient does not therapy localize where one suspects a fault exists, the patient should be asked to turn over his hands so that he might therapy localize with the opposite side. The back of the right hand is considered negative (–). The back of the left hand is considered positive (+). The front of the right hand is considered positive (+). The front of the left hand (palm) is considered negative (–). If a patient requires each section of their body to be therapy localized differently (in terms of positive or negative surfaces of the hands) this indicates the patient is in need of Nasal Respiratory Technique. (See chapter on Nasal Respiratory Technique.) Hereafter, under the subject of therapy localization, we shall refer to therapy localization with the positive and negative surfaces of the hand meaning the palms or nail surfaces.
3) It may occasionally be necessary to dampen the area to be therapy localized with pure water to increase conduction.

# TRANSFERENCE

The doctor's ability to adequately test muscles may be limited when treating patients who are very young, very old or who are in acute pain. However, through transference the doctor is able to use a second person to therapy localize the patient. This second person must first be examined and all gross structural faults must be eliminated. Place the second person's hand on the patient over the suspected area of involvement and retest the indicator muscle on the second person. If a fault is existent, a strong indicator muscle will become weak when tested on the second person. Then, challenge the fault to determine the direction of correction and retest the indicator muscle on the second person. Following correction, the doctor should retherapy localize the area, once again utilizing the second person to verify correction.

When using transference, keep in mind that only weakness transfers from the patient to the second person. Also, transference is most effective between two people of the same sex and people who are closely, empathically related.

# CHALLENGE TECHNIQUE

Challenge is used repeatedly in Applied Chiropractic Kinesiological Diagnosis and Technique. Generally, this term refers to pushing the segment, structure or tissue in one direction with light pressure (1 pound or less). After performing this challenge, always retest the indicator muscle within a matter of seconds and observe the response. The time factor, as well as the pressure used is critical. Spinal, pelvic and most cranial faults are always adjusted or corrected in the challenged direction which produces weakness of the indicator muscle and on the phase of respiration which abolishes the weakness. The body always rebounds in the opposite direction of the correction, and that is why the proper phase of respiration should be used in all corrections or adjustments. However, there are exceptions to this rebound phenomenon when adjusting the extremities and a few of the cranial faults, as these structures are adjusted or corrected in the direction which produces strength and on the phase of respiration which also produces strength.

For example, the atlas would be challenged as follows. Use a strong indicator muscle, e.g., hamstring. Press the atlas lightly anteriorly, posteriorly, laterally, superiorly, inferiorly, or in any compatible combination of these directions, testing the indicator muscle after each direction. After the correct line of correction has been established, add torque to the challenge in a counterclockwise or clockwise direction which will result in even greater weakness (retest the indicator after each direction of torque to determine the correct direction).

# TEMPORAL-SPHENOIDAL LINE

The Temporal-Sphenoidal Line was first observed by Dr. M. L. Rees of Sedan, Kansas. Dr. Rees associated the T.S. Line with visceral disturbances. In Applied Chriopractic Kinesiological Diagnosis and Technique, it has been found to be an invaluable aid for locating weak muscles.

The T.S. Line consists of 18 small points which are located along the border of the temporal and sphenoidal bones in the articulations between their adjacent osseous structures. Each point is less than one-quarter of an inch in total size and represents one or more muscles.

The T.S. Line should be palpated with a very light touch. If a muscle which has a corresponding point on the T.S. Line becomes weak, the point will reflect the weakness and become a palpable nodule. It will become swollen and tender to moderate pressure, which is easily verifiable by the patient. The fact that the T.S. Line points become swollen illustrates the articular motion of the skull. Palpation of the T.S. Line is difficult, but the information derived from this procedure is invaluable and well worth the time and effort required to master it. In older individuals, the T.S. Line is easier to palpate. Those findings derived from T.S. Line palpation should correspond to the doctor's postural and X-ray analyses.

After palpating the T.S. Line and making appropriate notes, the muscle should be checked to verify the weakness. The T.S. Line is infallible, but occasionally, due to the Five Element Law in acupuncture, the muscle which corresponds to the T.S. Line nodule may not test weak. This would indicate that the associated meridian is in excess. Therefore, the Five Element treatment method would have to be applied (see chapter on Acu-therapy). Other exceptions may be respiratory challenge faults (forced inspiration or forced expiration challenge), vertebral fixations and/or subluxations.

Keep in mind that the T.S. Line is utilized to locate weak muscles. Treatment of the muscle must be accomplished by any one of the five elements contained in the intervertebral foramen. If successful treatment has been administered, the nodule should disappear within 6 to 8 hours. The nodules on the T.S. Line are of a neurovascular nature. However, they will always indicate muscle weakness, which can be due to any one of the five elements of the intervertebral foramen.

If there is difficulty determining the presence of a nodule on the T.S. Line, then the muscle which corresponds to that point should be tested. If, for some reason, there is still doubt after testing the muscle, then therapy localization of the T.S. Line should be performed by placing one of the patient's fingertips (both positive and negative surfaces) on the point in question and retesting the corresponding muscle. If the point on the T.S. Line is a nodule, it will result in the weak corresponding muscle becoming strong. Positive therapy localization on the T.S. Line usually indicates that the neurovascular point, which is also associated with that muscle, is completely or partially responsible for the muscle weakness.

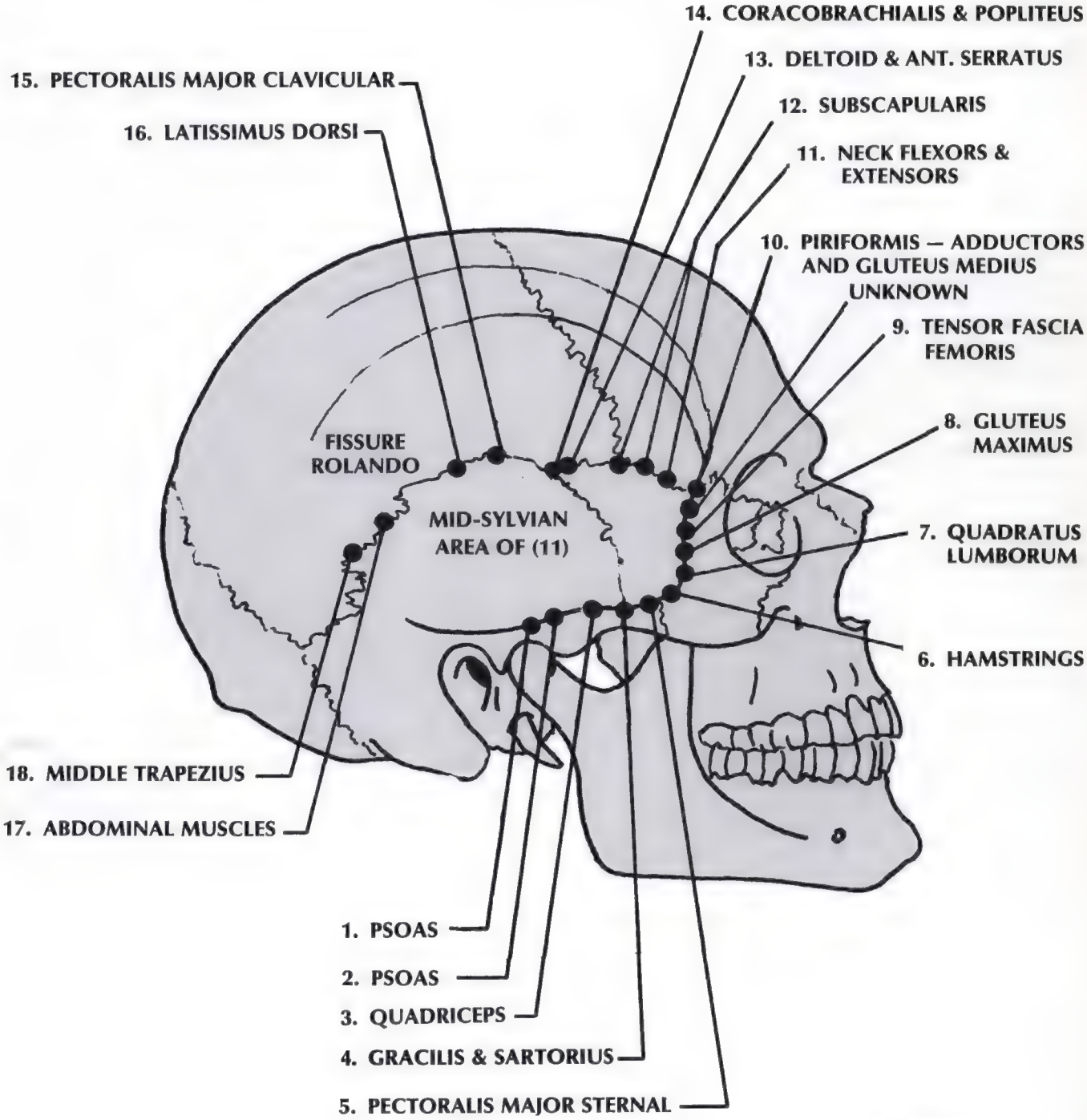


DR. T. BENNETT
DR. M. L. REES
DR. GEORGE GOODHEART

# NEUROVASCULAR RECEPTORS

The neurovascular receptors were first discovered by Terence Bennett, D.C. in the early 30's. Dr. Bennett primarily associated the neurovascular receptors with visceral disturbances and was not aware of the direct relationship between the neurovasculars and the musculoskeletal system. It was Dr. Goodheart who related the neurovascular points to specific muscles.

Lactic acid is a normal by-product of muscle contraction. Any blockage of the neurovascular receptor will prohibit the normal lactic acid response from occuring. Thus, lactic acid accumulates in the muscle and causes further dilation of the blood vessels. Any occuring dilation must take place through the nervous system, and any blockage of the neurovascular receptor will not allow the normal lactic acid response.

As can be seen from the following charts and illustrations, there are 16 neurovascular holding points on the body, and the majority of these points are located on the skull.

| MUSCLE | N.V. |
|---|---|
| ADDUCTORS | 7 |
| CORACOBRACHIALIS | 3 |
| DELTOID | 3 |
| DIAPHRAGM | 3, 5, 6 |
| GLUTEUS MAXIMUS | 7 |
| GLUTEUS MEDIUS & MINIMUS | 4 |
| GRACILIS | 6 |
| HAMSTRINGS | 5 |
| INFRASPINATUS | 4 |
| JAW MUSCLES | 13 |
| LATISSIMUS DORSI | 9 |
| NECK FLEXORS & EXTENSORS | 13 |
| PECTORALIS MAJOR — CLAVICULAR | 1 Left |
| PECTORALIS MAJOR — STERNAL | 2 Right |
| PERONEUS LONGUS & BREVIS | 1 |

| MUSCLE | N.V. |
|---|---|
| PIRIFORMIS | 4 |
| POPLITEUS | 15 |
| PSOAS MAJOR | 8 |
| QUADRATUS LUMBORUM | 4 Right |
| QUADRICEPS FEMORIS | 4 |
| SARTORIUS | 6 |
| ANTERIOR SERRATUS | 3 |
| SUBSCAPULARIS | 3 |
| SUPRASPINATUS | 3 |
| TENSOR FASCIA LATA | 4 |
| TERES MINOR | 11, 14 |
| ANTERIOR TIBIALIS | 1, 4 |
| TRAPEZIUS — MIDDLE & LOWER | 5 |
| TRAPEZIUS — UPPER | 12 |
| WRIST EXTENSORS | 16 |

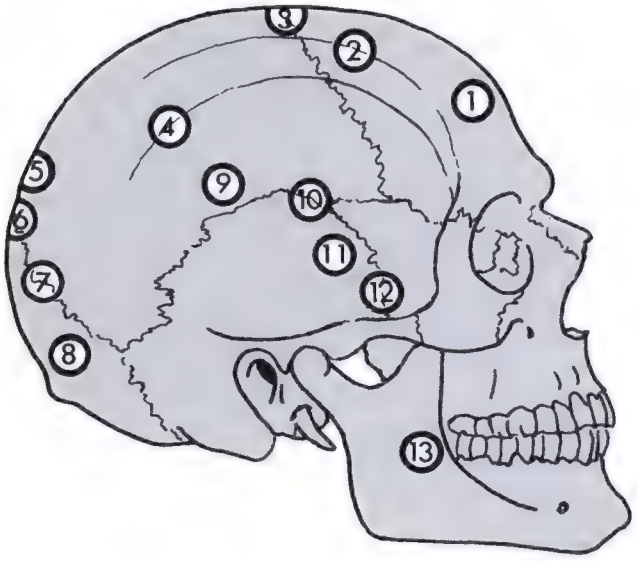

# NEUROVASCULAR RECEPTORS

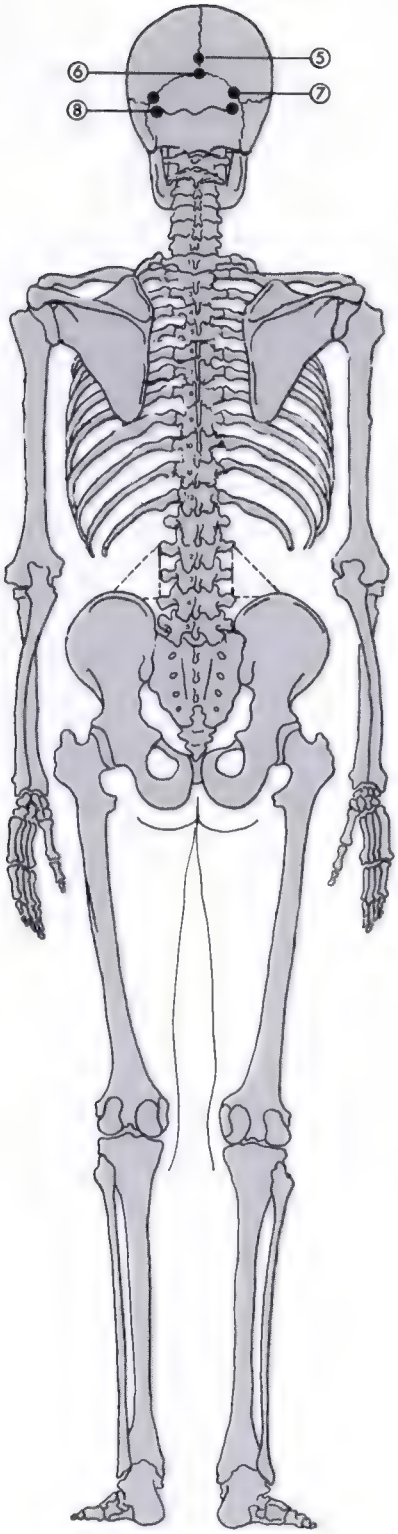


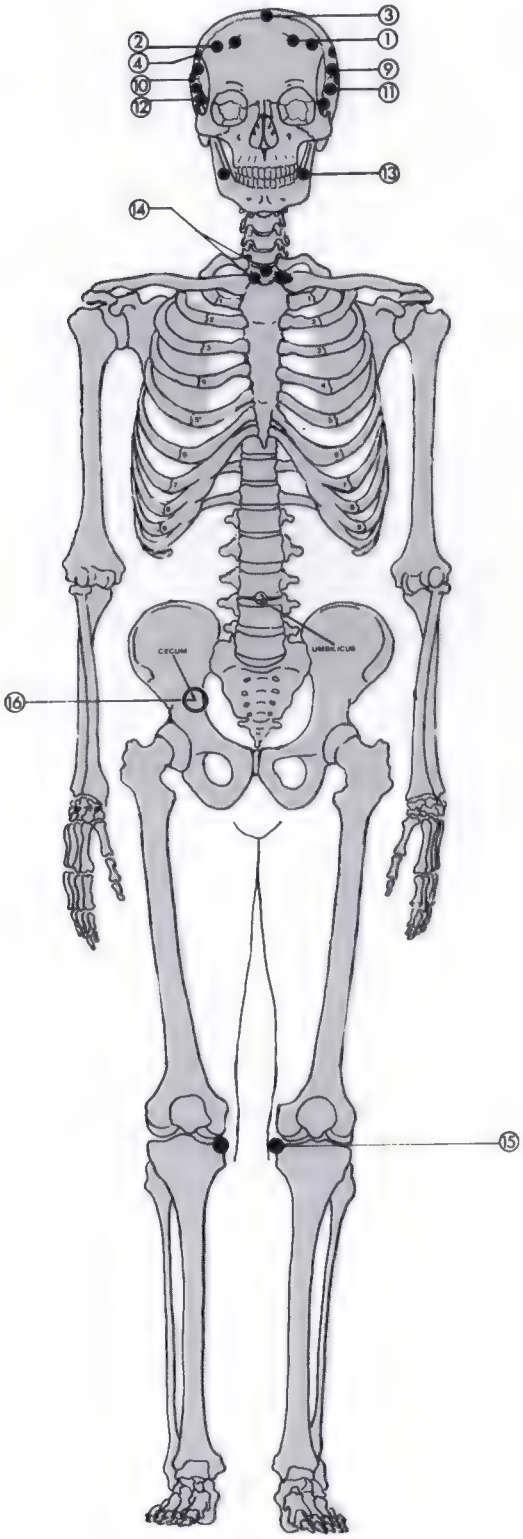

If a muscle is tested and found to be weak, then therapy localize its neurovascular holding point by placing a finger from each of the patient's hands over the neurovascular in question and retesting the weak muscle. If that neurovascular is at fault, it will result in the weak muscle becoming strong. If the muscle weakness is bilateral, a finger from each hand should be placed on the neurovasculars bilaterally.

If neurovascular treatment is indicated, make bilateral contact on the neurovascular holding point which is associated with the weakened muscle. Utilize a light contact with the pads of the fingers, stretching the skin slightly. A few seconds after the contact is made, a slight pulse can be felt over these points. Hold these points until the pulse becomes bilateral and equal, which usually occurs within 10 to 20 seconds. In extremely chronic or severe conditions, it may be necessary to hold these points up to 10 minutes, but this is rare.

After treatment has been administered in the above fashion, there will be an overwhelming increase in the strength of the muscle due to an increase in the blood circulation. Also, the associated organ of the muscle will improve in function. Following treatment of the neurovasculars, retherapy localize the neurovascular point to verify that the holding time was sufficient in duration. If the holding time was not sufficient, the muscle would indicate this fact by remaining weak upon retesting.

The neurovascular pulse is not related directly to the heartbeat, but is believed to be the primitive pulsation of the microscopic capillary beds in the skin.

# NEUROLYMPHATIC RECEPTORS

The neurolymphatic receptors were first discovered by Dr. Chapman, but he was not aware of their relationship to the myological system. George Goodheart, D.C. correlated the neurolymphatic receptors to the muscles as they are presented in this text.

The lymphatic system acts as the sewage system of the body, and any interference with this lymphatic drainage results in muscular weakness. The neurolymphatic reflex points act like circuit breakers or switches which turn off when the lymphatic system is overloaded. The neurolymphatic receptors do not correspond in location to the lymph glands, but are directly related to the lymph system.

The neurolymphatic receptors are located mainly on the chest and back and vary in size from the size of a small pencil eraser to that of a large bean. They may also occur singularly or in multiples. Most muscles have approximately four neurolymphatic drainage points. Usually, two points are located on the front of the body and two are located on the back.

When a muscle contracts, it produces lactic acid, and this lactic acid accumulates and causes further dilation in the blood vessels of the muscle. Since the dilation must take place through the nervous system, any blockage of the neurovascular or neurolymphatic receptors prohibits this dilation and results in an abnormal lactic acid response.

Stimulation of the neurolymphatic receptors activates the lymphatic circuit breaker which, in turn, allows the normal lymphatic drainage which is necessary for proper muscular tissue respiration.

If a muscle is found weak on examination, then therapy localize the neurolymphatic receptor responsible for the drainage of that particular muscle by placing either one or both of the patient's hands on the neurolymphatic point and retesting the weak muscle. If the neurolymphatic is responsible for the muscle weakness, therapy localization will result in the weak muscle becoming strong.

If the neurolymphatic receptor is found to be partially or totally responsible for the muscle weakness then stimulate the point on the anterior and posterior surfaces of the body, on the side of muscle weakness, with a soft-tissue manipulation in a circular direction. The direction of stimulation varies from point to point and patient to patient, so one must challenge the receptor or ask the patient to stimulate the receptor in each direction while the muscle is tested to determine its circular pattern (clockwise or counterclockwise). Soft-tissue manipulation in the proper direction will result in an increase of the muscle strength.

Repeat this circular motion 8 to 10 times and then retest the muscle to ascertain if increased strength has occurred. Then, therapy localize the neurolymphatic receptor to determine if the blockage has been totally eliminated. If the point requires more stimulation, the muscle will test weak upon retherapy localization.

# NEUROLYMPHATIC RECEPTORS

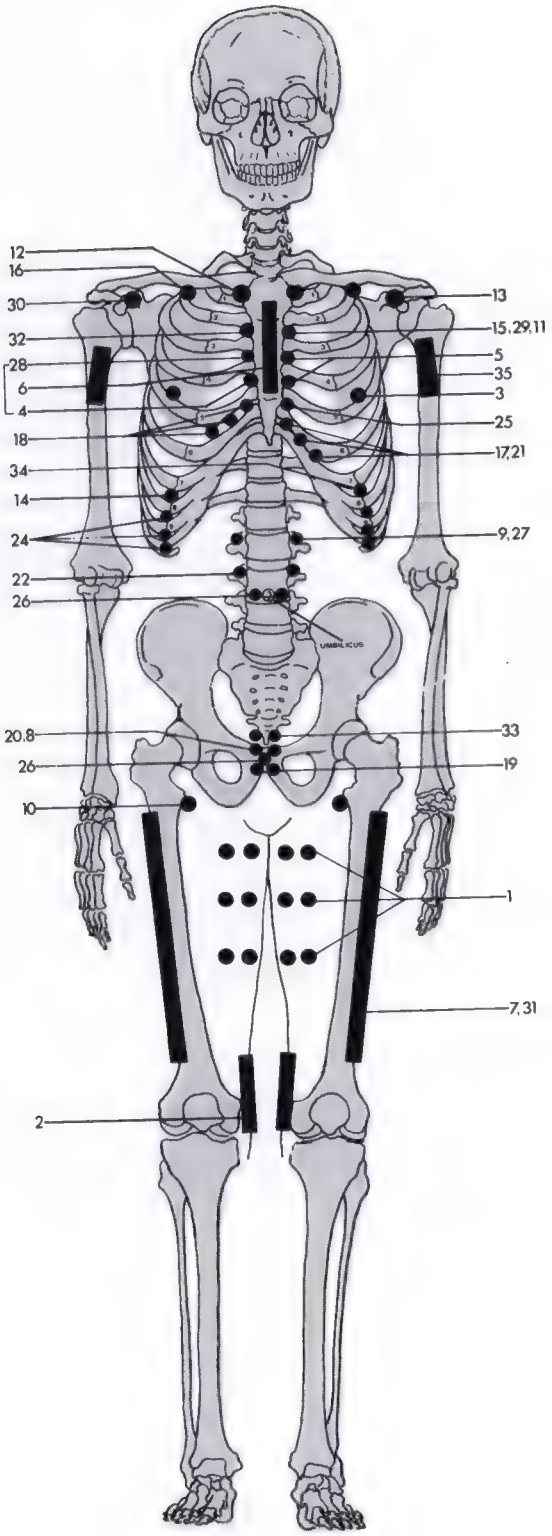


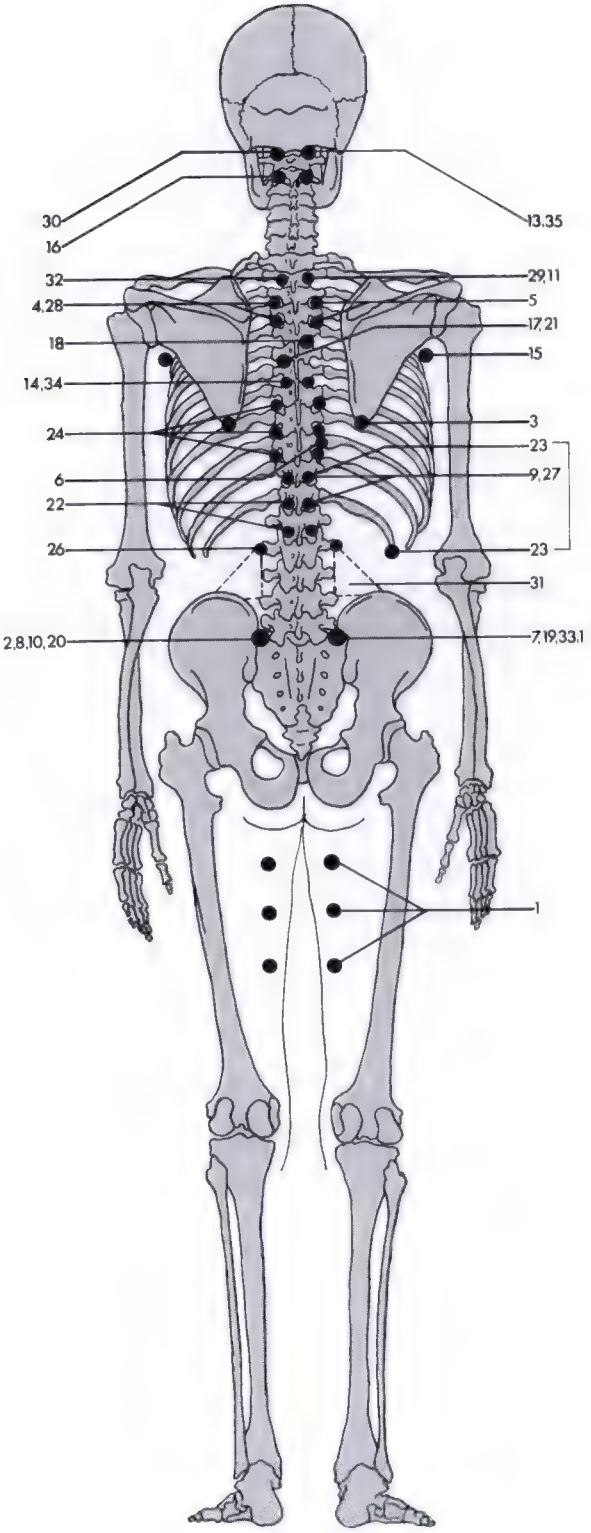

# NEUROLYMPHATIC RECEPTORS

| MUSCLE | N.L. |
|---|---|
| ABDOMINALS — TRANSVERSE | 1 |
| ABDOMINALS — RECTUS | 2 |
| ADDUCTORS | 3 |
| CORACOBRACHIALIS | 4 |
| DELTOID | 5 |
| DIAPHRAGM | 6 Right |
| GLUTEUS MAXIMUS | 7 |
| GLUTEUS MEDIUS & MINIMUS | 8 |
| GRACILIS | 9 |
| HAMSTRINGS | 10 |
| INFRASPINATUS | 11 |
| INTRINSIC SPINAL MUSCLES (K-27) | 12 |
| JAW MUSCLES | 13 |
| LATISSIMUS DORSI | 14 |
| LEVATOR SCAPULAE | 15 |
| NECK FLEXORS & EXTENSORS | 16 |
| PECTORALIS MAJOR — CLAVICULAR | 17 |
| PECTORALIS MAJOR — STERNAL | 18 |
| PERONEUS LONGUS & BREVIS | 19 |
| PIRIFORMIS | 20 |
| POPLITEUS | 21 |
| PSOAS MAJOR | 22 |
| QUADRATUS LUMBORUM | 23 |
| QUADRICEPS FEMORIS | 24 |
| RHOMBOIDS | 25 |
| SACROSPINALIS | 26 |
| SARTORIUS | 27 |
| ANTERIOR SERRATUS | 28 |
| SUBSCAPULARIS | 29 |
| SUPRASPINATUS | 30 |
| TENSOR FASCIA LATA | 31 |
| TERES MINOR | 32 |
| ANTERIOR TIBIALIS | 33 |
| TRAPEZIUS — MIDDLE & LOWER | 34 Left |
| TRAPEZIUS — UPPER | 35 |

# NUTRITION AND APPLIED KINESIOLOGICAL DIAGNOSIS AND TECHNIQUE

Individuals who have suffered esophageal damage often require surgical repair, whereby an artificial opening or stoma is made in the stomach. Through the stoma, these people are fed liquified and nutritionally balanced food containing the proper amount of vitamins and supplements. In spite of a well-balanced diet, these patients do very poorly and develop many problems, such as anemia, kidney stones and arthritis. However, when these patients are asked to chew the food (irrespective of their inability to swallow it), there is an immediate improvement in their general health.

We have all observed an infant stop crying and start smiling immediately upon the ingestion of food. The response could not be digestive in nature because of the time factor.

Further, if the iodine content of a piece of seafood is first measured, and the patient is then asked to chew the seafood, it will be found that there is a great reduction in the measurable iodine content of the food after it has been chewed. This phenomenon has been observed by many biochemists and is widely recognized. The parotid glands act as an electromagnet and draw the iodine out of the food for subsequent use by the thyroid.

Prompted by the implications of these three seemingly unrelated incidents, Dr. Goodheart designed an experiment to determine if muscle response could be affected merely by chewing nutritional concentrates. A patient was selected who had responded to treatment for an adrenal disturbance and low blood pressure, but who failed to respond to thyroid treatment. The teres minor muscle, which is commonly involved in thyroid disorders, tested weak on this patient. The patient was taking nutritional support for the thyroid in adequate amounts, but the teres minor muscle was still found to be weak upon retesting. Following kinesiological treatment of the muscle, only a fair response was noted. The patient was asked to chew the nutritional concentrate which she had been taking for thyroid support, and the teres minor muscle was retested prior to the patient swallowing the concentrate. There was an immediate increase in the strength of the teres minor muscle, and the patient also remarked that her sense of well-being had improved immediately. This experiment was validated by repeated observations of over 200 separate cases. Then, a double-blind study was performed whereby neither the patient nor the doctor knew the nature of the substance the patient was requested to chew. The response was appropriate and immediate to the nutritional concentrates.

Therefore, for maximum nutritional effectiveness, ask your patients to chew the nutritional substances you prescribe before swallowing them.

## NUTRITIONAL TESTING

If the pectoralis major sternal is tested and found to be weak, and the patient is suspected of having a vitamin deficiency, hold the muscle in question in its testing position and give the patient a low concentrate of natural vitamin A (1500 units). Ask the patient to chew the substance. Ten seconds after the substance has been chewed, retest the muscle. If the patient is deficient in the substance being tested, there will be a phenomenal increase in the muscle strength. If the substance is not needed by the patient, the muscle will remain weak.

Repeated tests have shown that small doses of vitamins, minerals or protomorphogens improve muscle strength faster and more effectively than macrodoses of the same substance. For example, if a patient needs vitamin E to strengthen a gluteus medius muscle, 400 I.U. of vitamin E is rarely effective. However, a microdose of 2 to 50 I.U. of vitamin E will always bring about an observable response.

The innate intelligence of the body is unerring in sensing what the body needs, the amount it needs and where it needs it. If a patient is found to be deficient in vitamin A and E and is given both substances at the same time to chew, a weak right pectoralis major sternal and a weak left gluteus medius will respond simultaneously to a microdose of these substances.

Through the miracle of therapy localization, the examiner can now determine the effect of a nutritional substance on a related organ, tissue or muscle. For example, if a patient is found to have a weak sartorius (adrenal glands) and it does not respond to adrenal concentrates, one could determine through therapy localization if supportive nutritional therapy to the thyroid would benefit the adrenals and, thus, the sartorius muscle. The examiner would give the patient a thyroid protomorphogen and ask the patient to put his hands over the adrenal glands. If the substance is needed by the thyroid to help support the adrenal glands, the sartorius will become strong, or if the sartorius tests strong and the doctor asks the patient to therapy localize the adrenals, and this results in the sartorius becoming weak, this would be indicative of the adrenal gland needing nutritional support. It could also indicate that one of the endocrine glands is not supporting its fellow glands as it should. The patient may then be asked to place one hand on the adrenal gland (same side as the muscle tested) and then with the other hand therapy localize the other related glands to determine their relative effect.

## MUSCLES AND RELATED NUTRITION

Multiple vitamins are not generally recommended. Due to the bombardive effect of macrodosed multiple vitamins, they do not produce good kinesiological test results, except occasionally for patients who are fast oxidizers.

Muscles have been tested on hundreds of occasions with different nutritional substances, and research has now revealed that the following muscles have a direct relationship to these corresponding nutritional substances.

| MUSCLE | BODY MECHANISM | RECOMMENDED DIETARY SUPPLEMENT |
|---|---|---|
| ABDOMINIS — RECTUS | DUODENAL | VITAMIN E |
| ABDOMINIS — TRANSVERSALIS | DUODENAL | VITAMIN E |
| ADDUCTORS — LONGUS, BREVIS & MAGNUS | CLIMACTERIC | VITAMIN E |
| ANTERIOR TIBIALS | URETHRA | VITAMIN B & G |
| CORACOBRACHIALIS | LUNG | VITAMIN C, LUNG PROTOMORPHOGEN |
| DELTOID — ANTERIOR, POSTERIOR & MEDIALIS | LUNG | VITAMIN C, LUNG PROTOMORPHOGEN |
| GASTROCNEMIUS | ADRENALS | ADRENAL EXTRACT |
| GLUTEUS MAXIMUS | SEX GLANDS | VITAMIN E, OVARIAN EXTRACT, MALE HORMONE |
| GLUTEUS MEDIUS | UTERUS & SEMINAL VESICLES | VITAMIN E, UTERINE EXTRACT, PROSTATE EXTRACT |
| GLUTEUS MINIMUS | UTERUS & SEMINAL VESICLES | VITAMIN E, UTERINE EXTRACT, PROSTATE EXTRACT |
| GRACILIS | ADRENALS | ADRENAL EXTRACT |
| HAMSTRINGS | RECTUM | VITAMIN E, WHEAT GERM OIL |
| ILIACUS | ILEO-CECAL VALVE | CHLOROPHYLL COMPLEX, BETAINE HYDROCHLORIDE |
| LATISSIMUS DORSI | PANCREAS | VITAMIN A, F & B COMPLEX, PANCREATIC PROTOMORPHOGEN |
| PECTORALIS MAJOR CLAVICULAR | GASTRIC | VITAMIN B & G |
| PECTORALIS MAJOR CLAVICULAR — BILATERAL WEAKNESS | ALLERGY, ETC. | BETAINE HYDROCHLORIDE |
| PECTORALIS MAJOR STERNAL | LIVER | VITAMIN A, BILE SALTS, LIVER PROTOMORPHOGEN |
| PERONEUS — LONGUS & BREVIS | BLADDER | VITAMIN B & C, GASTRIC ENZYMES |
| PIRIFORMIS | UTERUS OR SEMINAL VESICLES | VITAMIN E, UTERINE EXTRACT, PROSTATE EXTRACT |
| POPLITEUS | GALLBLADDER | GALLBLADDER EXTRACTS OF BILE SALTS |

Chart Continued:

| MUSCLE | BODY MECHANISM | RECOMMENDED DIETARY SUPPLEMENT |
|---|---|---|
| PSOAS | KIDNEY | VITAMIN E & A, KIDNEY EXTRACT |
| QUADRICEPS | SMALL INTESTINE | VITAMIN D |
| SACROSPINALIS | CYSTITIS | LIVER EXTRACT, VITAMIN A & C |
| SARTORIUS | ADRENALS | ADRENAL EXTRACT |
| SCALENE | SINUS | NIACINAMIDE & $B_6$ |
| SERRATUS | LUNG | VITAMIN C, LUNG PROTOMORPHOGEN |
| SOLEUS | ADRENALS | ADRENAL EXTRACT |
| SPLENIUS CAPITIS | SINUS | $B_6$ & NIACINAMIDE |
| STERNOCLEIDOMASTOID | SINUS | $B_6$ & NIACINAMIDE |
| SUBSCAPULARIS | HEART | CARDIAC PROTOMORPHOGEN |
| SUPRASPINATUS | BRAIN | RIBONUCLEIC ACID, BRAIN PROTOMORPHOGEN |
| TENSOR FASCIA LATA — UNILATERAL | COLON | VITAMIN B & D, INTESTINAL ENZYME, LACTOBACILLUS ACIDOPHILUS |
| TENSOR FASCIA LATA — BILATERAL | COLON | ORGANIC IRON, VITAMIN $B_{12}$; BILE SALTS, BETAINE HYDROCHLORIDE |
| TERES MAJOR | ACID-ALKALINE BALANCE | ORGANIC MINERALS, PHOSPHORUS |
| TERES MINOR | THYROID | ORGANIC IODINE, THYROID |
| TRAPEZIUS — UPPER | EYE, EAR | VITAMIN F & G |
| TRAPEZIUS — MIDDLE & LOWER | SPLEEN | VITAMIN C, SPLEEN EXTRACT |
| ANY MUSCLE | SLOW OXIDIZER | ALFALFA, YEAST, WHEAT GERM, LOW DOSES NATURAL MULTIPLE VITAMINS |
| ANY MUSCLE, ADDITIONAL HELP | FAST OXIDIZER | VITAMIN B, C & G, LUNG PROTOMORPHOGEN |

# FAST AND SLOW OXIDIZERS

Occasionally, after the proper nutritional concentrate has been administered, the patient may not respond as anticipated. This may be due to the patient's oxidation rate.

Dr. George Watson classifies people with these metabolic disturbances into two distinct types — "fast oxidizers" and "slow oxidizers." [2] A fast oxidizer is one who breaks down sugar in the tissues unusually rapidly, with a resultant depletion of the stores of the energy-rich intermediate acetate. A slow oxidizer is one who burns carbohydrates inefficiently, rather than too quickly. For the slow oxidizer, a diet which contains too much fat and protein would be undesirable, because unless sugar is being broken down normally, neither fat nor protein can be turned into energy.

The following questionnaire developed by Dr. George Watson will help determine if a patient is a fast oxidizer, a slow oxidizer or a normal oxidizer. A slow oxidizer will answer "always" or "very often" to most (17 or more) of the questions numbered 1, 2, 3, 6, 7, 11, 15, 16, 18, 19, 20, 22, 23, 26, 27, 33, 37, 41, 49, 50 or 51. If a patient is a fast oxidizer, he will answer "always" or "very often" to most (25 or more) of the questions numbered 4, 5, 8, 9, 10, 12, 13, 14, 17, 21, 24, 25, 28, 29, 30, 31, 32, 34, 35, 36, 38, 39, 40, 42, 43, 44, 45, 46, 47, 48 or 52. One is considered "normal" if he answers most (40 or more) of the questions "sometimes" or if he answers "always" or "very often" to both slow oxidizer questions (14 or more) and to fast oxidizer questions (20 or more).

## NUTRITION QUESTIONNAIRE[3]

1. If I drink tea I prefer lemon with it. (S)
   ☐ always or very often ☐ sometimes ☐ never or rarely
2. A hamburger sandwich tastes much better with a slice of raw onion on it. (S)
   ☐ always or very often ☐ sometimes ☐ never or rarely
3. When I feel low I pick right up if I eat something sweet such as fruit, pastry, or candy. (S)
   ☐ always or very often ☐ sometimes ☐ never or rarely
4. I could enjoy eating potatoes in some form two or three times a day. (F)
   ☐ always or very often ☐ sometimes ☐ never or rarely
5. I could eat steak or roast beef every day and frequently more than once a day. (F)
   ☐ always or very often ☐ sometimes ☐ never or rarely
6. I seem to crave sour-tasting foods. (S)
   ☐ always or very often ☐ sometimes ☐ never or rarely
7. Raw salad vegetables such as radishes, green onions, green peppers, and lettuce agree with me, and I like to eat them. (S)
   ☐ always or very often ☐ sometimes ☐ never or rarely
8. Fatty meat such as beef short ribs, spare ribs, or roast pork tastes better than very lean meat. (F)
   ☐ always or very often ☐ sometimes ☐ never or rarely
9. When I feel low I feel better if I eat something salty, like nuts, potato chips, or popcorn. (F)
   ☐ always or very often ☐ sometimes ☐ never or rarely
10. Sometimes I sort of drag through the day, but after a good meat dinner in the evening I begin to snap out of it. (F)
    ☐ always or very often ☐ sometimes ☐ never or rarely

[2]For more information on fast and slow oxidizers, see: Dr. George Watson, *Nutrition and Your Mind* (New York, 1972).

[3]Ibid., p. 93-99.

11. If I don't feel hungry and I eat something sweet, my appetite seems to pick up. (S)
☐ always or very often ☐ sometimes ☐ never or rarely

12. Steak for breakfast sounds pretty good to me. (F)
☐ always or very often ☐ sometimes ☐ never or rarely

13. I get hungry between meals and like a snack of peanuts, cheese and crackers, or maybe a hot dog. (F)
☐ always or very often ☐ sometimes ☐ never or rarely

14. For lunch I could eat a bacon and avocado sandwich with lots of mayonnaise. (F)
☐ always or very often ☐ sometimes ☐ never or rarely

15. I would like lettuce, cottage cheese, and fruit salad for lunch. (S)
☐ always or very often ☐ sometimes ☐ never or rarely

16. I have a craving for something sweet. (S)
☐ always or very often ☐ sometimes ☐ never or rarely

17. I feel better if I have some eggs with bacon or other kind of meat for breakfast. (F)
☐ always or very often ☐ sometimes ☐ never or rarely

18. When I'm hot and thirsty I can drink a lot of something like lemonade. (S)
☐ always or very often ☐ sometimes ☐ never or rarely

19. I like to eat raw onions. (S)
☐ always or very often ☐ sometimes ☐ never or rarely

20. I can easily skip breakfast without getting hungry or tired. (S)
☐ always or very often ☐ sometimes ☐ never or rarely

21. I prefer roast beef well done to roast beef cooked rare. (F)
☐ always or very often ☐ sometimes ☐ never or rarely

22. For breakfast I feel good with something like toast and coffee. (S)
☐ always or very often ☐ sometimes ☐ never or rarely

23. I like to drink buttermilk. (S)
☐ always or very often ☐ sometimes ☐ never or rarely

24. Steak and lobster is my idea of a real dinner, and I could eat them together. (F)
☐ always or very often ☐ sometimes ☐ never or rarely

25. Even after a big steak dinner I could eat a bowl of buttered popcorn. (F)
☐ always or very often ☐ sometimes ☐ never or rarely

26. I get thirsty and drink a lot of water. (S)
☐ always or very often ☐ sometimes ☐ never or rarely

27. I get so hungry that I have to eat something sweet between meals. (S)
☐ always or very often ☐ sometimes ☐ never or rarely

28. When I take the cap off a jar of mustard, the smell is so sharp that it hurts my nose. (F)
☐ always or very often ☐ sometimes ☐ never or rarely

29. I like the taste of olive oil. (F)
☐ always or very often ☐ sometimes ☐ never or rarely

30. If I drink coffee, it seems to make me feel jumpy or jittery. (F)
☐ always or very often ☐ sometimes ☐ never or rarely

31. I like to eat any kind of olives. (F)
☐ always or very often ☐ sometimes ☐ never or rarely

32. I like to eat bacon. (F)
☐ always or very often ☐ sometimes ☐ never or rarely

33. Avocados taste oily or too fat to me. (S)
☐ always or very often ☐ sometimes ☐ never or rarely

34. I seem to need a lot of salt on my food. (F)
☐ always or very often ☐ sometimes ☐ never or rarely

35. I would like a pat of butter added to my soft-boiled eggs. (F)
☐ always or very often ☐ sometimes ☐ never or rarely

36. I seem to want something more to eat like cheese or nuts even after I have eaten a regular dinner. (F)
☐ always or very often ☐ sometimes ☐ never or rarely

37. I can eat breakfast only if it is something sweet. (S)
☐ always or very often ☐ sometimes ☐ never or rarely

38. Sweet foods like candy or cake taste too sweet to me. (F)
☐ always or very often ☐ sometimes ☐ never or rarely

39. I like a pat of butter on a steak. (F)
☐ always or very often ☐ sometimes ☐ never or rarely

40. Sweet things taste sweet enough to me. (F)
☐ always or very often ☐ sometimes ☐ never or rarely

41. I prefer to eat mustard, catsup, or steak sauce on a meat patty. (S)
☐ always or very often ☐ sometimes ☐ never or rarely

42. I seem to feel a bit weak if I haven't eaten for two or three hours. (F)
☐ always or very often ☐ sometimes ☐ never or rarely

43. I could eat four to six pieces of bacon for breakfast. (F)
☐ always or very often ☐ sometimes ☐ never or rarely

44. I don't like the smell of cooking food, even though it tastes all right when I eat it. (F)
☐ always or very often ☐ sometimes ☐ never or rarely

45. I'd like broiled lamb chops for dinner. (F)
☐ always or very often ☐ sometimes ☐ never or rarely

46. Grapefruit juice tastes very sour to me. (F)
☐ always or very often ☐ sometimes ☐ never or rarely

47. I would like to eat baked beans with a lot of nice lean salt pork in them. (F)
☐ always or very often ☐ sometimes ☐ never or rarely

48. If I feel a little nauseated, I feel better if I eat something salty. (F)
☐ always or very often ☐ sometimes ☐ never or rarely

49. If I feel a little nauseated, I feel better if I eat something sour or sweet. (S)
☐ always or very often ☐ sometimes ☐ never or rarely

50. I could drink a large glass of grapefruit or orange juice. (S)
☐ always or very often ☐ sometimes ☐ never or rarely

51. If I eat liver, I want onions with it. (S)
☐ always or very often ☐ sometimes ☐ never or rarely

52. I would prefer to eat bacon with fried liver. (F)
☐ always or very often ☐ sometimes ☐ never or rarely

If it has been determined that a patient is either a fast oxidizer or a slow oxidizer, the following foods should be used sparingly:[4]

| FAST OXIDIZER — FOODS TO USE SPARINGLY | |
|---|---|
| **SWEETS:** | Candy, pastries, fruit, jams, jellies, ice cream, gelatin desserts, etc. |
| **STARCHES:** | Potatoes, rice, spaghetti, macaroni, bread, crackers, cereals, etc. |
| **SALADS:** | Lettuce, green peppers, onions, radishes, cabbage, pickles, cucumbers, etc. (celery and carrots excepted). |
| **PROTEINS:** | Milk, buttermilk, cottage cheese, eggs, fish (except herring, sardines, anchovies, tuna, salmon). |
| **MISCELLANY:** | Catsup, spicy sauces, soft drinks, coffee (decaffeinated coffee excepted), tea, beer, wine, or any other alcoholic beverage. |

| SLOW OXIDIZER — FOODS TO USE SPARINGLY | |
|---|---|
| **SWEETS:** | Pastries high in fat and low in flour, such as cheesecake, tortes, Danish pastries, etc. |
| **VEGETABLES:** | Avocados, artichoke hearts, beans, peas, lentils, cauliflower, spinach, asparagus. |
| **PROTEINS:** | Foods with high purine content, such as liver, kidney, caviar, meat concentrates, etc. (See chart, p. 96.) |
| **FATS:** | Lard and butter should be replaced by corn oil or safflower oil margarine. |
| **MISCELLANY:** | Hard alcoholic beverages. |

[4]Watson, p. 114 & 119.

# ORIGIN AND INSERTION TECHNIQUE

The origin and insertion technique was the first Applied Chiropractic Kinesiological Technique developed by Dr. Goodheart. It is a very simple technique for strengthening muscles and can be applied as effectively today as when it was developed.

This technique is primarily utilized on weak muscles created by stretch injuries, micro-avulsions or idiopathic scoliosis. If weakness is present, therapy localize over the origin or insertion of the muscle in question by first placing the fingertips of one of the patient's hands on the origin and retesting the indicator muscle. Then, place the fingertips of the other hand over the insertion and retest the indicator muscle. If the indicator muscle originally tested weak, therapy localization of the affected origin or insertion would cause the indicator muscle to become strong.

In order to employ this origin-insertion technique, simply press the muscle back into the bone on the origin, or, if the insertion is torn loose from its tendinous attachment, press it toward the tendon. This pressing technique must be utilized on the area of the muscle which is detached, but it is also a good idea to make use of this technique along the entire muscle. It may be necessary to tape the muscle in place if a severe detachment occurs. Always retest the muscle following treatment if the severity of the injury does not prohibit retesting.

When palpating a weakened muscle, one may note the presence of small nodules along the insertion or origin, and these nodules usually disappear within 24 hours after successful treatment has been administered.

# GOLGI TENDON APPARATUS AND SPINDLE CELL MECHANISM

The Golgi tendon apparatus consists of fusiform, fibrous capsules located throughout the muscle and at its tendinous attachments. It is sensitive to both muscle strength and contraction but it cannot distinguish between the two. It discharges as a result of tension on the tendon, and its threshold is relatively low. The information on the tension of the tendon is constantly being transmitted to the central nervous system. Therefore, this safety-valve action prevents damage from excessive contraction on the part of the muscle.

The spindle cell mechanism consists of a connective tissue capsule that is located within the spindle of the muscle fibers and contains special motor and sensory nerve endings. It, too, responds to stretch, but it does not respond to contraction. This mechanism sends messages to the nerve, the spinal cord and the brain and is responsible for highly skilled neuromuscular, coordinated motions.

Visualize a series of switches beginning at the origin of the muscle, running through the belly of the muscle and ending at the insertion of the muscle. Imagine these switches to be three-way switches, with the center position of the switch being neutral (when the muscle is at rest), the right side being Golgi tendon apparatus and the left side being spindle cell mechanism. For any one of a number of reasons, a muscle can become turned off which will result in muscular weakness or pain. Often, if direct trauma occurs to a muscle or if a muscle is stretched too far, it may result in the three-way switch being locked in one position. If this occurs, treatment is indicated. Most frequently, spindle cell is associated with stretch injuries and Golgi tendon apparatus is associated with contraction injuries.

After one has located a weakened muscle and therapy localization indicates the five elements of the intervertebral foramen are intact, then one should suspect either the Golgi tendon apparatus or the spindle cell mechanism.

To employ the Golgi tendon apparatus treatment, one begins at the origin of the muscle with deep, kneading pressure and works in this fashion from the origin to the insertion. Treatment by the spindle cell mechanism is bilaterally administered by beginning in the center of the muscle and working with deep, kneading digital pressure toward the origin and insertion simultaneously. To therapy localize the spindle cell mechanism or the Golgi tendon apparatus, select an intact muscle and use it as an indicator muscle. Then, place the patient's fingertips on or over the involved muscle and retest the indicator muscle. Repeat this procedure moving the fingertips from the origin of the muscle, through the belly and to the insertion, testing the indicator muscle at each point. When the involved Golgi or spindle cell is located, the indicator muscle will become weak upon retesting. Then, challenge that point to see if the Golgi or spindle cell is at fault by using the same method outlined above for treatment.

## REACTIVE MUSCLE TESTING

Recent research has revealed that occasionally some of the spindle cell mechanisms remain in the "on" position while the rest of those in the muscle have switched to the "neutral" position. As a result, under stress, the muscle overcontracts and can cause injury to its antagonist or to its associated contralateral muscle. The muscle suspected of being involved should be tested repeatedly in rapid succession. This is called reactive muscle testing. The muscle which contains the overcontracted spindle cell mechanism will weaken under the stress; e.g., one suspects the quadriceps to be a reactive muscle. One would test it in the usual fashion, and it would be found strong. Then, rapidly test the rectus abdominus or sartorius and retest the quadriceps. If the quadriceps is a so-called reactive muscle, it will immediately weaken under the stress. Then, therapy localize the muscle to determine which part of the spindle cell mechanism is in the "on" position.

To therapy localize the spindle cell mechanism or the Golgi tendon apparatus, select an intact muscle and use it as an indicator muscle. Then, place the patient's fingertips on or over the involved muscle and retest the indicator muscle. Repeat this procedure moving the fingertips from the origin of the muscle, through the belly and to the insertion, testing the indicator muscle at each point. When the Golgi or spindle cell is located, the indicator muscle will become weak. Then, challenge that point to see if the Golgi or spindle cell is at fault by using the same method outlined above for treatment.

The following list of reactive muscles were isolated by Jerold Morantz, a senior student at National College of Chiropractic. The list is not complete, but it will give the reader a number of muscles which are frequently involved.

## REACTIVE MUSCLES

| REACTIVE MUSCLE | ANTAGONIST OR CONTRALATERAL MUSCLE |
|---|---|
| Adductors | Psoas, Tensor Fascia Lata |
| Biceps | Trapezius, Upper Triceps |
| Gastrocnemius | Quadriceps |
| Gastrocnemius, (lateral head) | Popliteus |
| Gluteus Maximus | Pectoralis Major Clavicular |
| Hamstring | Opposite Latissimus Dorsi, Quadriceps |
| Hamstring, lateral | Popliteus |
| Latissimus Dorsi | Trapezius, Upper |
| Pectoralis Minor | Serratus Anterior, Supraspinatus, Deltoid |
| Psoas | Opposite Anterior Neck Flexor |
| Quadriceps | Rectus Abdominis, Sartorius |
| Rectus Abdominis | Opposite Gluteus Medius |
| Rhomboid | Serratus Anterior, Supraspinatus, Deltoid |
| Sacrospinalis | Gluteus Maximus |
| Sartorius | Tibial, Anterior |
| Splenius Capitus | Opposite Piriformis |
| Tensor Fascia Lata | Adductors, Peroneus Tertius |
| Transversalis | Sacrospinalis |
| Trapezius, Upper | Contralateral Upper Trapezius |

The first column is the one that would need to be treated. However, in some cases, group II could be the reactive muscle since they are antagonist or contralateral muscles, except for the piriformis and opposite splenic capitus.

# POINTS ON THE MASTOID

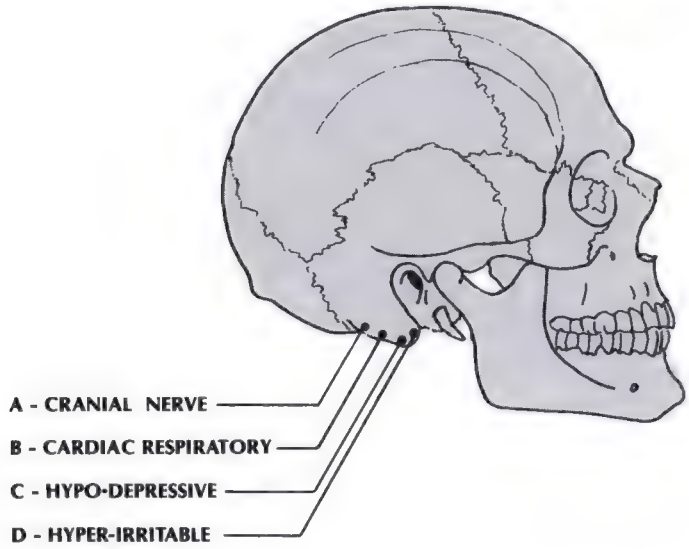

Point A is the most posterior point on the mastoid process and is treated in cranial nerve problems, based upon the direction of successful challenge. When the cardiac rate and respiration rate are not synchronized at 4 to 1 (four heartbeats to one unit of respiration), it will cause the asterion to become very sensitive on palpation. The asterion is the junction of the lambdoidal, occipito-mastoid and parieto-mastoid sutures. This point of sensitivity occurs in many cranial faults and also affects Point B on the mastoid.

Point B on the mastoid is slightly anterior to Point A. Synchronization of the heart and respiratory rate can be attained by contacting Point B bilaterally with the thenar eminences and pressing Point B firmly downward and backward while the patient takes a deep breath. As the patient exhales, maintain the pressure and release it at the end of the expiratory cycle. Hold the contact and press downward and backward as the patient once again inhales, then release the pressure at the end of the expiratory cycle. Repeat this procedure until the cardiac-respiratory rate gradually begins to balance at a 4 to 1 ratio. The procedure for determining the cardiac-respiratory ratio is as follows:

> Use the second hand on a wristwatch and time the patient's cardiac rate per minute. Then, time the patient's respiratory rate per minute. If the ratio is not four heartbeats per each respiration, utilize the following procedure to attain this desired ratio (this technique will correct those conditions which do not involve organic cardiac or lung disease): As the above procedure is applied to Point B on the mastoid, it will result in gradually decreasing the cardiac rate, and it should also result in proportionately balancing the cardiac-respiratory ratio. Gradually reduce the cardiac rate to 64-72 beats per minute or 16-18 respirations per minute, which is a normal respiratory rate. It only takes 3-5 minutes to attain a normal ratio.

Point C is the most inferior point on the mastoid. Patients who need treatment on Point C usually suffer from a low production of cerebral spinal fluid, which results in low blood pressure, lack of energy or morning fatigue with secondary fatigue by mid-afternoon. Ask the patient to inhale and then press inward on Point C as the patient exhales and gently pull Point C posterior or toward the patient's occiput. This is a pumping technique which will result in the rapid increase of cerebral spinal fluid pressure. If time allows, it is wise to synchronize this technique with the patient's respiration for 3-5 minutes.

Point D is the most anterior portion of the mastoid process. Patients who need treatment on this point are usually hypertensive individuals in terms of blood pressure readings. They may exhibit nervousness, migraine headaches, insomnia, tremors or a very tense muscle tone. Patients with epilepsy frequently benefit from treatment on this point due to the dampening effect of the cerebral spinal fluid. Hold Point D with the thenar eminences of both hands. Roll both hands left for a count of five and then roll both hands right for a count of five. Maintain this left and right alternating, rolling motion for at least two minutes. Many times, these patients will also require anterior or posterior movement of the temporal bone, based upon the Respiratory Assistance Technique. (See section on Cranial Faults.) This anterior or posterior directional movement is combined with the alternating lateral roll procedure.

# CRANIAL PUMP TECHNIQUE

If there is a gradual fading of muscle strength after all appropriate treatment has been tried, pump the cranium.

This technique is most frequently required for patients who have been chronically ill. These patients will exhibit unilateral or bilateral pain along the zygomatic bone. The pain will only be found bilaterally if muscular fading is bilateral; otherwise, the pain will only exist on the side of the muscle weakness. Point A on the mastoid will also be sensitive to palpation.

The cranial pump technique is performed by first turning the patient's head away from the side of muscle weakness. Place the thenar aspect of the thumb over the upper mastoid process while you place the other thenar aspect over the most inferior mastoid process and pump the upper hand toward the lower hand as rapidly as possible. The lower hand does not move and only holds the head in position. This technique is very effective in restoring the duration of the muscle strength. This does not correct muscle strength, but results in increased duration of muscle strength. Pump the upper mastoid process for 60 seconds (approximately 100 motions), and this will result in stimulation of the flow of cerebral spinal fluid. Duration of strength of the muscle should show a phenomenal increase (at least 50%), and the zygomatic pain and tenderness on Point A of the mastoid should disappear. If the duration of strength decreases, this would indicate a fixation or subluxation was not corrected before the cranial pump technique was utilized.

# CRANIAL FAULTS

Before one can learn the cranial faults, it is essential to have a thorough understanding of the cranial articulations and their respective movements on respiration. The following review may be helpful:

## REVIEW OF CRANIAL MOTION

| CRANIAL MOTION ON INSPIRATION | CRANIAL MOTION ON EXPIRATION |
|---|---|
| The sphenoid flexes anteriorly, the occiput moves inwardly at its base, the superior section of the occiput moves posteriorly, the mastoid portion of the temporal bones move backward, and the atlas moves forward. | The sphenoid flexes posteriorly, the occiput moves outward at its base, the superior section of the occiput moves anteriorly, the mastoid portion of the temporal bones move forward, and the atlas moves backward. |
| The occiput, sphenoid, ethmoid, mandible, hyoid, vomer and the sacrum all rotate about a transverse axis and extend forward on inspiration and backward on expiration. The rest of the bones of the skull which are midline structures either externally rotate or internally rotate. The respiratory cycle is a flexion of the midline bones with an associated external rotation of the peripheral bones, with a reverse cycle accompanying exhalation. | |

Cranial faults occur when the bones of the skull fail to move in the normal respiratory motion. When a cranial fault occurs, it alters the flow of cerebral spinal fluid, which results in an alteration of the lymphatic flow and its consistency.

The following are helpful hints for identifying cranial fault signs:

1) The prominent eyeball is always on the side of the elevated sphenoid.
2) The nasal-labial crease that extends from the corner of the nose down to the corner of the mouth is always deeper and longer on the side of the externally rotated maxilla.
3) The upper teeth slope more laterally on the side of the externally rotated maxilla.
4) If viewing the patient's forehead while the patient is in a supine position reveals the forehead slightly deviated laterally, this indicates a lateral shift of the sphenoid basilar articulation.
5) A low, prominent ear indicates an externally rotated temporal bone.
6) A crowded suture is indicated by a ridge.
7) A separated suture is indicated by a barely palpable groove.
8) A high occiput indicates weak anterior neck flexors and extensors and a weak piriformis on the same side.
9) A low occiput indicates a weak pectoralis major clavicular and psoas weakness on the same side.
10) A Banana Head is evident when the patient is in a supine position and the doctor looks down on the patient's head, finds a bulge on one side of the temporal bone and a concavity on the opposite side.
11) A classic key to cranial lesions is a failure of the occiput to parallel the level of the orbits, eyebrows or pupils.
12) The indicator for a jammed occiput is a short leg in the supine position with the same leg remaining short in a prone position (in the absence of an anatomical deficiency or posterior ilium), and pain upon palpation along the medial aspect of the gracilis and sartorius.

When therapy localizing a cranial fault, it will result in one of two responses from the indicator muscle:

1) If one begins with a strong indicator muscle, a positive therapy localization will result in the indicator muscle becoming weak.
2) If one begins with a weak indicator muscle, a positive therapy localization will result in the indicator muscle becoming strong.

NOTE: The patient's fingers or hands must remain on the fault while the muscle is being tested.

Exaggeration of cranial lesions is the best method of treatment for the vast majority of patients. However, if the cranial fault fails to respond, do not use the exaggerating technique; simply correct the fault as indicated. In children six years of age or younger, simply correct the cranial fault without exaggerating the lesion.

Listed below are the 15 most common cranial faults. One must remember that cranial faults may occur singularly or in any combination.

## CRANIAL FAULT IDENTIFICATION AND CORRECTION

**INSPIRATION ASSIST**

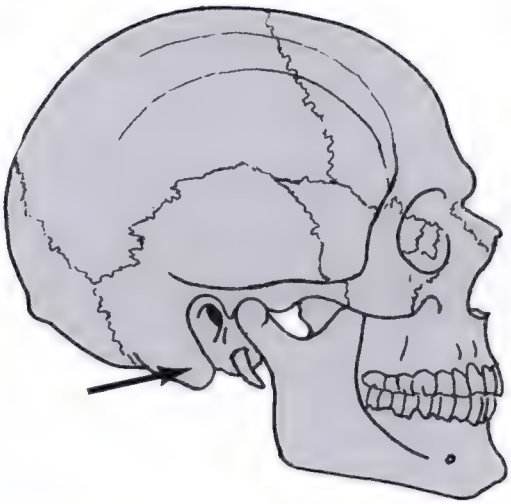

| | |
|---|---|
| IDENTIFYING CHARACTERISTICS: | If a muscle is tested and found to be weak, ask the patient to take a deep breath and hold it as the muscle is retested. If the inspiration increased the muscle strength, this would indicate the patient is in need of inspiration assist cranial correction. |
| THERAPY LOCALIZATION: | Therapy localize the mastoid processes to determine which side needs correction by placing the fingertips of both of the patient's hands on each mastoid and retesting the indicator muscle. Therapy localization of the affected mastoid will result in increased strength to the indicator muscle. |
| CHALLENGE: | (If one is able to obtain a positive therapy localization on the mastoid, challenge is not necessary.) Gently push the mastoid anterior on the weak indicator muscle side and then retest the indicator muscle. If the mastoid is in need of forward correction, the indicator muscle will increase in strength. If the challenge resulted in no change in the strength of the indicator muscle, challenge the opposite mastoid in the same manner. |
| KINESIOLOGICAL CORRECTION: | Gently push the mastoid process on the affected side forward on inspiration (exerting no more than 2 to 3 pounds of pressure). Repeat this procedure on 4 to 5 inspirations, and retest the muscle to verify correction. |

**EXPIRATION ASSIST**

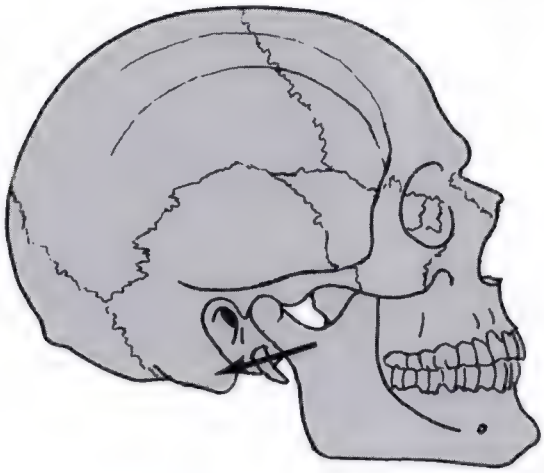

| | |
|---|---|
| IDENTIFYING CHARACTERISTICS: | If a muscle is tested and found to be weak, ask the patient to exhale and retest the muscle. If this results in increased strength of the indicator muscle, this would indicate the patient is in need of expiration assist cranial correction. |
| THERAPY LOCALIZATION: | Therapy localize the mastoid processes to determine which side needs correction by placing the fingertips of both of the patient's hands on each mastoid and retesting the indicator muscle. Therapy localization of the affected mastoid will result in increased strength to the indicator muscle. |
| CHALLENGE: | (If one is able to obtain a positive therapy localization on the mastoid, challenge is not necessary.) Gently push the mastoid posteriorly on the side of the weak indicator muscle and retest the indicator muscle. If the mastoid is in need of posterior correction, the weak indicator muscle will become strong. If the indicator muscle does not increase in strength, repeat the same procedure on the opposite mastoid. |
| KINESIOLOGICAL CORRECTION: | Usually, the muscle will be weak on the same side as the cranial lesion; however, this is not always true. Gently, move the mastoid portion of the temporal bone posteriorly on expiration on the affected side (no more than 2 to 3 pounds of pressure should be exerted). Repeat this procedure on 4 to 5 expirations and retest the muscle. Retherapy localize or rechallenge the mastoid to verify correction. |

**ONE-HALF BREATH IN ASSIST**

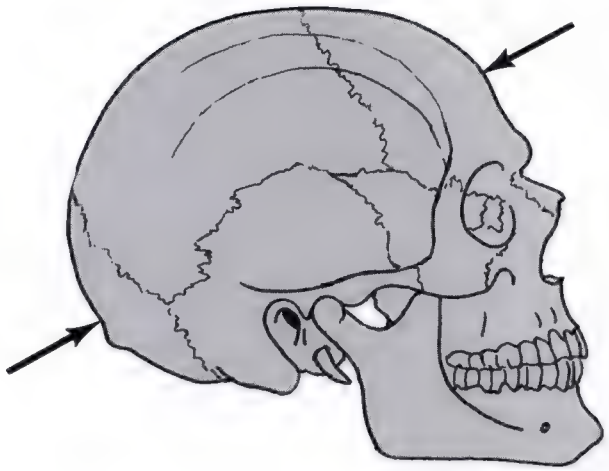

| | |
|---|---|
| IDENTIFYING CHARACTERISTICS: | The one-half breath in assist cranial fault is usually found in patients with allergies, such as hayfever, rosegrass allergies, itching, wheezing, hives, asthma, or even paroxysmal tachycardia. These same patients will also frequently exhibit what is termed a "BANANA HEAD." The term banana head was coined because the patient's head, when viewed from above while the patient is in a supine position, resembles the shape of a banana. This shape occurs as a result of a torsion lesion of the sphenobasiliar symphysis region of the skull. The net effect is a concave/convex lesion of the temporalis, but the actual torsion is at the sphenobasiliar symphysis. Pain may be exhibited at the most bulged point of the temporal bone. Often, these patients will also exhibit bilateral pectoralis major clavicular weakness. If the muscle is tested and found to be weak, ask the patient to take one-half breath in and retest the muscle. If it exhibits more strength, the patient then has a one-half breath in cranial fault. |
| THERAPY LOCALIZATION: | Place one of the patient's hands on the most bulged point on the temporal bone and the other hand on the opposite side of the head on the concave temporal bone. Retest the indicator muscle. If it originally tested strong and a fault is present, it will now test weak. |
| CHALLENGE: | After positive therapy localization, one must then challenge the fault to find the most effective line of correction. Contact the skull on each side of the head and place 1 pound of pressure in the direction which exaggerates the bulge. Retest the indicator muscle. This will result in a strong indicator muscle becoming weak or a weak indicator muscle becoming strong. |
| KINESIOLOGICAL CORRECTION: | Exaggerate the cranial lesion by molding the skull in such a fashion as to exaggerate the bulged temporal bone. For example, if the bulge is on the right, you would attempt to mold the frontal bone and the occipital bone with your hands so as to increase the bulge while the patient uses a forced respiration. Initiate the bulging effect as the patient begins to inhale, with the greatest degree of pressure being exerted on half inspiration and gradually diminish the pressure 4 to 5 times using a relatively light pressure (not to exceed 2 to 3 pounds per hand). Retest the muscle and challenge or therapy localize the cranial fault to verify correction. In order to reduce the pain over the bulged temporal bone, use the neurovascular reflex for the pectoralis major clavicular and the parietal neurovascular reflex for the gluteus medius; hold for a simultaneous pulsation for at least 20 to 30 seconds. |

**ONE-HALF BREATH OUT ASSIST**

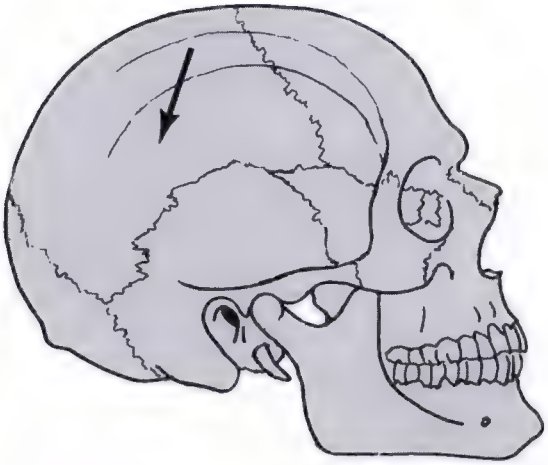

| | |
|---|---|
| IDENTIFYING CHARACTERISTICS: | If a muscle is tested and found to be weak, ask the patient to take a deep breath and let one-half of it out. Then, retest the muscle. If it is increased in strength, this would indicate the patient is in need of one-half breath out cranial correction. Frequently, this cranial fault is the result of a glancing-type blow to the skull, which causes the parietal bone to descend. Often, these patients also exhibit weakness of the anterior scaleni muscles, which are also associated with lumbar and sacral subluxation. |
| THERAPY LOCALIZATION: | Have the patient place fingertips from both hands over the suspected parietal bone. If the indicator muscle originally tested strong, it will then become weak on retesting in the presence of a fault. If no change occurs, retherapy localize the opposite parietal bone and retest the indicator muscle. |
| CHALLENGE: | After the affected parietal bone has been located, one must challenge it to determine what line of correction should be employed. Challenge the parietal bone by pushing it downward and slightly toward the occiput. Retest the indicator muscle; if it originally tested strong, it will now test weak. No more than 1 pound of pressure should be utilized when challenging. |
| KINESIOLOGICAL CORRECTION: | Exaggerate the parietal descent on the affected side as the patient takes a full breath and begins to exhale; gradually increase the pressure (pressure should never exceed 2 to 3 pounds). Repeat this procedure on 4 to 5 respirations on the expiratory phase. This method of correction causes the cranial fault to rebound and pushes the bone in the opposite direction. Retest the muscle and then rechallenge or retherapy localize the parietal bone to verify correction. |

**SAGITTAL SPREAD ASSIST**

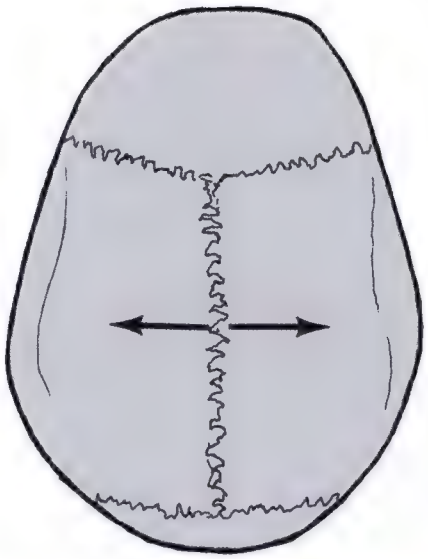

| | |
|---|---|
| IDENTIFYING CHARACTERISTICS: | This cranial lesion is frequently seen in patients with low back conditions. It is characterized by weak abdominal muscles, and, on palpation, one often finds a ridge formed by the jamming of the sagittal suture. |
| THERAPY LOCALIZATION: | Have the patient raise both hands above the skull and point the fingertips downward, lightly touching the sagittal sutures with the fingertips. This will result in a weak indicator muscle becoming strong when retested (if a fault is present). |
| CHALLENGE: | If the suture therapy localized positively, there is no need to challenge it. However, if challenge is necessary, it is performed by grasping both parietal bones and gently pulling downward on them. Retest the indicator muscle; if it was weak originally, it will now test strong. |
| KINESIOLOGICAL CORRECTION: | Separate the sagittal suture on the phase of respiration which increases the muscle strength. Repeat this procedure on 4 to 5 respirations (exerting no more than 2 to 3 pounds of pressure per hand). There is no specific phase of respiration associated with this cranial fault. Retest the abdominals and rechallenge or retherapy localize the sagittal suture to verify correction. |

**FORCED INSPIRATION CHALLENGE**

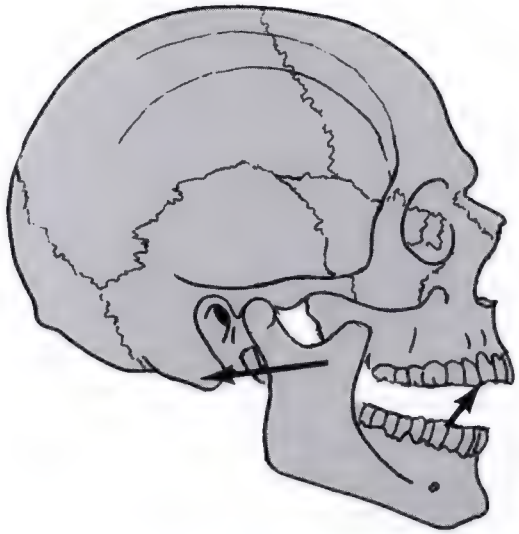

| | |
|---|---|
| IDENTIFYING CHARACTERISTICS: | If a muscle is tested and found to be strong but fails to lock, ask the patient to take a deep breath and then force more air into the lungs. Retest the muscle. If the patient is suffering from a forced inspiration assist cranial fault, this will cause the muscle to "blow out" or become spontaneously weak. This cranial fault is often associated with visual problems. Therefore, it is wise to check the patient's eyes with a Snellen Chart with his glasses on and off before correcting the fault; retest them after correction. This is termed forced inspiration challenge because it is actually a hidden expiration cranial fault. |
| THERAPY LOCALIZATION: | Ask the patient to open the mouth and place both thumbs on the roof of the mouth. A strong indicator muscle will then become weak in the presence of a fault. |
| CHALLENGE: | This cranial fault is rarely, if ever, challenged because it is found through respiration and can also be located by therapy localization. There is only one direction of correction. If challenge is indicated, it should be performed in the same manner as correction, except with less pressure. A strong indicator muscle would then become weak. |
| KINESIOLOGICAL CORRECTION: | Contact the central incisors in the front and the anterior portion of the mastoids bilaterally, pulling the central incisors forward and the mastoids backward (exert no more than 2 to 3 pounds of pressure per hand). One is actually pulling the head apart and separating the sutures, which allows them to rebound properly. Repeat this procedure on 3 to 5 expirations. Frequently, two people are needed to perform this procedure. Retest the muscle on forced inspiration to verify correction. |

**FORCED EXPIRATION CHALLENGE**

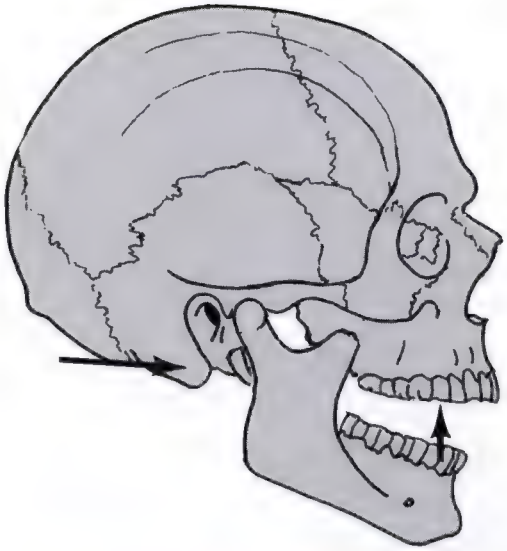

| | |
|---|---|
| IDENTIFYING CHARACTERISTICS: | If a muscle is tested and found to be strong but fails to lock, ask the patient to exhale and then force all the air out of his lungs. If the patient has a forced expiration cranial fault, this will literally cause the muscle being tested to "blow out" or become spontaneously weak. This cranial fault is frequently associated with visual disturbances; and, therefore, the eyes should be checked as indicated in the forced inspiration assist cranial fault. This is termed forced expiration challenge because it is actually a hidden inspiration cranial fault. |
| THERAPY LOCALIZATION: | This fault is rarely therapy localized because it is found in respiratory examination. However, if therapy localization is necessary, ask the patient to put one thumb on the roof of the mouth and the other hand under both mastoids in a cupped fashion. Retest the indicator muscle. If it was strong originally, it will now become weak in the presence of a fault. |
| CHALLENGE: | This fault is rarely, if ever, challenged. If the occasion should ever arise where one would need to challenge, it would be performed in the same manner as correction, except with less pressure. A strong indicator muscle would then become weak or a weak indicator muscle would then become strong. |
| KINESIOLOGICAL CORRECTION: | Both mastoids should be pushed anteriorly and, at the same time, the hard palate should be pushed superiorly. One is actually "pushing" the skull together. This procedure is performed as the patient inhales. It should be performed on 3 to 5 consecutive inspirations, and may require the assistance of a second person. No more than 2 to 3 pounds of pressure per hand should be exerted. Retest the muscle on forced expiration to verify correction. |

## INTERNAL FRONTAL BONE ROTATION

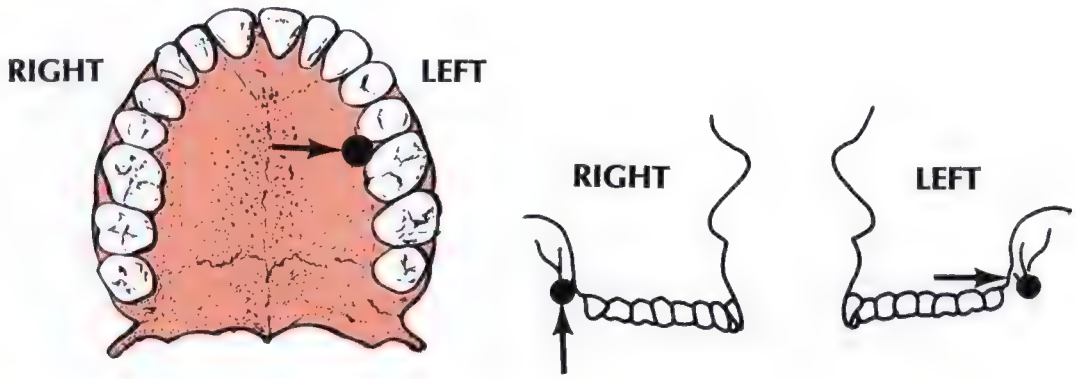


| | |
|---|---|
| IDENTIFYING CHARACTERISTICS: | This cranial fault is frequently seen in patients who have a history of whiplash or trauma to the cervical spine. These patients can be identified by exhibiting the appearance of having one eye smaller than the other. The small orbit will be on the side of rotation, and the nares will be larger on the side of internal rotation. Pain may be elicited upon palpation over the supra-orbital foramen, and the anterior neck flexors will be bilaterally weak. The internal frontal bone rotation cranial fault can also be identified through therapy localization. |
| THERAPY LOCALIZATION: | Have the patient place the fingertips from both hands (positive and negative surfaces) on the internally rotated frontal bone. This will result in a strong indicator muscle becoming weak when retested, if a fault is present. |
| CHALLENGE: | Contact the lateral aspect of the maxillary bone at the junction of the premolars and the first molar and push nasally; or, contact the alveolar process on the hard palate at the junction of the premolars and the first molar and press it superiorly. If the original indicator muscle was strong, this challenge would cause it to become weak. If one was using the weak anterior neck flexors, this would cause them to become strong. |
| KINESIOLOGICAL CORRECTION: | Place the thumb between the last premolar and first molar of the teeth on the hard palate (on the same side as the wide nares and the narrow orbit). Use a disposable, plastic glove and request the patient to remove any denture or removable bridge. When the thumb is in its proper place, press and roll laterally using between 2 to 3 pounds of pressure. Press and roll. Stop. Repeat this press and roll technique for 30 to 45 seconds. Then, check for pain at the supra-orbital area. Place your index finger along the lateral border of the molar teeth, press backward past the molar teeth, past the ramus of the jaw, until you reach the pterygoid process of the sphenoid bone. This will be a very painful, small, bony prominence that will be discernable to the doctor by its bony hardness and to the patient by its tenderness. If the roll and press technique fails to correct the painful supra-orbital area, press the pterygoid process sharply downward with your index finger for a period of approximately 10 seconds. Caution the patient that this will be a painful procedure before pressing on the pterygoid process. Then, place your finger in the pterygoid process on the opposite side (opposite the side of internal frontal bone rotation) and press it sharply upward toward the top of the head for a period of 10 seconds. Following this procedure, the pain should be gone, and a marked increase in strength should be noted in the anterior neck flexors. Verify correction by therapy localization. |

## EXTERNAL FRONTAL BONE ROTATION

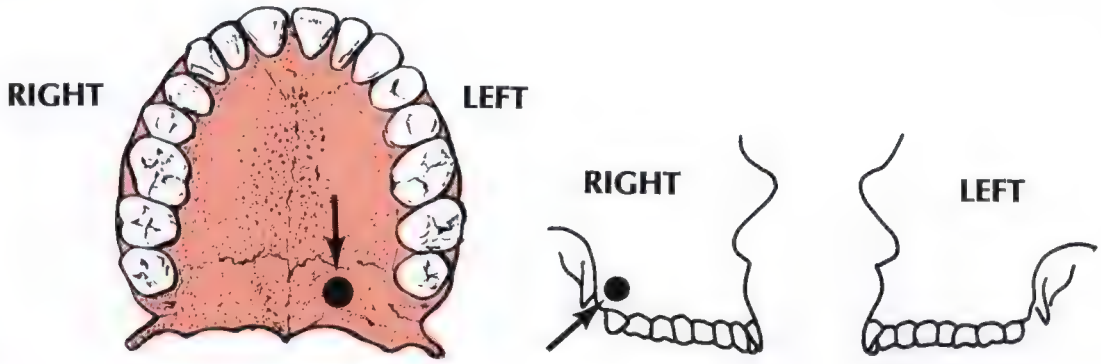


| | |
|---|---|
| IDENTIFYING CHARACTERISTICS: | This fault is frequently seen in patients who have experienced whiplash or other types of cervical trauma. It is characterized by the ocular orbit appearing much larger on the side of external rotation. The supraciliary arch will be painful upon palpation on the side of irritation, and the eyeball will be painful to pressure on the the side of external rotation. Also, the malar arch will be painful upon palpation on the opposite side of rotation. Muscle testing of the anterior neck flexors will disclose bilateral weakness. External frontal bone rotation can also be identified by therapy localization. |
| THERAPY LOCALIZATION: | Place the fingertips (positive and negative surfaces) from both hands on the externally rotated frontal bone. If the indicator muscle was originally strong, a positive therapy localization will result in the indicator muscle becoming weak. |
| CHALLENGE: | Pull down on the upper molar teeth or maxillary bone on the side of the narrow orbit. The challenge should result in increased strength of the anterior neck flexors if they were tested and originally found to be weak. |
| KINESIOLOGICAL CORRECTION: | If the external frontal rotation occurs on the right, press a gloved finger adjacent to the horizontal portion of the hard palate on the left side. Press the left hard palate upward toward the top of the head and backward toward the occiput. Vary the direction until you feel the patient's response in terms of being relieved from pain in the eyeball, cheekbone and supraciliary arch. When this point is found, it should not take more than 30 seconds to correct it (applying less than 2 pounds of pressure). Following this procedure, move your treating finger superiorly and posteriorly to the pterygoid muscle pocket and rotate it internally and medially with the treating finger. Then, press upward and inward and hold for a period of 20 to 30 seconds with the treating finger. Following this procedure, there should be a marked increase in strength of the anterior neck flexors and complete disappearance of pain in the before-mentioned areas. Verify correction through therapy localization. |

**ZYGOMATIC CRANIAL FAULT**

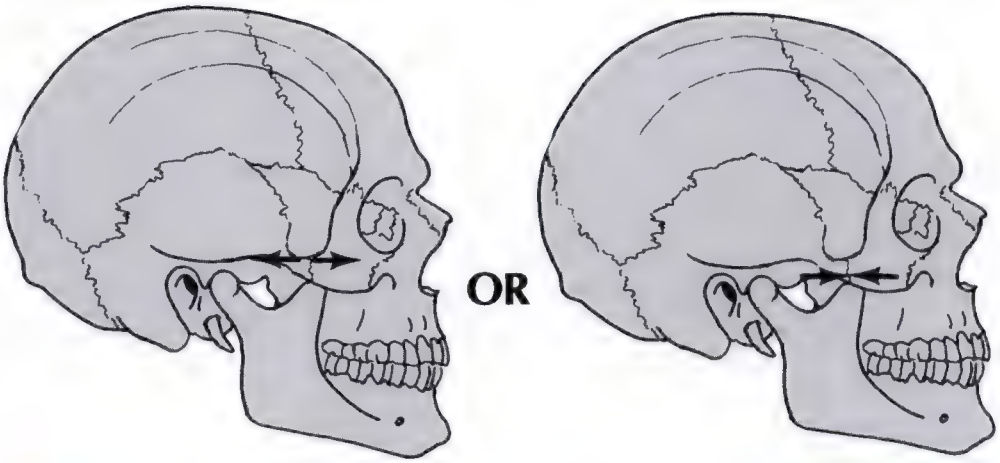


| | |
|---|---|
| IDENTIFYING CHARACTERISTICS: | This cranial fault is frequently seen in patients with an ileocecal valve syndrome. Also, if the patient complains of sneezing attacks in the absence of allergies, suspect a zygomatic cranial fault. Many times this fault is also seen in patients who suffer from hiccup attacks. This fault occurs at the zygomatic suture, between the zygoma and zygomatic process of the frontal bone. |
| THERAPY LOCALIZATION: | Have the patient place the fingers from each hand over the suspected zygomatic suture. If the fault is present on the side being therapy localized, it will result in a strong indicator muscle becoming weak. |
| CHALLENGE: | Ask the patient to take a deep breath and then force it out (with the oral and nasal passages closed), as if they had just stifled a sneeze. Recheck the indicator muscle. If the fault is present, the indicator muscle will become weak. Find the line of correction by separating or reuniting the suture and rechecking the indicator muscle after each direction is challenged. If the fault is present, the indicator muscle will become weak. Most frequently, this fault is in need of separation. |
| KINESIOLOGICAL CORRECTION: | The correction is performed in the manner in which the fault was successfully challenged but on the phase of respiration which abolishes the muscle weakness. Repeat the correctional procedure on 4-5 successive respirations and rechallenge or retherapy localize to verify correction.. |

**LAMBDOIDAL SUTURE FAULT**

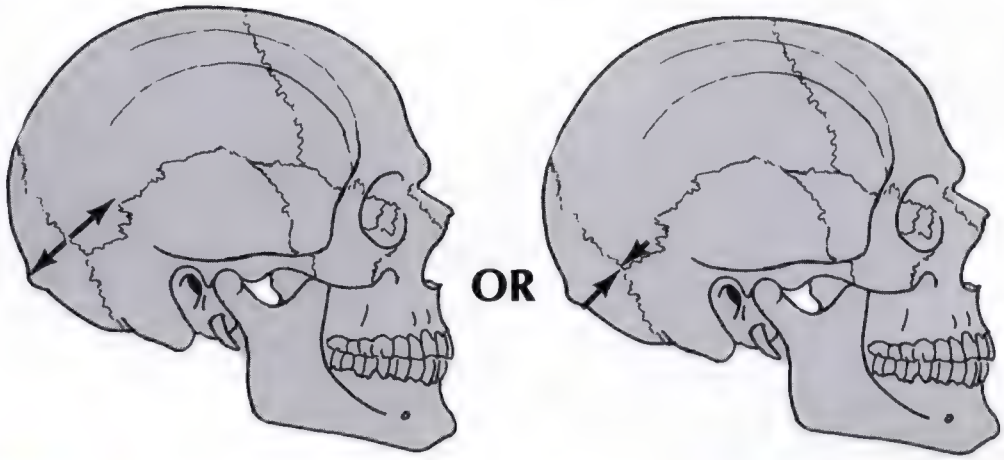


| | |
|---|---|
| IDENTIFYING CHARACTERISTICS: | This cranial fault is frequently seen in patients with low back conditions. The lambdoidal suture is located between the occipital and parietal bones and may be jammed together and in need of separation or it may be separated and in need of reunion. This fault may occur bilaterally or unilaterally and may be identified through therapy localization or challenge. |
| THERAPY LOCALIZATION: | Place the patient in a prone position and ask the patient to place several fingers from both hands over the lambdoidal suture. If there is a fault, it will result in a strong indicator muscle becoming weak when retested. Keep in mind that therapy localization does not tell the examiner what is wrong — it simply indicates the location of the fault. |
| CHALLENGE: | Now that the fault has been located, one must challenge to see if a separation or a reunion of the suture is required. Press the lambdoidal suture together and if this results in a strong indicator muscle becoming weak, then correct the fault in this direction. However, if no change occurs, separate the suture; if this is the direction in which the fault should be corrected, it will result in the strong indicator muscle becoming weak. |
| KINESIOLOGICAL CORRECTION: | If the challenge resulted in the strong indicator muscle becoming weak, find the phase of respiration which abolishes the weakness. When making the correction, one must adjust the sutures in the direction which produces weakness but on the phase of respiration which increases the muscle strength. Verify correction through retherapy localization or rechallenging the suture. |

## OCCIPITAL ATLANTAL COUNTERTORQUE

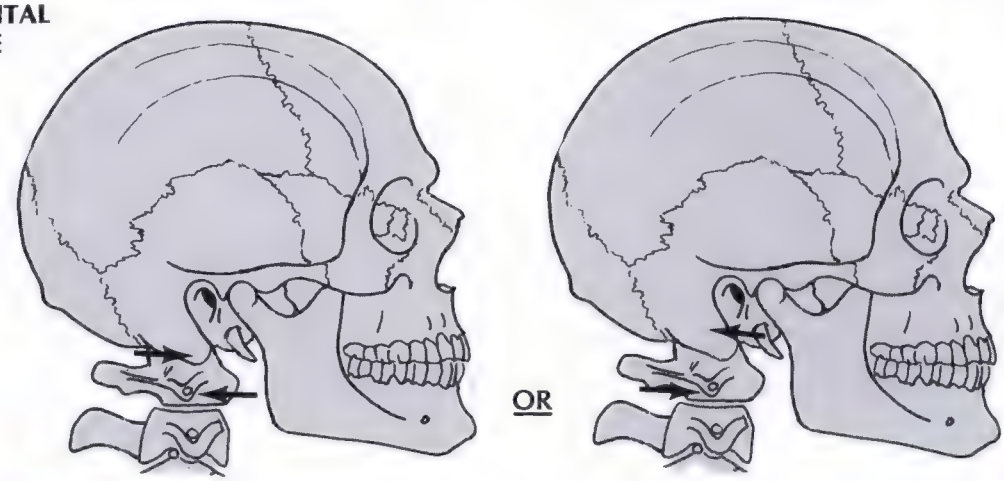


| | |
|---|---|
| IDENTIFYING CHARACTERISTICS: | This cranial fault is frequently seen in patients who suffer from chronic, tonic, clonic, spastic torticollis and is evidenced by the patient's head involuntarily pulling to one side. This fault is also frequently seen in patients who exhibit a sacral wobble, and the wobble is located on the same side as the fault. Normally, the occiput moves forward on inspiration and the atlas moves backward, while the atlas moves forward on expiration as the occiput moves backward. However, in some people, this movement is not equal or bilateral, and this creates an occipital atlantal countertorque cranial fault. |
| THERAPY LOCALIZATION: | The affected side can be identified through therapy localization by placing two fingers of one hand on the occiput and two fingers of the other hand on the atlas (on the same side of the head). Therapy localize with positive and negative surface of hands. Retest the indicator muscle. If therapy localization is positive, it will result in the weak indicator muscle becoming strong. |
| CHALLENGE: | This condition can also be identified by placing the patient supine and contacting the posterior aspect of the mastoid with one hand and the anterior aspect of the transverse process of atlas (on the same side) with the other hand. Then, press the mastoid process anteriorly and the atlas posteriorly, simultaneously; or, press the mastoid process posteriorly and the atlas anteriorly, simultaneously. If either direction results in weakening the tested muscle, this would indicate the patient has an occipital atlantal countertorque cranial fault. Correction would be made in the direction that the challenge produced muscle weakening, but on the phase of respiration which resulted in increased muscle strength. |
| KINESIOLOGICAL CORRECTION: | Test a convenient muscle and note the respirational phase which increases the muscle strength. This fault occurs primarily on inspiration. If it is inspirational, place the patient supine and contact the posterior aspect of the mastoid with one hand and the anterior aspect of the transverse process of atlas (on the same side) with the other hand. Then, press the mastoid process anteriorly and the atlas posteriorly, simultaneously. Perform this action 4 to 5 times on inspiration, using 1 to 2 pounds of pressure on each hand. Retherapy localize or rechallenge the fault to verify correction. However, if the fault is expirational, contact the anterior aspect of the mastoid and the posterior aspect of the transverse process (on the same side) and press the mastoid posteriorly and the atlas transverse process anteriorly, simultaneously (this would be the opposite direction from the motion applied in inspirational faults). Perform this action 4 to 5 times on expiration, using 1 to 2 pounds of pressure on each hand. Correction would be on the phase of respiration that abolishes the muscle weakness but based upon the challenge which weakens the strong indicator muscle. Retherapy localize or rechallenge the fault to verify correction. |

## OCULAR LOCK

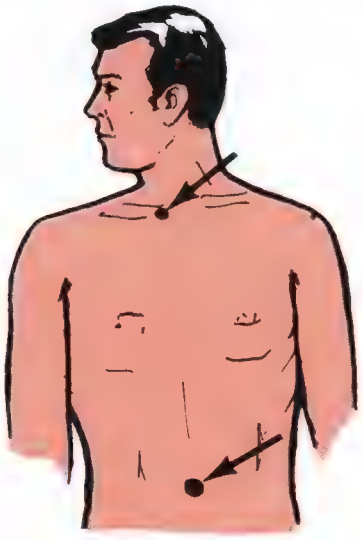

| | |
|---|---|
| IDENTIFYING CHARACTERISTICS: | This cranial fault occurs occasionally in conjunction with the glabella fault. Ocular lock occurs most frequently in structural faults, scoliosis, recurring vertebral patterns and frequently in occipital atlantal countertorque problems. |
| THERAPY LOCALIZATION: | To date, research has not revealed a suitable method of therapy localizing this fault. |
| CHALLENGE: | In order to identify an ocular lock cranial fault, place the patient in a supine position and test a convenient muscle. If it is found to be strong, ask the patient to forcibly look to the left with his eyes, but do not allow the patient to turn his head as he does this. Test the indicator muscle as the patient is forcibly looking to the left. Then, ask the patient to forcibly look right, up and down and check the indicator muscle as the patient looks in each of these directions. Once you have located the ocular lock (demonstrated by the muscle becoming weak when looking in one of the above directions), you have established the existence of an ocular lock cranial fault. |
| KINESIOLOGICAL CORRECTION: | Contact the umbilicus and K-27 with a fairly firm pressure. (K-27 is located at the junction of the first rib, sternum and clavicle, bilaterally.) Use an alternating, soft-tissue manipulation at each of these points for approximately 30 to 45 seconds. Then, rechallenge the ocular lock; if correction did not occur, check for an occipital atlantal counter torque or a glabella fault. Ocular lock is a compensatory mechanism which the body utilizes to correct distortional patterns in the body. For example, if distortion occurs in the neck and upper back, causing the eyes to be uneven, the body would compensate. It would cause the eye on the high side to gimbal downward and the eye on the low side to gimbal upward, in an effort to maintain a level field of vision (in spite of the head being tilted). If the head tilt is corrected and the ocular lock is not, the ocular lock will then cause the head tilt to recur. |

## GLABELLA FAULT

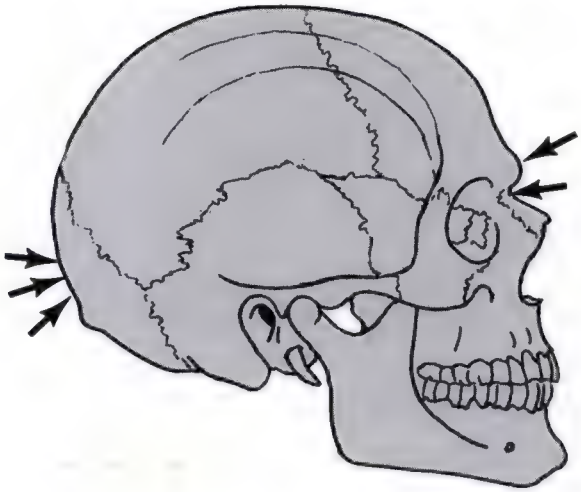

| | |
|---|---|
| IDENTIFYING CHARACTERISTICS: | This fault is frequently associated with ocular lock and a sacral fault. One is normally able to breathe through his nose or his mouth. However, when a patient has a glabella fault, he is unable to breathe through one of these passages without resultant muscular weakness. |
| THERAPY LOCALIZATION: | Therapy localization may be performed by placing the positive or negative surfaces of the patient's fingertips over the glabella and testing an indicator muscle. If therapy localization is positive, a strong indicator muscle will become weak (one must be careful in therapy localizing over this area that a sinus infection or other similar involvement may be revealed rather than a glabella fault). |
| CHALLENGE: | Ask the patient to close his mouth and take a deep breath through his nose. Retest the indicator muscle while the patient holds the breath (weakness will rarely be found on nasal inhalation). If the muscle remains strong, ask the patient to occlude both nostrils and take a deep breath through his mouth. Again, test the indicator muscle. If the muscle is weakened on inhalation through either passage, the patient has a glabella fault. |
| KINESIOLOGICAL CORRECTION: | Place 2 or 3 fingers on the glabella with one hand and 2 or 3 fingers of the other hand on the external occipital protruberance while the patient is in a supine position. Then, apply pressure (not to exceed 2 to 3 pounds in each hand) simultaneously as the patient breathes through his nostrils. Repeat this procedure 4 to 5 times in combination with the patient's respiration. Rechallenge the fault. In rare instances, the patient may have adapted to oral respiration and will not respond to the above treatment. It is then necessary to use the same contacts but ask the patient to breathe orally, instead of nasally. It is also important to check the sacrum, because a corresponding sacral fault will generally occur in conjunction with a glabella fault. Therefore, test the indicator muscle while the patient is in a prone position. Ask the patient to take a deep breath through the nose and retest the indicator muscle. If the muscle weakens, have the patient take 4 to 5 breaths nasally while you apply a forward pressure at the apex of the sacrum, pushing it forward simultaneously with the nasal respiration. If the muscle tests strong on nasal inspiration, ask the patient to take a deep breath orally, occluding the nasal passages and retest the muscle. If the muscle weakens, then repeat the same procedure while the patient breathes orally. Rechallenge to verify correction. |

## UNIVERSAL OR INTEROSSEOUS CRANIAL FAULT

| | |
|---|---|
| IDENTIFYING CHARACTERISTICS: | This cranial fault is produced by trauma and primarily by prenatal trauma in the birth canal. Occasionally, in the descent of the child's head through the mother's pelvis, one parietal bone may hang up within the pelvis. The birth process continues to force the skull downward and outward, causing one parietal eminence to hang up within the pelvis and literally shoves the occiput upon itself. Therefore, the universal cranial fault is formed on the occiput. Often, due to the adjacent squama dragging against the mother's pelvis, one condyle will move laterally and posteriorly and compress itself against the temporal bone on that side. |
| THERAPY LOCALIZATION: | Research has not revealed a suitable method of therapy localizing this fault. |
| CHALLENGE: | If the patient is suspected of having a universal cranial fault, test a muscle and ask the patient to take a deep breath with the mouth closed and one nostril occluded. Retest the muscle and observe for weakness. If the muscle weakens from occlusion of one nostril or the other, this will indicate the presence of a universal cranial fault. If the fault is not evident by those identifying characteristics mentioned above, ask the patient to lie in a prone position. Press the mastoid process of the temporal bone upward, toward the vertex, with the index finger, and press the opposite mastoid process in a caudal direction, with the thumb, while the cupped hand contacts the occipital squama and presses it in the same direction. Retest the muscle. If it remains strong, press the mastoids in the opposite direction and retest the muscle. |
| KINESIOLOGICAL CORRECTION: | Once it has been determined which direction induces the weakness, administer treatment in the opposite direction. At the same time, the opposite hand is used to rotate the occipital squama in the same direction as the other hand is moving. Repeat this motion using 4 to 5 respirations to initiate correction. For example, if the occiput is in a universal cranial fault position, and pressure is applied in a vertex direction on the right mastoid and a caudal direction on the left mastoid produces weakness (counterclockwise direction), then treatment would be initiated in the opposite direction (clockwise direction). In this instance, correction would be administered by pressing the right mastoid process in a caudal direction and the left mastoid in a vertex direction. At the same time, the opposite hand would rotate the temporal squama in the same direction, using 4 to 5 respirations. The universal cranial fault does not necessarily have a corresponding sacral fault. However, in many instances, there is a simultaneous jamming of the two ilia. This can be detected by a weak hamstring which will coincide with the same phase of respiration previously shown on the initial nasal occlusion test. Correction frequently requires simultaneous, quick, thrusting separation of the two ilia on the sacrum. Often, in a universal cranial fault, there also exists a very difficult upper cervical problem which requires close monitoring. |

# CRANIAL STRESS CENTERS

If there are points on the body such as neurolymphatics, neurovasculars, etc. which, when stimulated, result in "turning a muscle on" or strengthening it, then it is not illogical to assume that there are also points on the body which will "turn a muscle off."

A patient fell on the ice, hit her head at the base of the skull and subsequently developed a severe hamstring cramp. Dr. Goodheart used all the existing Applied Chiropractic Kinesiological Diagnoses and Techniques to eliminate the cramping of the hamstring, but he was unsuccessful. Since the patient stated she had fallen and hit her head, Dr. Goodheart carefully palpated the skull, and this revealed a sensitive area on the parietal bone, approximately one-half inch off the midline. Dr. Goodheart discovered he was able to correct this patient's problem through digital pressure on the skull in a caudal direction. Digital pressure in a vertex direction seemed to accentuate the problem. This finding partially led to the discovery of the existence of cranial stress centers.

Cranial stress centers are located on the skull and act like circuit breakers. When a muscle is under excess stress, the body innately turns off the circuit and turns on the cranial stress center. Therefore, any attempt to turn on the muscles through any of the elements of the intervertebral foramen would be futile until the cranial stress center is turned off.

To date, 36 cranial stress centers have been located which correlate with specific muscles. The following diagrams illustrating these stress centers represent a collaboration of research done by Dr. J. Elvidge of Washington and Dr. George Goodheart.

**ANTERIOR VIEW**

4. ANTERIOR SCALENUS
5. ANTERIOR TIBIALIS
6. BICEPS
8. DELTOID (UPPER)
9. GASTROCNEMIUS
15. LATISSIMUS DORSI
20. PECTORALIS MAJOR STERNAL
29. SUBSCAPULARIS
30. SUPRASPINATUS
32. TERES MINOR
33. TERES MAJOR
35. TRAPEZIUS (UPPER)

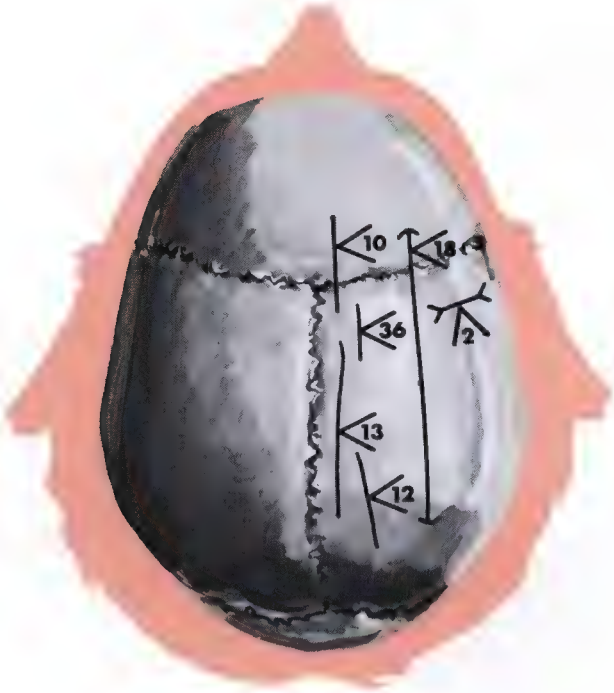

**POSTERIOR AND SUPERIOR VIEW**

1. ABDOMINIS (RECTUS)
2. ABDOMINIS (TRANSVERSE)
3. ADDUCTORS
10. GLUTEUS MAXIMUS
11. GLUTEUS MEDIUS
12. GLUTEUS MINIMUS
13. HAMSTRINGS
14. ILEOCECAL
16. LEVATOR SCAPULAE
17. NECK EXTENSORS AND FLEXORS
18. PECTORALIS MAJOR CLAVICULAR (BILATERAL)
21. PIRIFORMIS
22. POPLITEUS
24. QUADRATUS LUMBORUM
26. SARTORIUS
28. SOLEUS
31. TENSOR FASCIA LATA
36. TRICEPS

**LATERAL VIEW**

7. CORACOBRACHIALIS
16. LEVATOR SCAPULAE
17. NECK EXTENSORS & NECK FLEXORS
19. PECTORALIS MAJOR CLAVICULAR
20. PECTORALIS MAJOR STERNAL
23. PSOAS MAJOR
25. RHOMBOID
27. SERRATUS ANTERIOR
34. TRAPEZIUS (LOWER & MIDDLE)

If a muscle tests weak and cannot be strengthened through the use of any of the Applied Chiropractic Kinesiological Techniques, then the cranial stress center should be checked by one of the following methods: Either challenge the cranial stress center point in a linear direction (forward or backward), using 3 to 5 pounds of pressure to determine if this will strengthen the muscle; or, therapy localize the cranial stress center point by placing the fingertips (positive and negative surfaces) from both of the patient's hands on the cranial stress center in question. If the cranial stress center is at fault, therapy localization of that point will result in the weak muscle becoming strong. Then it is necessary to challenge the cranial stress center to determine how to turn it off.

If the cranial stress center is at fault, correction may then be performed by one of the following methods:

1) Simply activate the cranial stress center point in the direction which turns it off; this will result in strengthening the muscle.
2) Challenge the proper cranial stress center in a linear direction (either forward or backward) to see which direction will turn the stress center on and result in weakening the muscle. Then, press the cranial stress center point in the direction which weakens the muscle 4 to 5 times on the phase of respiration which strengthens the muscle (using 3 to 5 pounds of pressure). This procedure seems to neutralize the cranial stress center and results in strengthening the muscle.

It is wise to therapy localize the other five elements of the intervertebral foramen and treat them, if necessary.

In a difficult case, it occasionally may be necessary to activate a cranial stress center point with a bilateral, simultaneous pressure in order to correct a single or double muscle weakness.

The cranial stress centers are frequently involved and should be checked on your patients routinely.

# EMOTIONAL PATTERNS

There have been many theories relating psychological and structural imbalances. Wilhelm Reich was a contempory of Freud; he discovered that the muscles which crisscross above the eyes, mouth, solar plexus, chest and pelvis tend to become hardened and interfere with what he called "organ energy." He found it interesting that "yes" is universally expressed in body language by an upward and downward motion of the head, while "no" is expressed by a crosswise motion of the head. Feldencross, in Israel, observed that for every psychological imbalance, there is an accompanying postural fault which must be corrected before any changes in the psychological state could be made.

As outlined earlier in this chapter, man can be likened to an equilateral triangle; the base is structural, one side is chemical, and one side is psychological. If one's psychological posture is altered due to trauma, it can affect one's structure. This, in turn, can affect the intervertebral foramen and its contents and, thus, affect the chemical relationships of the body and the psychological or emotional aspect of man.

Dr. Goodheart has documentation on several patients who suffered immediate and startling reduction in muscle tone of the pectoralis major clavicular as a result of severe emotional trauma. In each case, Dr. Goodheart's records indicate that the muscular tone was well balanced and strong, and the patients were all emotionally stable before the trauma. He further observed that immediate pectoralis major clavicular weakness would recur while the patients were thinking of their past psychological trauma. If the pectoralis major clavicular weakness was corrected, the muscle would, once again, become weak when the patient relived the trauma. Dr. Goodheart found that by holding a prolonged neurovascular contact for the pectoralis major clavicular for 3 to 4 minutes while the patient relived the memory of the trauma, it would result in abolishing this pectoralis major clavicular weakness. The patients often remarked that they felt much better mentally immediately. Upon retesting the pectoralis major clavicular muscle while the patient relived the emotion, the neurovascular stimulation abolished the muscular weakness and the patient seemed to have no subsequent mental or physical weakness as a result of the trauma.

Dr. Goodheart feels that we should be able to forget emotional trauma and emotional trauma should not penetrate into the soma. He further feels that there is a psychological threshold switch which connects man's body with his mind. Occasionally, this switch is turned off by the power of an emotional shock or trauma; it should be rapidly turned back on, but sometimes the body fails to do so. This opens the channel between man's body and his mind, and the mind then starts to influence body function. Therefore, man is left prey to his emotions, which, in turn, affects his digestion or some other physiological process.

## TREATMENT

In an emotional pattern, palpate the T.S. Line, which many times will indicate pectoralis major clavicular involvement, either unilaterally or bilaterally. If the pectoralis major clavicular muscles test strong, ask the patient to relive the memory of the painful or traumatic emotional experience and then retest the muscles. After 30 to 60 seconds of reliving the memory, the muscles will become extremely weakened. Then, hold the emotional contact (neurovascular point) for the pectoralis major clavicular from 1 to 4 minutes, depending upon the degree of emotional trauma. Retest the pectoralis major clavicular muscles and they should test strong. The patient is then asked to again relive the traumatic, emotional memory; the muscles are then retested to see if they maintain correction under the emotional stress. This process can be enhanced by reversing the conception vessel and governing vessel or running it backwards prior to asking the patient to relive the trauma. Then, while the patient relives the trauma, one can observe eye movements underneath the closed lids. These are called "REMS" and are characteristic of subconscious brain activity. After a periof of 30 to 60 seconds of observable REMS, apply the neurovascular contact at the gastric center; this may be held from 1 to 4 minutes. Retest the appropriate muscles, and generally speaking, there should be a tremendous return of strength, with no loss following the second memory recall process. Following this procedure, the emotional pattern is locked by running the conception vessel and governing vessel from their points of origin to their points of termination.

# "LOVETT" BROTHER
*(Half-Wit Brother)*

Each vertebral segment follows a respiratory pattern similar to that of the sacrum. The most inferior portion of the spinous process moves forward toward the umbilicus on inspiration and backwards on expiration. As stated previously, when we breathe, the bones of the skull move, and this acts as a pump to circulate the cerebral spinal fluid down the spinal cord and through the vertebral column. Visualize each vertebral segment acting as an individual member of a bucket brigade, passing the flow of cerebral spinal fluid down the cord. Sixteen to twenty times per minute, each vertebral segment exhibits a massaging effect on the dura sleeve of the intervertebral foramen. Therefore, the vertebral movement stimulates the intervertebral foramen coincident with respiration.

In the past, implementation of this bucket brigade has been therapeutically ineffective. Dr. Goodheart just recently discovered that each vertebral segment literally has a Lovett Brother which, allegorically speaking, can handcuff its brother. For example, in the bucket brigade, the atlas can handcuff (restrict) the fifth lumbar and the fifth lumbar is capable of handcuffing (restricting) the atlas. Therefore, even though their house is on fire, they have handcuffed each other and become ineffective transmitters of the necessary cerebral spinal fluid. Likewise, the sphenoid is directly related to the coccyx, the occiput is directly related to the sacrum, etc. Anytime one vertebra becomes subluxated or fixed in the spine, its Lovett Brother should be therapy localized or challenged. As one vertebra moves, the other vertebra will also move in the same or opposite direction for structural stability and counterbalance. For example, if one were to therapy localize the atlas and fifth lumbar, the patient would be placed in a prone position with one hand over the atlas and one hand over the fifth lumbar. Then, a strong indicator muscle would be retested; and if the Lovett Brother was involved, a strong indicator muscle would become weak.

Following spinal correction, if one finds spinous process hypersensitivity upon palpation of the fifth lumbar, one could relieve that particular problem by going to the same side on the atlas tubercle and pressing downward, coincident with respiration. For example, if one was to find spinous processes, hypersensitivity, challenge the spinous processes in a forward direction on inspiration. If this weakens the strong indicator muscle, then it is in that direction in which the correction will be made on inspiration. Challenge the spinous process headward on expiration. If this weakens the indicator muscle, that is the direction, correction will be made on that phase of respiration. For example, for an inspirational fault, press downward with each inspiration. Repeat this procedure 5 to 10 times and this will release the hypersensitivity of the fifth lumbar spinous process. This same procedure may be used on each vertebral segment and its Lovett Brother on the proper phase of respiration.

In the dorsal spine, it is wise to exert pressure on the spinous process in an inferior or footward direction on inspiration and, at the same time, exert an upward or headward counterpressure over the ribs on expiration. In other words, as you press the dorsal spinous process footward, lift the rib section headward. A countermotion is only necessary in the thoracic area. This technique is only used following correction of the area where a Lovett Brother may still exhibit hypersensitivity following correction.

The following chart illustrates each Lovett Brother and its associated structure.

## "LOVETT" BROTHER VERTEBRAE

*(Half-Wit Brother)*

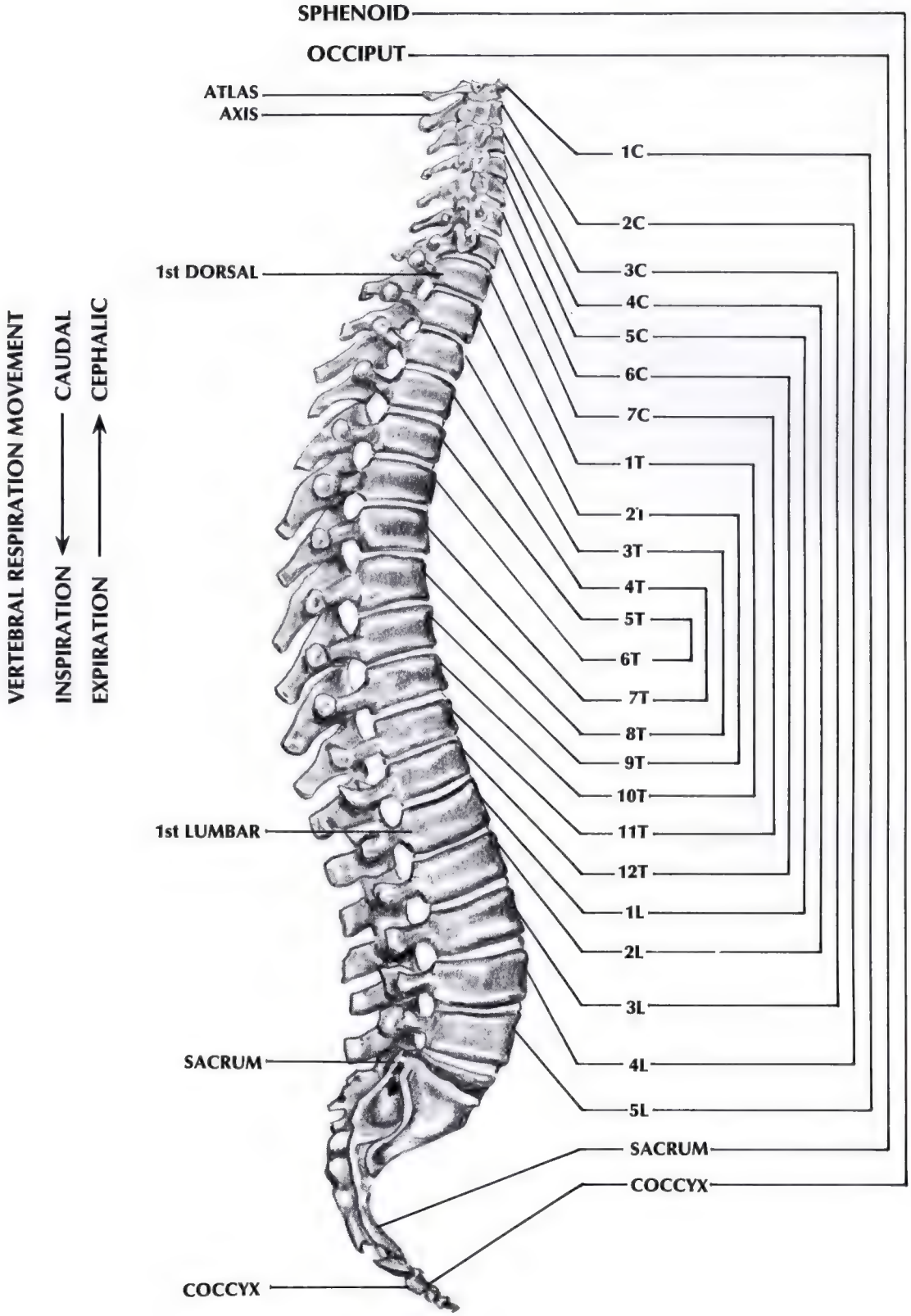

# APPLIED CHIROPRACTIC KINESIOLOGICAL DIAGNOSIS AND TECHNIQUE FOR SPINAL AND PELVIC SUBLUXATIONS AND FIXATIONS

Test a muscle in the usual fashion, e.g., psoas. If it is weak, treat it according to any one or combination of the five elements which emit through the intervertebral foramen, such as the neurolymphatics, neurovasculars, nerve, nutrition, cerebral spinal fluid or acupuncture meridian connector. Retest the psoas. If it is strong, ask the patient to place fingertips (therapy localize) from both his hands on the axis. Retest the psoas. If there is a fault at the axis which could be mechanical or related to the atlas or 3rd cervical in a vertebral way, there will be marked weakening of the psoas despite the fact that you may have strengthened the muscle by any of the five intervertebral foraminal elements. If the muscle weakens, then examine the area for mechanical faults.

After a spinal fault has been therapy localized, one must challenge the fault to determine the line of correction and the phase of respiration which abolishes the muscle weakness. To challenge, press the vertebra lightly from right to left, posterior to anterior, superior to inferior, and/or any combination of these directions. Following each vertebral challenge, retest the indicator muscle. When the appropriate challenge is made, it will result in the strong indicator muscle becoming weak. Corrections are always made in the challenged direction which resulted in the strong indicator muscle becoming weak.

Next, therapy localize the Lovett Brother by placing one of the patient's hands over the axis and the other hand over its corresponding vertebra, e.g., C-2 and L-4. Retest the strong indicator muscle; and, if it once again becomes weak, the Lovett Brother is also involved and needs to be adjusted. This procedure can be utilized for correction of all spinal and pelvic subluxation.

## RESPIRATORY SPINAL AND PELVIC CORRECTION TECHNIQUE

If, for any reason, (e.g. severe whiplash) a patient cannot tolerate the usual thrust which accompanies an adjustment or spinal correction, utilize the following technique. Locate a strong indicator muscle and challenge the vertebra in the before-mentioned fashion. Then, find the phase of respiration which will abolish the weakness and repeat this same procedure using 3 to 5 pounds of pressure on 4 to 5 respirations. Rechallenge or retherapy localize the vertebral fault to verify correction. Any time a Lovett Brother is involved, both vertebrae will have the same respiratory phase but will not necessarily challenge in the same direction. Therefore, one must challenge the Lovett Brother to determine the direction of correction.

## SPINAL FIXATION

The concept of subluxation of the vertebra, sacrum, ilium, or even an extremity is easily visualized. However, the concept of these structures being locked into place or out of their normal respiratory phase is certainly more difficult to imagine. The diagnosis of fixation is complicated by the fact that they are not visible on x-ray nor are they detectable by heat-reading devices or by motionless palpation.

Spinal fixations usually occur in units of three and frequently result in bilateral muscle weakness. Subclinical spinal microfixations, however, do not result in bilateral muscle weakness, but are evidenced by a fixation usually of only one anterior or one posterior facet.

Motion could be considered one of the first laws of Chiropractic. Each spinal and pelvic structure has a normal orthopedic range of motion in addition to a normal respiratory motion. It is this primary respiratory motion which is mainly lost in microfixation. In fixations, the normal orthopedic range of motion is decreased in addition to the respiratory motion.

Recurrent subluxations are frequently caused by a non-palpable microfixation or fixation. Fixations usually occur in groups of three vertebrae due to the intricate spinal muscles, specifically the rotatores brevis and longus. The rotatores brevis muscle runs from the transverse process of one vertebra up to the lamina of the vertebra immediately above. The rotatores longus runs from the transverse process of one vertebra and inserts into the 2nd vertebra above its origin. The rotatores brevis muscle imbalances are seen on x-ray in the form of vertebral rotation. This is due to one rotatores brevis constricting and the opposite being hypotonic. The spinous of the vertebra will be pulled toward the side of the rotatores brevis spasm. Spasm or hypertonicity of one rotatores longus muscle causes the vertebra to become laterally flexed.

Balance the musculature before correcting a spinal fixation. K-27 is an acupuncture point located at the junction of the first rib and the proximal end of the clavicle. The neurolymphatic points for the erector spinae (rotatores longus and brevis) muscles are located under K-27. These points should be manipulated with soft-tissue technique before one begins correction of any spinal fixation.

# FIXATION CHART

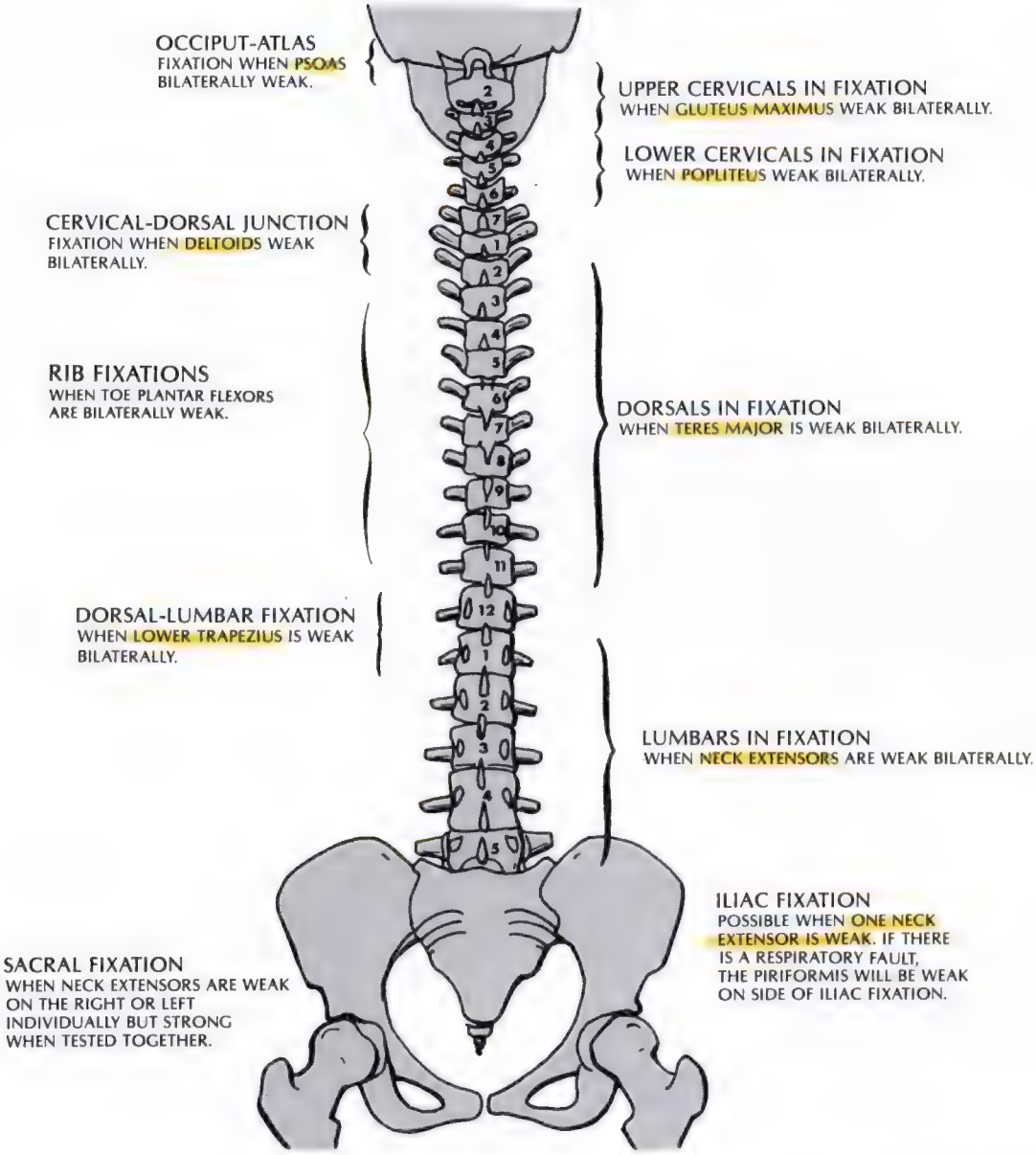


## THERAPY LOCALIZATION

Fixations, which occur at the various spinal levels that are indicated on the chart on page 55, are easy to locate. Microfixations and fixations, which are not illustrated because they do not result in bilateral muscle weakness, are more difficult to locate.

A spinal fixation or microfixation cannot be therapy localized in the usual fashion. They must be therapy localized while the segment is in motion. A strong indicator muscle will become weak upon positive therapy localization of the fixation or microfixation. The fixation must then be challenged to determine the direction of correction.

## CHALLENGE

Challenge is necessary to determine if the fixation or microfixation is occurring at the anterior or posterior facet. Each segment of the entire spine can be challenged in less than a minute and a half. If the fixation or microfixation was located by muscle testing or therapy localization, challenge is still necessary to determine the direction of correction. The challenge is performed by pressing the spinous process of the vertebra in question from right to

left while pressing the spinous process above or below in the opposite direction from left to right. Note the ease of movement of the vertebra in question and then repeat the same procedure, this time pressing the vertebra in the opposite direction. Once again, note which direction the spinous process moves the easiest. The vertebra which is fixed tends to move easier into the lesion than away from the lesion. This is due to the muscle imbalance, and the vertebra will always move easily in the direction of muscle hypertonicity or tension. As stated before, fixations usually occur in groups of three segments, thus it is necessary to check the degree of motion of each segment in the group of three vertebra. Correction of fixations are always made in the direction of resistance and only after treatment of the neurolymphatic reflex point under K-27 has been stimulated. (See Chapter I.)

The technique for determining a fixation is based upon the movement of the vertebra. If a vertebra is fixed, the spinous process will move easily in one direction and when the examiner attempts to press the spinous process in the opposite direction, immediate resistance is noted. Press the anterior (superior) and then the posterior (inferior) facet to determine its ease of movement in the direction that the spinous process moved easily. The facet will either be fixated at the anterior or posterior facet but rarely at both. Each vertebra of the unit of three will exhibit the same direction of motion not only of the spinous but also of the facet. If the anterior facet is fixed, adjust the last vertebra of the unit of three. With the opposite hand, stabilize the vertebra immediately above it. In the case of a posterior facet fixation, adjust the upper most vertebra of the unit of three and stabilize the vertebra immediately below the fixation with the other hand. Each of the fixed vertebra of the unit of three frequently requires correction.

The challenge is basically the same. Select a strong indicator muscle and then press the vertebra in the direction you believe it to be fixed. Recheck the strong indicator muscle. If that is the correct direction, the strong indicator muscle will become weak upon reexamination. Following correction of the fixation, retherapy localize the segment in motion or rechallenge to verify correction.

## GRAVITATIONAL FIXATION

If a patient suffers from a recurrent cervical fixation, challenge the cervical spine for a gravitational weakness. Make sure the rest of the spine is free from fixation or subluxation before testing the area in question. Place the patient in a prone position and test a gluteus maximus, which is a good indicator muscle for gravitational cervical fixations. If necessary, correct any weakness through any of the five elements of the intervertebral foramen. Then, press the head and neck downward into the patient's body. Retest the gluteus maximus; if it becomes weak, give the patient a small amount of wheat germ oil which is palatable. Retest the indicator muscle and it should test strong. Rechallenge the gravitational cervical fixation by pressing the head and neck back down into the body and retest the indicator muscle. If it is now strong, the patient is in need of antigravitational supplements, e.g. wheat germ or he may need correction of the fixation in addition to wheat germ. If correction is necessary, challenge the segment as previously directed. Place the patient on four capsules of wheat germ per day (6 minims per capsule).

A patient with a recurrent sacral, lumbar or iliac fixation should also be examined for gravitational fixation. This patient will also exhibit strong neck extensors which become weak when the ischium, sacrum or lumbar spine is challenged by a downward and lateral pressure. If weakness occurs after challenge, give the patient a small amount of wheat germ oil (6 minims); and after he has tasted it, rechallenge the structure to verify if correction has taken place. If the neck extensors become strong, the patient is in need of antigravitational supplements, e.g., wheat germ or he may need correction of the fixation in addition to wheat germ. If correction is necessary, challenge the segment as previously directed and place the patient on four capsules of wheat germ per day (6 minims per capsule).

## OCCIPITAL FIXATION AND SUBLUXATION

### SYMPTOMS

Any one of the following symptoms may indicate an occipital fixation or subluxation: recurring headaches, difficult cervical flexion or extension, dizziness when looking up or down, recurrent cervical strain, back pain when getting up from a seated position.

### CLINICAL OBSERVATION

If a patient exhibits a high occiput in a standing position or bilaterally weak psoas muscles, this usually indicates an occiput fixation and/or occipital-atlas subluxation. Frequently, when a patient is in a prone position, one leg will appear short and when the patient is in a supine position, that same leg will appear long. This indicates an occipital fixation or subluxation. This occurs in the absence of any pelvic problems or actual anatomical deficiencies (may also indicate lateral atlas).

### THERAPY LOCALIZATION

The patient is in a supine position. Ask the patient to place the fingertips (both positive and negative surfaces) of both hands at the base of the occiput and retest a strong indicator muscle. If the indicator becomes weak, this indi-

cates a cranial fault, subluxation or fixation. If therapy localization has no effect on the strong indicator muscle, ask the patient to retherapy localize, this time turning his head from side to side and up and down as the indicator muscle is being retested. If this resulted in a positive therapy localization, it would indicate any one or combination of the before stated faults. Challenge will be necessary to isolate the lesion or lesions.

### CHALLENGE

1) Place the patient in a supine position and locate a strong indicator muscle. Place your fist along the cervical spine transverse processes, this will prevent lateral movement and stabilize the cervical spine on that side. With your opposite hand, press the occiput straight lateralward toward the side of stabilization. Retest the indicator muscle. If it tests weak, this would indicate an occipital fixation on the side challenged.
2) Ask the patient to stick his tongue straight out and test the indicator muscle, i.e., pectoralis major clavicular (PMC). Then, have the patient point the tongue to the left and right, retesting the indicator muscle after each direction. The occiput is adjusted on the side which the pointed tongue produced PMC weakness.

### TREATMENT

1) In the case where one observed a high occiput in a vertical position, correct it by stimulating the neurolymphatics and neurovasculars of the sternocleidomastoid, pectoralis major clavicular and anterior scalenus muscles. Following this treatment, if the patient still exhibits a high occiput, check the psoas. Bilateral weakness of the psoas, in conjunction with a high occiput after correction, indicates an occipital fixation or subluxation.
2) The patient is in a supine position. One will usually note a very sensitive area when palpating the base of the high occiput. Make a metacarpal contact on the high occiput side while the other hand contacts the general occipital area on the low occiput side; exert a small amount of traction on the cervical spine. The patient's head should not be turned. A thrust is given straight, lateralward over the sensitive area on the high occiput side. Frequently this adjustment will yield an audible correction, but it is not necessary. Retest the indicator muscle and reevaluate the occiput level in a standing position. Retherapy localize the occiput. Audible adjustments do not necessarily mean correction has been made in that area of the spine, it only indicates bone movement. One must always depend on the reexamination of the indicator muscle to determine correction.

## OCCIPUT-ATLAS ROCKER MECHANISM

Frequently patients with sedentary jobs or patients who work with their head or neck turned in one direction will exhibit occipital or atlas symptoms, but examination of the area is frequently negative. In these patients, the doctor should suspect an occiput-atlas rocker mechanism fault.

### CHALLENGE

The patient should be in a supine position. The patient attempts to approximate his chin to his chest without raising his head from the table. This motion flexes the occiput on the atlas. The examiner retests the strong indicator muscle; if it weakens, this indicates the fault is present. Next, the examiner tests for occiput on atlas extension. This is performed with the patient this time extending his head as far backward as possible without raising his head off the table. Once again, the strong indicator muscle is retested; if it becomes weak, the fault is present.

### TREATMENT

Correction is performed by having the patient perform the same flexion and extension as before but this time the doctor offers a counterresistance to the flexion and extension. The doctor should contact the temporo-occipital area bilaterally and then ask the patient to touch the chin to the chest as the doctor resists the motion. Ask the patient to extend his head as far backward as possible and once again the doctor resists the motion. The doctor should have the patient flex and extend the head three times as the doctor offers counterresistance before the doctor reexamines the fault to verify correction.

## CERVICAL FIXATION DISCUSSION

The before described method of isolating microfixations and fixations can be applied easily to the dorsal and lumbar spine. To locate a cervical fixation or microfixation utilize the same basic principle of motion to locate the fault but a different technique is used to determine the vertebral motion.

## ATLAS-OCCIPUT ROCKER MECHANISM

### CHALLENGE

The testing procedure is very similar to the occiput-atlas rocker mechanism but differs in that the patient's head is off the table. The patient should be in a supine position. The patient lifts his head from the table and attempts to place his chin on the manubrium of the sternum, thus flexing the atlas-occiput area. The doctor then retests the strong indicator muscle; if it becomes weak, then a fault exists. In the event the indicator muscle remained strong, ask the patient to extend his head and neck as far backward as possible but without touching his head to the table. The indicator muscle is retested. If it weakens, then a fault exists.

### TREATMENT

Correction is initiated with the patient's head lying on the table. The doctor bilaterally contacts the patient's occipital-temporal bone area. The patient remains passive and the doctor flexes the patient's head and neck so that the chin approximates the patient's chest. Then the doctor flexes the patient's head and neck as far backward as possible. This procedure is repeated three times. The atlas-occiput rocker mechanism is then rechallenged to verify correction.

## ATLAS, AXIS AND 3RD CERVICAL FIXATION

Atlas, axis and third cervical fixation can be isolated by challenge or motion therapy localization as deliniated in the earlier portion of this section under the respective subtitles. To correct an upper cervical fixation, the patient can be either in a prone or supine position. Locate a strong convenient indicator muscle. The doctor then contacts the right posterior portion of the atlas transverse process with one hand and the left anterior portion of the transverse process with his other hand. The doctor then attempts to rotate the atlas from right to left and from left to right. Note the side that the vertebra feels "fixed." If the vertebra moves freely on each side, no fixation is present. A vertebra which is fixed will tend to move easily into the lesion but not away from the lesion.

The same procedure is used for the second and third cervical vertebra that was used for the atlas to determine if a fixation exists and also to determine if the fixation is occurring at the anterior (superior) facet or the posterior (inferior) facet. In an anterior facet fixation, the last vertebra of the group must be corrected first. In this case, C-3 would be adjusted on C-2. The contact on C-3 would be near the facet line and with the doctor's other hand offering a counterresistance to C-2 on the opposite side of the fixation. A short sharp thrust is all that is usually necessary and correction is always made in the direction of vertebral resistance.

If a posterior facet is fixed, utilize the same method of correction with counterresistance to the segment below. In posterior fixations, however, the top vertebra of the group of three must be adjusted first.

## LOWER CERVICAL FIXATION

Use the same technique described under the subheading of Atlas, Axis, Third Cervical Fixation for the other cervical vertebrae. Thus, there is no need to repeat the same technique for C-4 to C-7.

## DORSAL AND LUMBAR FIXATION

The method of determining fixation and microfixation of the dorsal and lumbar spine was described under the subheading of Spinal Fixation, Therapy Localization and Challenge under the general heading of Chiropractic Kinesiological Diagnosis and Technique for spinal and pelvic subluxation and fixation. Thus, there is no need to repeat the same material under this heading.

## UPPER DORSAL RIB FIXATION

The levator costalis muscles run from the upper surface of the costal border of the rib to the transverse processes of the vertebrae above. They are located on each pair of ribs, and the last levator costalis muscle begins on the first rib and inserts into the seventh cervical transverse process. Because of the involvement of the levator costalis muscle, ribs can also become fixed. Therefore, in addition to examining for vertebral movement, one should examine for rib movement as well.

Frequently, in cervical dorsal fixations, the first three ribs may also become fixed. Examine the first two ribs for fixation by pressing downward on the first rib on the left, and, at the same time, pressing upward (headward) on the first rib on the right. Then, reverse the process by pressing the first rib on the right downward (footward) and the

first rib on the left upward (headward). This procedure can be used to examine the movement of all the ribs, checking two ribs at a time. If the ribs are in a state of fixation, those on one side will show greater movement than those on the other. After one has located the fixed ribs, one should proceed to the junction of the rib and transverse process. Press on the junction of the rib and its articulation with the transverse process, utilizing basically a P-A direction. One can feel a rather free motion on one side and a restriction on the opposite side, indicating the presence of a fixation. Rib fixations can be challenged by using the same technique described under the general heading of Chiropractic Kinesiological Diagnosis and Technique under the subheading of Challenge.

### TREATMENT

If the posterior side is fixed, try adjusting rib one, for example, on the right, towards rib two on the left. However, if it is the anterior side that is fixed, adjust rib three on the left towards rib two on the right, or vice versa, depending upon which side is weak.

## ANTERIOR DORSAL AND LEVATOR COSTALIS TECHNIQUE

Anterior dorsals can cause chest pain, upper gastro-intestinal distress and upper back and neck pain. The anterior dorsal caused by trauma or reflex activity is best located by pressing upward against the spinous process of the vertebra in question. The spinous process of the anterior vertebra will be sensitive to pressure.

The levator costalis brevis gains its origin from the transverse process of the vertebra and inserts into the ribs below. The levator costalis longus gains its origin from the vertebral transverse process and inserts into the costal angle two ribs below its origin.

Locate the anterior dorsals through therapy localization or palpation. The levator costalis brevis muscle over the rib immediately below the offending anterior dorsal vertebra should then be pressed in a medial anterior direction, or the levator costalis longus over the second rib below the offending anterior dorsal vertebra should be pressed in the same direction. Retest a previously strong indicator muscle. If the indicator muscle tests weak, find the phase of respiration which abolishes the weakness. Repeat correction of the muscles in the challenged direction which produced weakness, on the phase of respiration which corrects the weakness. Repeat this procedure on 4 to 5 respirations. Then, palpate the anterior dorsal or retest the indicator muscle to verify correction. It may be necessary to repeat this procedure twice. If the anterior vertebra persists, correct it through any one of the standard anterior dorsal techniques and utilize the before-mentioned technique on the levator costalis muscles.

SACRAL INSPIRATION ASSIST

LOGAN BASIC CONTACT

## SACRUM BALANCE

Sacral balance is important to achieve good pelvic balance and muscle tone. A quick review of how to balance the sacrum is as follows.

Test the hamstrings one at a time. If they are not bilaterally strong, ask the patient to take a deep breath and hold it. Then, retest the hamstring; and if inspiration increased the strength of the muscle, the sacral apex must be adjusted lightly anteriorly on 3 to 4 inspirations. Following treatment, retest the previously weak hamstring to verify correction. If the inspiration did not increase the muscle's strength upon reexamination, ask the patient to exhale and retest the hamstring. If exhalation increases the hamstring's strength, perform a basic contact on the side of

weakness with the thumb of one hand. A basic contact is performed by placing the thumbs, if bilateral, or thumb, if unilateral, under the lower one-third of the sacrum and lifting the sacrum superiorly as the patient exhales. Repeat this procedure on 4 to 5 expirations.

## SACRUM FIXATION

Sacral fixation may be indicated by the presence of weak left and right neck extensors (splenius capitis), tested separately, or positive therapy localization over the sacrum. The sacral fixation may be challenged by attempting to move the spine of the sacrum first to the left and then to the right with the thumb. Treatment would be made in the direction which displays the greatest amount of resistance to the testing pressure. Following treatment, retest the splenius capitis or retherapy localize the sacrum to verify correction.

## SACRAL WOBBLE FAULT

The sacral apex wobbles forward on inspiration and backward on expiration. This wobbling motion of the sacrum is continuous with each inspiration and expiration. The sacrum can become fixed in a wobble position and this occurs most frequently on the side of the patient's handedness, e.g. if the patient is right handed, the wobble occurs more frequently on the right side. This condition can be determined by therapy localization or challenge.

To therapy localize the sacral wobble, put the patient in a prone position and ask him to lay both hands on the sacrum with the fingertips pointed toward the symphysis pubis and retest a hamstring. If the sacral wobble fault is present, it will result in the indicator muscle becoming weak.

To challenge for a sacral wobble fault on a right handed person, place your hand on the left lower third of the sacrum and put your right hand under the right anterior superior iliac spine. Then, press the sacrum toward the pubic symphysis with your left hand while pulling posteriorly on the anterior superior iliac spine. If this sacral wobble fault challenge results in weakening the indicator muscle, correction is made in the same fashion and on the phase of respiration which abolishes the muscle weakness. If the sacral fault challenge results in increased strength, challenge the opposite side.

The sacral wobble fault often occurs in conjunction with an occipito-atlanteal countertorque or a sphenoid cranial fault. Many times, after correction of a sacral wobble, the body is able to express its language to a greater degree, and other faults often become observable.

## PELVIC FAULTS

Pelvic faults, according to Dr. Major DeJarnette can be classified into three major categories. His method of classification of the pelvis has been widely accepted by the profession and it is easy to learn and apply.

## CATEGORY III

Category III is a normal pelvis, thus, there is no positive therapy localization to the sacroiliac articulation. The involvement is in the lumbar spine and will easily therapy localize. To therapy localize the lumbar spine, place the patient's fingertips (both positive and negative surfaces) over the lumbar spine and retest the strong indicator muscle. If the strong indicator muscle weakens, it indicates a positive therapy localization. In the event that the indicator muscle remained strong, then therapy localize a different area of the spine by moving the patient's hands to an adjacent area of the lumbar spine. If there was a positive therapy localization, challenge the vertebra to determine the direction of correction. To challenge a vertebra, push the spinous process or lamina pedicle junction lightly from right to left, superior to inferior, posterior to anterior or any combination of these directions. Following each challenge, retest the indicator muscle. The challenge that results in the strong indicator becoming weak, is the direction that the adjustment should be made. Following correction of the vertebra, retherapy localize or rechallenge the vertebra to verify correction. To correct and localize a disc involvement, see Disc under the subheading of Unusual Therapy Localization.

## CATEGORY II

### THERAPY LOCALIZATION

Category II is either a sacroiliac lesion or an iliosacral lesion, resulting in a posterior ilium or a posterior ischium. A category II can be therapy localized by having the patient place one hand over the involved sacroiliac articulation. The strong indicator muscle will weaken upon reexamination while therapy localizing. Have the patient therapy localize with both the positive and negative surfaces of his hands. The doctor must determine whether the patient has a posterior ilium or a posterior ischium. The signs of a posterior ilium and ischium are listed on the following page for your convenience.

## SIGNS OF A POSTERIOR ILIUM

With the patient in a supine position, one leg will appear short. Palpation of the short leg will reveal the following: pain elicited upon palpation at the upper attachment of the sartorius and gracilis, pain elicited upon palpation over the obturator and also the medial one-third of the thigh, pain elicited upon palpation below the knee. Pain can also be elicited upon palpation over the first rib head on the side of the positive ilium.

## SIGNS OF A POSTERIOR ISCHIUM

With the patient in a supine position, one leg will appear longer. Palpation of the long leg will reveal the following: pain elicited upon palpation at the upper attachment of the pectineus and adductor longus, pain elicited upon palpation of the lower one-third of the vastus lateralis and also the biceps femoris, pain elicited upon palpation at the lateral aspect of the leg and directly over the ischium. Pain can also be elicited over the first rib head on the long leg side.

If all of the above-mentioned signs are not present, suspect a category I or a sacral lesion.

## CHALLENGE

Press the posterior ilium or ischium in an anterior and lateralward direction. Retest the strong indicator muscle. If it weakens, this is the direction that correction should be made.

## TREATMENT

Balance the muscle involved in either the posterior ilium or ischium before beginning any osseous correction. If the muscles do not reveal weakness using standard muscle testing (See Chapter IV) have the patient therapy localize the neurolymphatics to each muscle and retest the muscle. This will often reveal muscle weakness that does not ordinarily appear. Frequently, by correcting the musculature involved in a posterior ilium or ischium, the osseous misalignment will be corrected, and thus, no adjustment will be necessary in some cases.

The osseous adjustment of a posterior ilium or ischium can be performed in a side roll position or with the patient prone. If for some reason the patient is unable to tolerate an adjustment to the pelvic structure, the DeJarnette block method is equally effective but requires more time to administer. With the patient in a supine position, place a DeJarnette block under the posterior ilium and another DeJarnette block under the ischium on the opposite side. The long leg is flexed and is brought medially, while the short leg is laterally flexed. The patient holds the blocks in place as the patient's body weight corrects the osseous misalignment. Irrespective of the method of correction, retherapy localize the pelvis to verify correction.

# CATEGORY I

Category I is a nonsubluxated, torqued pelvis. One side of the pelvis is in a torqued position and the opposite side is countertorqued.

## SIGNS

Pain can be elicited upon palpation of the first rib head. The patient's leg length will appear even in a supine position, but when the patient is in a prone position, one leg will appear short. Frequently, the piriformis, sacrospinalis and quadratus lumborum will be weak. A cranial bone countertorque is frequently present in a category I lesion (not a true cranial fault). For ease of learning, category I has been divided into two phases. The first phase is signs, therapy localization and challenge.

## THERAPY LOCALIZATION

A category I is therapy localized by having the patient in a prone position with the patient's right hand over his right sacroiliac articulation and his left hand over his left sacroiliac articulation. If the lesion is present, a strong indicator muscle will weaken. If the before stated signs are not present but positive therapy localization occurs, suspect a bilateral posterior ilium or bilateral posterior ischium. After one has therapy localized bilaterally to the sacroiliac joints simultaneously, have the patient place both hands over each sacroiliac joint separately and retest the indicator muscle. The sacroiliac joint which resulted in positive therapy localization with both of the patient's hands over it is the joint which is torqued. Note the findings.

## CHALLENGE

The challenge is performed by pushing anteriorly and lateralward on the posterior iliac spine of one ilium and simultaneously pushing in the same direction on the posterior aspect of the opposite ischium. Retest the strong indicator muscle. If it weakens, that is the direction in which the pelvis is torqued and countertorqued. If the strong indicator muscle did not weaken, challenge the opposite ilium and ischium in the same fashion.

## PHASE TWO

Piriformis weakness is frequently present in a category I. Test the muscle in the usual fashion, but if the weakness is not immediately evident, test the muscle in a weight-bearing position. Ask the patient to rise from his prone position on the table to where he is on all fours and retest the piriformis. If piriformis weakness is evident in either position, determine the phase of respiration that will neutralize the piriformis weakness. A quick review of the procedure is as follows. If inspiration increased the strength of the piriformis muscle, press the mastoid forward on inspiration and press the sacrum forward by contacting the apex of the sacrum on inspiration. If expiration increased the strength of the piriformis, press the mastoid backward on expiration and establish a thumb contact (basic contact) underneath the lower one-third of the sacrum and lift the sacrum posteriorly coincident with expiration. Retest the piriformis in the position that weakness was discovered to verify respiratory correction. The respiratory assist correction will not replace the need for treatment of the neurolymphatics or neurovasculars or any of the other elements of the intervertebral foramen that may be needed to correct the piriformis weakness. Nutrition is small amounts of Vitamin E.

If the piriformis did not show weakness in either position or following correction of any weakness to the piriformis, have the patient therapy localize the neurolymphatics for the sacrospinalis and quadratus lumborum. Therapy localization can be performed by placing one of the patient's hands just above the crest of the ilium and the other hand on the same side of the spine but just slightly above the other hand around D-12 and L-1. Retest the strong indicator muscle; if it weakens, treat it accordingly. (See Chapter IV.) Then, test the sacrospinalis and quadratus lumborum of the opposite side in the same fashion. Also examine the gluteus maximus and medius and treat if indicated. Nutritional support is ACP Complex and a veal bone protomorphogen.

## TREATMENT

With the patient in a prone position, place a DeJarnette block under the femoral head on the posterior ilium side, which is the side of the short leg. On the posterior ischium side, the block is placed under the anterior-superior iliac spine. If in doubt about the position of the blocks, have the patient retherapy localize in the same fashion that revealed the category I. If the blocks are placed correctly, the therapy localization will be negative. The patient should be on the blocks for 3 to 5 minutes.

Always adjust the non-involved posterior ilium. The non-involved side can be determined by therapy localization. A double hand contact (therapy localization) on the non-involved side will not weaken the strong indicator muscle. The adjustment of the non-involved side is always in the challenge direction which produced weakness. The correction is 5 to 10 light adjustive thrusts. Following correction, all signs of the category I should be abolished along with negative therapy localization of the torqued ilium.

# CRANIAL TORQUE LESION

Also present in a category I is a torque lesion of the cranium. The lesion frequently affects both the temporal bone and the sphenoid bone. The clinical picture is usually a bulged temporal bone on the opposite side of the involved sacroiliac joint. The patient will usually exhibit a protruded eye due to the sphenoid bone being high on that side.

## THERAPY LOCALIZATION

Have the patient place his fingertips from each hand (positive and negative surfaces) on each temporal bone. A strong indicator muscle will weaken when retested if the lesion is present. Then, have the patient remove one

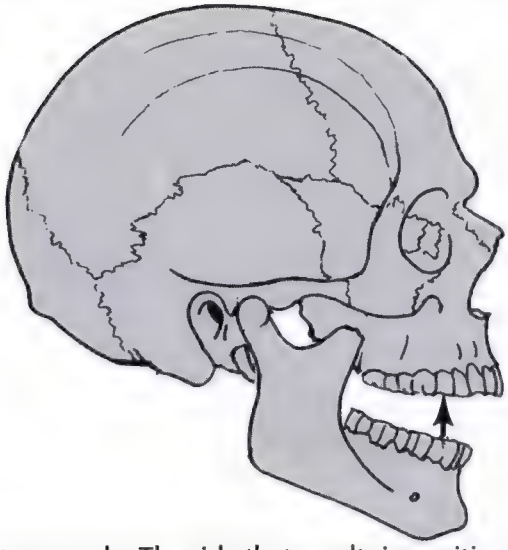

hand and retest the strong indicator muscle. The side that results in positive therapy localization is the side of the temporal bone lesion. Next, have the patient place the thumbs of both hands in the roof of his mouth to therapy localize for a sphenoid lesion. If the strong indicator muscle weakens, the sphenoid lesion is present.

### CHALLENGE AND CORRECTION

Correct the temporal bulge by exaggerating the lesion based upon the direction of successful challenge. (See Cranial Faults One-Half-Breath-In-Assist.) It appears that approximately 95 percent of all category I's are inspiration. Thus, correct the sphenoid lesion by placing a gloved finger into the patient's mouth and press the hard palate superior coincident with inspiration. For patients that are half-breath-in-assist, correct the sphenoid in the same fashion but on a half-breath inspiration. Retherapy localize the cranial torque lesion to verify correction. For further information, see Chapter I.

## ILIAC MOVEMENTS ON RESPIRATION

On inspiration, the anterior superior iliac spine moves laterally and the posterior superior iliac spine moves medially. The opposite motion occurs on expiration (the posterior superior iliac spine moves laterally and the anterior superior iliac spine moves medially).

### ILIUM FIXATION

The ilium can be fixed in one of three positions:

1. Inspirational Fixation — a respiratory fixation.
2. Expirational Fixation — a respiratory fixation.
3. Fixation — a simple fixation where the bone is in place but does not move in its normal range.

### SIGNS OF ILIUM FIXATION

1. Unilateral Weakness of the Splenius Capitis
   This may be found when muscle testing and indicates ilium fixation; or, after the splenius capitis has been balanced, challenge of the ilium will cause the splenius capitis to become unilaterally weak.
2. Piriformis Weakness
   If the piriformis is weak, ask the patient to inspire; and if an ilium fixation is present, the inspiration will result in momentary strength to the piriformis and splenius capitis.

### CORRECTION OF ILIUM FIXATION

If the piriformis strengthens on inspiration, this indicates the ilium is fixed in an expirational respiratory phase. Conversely, if the piriformis strengthens on expiration, it indicates the ilium is fixed in the inspirational phase of movement. Correction is made on the proper phase of respiration and in the ilium's plane of motion (the direction in which the challenge was successful).

### THERAPY LOCALIZATION OF INTERNAL/EXTERNAL ILIUM

Positive therapy localization to the sacroiliac joint in the absence of the other signs of a posterior ilium or ischium can be indicative of an internal or external ilium. To determine if the ilium is internal or external, have the patient take a deep breath while therapy localizing the sacroiliac joint. If the deep breath abolishes the muscle weakness on therapy localization, this can indicate the ilium is internal or medial on the sacrum. Correction can be performed based upon the respiratory spinal and pelvic correction technique (See subheading this chapter), or adjust

the ilium in the direction of successful challenge which produced muscle weakness. Retherapy localize to verify correction. If inspiration does not abolish the muscle weakness, then ask the patient to exhale and retest the indicator muscle. If this results in the weak indicator muscle becoming strong, the ilium would then be in an external position or moved away from the sacrum. Correction can be based upon the respiratory spinal and pelvic technique or by adjusting the ilium in the direction in which the challenge produces muscle weakness. Retherapy localize to verify correction.

## UNUSUAL THERAPY LOCALIZATION TECHNIQUES

1. Eye Defects
   In obvious eye problems, e.g., myopia, retinitis pigmentosa and macular degeneration, therapy localization in the usual fashion will not always elicit a response. Therefore, one must use a cross-hand pattern and place the right hand on the left eye and the left hand on the right eye. When it is necessary to use this cross-hand method, ask the patient to take a deep breath or exhale. This will neutralize the patient's respiratory phase so that one can determine the direction in which the fault must be corrected by challenging.
2. Femoral Arthritis
   In difficult cases of femoral arthritis, have the patient therapy localize the neurolymphatic of the tensor fascia lata, as it is frequently involved. The neurolymphatic may require up to five minutes of soft-tissue manipulation. The results are spectacular.
3. Disc Lesions
   Have the patient place one hand above and one hand below the disc space in question. Weakening of a strong indicator muscle indicates the presence of a disc lesion.

### CHALLENGE TECHNIQUE FOR POSTERIOR SHIFT OF NUCLEUS PULPOSUS

Press the spinous process together, above and below the disc involvement and retest the indicator muscle. If the indicator muscle weakens, that is the direction of correction. Use Respiratory Spinal and Pelvic Correction Technique on acute patients. If the indicator muscle did not change, then press the spinous process apart and retest the indicator muscle.

### CHALLENGE TECHNIQUE FOR LATERAL SHIFT OF NUCLEUS PULPOSUS

Press the transverse processes of the vertebrae surrounding the involved disc together and retest the indicator muscle. The side of the vertebra that the strong indicator muscle weakened is the side of the respiratory spinal and pelvic correction technique should be applied. Check both sides of the spine.

## CLAVICLE SUBLUXATION OR FIXATION

Bilateral soft-tissue manipulation of K-27 and activation of the umbilical neurolymphatic should be performed before challenging or therapy localizing the clavicle. Often, the clavicle will subluxate or fixate in the same direction as the atlas, and, therefore, require attention. For example, if the atlas is right laterally, then the involved clavical will also be right laterally. If the atlas is anterior on the left, the involved clavicle will be anterior on the left. To challenge the clavicle, one must press it upward, downward, pull it outward or push it posteriorly. After each challenge, be sure to check the indicator muscle to determine the direction of correction. The clavicle should be treated in the challenged direction which produces strength.

# APPLIED KINESIOLOGICAL REFLEX POINTS

### NUTRITION

1 — ADRENAL EXTRACT
2 — BETAINE HCL
3 — BILE SALTS
4 — BONE CONCENTRATE
5 — BRAIN CONCENTRATE
6 — CALCIUM
7 — COMFREY MATERIAL
8 — FENUGREEK
9 — HEART EXTRACT
10 — IODINE/THYROID EXTRACT
11 — KIDNEY EXTRACT
12 — LACTIC ACID PRODUCTS
13 — LIVER EXTRACT
14 — LUNG EXTRACT
15 — NIACINAMIDE
16 — OVARIAN/TESTICULAR EXTRACT
17 — PANCREAS EXTRACT
18 — PROSTATE/UTERUS EXTRACT
19 — SPLEEN EXTRACT
20 — VITAMIN A
21 — VITAMIN B
22 — VITAMIN $B_6$
23 — VITAMIN C
24 — VITAMIN E
25 — VITAMIN F
26 — VITAMIN G

| MUSCLE | ORGAN | T.S. □ | N.L. | N.V. ○ | NUTRITION |
|---|---|---|---|---|---|
| ABDOMINALS — TRANSVERSE | DUODENUM | 17 | 1 | | 24 |
| ABDOMINALS — RECTUS | DUODENUM | 17 | 2 | | 24 |
| ADDUCTORS | CLIMACTERIC | 10 | 3 | 7 | |
| CORACOBRACHIALIS | LUNGS | 14 | 4 | 3 | 14 |
| DELTOID | LUNGS | 13 | 5 | 3 | 14 |
| DIAPHRAGM | | | 6 Right | 3, 5, 6 | |
| GLUTEUS MAXIMUS | PROSTATE/BROAD LIGAMENT | 8 | 7 | 7 | 16, 24 |
| GLUTEUS MEDIUS & MINIMUS | UTERUS/SEMINAL VESSICLES | 10 | 8 | 4 | 24 |
| GRACILIS | ADRENALS | 4 | 9 | 6 | 1 |
| HAMSTRINGS | RECTUM | 6 | 10 | 5 | 24 |
| INFRASPINATUS | THYROID | | 11 | 4 | 10 |
| INTRINSIC SPINAL MUSCLES (K-27) | | | 12 | | |
| JAW MUSCLES | CLICKING JAW | | 13 | 13 | |
| LATISSIMUS DORSI | PANCREAS | 16 | 14 | 9 | 17, 20, 25 |
| LEVATOR SCAPULAE | | | 15 | | |
| NECK FLEXORS & EXTENSORS | SINUSES | 11 | 16 | 13 | 15,22 |
| PECTORALIS MAJOR — CLAVICULAR | GASTRIC | 15 | 17 | 1 Left | 2, 21, 26 |
| PECTORALIS MAJOR — STERNAL | LIVER & GALL-BLADDER | 5 | 18 | 2 Right | 3, 13, 20 |
| PERONEUS LONGUS & BREVIS | BLADDER | | 19 | 1 | 6, 26 |
| PIRIFORMIS | UTERUS/SEMINAL VESSICLES | 10 | 20 | 4 | 18, 24 |
| POPLITEUS | GALLBLADDER DUCT | 14 | 21 | 15 | |
| PSOAS MAJOR | KIDNEY | 1, 2 | 22 | 8 | 11, 24 |
| QUADRATUS LUMBORUM | APPENDIX | 7 | 23 | 4 Right | |
| QUADRICEPS FEMORIS | SMALL INTESTINE | 3 | 24 | 4 | |
| RHOMBOIDS | | | 25 | | |
| SACROSPINALIS | CYSTITIS | 15 | 26 | | |
| SARTORIUS | ADRENALS | | 27 | 6 | 1 |
| ANTERIOR SERRATUS | LUNGS | 13 | 28 | 3 | 14 |
| SUBSCAPULARIS | HEART | 12 | 29 | 3 | 9, 26 |
| SUPRASPINATUS | BRAIN FAG | | 30 | 3 | 5 |
| TENSOR FASCIA LATA | COLON | 9 | 31 | 4 | 7, 8, 12 |
| TERES MINOR | THYROID | | 32 | 11, 14 | 10 |
| ANTERIOR TIBIALIS | URETHRA | | 33 | 1, 4 | |
| TRAPEZIUS — MIDDLE & LOWER | SPLEEN | 18 | 34 Left | 5 | 19, 23 |
| TRAPEZIUS — UPPER | EYE, EAR | | 35 | 12 | 25, 26 |
| WRIST EXTENSORS | | | | 16 | |
| OPPONENS | CARPAL TUNNEL | | | | 2, 4 |

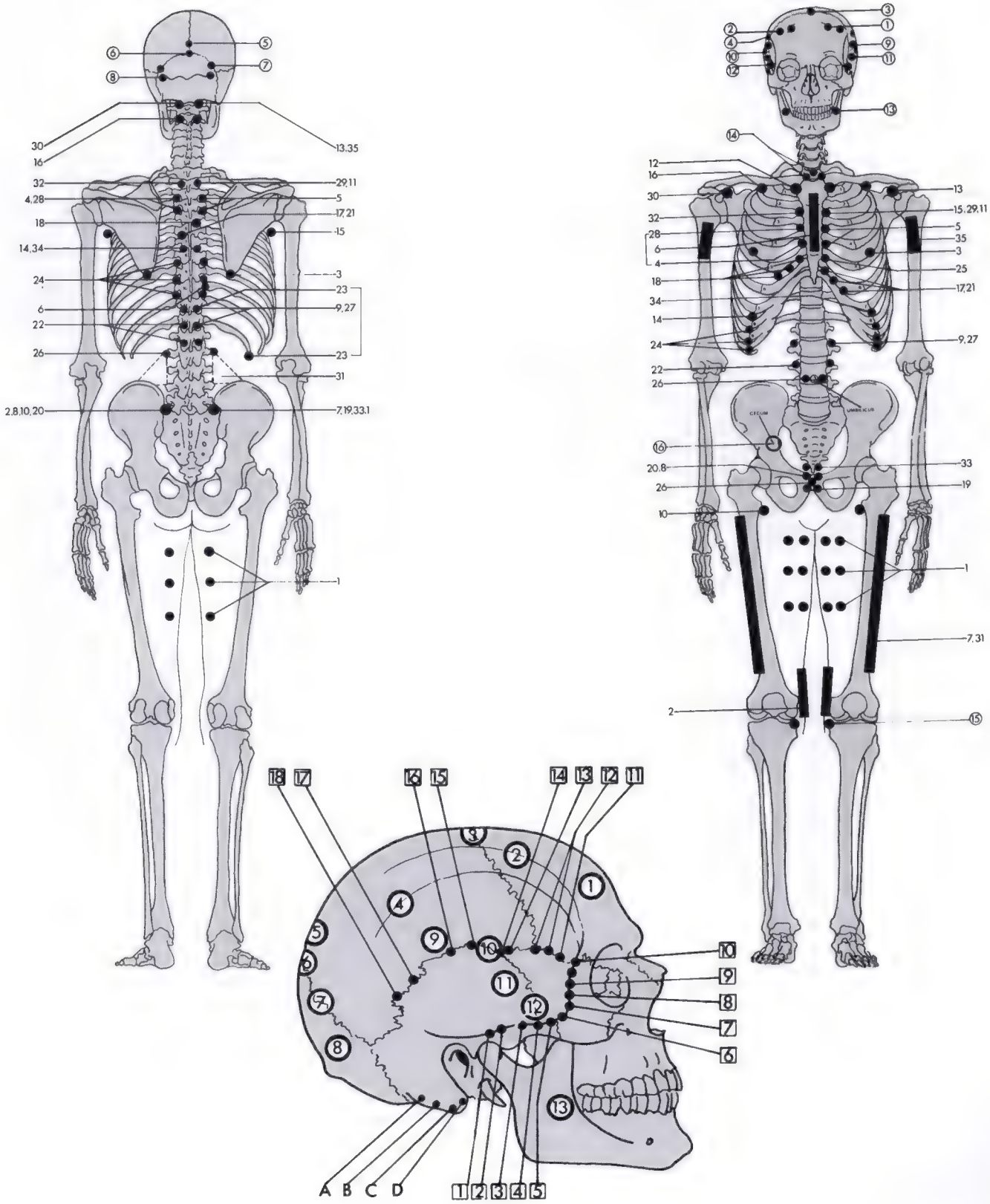
6
5
8
7
30
16
13,35
32
29,11
4,28
5
18
17,21
15
14,34
3
24
23
6
9,27
22
26
23
31
2,8,10,20
7,19,33,1
1
3
2
1
4
9
10
11
12
13
14
12
16
13
30
15,29,11
32
5
28
35
6
3
4
25
18
17,21
34
14
24
9,27
22
26
16
33
20,8
26
19
10
1
7,31
2
15
18 17 16 15 14 13 12 11
10
9
8
7
6
A B C D
1 2 3 4 5

# CHAPTER II

## INTRODUCTION TO ACU-THERAPY

The philosophy of the ancient science known as acupuncture parallels the philosophy of Chiropractic in many ways. Both sciences treat the total person through energy re-balancing, nutrition, etc. They also feel that prevention of disease should be their primary goal, they avoid palliative and symptom-suppressive treatments, and believe in dealing directly with the cause of the patient's illness. These are only a few of the most obvious likenesses between the two philosophies. I am sure that many more parallels could be drawn.

Even though the philosophies of acupuncture and Chiropractic parallel one another in many ways, the actual practice of these sciences have many significant differences. I am a resident of Nevada which was the first state to license acupuncturists. I have witnessed the mass migration of patients to Nevada from all over the country, seeking the services of acupuncturists. However, after only eighteen months of practice, many acupuncturists have had to close their doors because of a lack of patients. We know there is no depression on sickness and disease. Why, then, in less than two years have so many people who were eagerly seeking the services of an acupuncturist changed their minds? The answer is simple. The meridians will show energy imbalances in almost all diseases. However, this may be an indirect result (or side effect) of the actual cause of the problem. In other words, if a patient is not an acupuncture patient (because the basic underlying cause is not an imbalanced meridian), then acupuncture will not correct that particular patient's illness. Now and then, we hear of "miracle cures" being attributed to acupuncture. These occasional "miracle cures" may occur when the patient's basic problem is a meridian involvement Unfortunately, when the acupuncturist reads the pulses or uses his electrical machines, he cannot tell whether the imbalanced meridian is the basic cause of the problem or the mirror image reflection of another basic cause.

Armed with the knowledge from the contributions which Dr. Goodheart has made to the ancient science of acupuncture, we have definite advantages over the acupuncturists. For years the backbone of our philosophy has been the spine and the intervertebral foramen and its contents. The intervertebral foramen was thought to contain only four elements. However, in light of the research being performed in the field of Applied Chiropractic Kinesiological Diagnosis and Technique, a fifth element has been added — the Acupuncture Meridian Connector. We now know it is impossible to adjust the spine without affecting the Acupuncture Meridian Connector. This, in turn, affects the corresponding meridian and its interrelationship with other meridians. For every meridian imbalance there is an associated subluxation. Acu-therapy is incomplete without correction of the spine.

Through the miracle of therapy localization, we can now diagnose if a patient is suffering because of an imbalanced meridian. Through muscle testing, we can immediately determine if our correction resulted in a balanced meridian.

The meridian system should be checked routinely in your examination and on subsequent office calls. No specific equipment is needed, and it can be performed fast, efficiently and accurately.

The term Acu-therapy will be used throughout this manual in reference to treatment. Acupuncture is a misleading term, as puncturing the skin is not at all necessary.

# MERIDIANS

Oriental medicine has a basic premise that the life process is activated and maintained by what they call in acupuncture, a "vital force" or "life force" (called Qi). This force is energy derived from our environment, nutrition and respiration, and it is converted into assimilable forms by the body. This energy then circulates through the body by definite pathways called meridians. The functional capacity of the organs, muscles and cells is partially dependent upon this basic form of "life force." Any blockage of a meridian will result in a blockage of energy to the related organ or system, and this can result in disease.

In order to facilitate learning, the meridians have been grouped by similarities as follows:

| MERIDIAN | RULE |
|---|---|
| **HEART, CIRCULATION SEX, LUNG.** | Three meridians start on the thorax and finish on the fingertips, with energy flowing toward the fingers. |
| **SMALL INTESTINE, TRIPLE WARMER, LARGE INTESTINE** | Three meridians start on the fingertips and finish on the face with energy flowing up the arm. |
| **BLADDER, GALLBLADDER, STOMACH.** | Three meridians start on the face and finish on the toes with energy flowing toward the toes. |
| **KIDNEY, LIVER, SPLEEN.** | Three meridians start on the feet and end on the thorax with energy flowing toward the chest. |

Listed below are the fourteen acupuncture meridians. (European Auc-therapists use Roman numerals when referring to the meridians instead of the meridian name.)

**FIG. A-1**

**HEART MERIDIAN, I**

Begins on the trunk at the apex of the axilla, below the border of the first rib. The path goes down the arm and forearm on the inside of the arm and finishes at the root on the little fingernail.

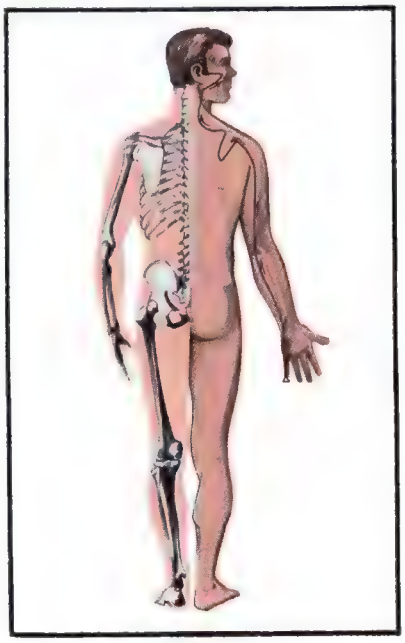

**FIG. A-2**

**SMALL INTESTINE MERIDIAN, II**

Begins on the little finger at the root of the fingernail and travels up the posterior internal aspect of the arm, over the shoulder to the face, just anterior to the tragus.

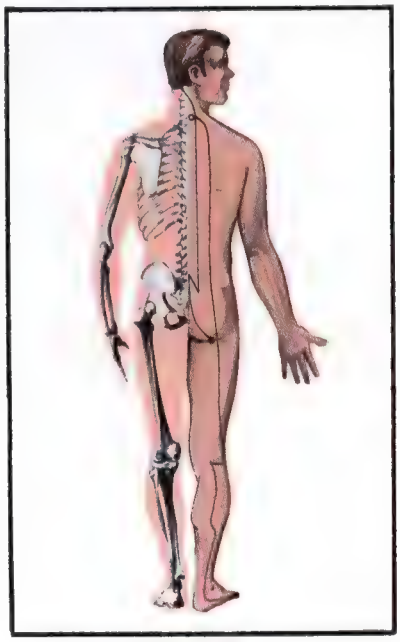

**FIG. A-3**

**BLADDER MERIDIAN, III**

Begins at the inner corner of the eyes and goes over the head, down the back of the neck, back, thighs and legs to end at the root of the nail of the little toe.

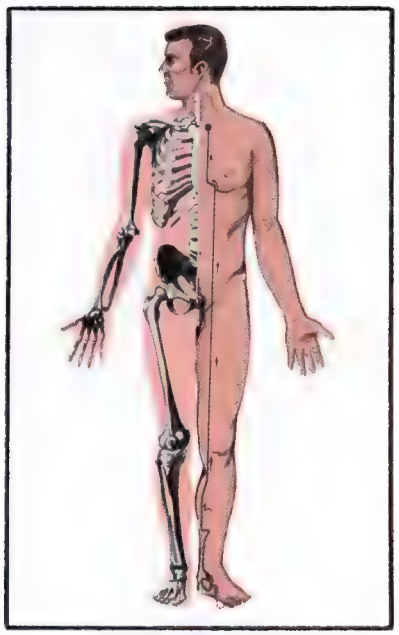

**FIG. A-4**

**KIDNEY MERIDIAN, IV**

Begins on the sole of the foot and goes up the inner aspect of the leg and thigh, up the abdomen and thorax with its last point just below the clavicle, first rib and sternum.

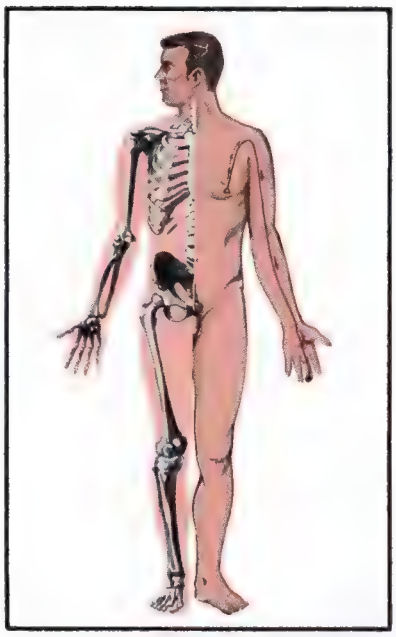

**FIG. A-5**

**CIRCULATION SEX MERIDIAN, V**

Begins lateral to the nipple on the thorax, up to the shoulder and then down the anterior surface of the arm, forearm and over the surface of the palm to end on the root of the nail of the middle finger.

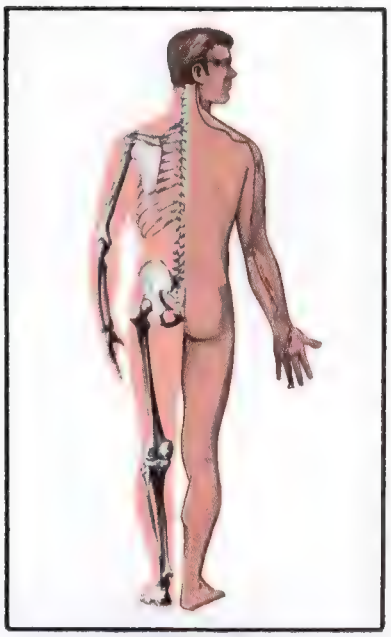

**FIG. A-6**

**TRIPLE WARMER MERIDIAN (THREE HEATER), VI**

Begins at the nail root of the ring finger (little finger side) and goes up the back of the forearm, arm and over the back of the shoulder, around the ear to end near the outer extremity of the eyebrow.

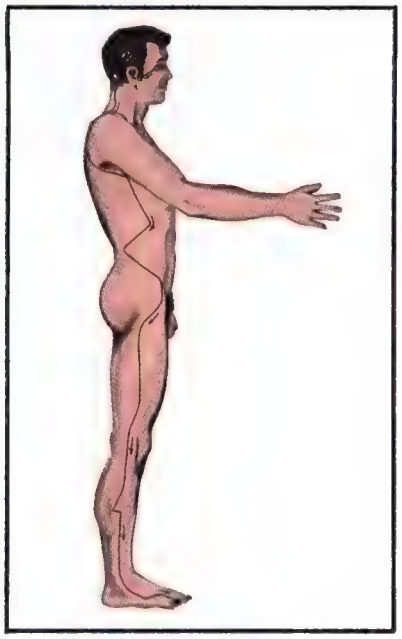

**FIG. A-7**

**GALLBLADDER MERIDIAN, VII**

Begins at the outer corner of the eye, goes back and forth over the skull and down the back of the shoulder, down the side of the thorax, abdomen and outer side of the thigh, leg, foot and ends on the fourth toe (little toe side).

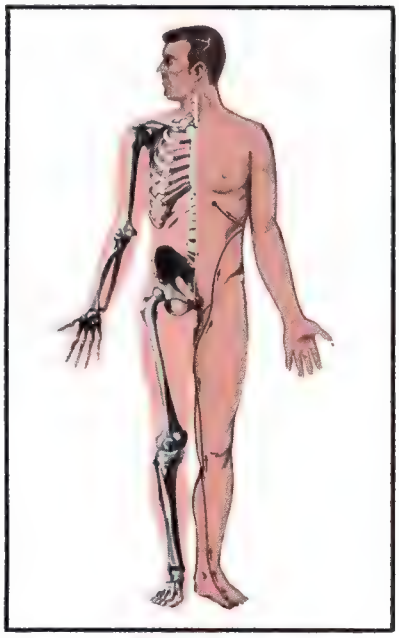

**FIG. A-8**

**LIVER MERIDIAN, VIII**

Begins on the root of the big toenail (second toe side), proceeds up the inner surface of the leg, thigh, up the abdomen to the costal border of the sternum.

**FIG. A-9**

**LUNG MERIDIAN, IX**

Begins in the first intercostal space, proceeds to the shoulder, then goes down the anterior lateral aspect of the arm to end at the root of the thumbnail.

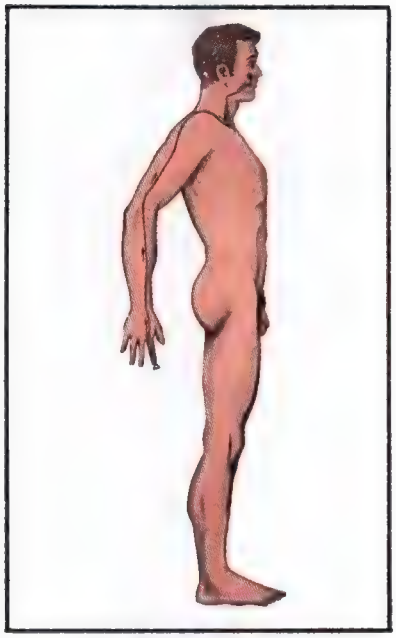

**FIG. A-10**
**LARGE INTESTINE MERIDIAN, X**

Begins at the root of the first fingernail and then proceeds up the postero-lateral aspect of the forearm, arm and over the shoulder and neck to finish at the side of the nose.

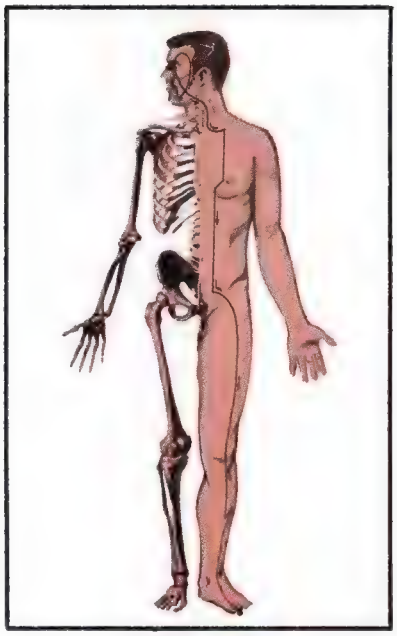

**FIG. A-11**
**STOMACH MERIDIAN, XI**

Begins at the center of lower edge of the ocular orbital cavity and proceeds down the face to the edge of the jaw and then back to the ear and up to the forehead, then down to the throat, the front of the thorax, abdomen, anterior of the thigh, leg and foot to finish at the root of the second toenail.

**FIG. A-12**
**SPLEEN MERIDIAN, XII**

Begins at the root of the big toe and proceeds up the internal aspect of the leg, thigh and up the abdomen, thorax, lateral to the nipple, to the second rib, then down to end at the sixth intercostal space on the axillary line.

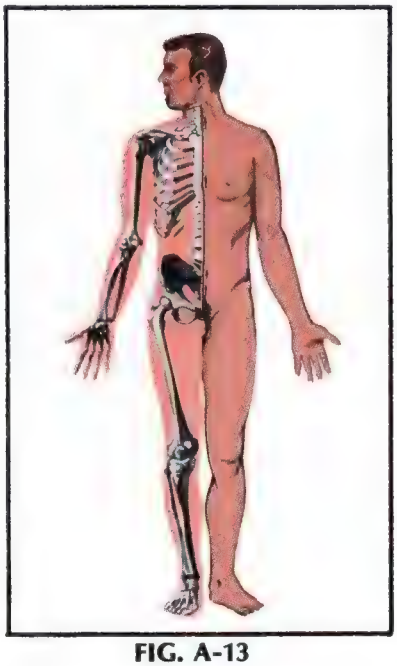

**FIG. A-13**

**CONCEPTION VESSEL**

Begins in the center of the perineum and proceeds up the center of the abdomen, sternum and throat to end on the top of the lower lip.

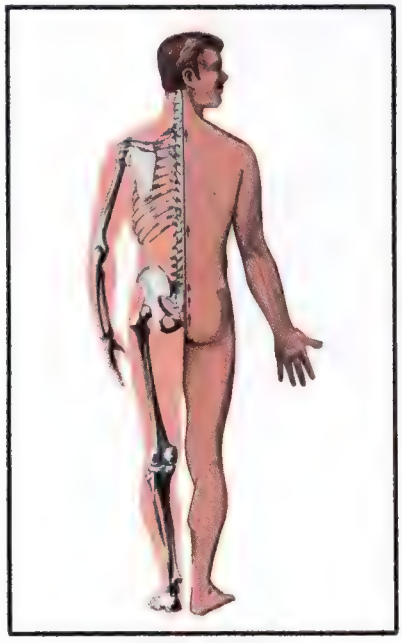

**FIG. A-14**

**GOVERNING VESSEL**

Begins on the tip of the coccyx and then proceeds up the center of the coccyx, sacrum and spine, over the middle of the head, down the middle of the forehead, nose and ends on the top lip.

# MERIDIAN ENERGY FLOW

The following is a chart illustrating the direction which energy flows between the meridians. Also, listed opposite each meridian are the muscles and organs which are associated with that particular meridian.

| MERIDIAN | MUSCLE | ORGAN |
|---|---|---|
| HEART | SUBSCAPULARIS. | HEART |
| SMALL INTESTINE | ABDOMINALS, QUADRICEPS. | SMALL INTESTINE |
| BLADDER | PERONEII OR PERONEUS, ANTERIOR TIBIALIS, SACROSPINALIS. | BLADDER |
| KIDNEY | PSOAS, ILIACUS, UPPER TRAPEZIUS, WRIST EXTENSORS. | KIDNEY, EYES, EARS & ILEO-CECAL VALVE |
| CIRCULATION SEX | GLUTEUS MINIMUS, GLUTEUS MEDIUS, GLUTEUS MAXIMUS, PIRIFORMIS, LEVATOR ANI, GRACILIS, ADDUCTORS, SOLEUS, SARTORIUS, GASTROCNEMIUS. | PERICARDIUM, ADRENAL GLANDS |
| TRIPLE WARMER | TERES MINOR, INFRASPINATUS. | THYROID |
| GALLBLADDER | POPLITEUS. | GALLBLADDER |
| LIVER | PECTORALIS MAJOR STERNAL, POSTERIOR TIBIALIS. | LIVER |
| LUNGS | ANTERIOR SERRATUS, DELTOIDS, CORACOBRACHIALIS. | LUNGS |
| LARGE INTESTINE | TENSOR FASCIA LATA, HAMSTRINGS, QUADRATUS LUMBORUM, FOREARM PRONATORS; i.e., PRONATOR TERES & QUADRATUS. | LARGE INTESTINE |
| STOMACH | PECTORALIS MAJOR CLAVICULAR, PTERYGOIDS, MASSETERS, TEMPORALIS, ANTERIOR & POSTERIOR & LATERAL NECK FLEXORS & EXTENSORS, LEVATOR SCAPULAE, BRACHIORADIALIS, BICEPS BRACHII, RHOMBOIDS. | STOMACH, SINUSES |
| SPLEEN | ANCONEUS, MIDDLE & LOWER TRAPEZIUS LATISSIMUS DORSI, TRICEPS BRACHII. | SPLEEN |

ENERGY FLOW

# YIN AND YANG

Oriental philosophy teaches that harmony in the universe and in nature exists because of the balance of the Yin and Yang. These are not two different forces, nor are they separate, but merely polarities of the "vital force" (called Qi). Both polarities are ideal and antagonistic to one another. In life, neither of these forces can exist in a pure state — there is always some Yin in Yang and some Yang in Yin. Certain states are called Yin because they are made up of a larger percentage of Yin than Yang (and likewise for Yang states). The ancient orientals feel that disease is due to an abnormal excess of Yin or Yang. Yang or Fu is characterized by positive, active state, heat, light and the exterior — the male is considered Yang in nature. Yin or Tsang is characterized by inactivity, cold, darkness, interior and passivity — the female is considered Yin in nature.

The meridians may be grouped according to Yin or Yang, and each Yin meridian is paired with a Yang meridian for balance.

| YIN MERIDIANS | | YANG MERIDIANS | |
|---|---|---|---|
| (I) | Heart | (II) | Small Intestine |
| (IV) | Kidney | (III) | Bladder |
| (V) | Circulation Sex | (VI) | Triple Warmer |
| (VIII) | Liver | (VII) | Gallbladder |
| (IX) | Lungs | (X) | Large Intestine |
| (XII) | Spleen | (XI) | Stomach |

Changes in energy polarity from Yin to Yang or vice versa occur as the energy passes between two coupled meridians. This change takes place at the end of the limbs or extremities.

Yang organs are concerned with nutritional assimilation and excretion and are considered hollow organs. Yin organs are concerned with storage and distribution of assimilated energy and are considered solid organs.

In the human body, the back is Yang and the front is considered Yin.

One must remember that Yin and Yang are polarities of one force and are ever changing. However, the following states are relatively constant:

| YANG | YIN |
|---|---|
| DAY | NIGHT |
| SOUTH | NORTH |
| EAST | WEST |
| UPPER | LOWER |
| HOT | COLD |
| FIRE | WATER |
| MALE | FEMALE |
| BODY OUTER SURFACE | BODY INTERIOR |
| BODY ENERGY | BLOOD |
| ACUTE DISEASE | CHRONIC DISEASE |
| BODY FEVER | SUBNORMAL BODY TEMPERATURE |

## THE FIVE ELEMENTS

Chinese tradition teaches that everything in the world can be related back to the basic Five Elements. The Five Elements should be learned in order, as they are fundamental to the understanding of Acu-therapy. They are as follows:

**WOOD**

**FIRE**

**EARTH**

**METAL**

**WATER**

## THE CREATION CYCLE

After learning the Five Elements, if one employs a little imagination, the Creation Cycle can be easily understood. The Creation Cycle gives rise to what is known as the Mother-Son Law or Cycle of Engenders.

**FIRE IS THE MOTHER OF EARTH AND FIRE IS THE SON OF WOOD**
**EARTH IS THE MOTHER OF METAL AND EARTH IS THE SON OF FIRE**
**METAL IS THE MOTHER OF WATER AND METAL IS THE SON OF EARTH**
**WATER IS THE MOTHER OF WOOD AND WATER IS THE SON OF METAL**
**WOOD IS THE MOTHER OF FIRE AND WOOD IS THE SON OF WATER**

(See FIG. A-16.)

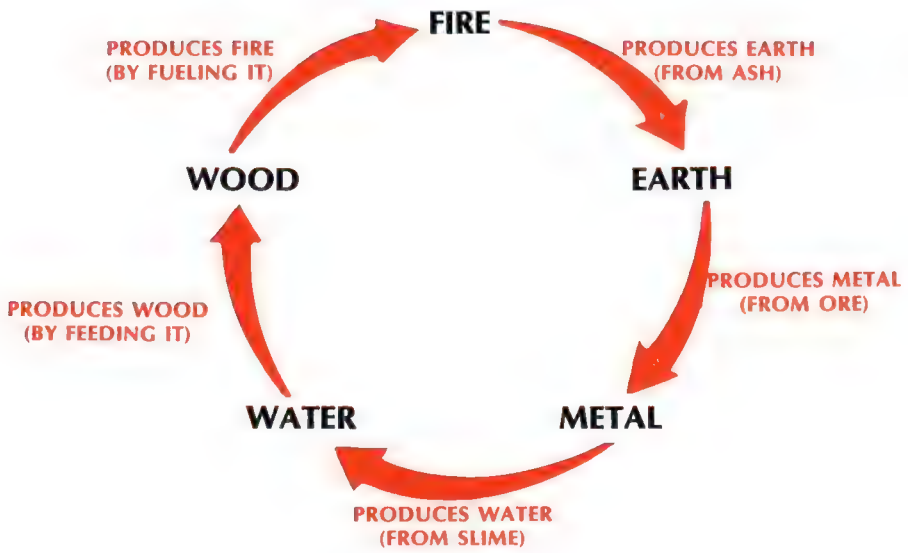


**FIG. A-16**

## KO OR DESTRUCTION CYCLE

This Cycle is also referred to as the Subdue Cycle, Subjugate Cycle or Control Cycle.

**FIRE OVERCOMES METAL (BY MELTING IT)**
**METAL OVERCOMES WOOD (BY CUTTING IT)**
**WOOD OVERCOMES EARTH (BY COVERING IT)**
**EARTH OVERCOMES WATER (BY DAMMING IT)**
**WATER OVERCOMES FIRE (BY EXTINGUISHING IT)**

(See FIG. A-17.)

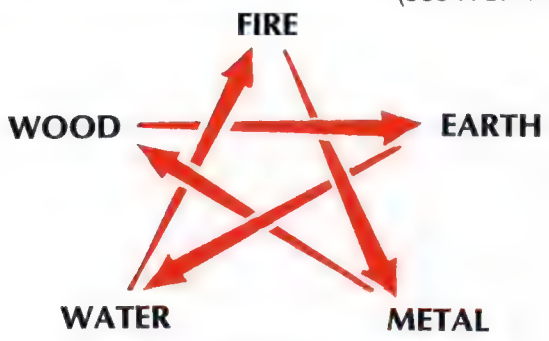


**FIG. A-17**

## BASIC ACTION OF THE KO CYCLE

**EXCESS ENERGY IN THE KIDNEYS CAUSES WEAK HEART**
**EXCESS ENERGY IN THE SPLEEN CAUSES WEAK KIDNEYS**
**EXCESS ENERGY IN THE LUNGS CAUSES WEAK LIVER**
**EXCESS ENERGY IN THE HEART CAUSES WEAK LUNGS**
**EXCESS ENERGY IN THE LIVER CAUSES WEAK SPLEEN**

(There is no circulating process in these relationships, e.g., increased energy in the Kidneys causes weakening of the Heart only. There is no repercussion on the other organs.) (See FIG. A-18.)

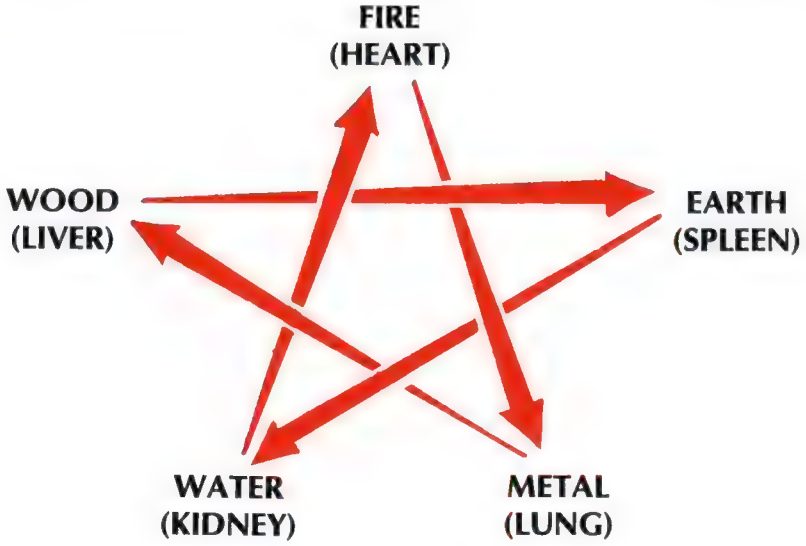


**FIG. A-18**

The Ko Cycle is complex because of the possibility of the interaction of Yin and Yang. According to Oriental tradition, the Yin subjects the Yang and the Yang subjects the Yin in the Ko Cycle. For example, the Kidneys (Water) are subject to Earth, but you cannot assume that the organ which dominates the kidneys is either the stomach or the spleen as indicated by the diagram below because the stomach (Yang) subjects the kidneys (Yin), and, inversely, the kidneys (Yin) subject the bladder (Yang) (FIG. A-19). From this, it is easy to see how Acu-therapy can become very confusing. Many factors must be known relative to the interaction of Yin and Yang. For example, is the disorder a Yin or a Yang condition? Is the patient being treated in Yin or Yang time? Where is the involved organ in relation to Midday and Midnight Law, just to name a few of the points one would have to consider. However, by using the research which is being revealed in this text, and the principles of the Five Elements on page 76, in addition to the portion of this chapter entitled "Practical Use of Acu-therapy," the reader will have a good working knowledge of Acu-therapy in addition to being able to apply the material immediately.

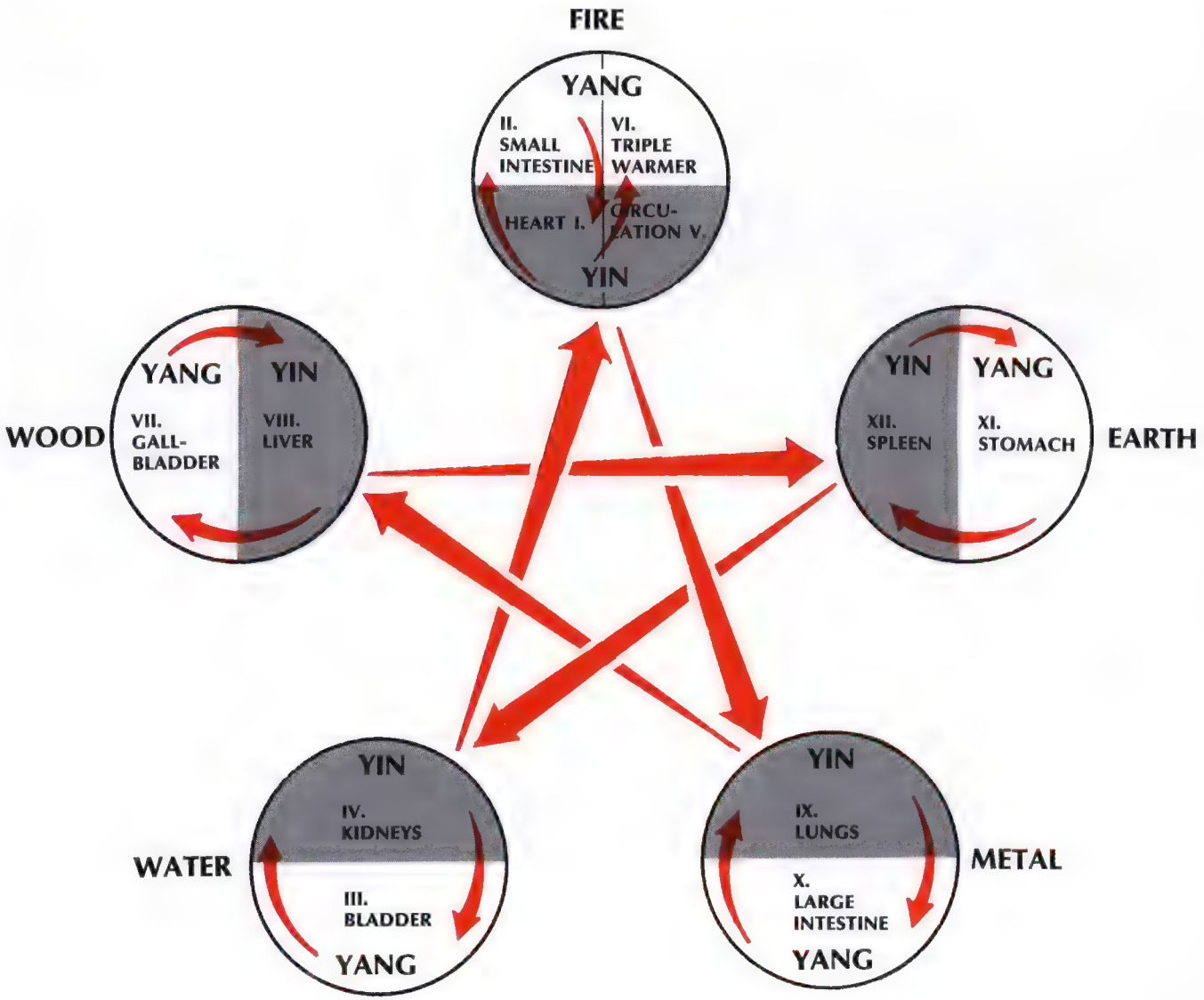


FIG. A-19

## EMOTIONS AND THE FIVE ELEMENTS

Each element has an associated emotion or temperament in intimate connection with its organ. Each element also has an associated sound which is related to the emotion and organ; e.g., Wood-shout, Fire-laugh, Earth-sing, Metal-weep, Water-groan (FIG. A-20).

**FIG. A-20**

The Ko Cycle and Creation Cycle also apply to the emotions. For example, in the Ko Cycle, sympathy overcomes fear, fear overcomes joy, joy overcomes grief, etc. In the Creation Cycle, excess sympathy produces grief, excess grief produces fear, excess fear produces anger, etc.

Anger can be harmful to the liver and gallbladder.
Extravagant joy can be injurious to the heart, small intestine, adrenals and thyroid.
Extreme sympathy (worry) is injurious to the stomach and spleen.
Extreme grief is injurious to the lungs and large intestine.
Extreme fear is injurious to the kidneys and bladder.

These emotions and sounds may be utilized as diagnostic tools. For example, excessive laughter would indicate an overly strong Heart, someone who cries excessively could have Lung problems, etc.

## CREATION AND DESTRUCTION CYCLE TOGETHER

### PRINCIPLES OF THE FIVE ELEMENTS

(Refer to FIG. A-21.)

1) Yang or Fu are outside the large circle and are associated with digestion and elimination of waste, which is an intermittent function. These organs are called hollow organs.
2) Yin or Tsang organs are inside the large circle and their function is continual. They are called solid organs.
3) The Yin and the Yang organs are joined together by the conjunctive vessels and are influenced by appropriate action at points on the meridian called the Command Points.
4) The arrows between the organs indicate the energy flow between the organs themselves (deep and internal), NOT the superficial external energy of the meridians.
5) Excess energy always flows in the direction of the arrows and deficiencies travel (pull) in the opposite direction.
6) The essence of the use of the Five Element Law is one of transfer from excess to deficiency of the inner energy relationships.

7) This method is primarily used when there is an excess of energy of one or more organs and, at the same time, a deficiency of one or more organs.

8) The two energy circulations can be influenced through action on the meridians at the points called the Command Points.

9) Connecting Points are used when we are rebalancing between different elements or drawing energy across the large circle, or from inside the circle to an element outside the circle that has the same related element, or from outside the circle to inside the circle on the meridian of the same element toward the organ.

10) Always act on the deficient meridian of the organ by supplying, supplementing or drawing excess energy.

11) The Command Point is the point on the meridian that has direct linkage to the meridian organ's energy. The Command Point on all Yin meridians coincide with the Earth Point. On Yang meridians, the Command Point is a separate point.

12) Internal (Yin) external (Yang) and/or external/external (Yang) imbalances cannot be balanced by external (Yang) organs alone. Command Points must be used by acting on the Connecting Points to draw energy across the line.

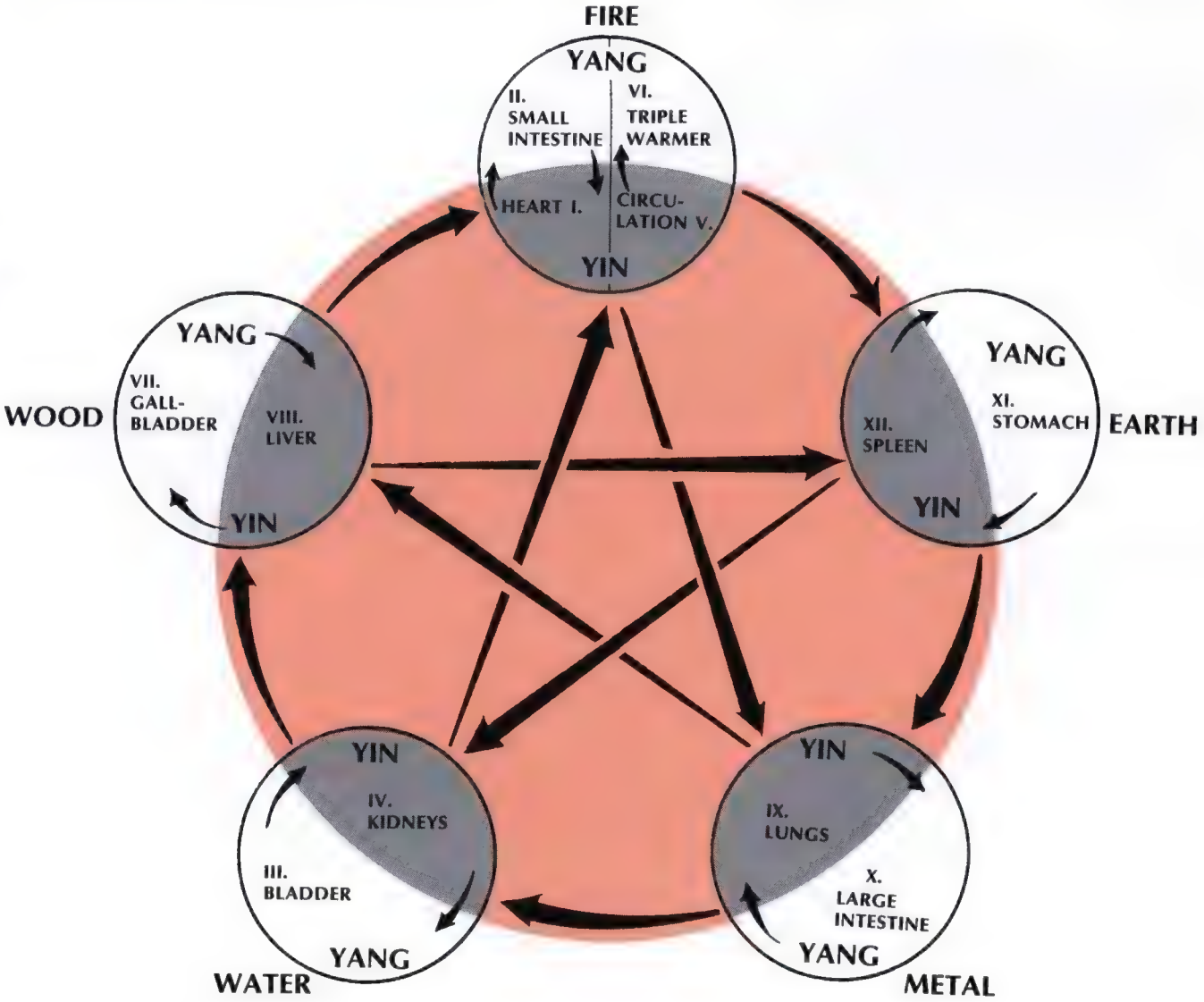


FIG. A-21

# LAWS OF ACU-THERAPY

## MOTHER-SON LAW

It is a Chinese Law that, "If a meridian is empty, tonify its mother. If it is full, disperse the child." This Law primarily relates to superficial energy. The Mother gives her energy to the Son; thus, if the Son is deficient, treat the Mother. For example, tonification of the Lungs (Mother) produces tonification of the Large Intestine (Son), with secondary effects of tonification of the preceding meridian (Liver). (See FIG. A-15.) If the Mother, on the other hand, is sedated, the Son meridian is sedated, with secondary effects of sedation of the preceding meridian.

Application of this Law may be used in your practice as follows. If you have a patient with a weak tensor fascia lata (based upon T.S. Line palpation, postural analysis and kinesiological examination), you would then seek the cause. If you found that therapy localization over the muscle was negative, therapy localization over the neurolymphatics and neurovasculars was negative, subluxation and/or fixation was negative and the patient was also nutritionally negative, you could therapy localize the pulses or the Alarm Points. Upon getting a positive finding for the Large Intestine meridian (Son), which is directly related to the tensor fascia lata, and seeing that there were no other energy blockages, you could then tonify the Lung meridian (Mother). This, in turn, would tonify the tensor fascia lata, the preceding meridian (Liver meridian), and also the associated muscles (pectoralis major sternal) (FIG. A-15).

## PULSES—HUSBAND-WIFE LAW (Law of Endanger)

It is a Chinese Law that, "Weak 'husband,' strong 'wife'; then there is destruction. Strong 'husband,' weak 'wife,' then there is security." The Law deals basically with the left wrist pulse (husband and Yang) and the right wrist pulse (wife and Yin) relationship. The left and right sides of the Five Element diagram coincide with the left and right hand pulses. The superficial pulses are represented outside of the large circle and the deep pulses are inside the circle. (See FIG. A-5.)

| LEFT WRIST—HUSBAND & YANG | RIGHT WRIST—WIFE & YIN |
|---|---|
| SMALL INTESTINE DOMINATES THE LARGE INTESTINE. | LARGE INTESTINE ENDANGERS THE SMALL INTESTINE. |
| HEART DOMINATES THE LUNGS. | LUNGS ENDANGER THE HEART. |
| GALLBLADDER DOMINATES THE STOMACH. | STOMACH ENDANGERS THE GALLBLADDER. |
| LIVER DOMINATES THE SPLEEN. | SPLEEN ENDANGERS THE LIVER. |
| BLADDER DOMINATES THE TRIPLE WARMER. | TRIPLE WARMER ENDANGERS THE BLADDER. |
| KIDNEYS DOMINATE THE CIRCULATION SEX. | CIRCULATION SEX ENDANGERS THE KIDNEYS. |

This Law deals basically with the balance between the pulses on the wrists. As you will note in FIG. A-22, there are six pulses located on each wrist. The three superficial pulses are felt by lightly placing the index finger, middle finger and ring finger over these points. The deep pulses are felt by placing these same fingers over these points, exerting slightly more pressure.

An example of the application of this Law is as follows:

> If the first superficial pulse point (Small Intestine) on the left wrist is stronger than the first superficial pulse point (Large Intestine) on the right wrist, this means that the Small Intestine is dominating the Large Intestine. If the first superficial pulse point (Large Intestine) on the right wrist is stronger than the first superficial pulse point (Small Intestine) on the left wrist, then the Large Intestine is endangering the action of the Small Intestine.

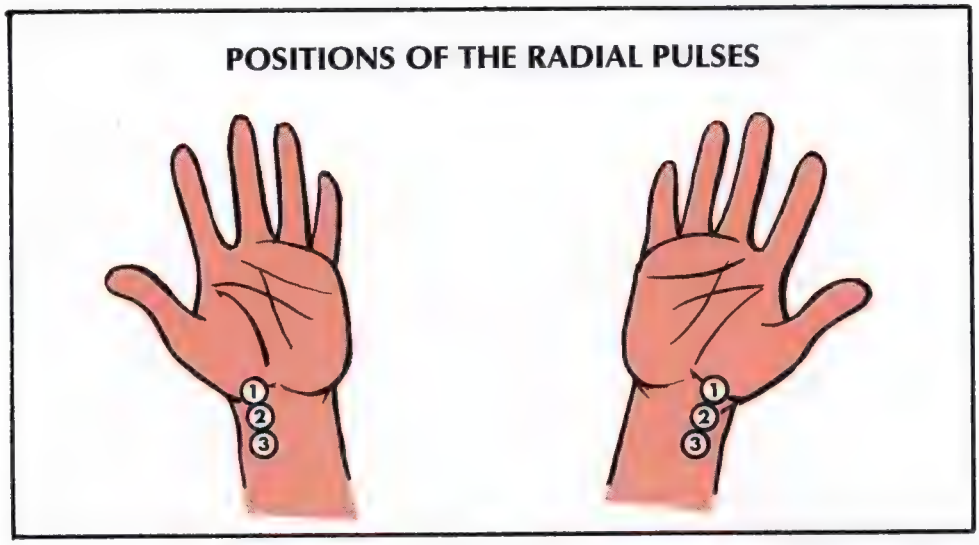


FIG. A-22

| LEFT HAND | | | RIGHT HAND | |
|---|---|---|---|---|
| **Superficial** | **Deep** | **POSITIONS** | **Deep** | **Superficial** |
| Small Intestine | Heart | 1st | Lung | Large Intestine |
| Gallbladder | Liver | 2nd | Spleen | Stomach |
| Bladder | Kidney | 3rd | Circulation Sex | Triple Warmer |

## THERAPY LOCALIZING THE PULSES

Have the patient place his finger on the first pulse point on either wrist and test a convenient muscle. If the muscle tests negative, then check the second pulse point and finally, the third pulse point. If therapy localization of all the pulse points are negative on that side, it is safe to assume the meridian system on that side is intact. Then, have the patient therapy localize the pulses on the opposite wrist in the same manner. If point one on the right wrist is therapy localized and the muscle tested "blows,"* proceed to test points 2 and 3 to make sure the meridians associated with these points are not also involved. The fact that the muscle blew when you tested point 1 does not tell you which meridian is out of balance. Test the muscles associated with point 1 and this will give you an idea if the meridian is underactive or overactive. Then you must therapy localize the Alarm Points associated with the deep and superficial pulses on point 1. Once this has been performed, you can proceed to make your correction. In order to make sure your correction is effective, retherapy localize the pulse point to see if it tests negative.

Therapy localization of the pulses for the Conception Vessel and the Governing Vessel are located distal to the Pulse Point 1 toward the thumb. However, once again, if the tested muscle blows, one must then therapy localize the Alarm Points for each of these meridians to determine which one needs attention.

It is important to keep in mind that if therapy localization of the pulse blows the muscle, it does not mean that only Acu-therapy is indicated. It is possible that any one of the five elements of the intervertebral foramen may be involved. The most expedient method of determining this is through therapy localization.

*"Blows" means the muscle becomes spontaneously weak.

## MIDDAY-MIDNIGHT LAW

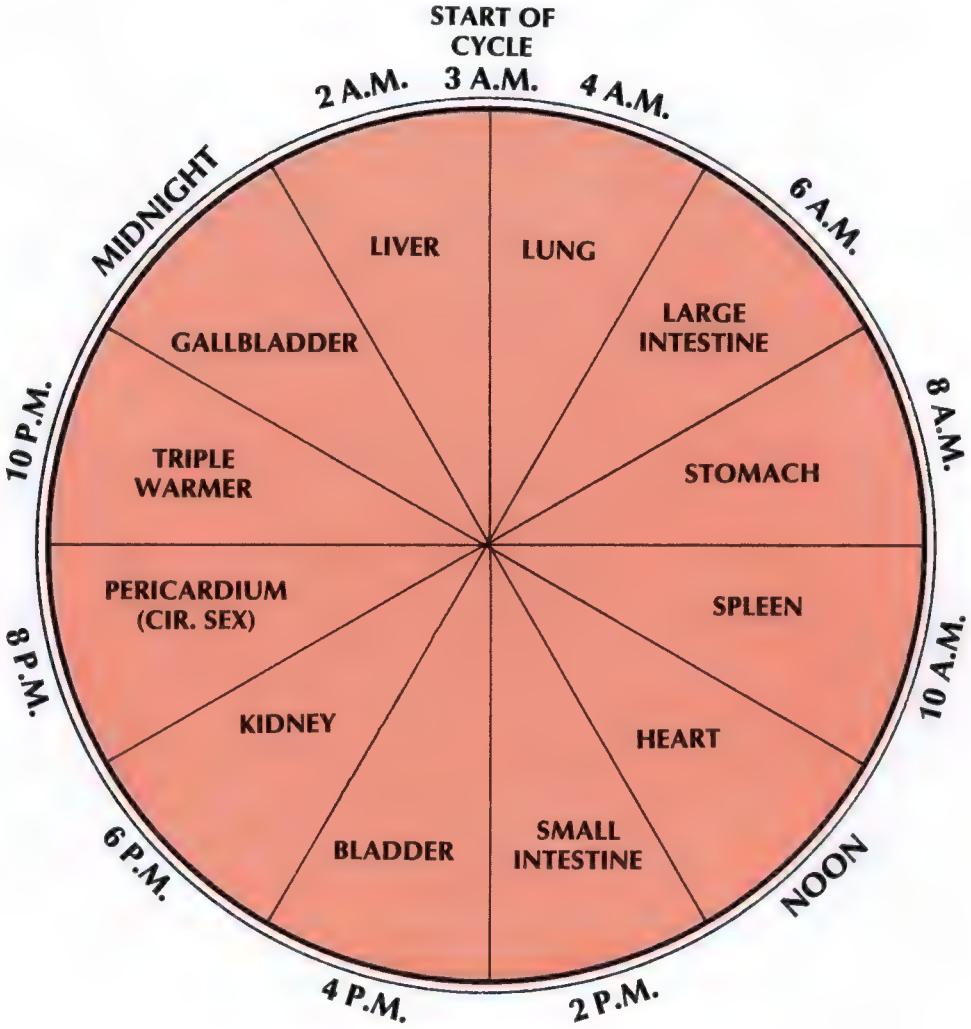


FIG. A-23

Energy flows through the 12 meridians, over a period of 24 hours. The Law states that there is a relationship between organs which receive their maximum flow at opposite times. The heart receives its maximum energy flow at Noon, the gallbladder receives its minimal energy flow at the same time. Likewise, at Midnight the gallbladder receives its maximum energy, and the heart receives its minimal energy flow at that time. Application of the Law is as follows: If an organ is moderately stimulated, only the organ itself is affected. However, if the same organ is stimulated strongly, the organ which is opposite it on the above chart receives the reverse effect. In other words it will cause it to be sedated.

The Law can be more effective if Yin organ is stimulated at Yin time — Noon to Midnight; or if Yang organ is stimulated at Yang time — Midnight to Noon.

If a patient has a recurring pain or problem daily at the same time of day, check the Midday-Midnight clock, as it can give you an excellent clue to where the problem might exist.

# CATEGORIES OF MERIDIAN POINTS

## ALARM POINTS

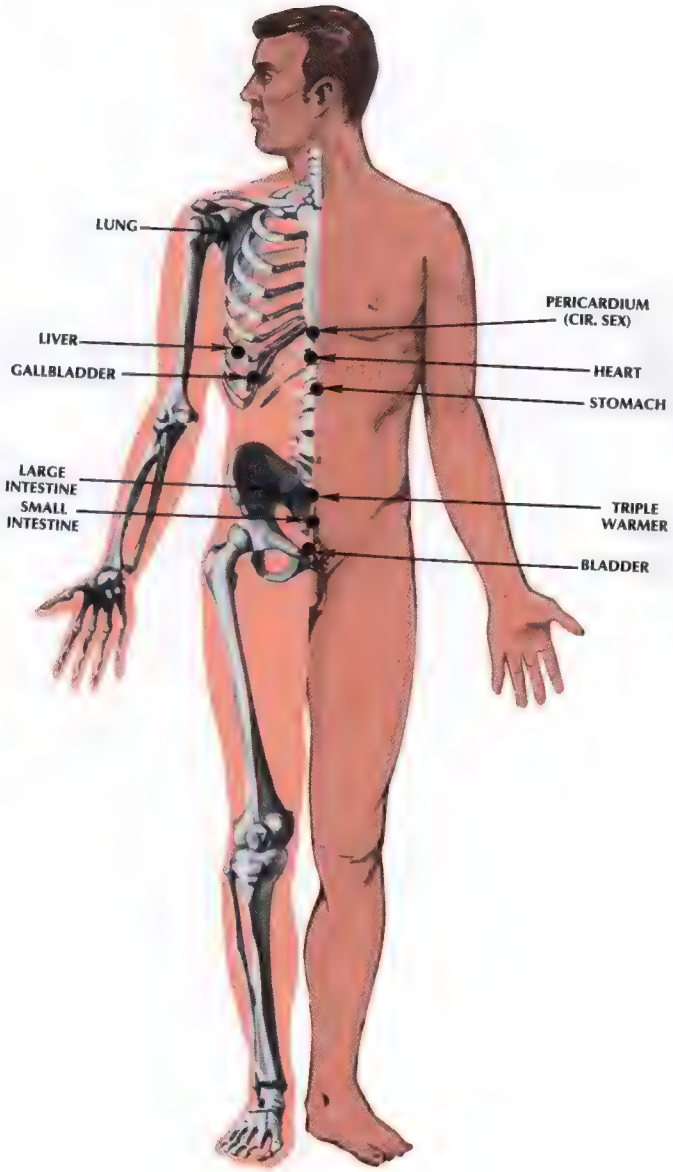


FIG. A-24

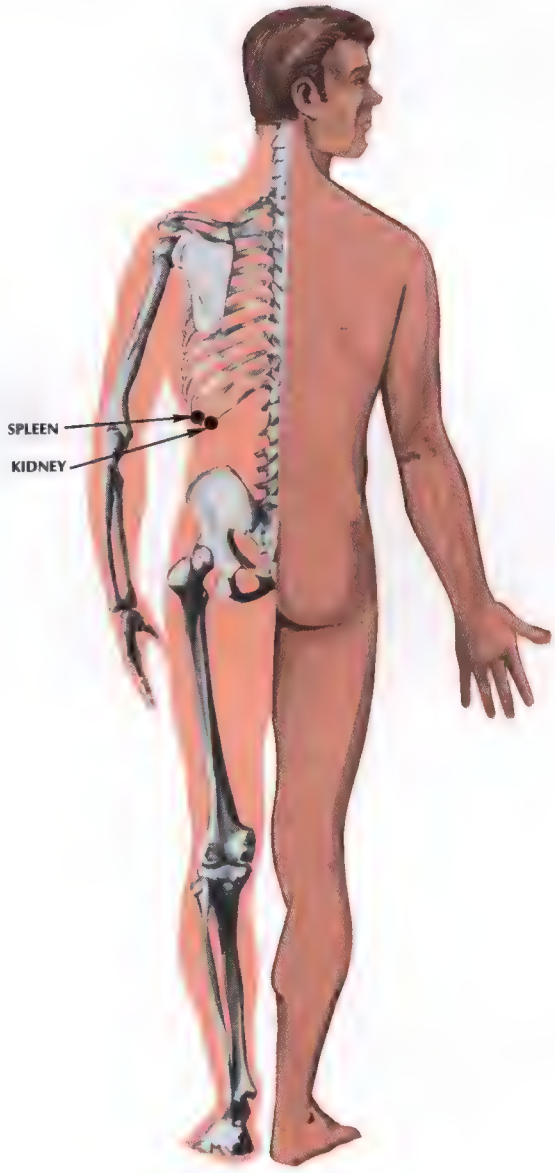


FIG. A-25

These are a series of points found on meridians on the anterior and lateral surfaces of the body. The majority of these points are found on the Conception Vessel. According to Chinese tradition, they are associated with Yin disease. It was also believed that if disease occurred in the internal organ, the Alarm Point related to that organ would become spontaneously tender. Upon palpating the Alarm Points, they were believed to be more tender than the adjacent tissue.

Alan Beardall, D.C., Jack Rarey, D.C. and Orvil Ladd, D.C. found that if they challenged an Alarm Point and it was deficient, it would result in blowing out the associated muscle. Their method of challenge was a sharp thrust over the Alarm Point. They would then follow the clock (energy flow) counterclockwise by challenging each Alarm Point, and if it was deficient, it would also result in blowing out its associated muscle. When they challenged the Alarm Point where the energy was blocked (excessive), the associated muscle would not blow. Then, they would stimulate the Connecting Point for approximately 20 seconds and begin retesting the muscles and rechallenging

the Alarm Points in a clockwise direction to verify correction. This method can be practiced today. However, therapy localization on the Alarm Points is preferred and is performed by placing the patient's hands over the Alarm Point in question and retesting an intact indicator muscle. If the Alarm Point is deficient, it will result in blowing out the associated muscle.

One must remember that the Alarm Point challenge may show bilateral or unilateral energy blockage. For example, challenging the Kidney meridian may show a blow out of a muscle (psoas) on the same side, but when it is challenged on the opposite side, the muscle (psoas) on that side may remain strong. It is possible to have energy blocked at the Stomach on one side and the Liver on the opposite side. Soft tissue manipulation at the appropriate points on the meridian will start the energy flow.

| ORGAN | POINTS OF TONIFICATION | | | |
|---|---|---|---|---|
| | FIRST | | SECOND | |
| LUNGS | L9 | Sp3 | L10 | H8 |
| KIDNEY | K7 | L8 | K5 | Sp3 |
| LIVER | Liv8 | K10 | Liv4 | L8 |
| HEART | H9 | Liv1 | H3 | K10 |
| SPLEEN | Sp2 | H8 | Sp1 | Liv1 |
| LARGE INTESTINE | Li11 | S36 | Li5 | Si5 |
| BLADDER | B67 | Li1 | B54 | S36 |
| GALLBLADDER | G43 | B66 | G44 | Li1 |
| SMALL INTESTINE | Si3 | G41 | Si2 | B66 |
| STOMACH | S41 | Si5 | S43 | G41 |
| CIRCULATION SEX | Cx9 | Liv1 | Cx3 | K10 |
| TRIPLE WARMER | T3 | G41 | T2 | B66 |

**FIG. A-26**

## POINTS OF TONIFICATION

These points on the meridian, if stimulated, will result in tonification of the meridian and its organ. Tonification is brought about by contacting the appropriate four points. (See FIG. A-26.) A deep, soft-tissue manipulating pressure over two of these four points simultaneously (for approximately 15 seconds) will bring about tonification. There are four points of tonification listed because when a meridian is deficient, it is often necessary to manipulate the second set of points if the first two points are ineffective. Frequently, the first two points are adequate. When using a needle, usually only the first point is necessary. The points to contact for tonification are listed in FIG. A-26 below and are also illustrated in Chapter 4. If one therapy localizes a point of tonification, it will result in the indicator muscle becoming strong. Therefore, if one questions the actual location of the point, therapy localization may be used for verification. Naturally, the contact must be held on the point of tonification while the indicator muscle is being tested.

Tonification of a meridian will produce secondary effects. The Husband-Wife Law goes into effect as follows: If the Heart is tonified, the Lung is sedated (this only occurs if the Lung (wife) is in excess (see Husband-Wife Law). If one strongly tonifies a meridian during its peak energy time, the Midday-Midnight Law will also go into effect. For example, if one strongly tonifies the Heart, it will produce sedation of the Gallbladder.

| ORGAN | POINTS OF SEDATION | | | |
|---|---|---|---|---|
| | FIRST | | SECOND | |
| LUNGS | L5 | K10 | L10 | H8 |
| KIDNEY | K1 | Liv1 | K5 | Sp3 |
| LIVER | Liv2 | H8 | Liv4 | L8 |
| HEART | H7 | Sp3 | H3 | K10 |
| SPLEEN | Sp5 | L8 | Sp1 | Liv1 |
| LARGE INTESTINE | Li2 | B66 | Li5 | Si5 |
| BLADDER | B65 | G41 | B54 | S36 |
| GALLBLADDER | G38 | Si5 | G44 | Li1 |
| SMALL INTESTINE | Si8 | S36 | Si2 | B66 |
| STOMACH | S45 | Li1 | S43 | G41 |
| CIRCULATION SEX | Cx7 | Sp3 | Cx3 | K10 |
| TRIPLE WARMER | T10 | S36 | T2 | B66 |

**FIG. A-27**

## POINTS OF SEDATION

Each meridian also has Points of Sedation. Sedation is brought about by the doctor placing each hand directly over the two points simultaneously for approximately 10 seconds. As in tonification, there are four points listed for sedation. (See FIG. A-27.) Four points are given because if the muscle or meridian is hypertonic, all four of these points may need to be utilized. Usually, only the first two points are needed, and if a needle is used, only the first point is necessary. If one therapy localizes a point of sedation, it will result in the indicator muscle becoming weak. Therefore, if one questions the actual location of the point, therapy localization may be used for verification. The contact must be held on the point of sedation while the indicator muscle is being tested.

Sedation of a meridian can produce secondary effects. Sedation of the small intestine meridian can cause the Husband-Wife Law to go into effect and results in tonification of the large intestine. These secondary effects are more theoretical and not frequently observed in actual practice. However, occasionally they do occur if over-stimulated at a peak energy time. For example, according to the Midday-Midnight Law, if the Sedation Points on the Small Intestine are stimulated at a peak energy time for that organ, it will result in the Liver being tonified.

# CONNECTING POINTS

These Points are on secondary meridians which connect coupled meridians. Coupled meridians follow one another in the superficial circulation of energy, but one is Yin, located on the anterior surface of the body, legs or arms, and the other is Yang, which is found on the posterior surface of the body, legs or arms.

If there is a deficient Liver meridian (pectoralis major sternal is weak) and excess energy in the Gallbladder meridian (popliteus hypertonus), the Liver meridian may be tonified at its Connecting Point or the Gallbladder may also be sedated at its Connecting Point. However, only one Point needs to be treated between the imbalanced coupled meridians.

The Connecting Points are also known as Luo Points, Coupled Points or Passage Points. (See FIG. A-28 and A-29 for the Connecting Points and the Coupled meridians):

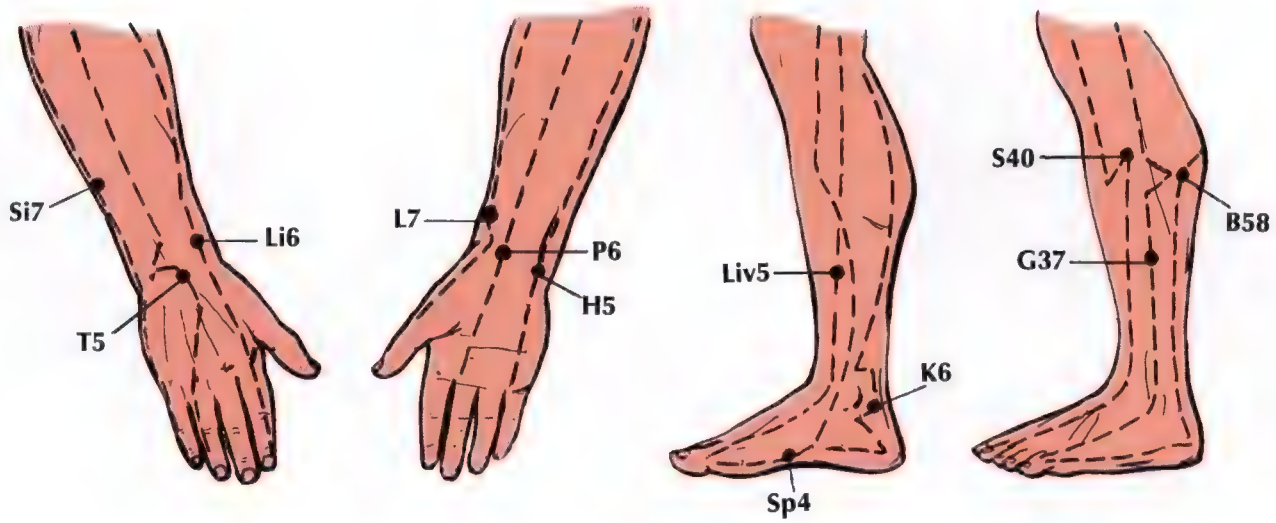


**FIG. A-28**

**B** - Bladder
**G** - Gallbladder
**H** - Heart
**Li** - Large Intestine
**Liv** - Liver
**L** - Lungs
or { **P** - Pericardium / **Cx** - Circulation Sex
**Si** - Small Intestine
**Sp** - Spleen
**S** - Stomach
**T** - Triple Warmer

| | | | |
|---|---|---|---|
| **COUPLED MERIDIANS** | LUNGS | **YIN** | POINT L7 |
| | LARGE INTESTINE | **YANG** | POINT Li6 |
| **COUPLED MERIDIANS** | STOMACH | **YANG** | POINT S40 |
| | SPLEEN | **YIN** | POINT Sp4 |
| **COUPLED MERIDIANS** | HEART | **YIN** | POINT H5 |
| | SMALL INTESTINE | **YANG** | POINT Si7 |
| **COUPLED MERIDIANS** | BLADDER | **YANG** | POINT B58 |
| | KIDNEY | **YIN** | POINT K6 |
| **COUPLED MERIDIANS** | PERICARDIUM | **YIN** | POINT P6 |
| | TRIPLE WARMER | **YANG** | POINT T5 |
| **COUPLED MERIDIANS** | GALLBLADDER | **YANG** | POINT G37 |
| | LIVER | **YIN** | POINT Liv5 |

**FIG. A-29**

# COMMAND POINTS

Command Points are also known as Source Points, Organ Points, Control Points, Prime Mover Points, Regulator Points or Element Points.

These are points found on the meridian which, according to tradition, have a direct link to the actual organ with which the meridian is associated. These points can be used either by themselves or in conjunction with other points on the meridian.

Treatment on these points tends to re-balance the energy in the meridian, whether it is overactive or underactive. However, if this point is stimulated following tonification or sedation, it will accentuate these effects. Stimulation of the Command Points is brought about by soft-tissue manipulation of the skin (for approximately 10 seconds).

Stimulation of these points will bring about an indirect effect of the Husband-Wife Law and the Midday-Midnight Law.

All Yin meridians have their Command Point at the same site as the Earth Point. Yang meridians have a specific point for the Command Point. (See FIG. A-30.)

## COMMAND POINTS

| MERIDIAN | WOOD POINT | FIRE POINT | EARTH POINT | METAL POINT | WATER POINT | COMMAND POINT |
|---|---|---|---|---|---|---|
| (I) HEART | .9 | .8 | .7 | .4 | .3 | .7 |
| (II) SMALL INTESTINE | .3 | .5 | .8 | .1 | .2 | .4 |
| (III) BLADDER | .65 | .60 | .54 | .67 | .66 | .64 |
| (IV) KIDNEYS | .1 | .2 | .3 | .7 | .10 | .3 |
| (V) CIRCULATION | .9 | .8 | .7 | .5 | .3 | .7 |
| (VI) THREE-HEATER | .3 | .6 | .10 | .1 | .2 | .4 |
| (VII) GALLBLADDER | .41 | .38 | .34 | .44 | .43 | .40 |
| (VIII) LIVER | .1 | .2 | .3 | .4 | .8 | .3 |
| (IX) LUNGS | .11 | .10 | .9 | .8 | .5 | .9 |
| (X) LARGE INTESTINE | .3 | .5 | .11 | .1 | .2 | .4 |
| (XI) STOMACH | .43 | .41 | .36 | .45 | .44 | .42 |
| (XII) SPLEEN | .1 | .2 | .3 | .5 | .9 | .3 |

**FIG. A-30**

When we refer to the Stomach as an Earth element or the Kidney as a Water organ, never forget the inner organs and meridians are classified according to their dominant element. All organs and meridians contain traces of the other four elements; and because of these traces, an organ is linked with the other organs of different dominant elements and with the main element pool. There are five main element pools of energy supposedly located deep within the body which are used as banking systems for their own meridians and organs.

## ASSOCIATED POINTS

The Bladder meridian, which is located on the back and adjacent to the spine, contains Associated Points for each major meridian.

Dr. George Goodheart found that for every meridian out of balance there is a corresponding vertebral subluxation adjacent to the Associated Point on the Bladder meridian. He discovered that this relationship which exists between the meridian system and the spine may be two-fold. For example, a vertebra can subluxate in such a fashion as to interfere with an Acupuncture Meridian Connector (AMC) to produce a meridian imbalance; or, on the other hand, a meridian imbalance can cause a vertebra to subluxate. Therefore, all Acu-therapy treatments are not complete until the challenge subluxation is corrected. This discovery, once again, proves the importance of the spine and the contents of the intervertebral foramen to the meridian system and health. Therefore, following the balancing of any of the meridians, one must then go to the associated bladder point on the spine and challenge the vertebrae associated with that point. A challenge subluxation will always be existent in the spine at the point on the Bladder meridian which corresponds to the blocked meridian, or the Lovett vertebra for that level. For example, if therapy localization over the Alarm Point of the pectoralis major clavicular (Stomach) results in the muscle becoming weak, this would indicate the Stomach meridian is out of balance. The Stomach meridian gets its energy from the Large Intestine (tensor fascia lata). If therapy localization over the Alarm Point of the Large Intestine is positive, this would indicate that this meridian is also deficient. Since the Large Intestine gets its energy from the Lung (deltoid), one would then therapy localize the Alarm Point of the Lung. If therapy localization is negative, one would use a firm, soft-tissue manipulation over the Connecting Point of the Lung (L-7) for approximately 20 seconds. Then, the Alarm Point of the Stomach would be retherapy localized (pectoralis major clavicular) to verify correction. One should then proceed to the Associated Point on the Bladder to correct the challenge subluxation (B-13 or D-¾).

The following muscles associated with their respective meridians are as complete as we now know them. (See FIG. A-31.) This material is still being researched. Keep in mind that some meridians can become blocked toward the end of the extremities whereby they change polarities. This can cause the meridian to switch and control another muscle or group of muscles. Switch refers to a meridian in which the energy runs in the opposite direction from which it should. This is frequently seen in the conception vessel. Also, a meridian may get switched because of scar formation, amputation, etc.

## RUNNING MERIDIANS

George Goodheart, D.C. of Detroit, Michigan and John Thie, D.C. of Pasadena, California found that if a meridian is deficient (turned off), the treating doctor could turn on the meridian by "running it." The doctor "runs" a meridian by moving his hand over the skin, tracing the course of the meridian from beginning to end.

If one traces a meridian backward (or from end to the beginning), it will turn the meridian and its associated muscles off. If this action does not turn the meridian off, this means there is excess energy in that meridian, and the doctor would need to therapy localize the pulses to determine where the deficiency exists.

Occasionally, meridians become reversed and run backwards. In order to correct this, one must "run" the energy from its coupled meridian over the end of the extremity several times and then "run" the meridian several times.

## NATURE OF ENERGY

There has been much speculation as to the kind and type of energy which flows through the meridians. Dr. Goodheart has proven conclusively that the energy picked up by the superficial meridians is of an electromagnetic nature. This can be proven as follows. Depending upon which pole is used, a simple pencil magnet will turn a meridian on or off if applied to the proper point on the meridian. Secondly, if an acupuncture needle is placed on a meridian point to tonify, tonification will occur. However, if a lead cup is placed snugly against the skin over the needle, the tonification process will stop and the meridian will return to its original state. If the lead cup is removed, the needle will again bring about tonification. This proves the energy is being picked up by the meridian from external sources or the polarities of the earth's surface. The needle only acts as a mere antenna. (This observation was made by Dr. Terry Franks, Dr. Goodheart's Associate.)

Needles in the practice of acupuncture do not appear to be necessary. One can obtain the same results with the mere use of the hands, because the doctor's hands act as a sending and receiving point of electrical magnetic force.

## ASSOCIATED POINTS

| BLADDER MERIDIAN ASSOCIATED POINT NUMBER | ORGAN AND ASSOCIATED MUSCLES | | CHALLENGE SUBLUXATION |
|---|---|---|---|
| **B-13** | LUNGS — | ANTERIOR SERRATUS, DELTOIDS, CORACOBRACHIALIS. | D-3/4 |
| **B-14** | PERICARDIUM — (Circulation Sex) | GLUTEUS MINIMUS, GLUTEUS MEDIUS, GLUTEUS MAXIMUS, PIRIFORMIS, LEVATOR ANI, GRACILIS, ADDUCTORS, SARTORIUS, SOLEUS, GASTROCNEMIUS. | D-4/5 |
| **B-15** | HEART — | SUBSCAPULARIS. | D-5/6 |
| **B-18** | LIVER — | PECTORALIS MAJOR STERNAL, POSTERIOR TIBIALIS. | D-9/10 |
| **B-19** | GALLBLADDER — | POPLITEUS. | D-10/11 |
| **B-20** | SPLEEN — | ANCONEUS, MIDDLE AND LOWER TRAPEZIUS, LATISSIMUS DORSI, TRICEPS BRACHII. | D-11/12 |
| **B-21** | STOMACH — | PECTORALIS MAJOR CLAVICULAR, PTERYGOIDS, MASSETERS, TEMPORALIS, ANTERIOR AND POSTERIOR AND LATERAL NECK FLEXORS AND EXTENSORS, LEVATOR SCAPULAE, BRACHIORADIALIS, BICEPS BRACHII, RHOMBOIDS. | D-12/L-1 |
| **B-22** | THYROID — (Triple Warmer) | TERES MINOR, INFRASPINATUS. | L-1/2 |
| **B-23** | KIDNEY — | PSOAS, ILIACUS, UPPER TRAPEZIUS. | L-2/3 |
| **B-25** | LARGE INTESTINE — | TENSOR FASCIA LATA, HAMSTRINGS, QUADRATUS LUMBORUM. | L-4/5 |
| **B-27** | SMALL INTESTINE — | ABDOMINALS, QUADRICEPS. | Level of First Sacral Foramen. |
| **B-28** | BLADDER — | PERONEUS, ANTERIOR TIBIALIS, SACROSPINALIS. | Level of Second Sacral Foramen. |

**FIG. A-31**

## FIGURE EIGHT ENERGY

It has been discovered that energy forms the pattern of a figure eight (8) on the front and back of the body. Several people have written about the existence of this pattern of energy, but only recently has it been utilized in treatment.*

In Japan, three scientists found that they could draw energy from this figure eight energy pattern. They also found that it had a very beneficial effect in treating patients with burns. Their technique began by separating the figure eight energy pattern into four separate quadrants. They then covered the burned area with aluminum foil and attached a wire from the aluminum to an acupuncture point on the contralateral side of the body to draw energy to the burned area.

A similar procedure was used by William McGarey, M.D. in Phoenix, Arizona. He, too, reported excellent results when utilizing this technique for the treatment of burns.

If one were to make a rapid, superficial pass from a patient's upper left shoulder to the lower right femoral head, this would not result in muscle weakness. However, on some people, if one does just the opposite, or performs a rapid superficial sweeping motion from the lower right hip area to the upper left shoulder area, a weakness may be noted. This weakness indicates a lack of energy in one of the quadrants of the figure eight or that the energy field has been opposed.

The figure eight energy field should be checked in problem cases and on patients who suffer from fatigue.

## METHOD OF CORRECTION

The energy imbalance can be corrected very simply and rapidly. Place one hand on the front of the patient's left shoulder and the other hand on the front of the patient's right shoulder. Then remove the first hand and place it on the patient's right femoral surface and place the second hand over the patient's left femoral surface. Repeat this process four or five times. Rechallenge the previously weak figure eight pattern, and if correction has occurred, no weakness will be noted. Patients who only benefit temporarily from this procedure may receive 24-hour treatment through the use of acu-aids. The acu-aids should be placed on Sp-21 (left side), Sp-4 (bilaterally) and Cx-6 (bilaterally). The aids should be worn for 24 hours.

These procedures do not correct any specific condition, but are beneficial to the patient from a vital energy standpoint.

## PRACTICAL USE OF ACU-THERAPY

If a muscle is indicated to be weak by the T.S. Line, and upon testing it, it is found to be strong, this indicates a meridian excess. Therapy localization over an Alarm Point that is deficient will blow any muscle being tested. If energy is blocked at one of the organs which function continuously, the organ will draw from across the circle (Ko Cycle).

On occasion, after treating a patient, he will return on a subsequent visit and state he has a new problem, indicating that your last treatment brought it about. This type of complaint usually indicates a Five Element imbalance. Energy may have been taken from a meridian which was weak and given to one that was weaker. Energy should be transferred from excess deficiency in order to achieve balance.

The following examples are given so that you might become more familiar with the Five Element Laws and their use in your practice. All examples are given under the supposition that all Chiropractic kinesiological problems have been corrected and the patient is only an Acu-therapy patient.

*For additional information on figure eight energy, read "Breakthrough to Creativity — Your Higher Sense Perception," Karagulla; "Odick Force," Carl Von Reichenbach; "Acupuncture and Body Energies," W. A. McGarey.

## EXAMPLE I

The T.S. Line indicates a weak latissimus dorsi, but upon examination it is found to be strong. One must then examine the other meridians to find which one is deficient. There cannot be a meridian with excessive energy unless another one is deficient. Begin by therapy localizing the Alarm Points of the organ's counterpart, in this case, the Stomach. If the Stomach is deficient, this will weaken the muscle that was being used for test purposes. Then, use the Connecting Point for the Stomach (Stomach 40), and this will establish equilibrium between the meridians. Retest the latissimus dorsi while therapy localizing the Spleen Alarm Point to verify correction. Next, go to the associated point for the Stomach meridian (on the Bladder meridian, B-21 at D-12/L-1) and correct the challenge subluxation. Then, therapy localize the Lovett Brother to determine its involvement and make any necessary corrections.

## EXAMPLE II

The latissimus dorsi is found weak upon examination. Therapy localize the Alarm Point of the Stomach, the Spleen's counterpart. If the muscle tests strong, then therapy localize the Alarm Points counterclockwise. (See FIG. A-21.) For example, if therapy localization to the Circulation Sex Alarm Point causes strengthening of the latissimus dorsi then the energy is blocked at this meridian. The Connecting Point for Circulation Sex (CX-6) or the Fire Point on the Spleen meridian could be used to draw energy to the deficiency. Always draw from excess to deficiency. Rechallenge the Alarm Point of the Spleen meridian to verify correction. Then, challenge for the subluxation at the associated point for the Circulation Sex meridian (on Bladder meridian, B-14 at D-4/5) and challenge the Lovett Reactive (Brother) vertebra.

SIDE NOTE: A meridian is named for its dominant element, but it also has properties of the other four elements with points on the meridian appropriate to the other four elements. (See FIG. A-30.)

## EXAMPLE III

The latissimus dorsi is found weak upon examination. Therapy localize all Alarm Points counterclockwise (See FIG. A-21), and if therapy localization to one of the Liver Alarm Points results in strengthening of the latissimus dorsi, then the energy is blocked there and the patient would exhibit a hypertonic pectoralis major sternal without spasticity. Draw energy through the circle by contacting the Wood Point on the Spleen meridian. Rechallenge the Alarm Points clockwise and challenge for a subluxation at the associated point for the Liver (on the Bladder meridian, B-18 at D-9/10). Then, therapy localize the Lovett Brother and make any corrections necessary.

SIDE NOTE: This is an example of the use of the Ko or Control Cycle. Always draw energy in the most expedient way following oriental law.

## EXAMPLE IV

The latissimus dorsi is found weak upon examination. Therapy localization of the Alarm Points counterclockwise (See FIG. A-21) reveals excess energy at the Lung. Correction would be made by contacting the Wood Point on the Spleen (draw energy from Liver, creating artificial deficiency, Ko Cycle). Then, contact the Metal Point on the Liver, drawing from the excess at the lung, correct the challenge subluxation at the associated point for the lung (on Bladder meridian, B-13, at D-3/4). Then therapy localize the Lovett Brother.

SIDE NOTE: Deficiencies which occur in the organs which function continuously will usually draw energy from across the circle.

## EXAMPLE V

The latissimus dorsi is found weak upon examination. Therapy localization of the Alarm Points counterclockwise on the Five Element chart (FIG. A-21) reveals energy blocked at the Gallbladder. First, contact Wood Point on the Spleen, then the Connecting Points on the Liver. Rechallenge the Alarm Points and correct the challenge subluxation. Challenge the Lovett Brother.

SIDE NOTE: After one has gained some experience using the Five Element Laws, one will think in terms of continuous functioning organs or hollow organs. If a hollow organ is involved, challenge its counterpart first. If this is unsuccessful, proceed to challenge the Alarm Points counterclockwise on the Five Element Chart. (See FIG. A-21.) If solid or continuous functioning organs are involved, think in terms of its opposite organ on the Five Element chart, e.g., weak latissimus dorsi (Spleen, Pancreas), think in terms of popliteus (Gallbladder) or the pectoralis major sternal (Liver) — (Ko Cycle).

## HOW ONE FORM OF ENERGY ENTERS THE BODY

Energy in the body seems to travel in a figure eight pattern. Subsequent research on body energy has revealed that this electromagnetic energy enters the body on the left side only. If an acu-aid is placed on the Spleen 21 acupuncture point (which is located only on the left side of the body), it will result in drawing additional energy to the meridian system. Furthermore, when an acu-aid is placed on this Spleen 21 acupuncture point, the examiner will be unable to bring about a blockage or interruption of this figure eight energy pattern.

It has also been found that the Conception Vessel and the Governing Vessel are reservoirs of used energy; and if they should become blocked, it directly affects the flow of this figure eight energy pattern.

If a patient suffers from chronic fatigue and the examiner is unable to correct this condition through treatment of any of the five elements of the intervertebral foramen, an acu-aid should be placed on Sp-21 (left) and Sp-4 and Cx-6 (bilaterally). This seems to help relieve the fatigue if the Conception or Governing Vessels are not blocked.

## TREATMENT OF THE CONCEPTION AND GOVERNING VESSEL

(How This Energy Leaves the Body)

This electromagnetic energy leaves the body by way of the mouth. If a small, lead covering is placed over the patient's mouth, it will result in immediate muscle weakness of all of the muscles of the body if there is a blockage of the Governing or Conception Vessels. If the energy is blocked in the Governing or Conception Vessels, the lead covering will act as a further barrier and add to the blockage. Therefore, the body (which is still drawing energy) will be in the state of "too much energy," of which Palmer spoke, as there will be little or no energy leaving the body. If a lead square is not available, then ask the patient to stop breathing (apnea) for 10 seconds and this will have the same effect as the lead square.

The point of blockage on the Conception or Governing Vessels may be located through therapy localization. When a blockage exists on the Conception Vessel, the examiner should also therapy localize the Governing Vessel, as there is frequently a blockage on the Conception Vessel just opposite to that on the Governing Vessel or vice versa. These points on the Conception Vessel or Governing Vessel should be treated by the doctor holding his hand over the point on the Conception Vessel and his other hand over the Governing Vessel simultaneously for 30 seconds. Then, have the patient retherapy localize the individual points to verify correction. The patient should then be retested with a lead covering placed over the mouth, once again or suspended breathing for 10 seconds to validate correction. Correction is due to the fact that the energy is now free-flowing, and the lead square or apnea does not sufficiently block the energy to cause muscle weakness.

## IF MORE THAN THREE MERIDIANS ARE IMBALANCED

Recent research has revealed that the majority of patients who have three or more meridian imbalances are due to an occipital fixation or subluxation. After correction of the occiput lesion, be sure to retherapy localize the alarm points of the original imbalanced meridians to verify correction. Occasionally, it will be necessary to balance treat a meridian or two.

| | |
|---|---|
| **MERIDIAN** | BLADDER |
| **ASSOCIATED MUSCLES** | PERONEII, ANTERIOR TIBIALS, SACROSPINALIS |
| **PULSE SIDE** | LEFT WRIST, POSITION #3, SUPERFICIAL |
| **YIN OR YANG** | YANG |
| **ELEMENT** | WATER |
| **ALARM POINT** | CV-3 |
| **COUPLED MERIDIAN** | KIDNEY |
| **MERIDIAN CONNECTOR** | B-58 |
| **ASSOCIATED POINT** | B-28, SECOND SACRAL FORAMEN |
| **ENDANGERS or DOMINATES** | TRIPLE WARMER |
| **MOTHER OF** | KIDNEY |
| **SON OF** | SMALL INTESTINE |
| **EMOTION** | FEAR, GROAN |
| **ENERGY FLOW** | DOWN THE BACK & LEGS |
| **NO. POINTS ON MERIDIAN** | 67 |
| **ORGAN** | BLADDER |

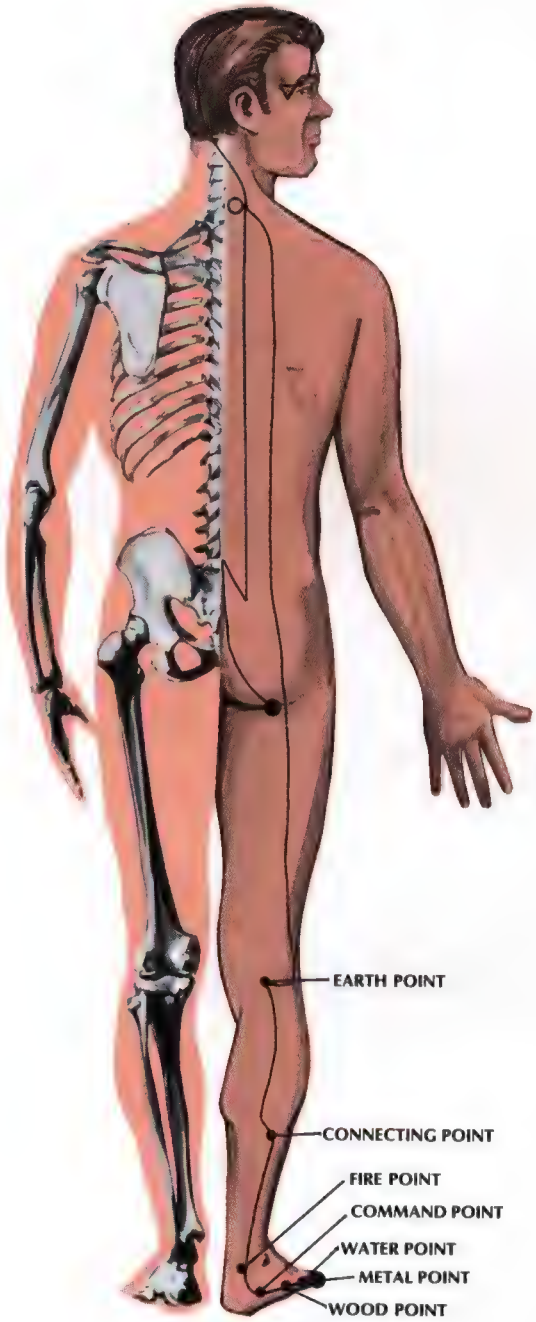


FIG. A-32

| | |
|---|---|
| **MERIDIAN** | CIRCULATION SEX |
| **ASSOCIATED MUSCLES** | GASTROCNEMIUS, GLUTEUS MINIMUS, MAXIMUS & MEDIUS, PIRIFORMIS, SOLEUS, GRACILIS, SARTORIUS, LEVATOR ANI |
| **PULSE SIDE** | RIGHT WRIST, POSITION #3, DEEP |
| **YIN OR YANG** | YIN |
| **ELEMENT** | FIRE |
| **ALARM POINT** | CV-15 |
| **COUPLED MERIDIAN** | TRIPLE WARMER |
| **MERIDIAN CONNECTOR** | CX-6 |
| **ASSOCIATED POINT** | B-14, D-4/5 |
| **ENDANGERS or DOMINATES** | KIDNEY |
| **MOTHER OF** | TRIPLE WARMER |
| **SON OF** | KIDNEYS |
| **EMOTION** | JOY, LAUGH |
| **ENERGY FLOW** | DOWN THE ARMS |
| **NO. POINTS ON MERIDIAN** | 9 |
| **ORGAN** | PERICARDIUM, ADRENAL (SUPRARENAL) GLANDS |

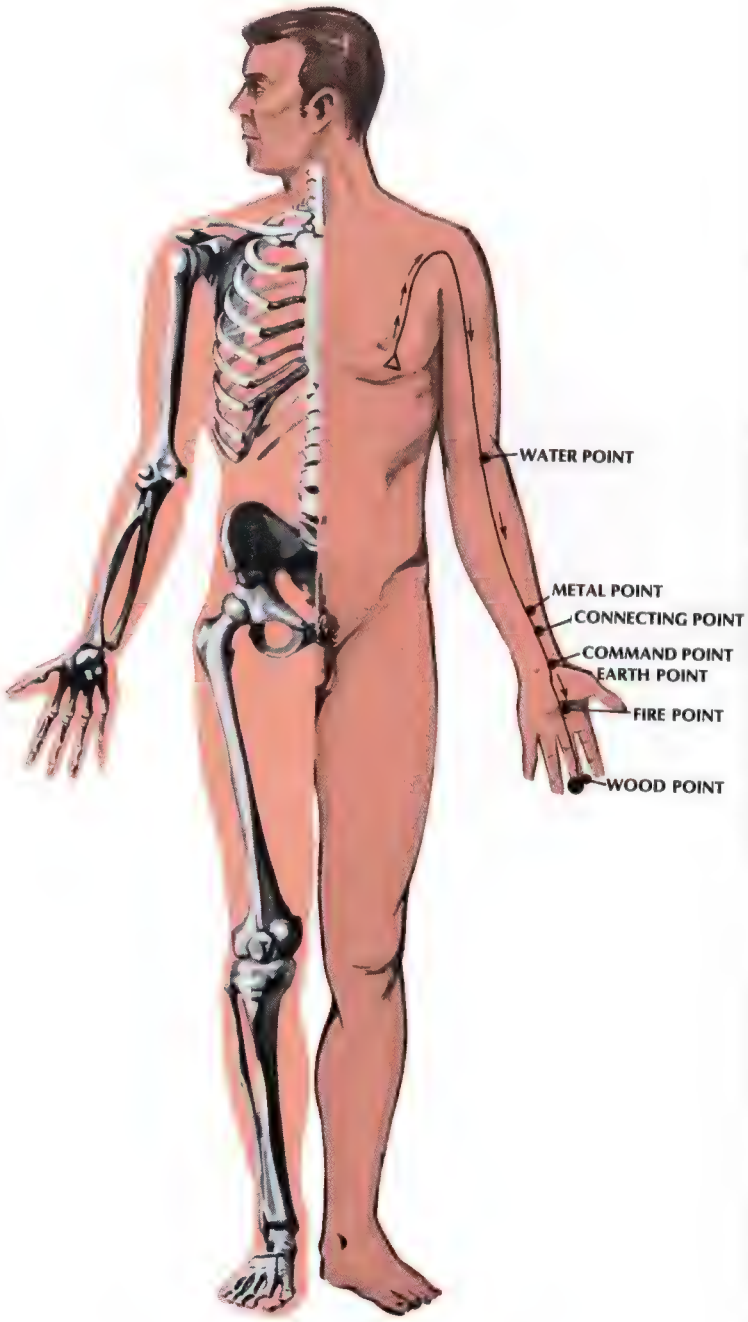




FIG. A-33

| | |
|---|---|
| **MERIDIAN** | GALLBLADDER |
| **ASSOCIATED MUSCLE** | POPLITEUS |
| **PULSE SIDE** | LEFT WRIST, POSITION #2, SUPERFICIAL |
| **YIN OR YANG** | YANG |
| **ELEMENT** | WOOD |
| **ALARM POINT** | G-23, G-24 |
| **COUPLED MERIDIAN** | LIVER |
| **MERIDIAN CONNECTOR** | G-37 |
| **ASSOCIATED POINT** | B-19, D-10/11 |
| **ENDANGERS or DOMINATES** | STOMACH |
| **MOTHER OF** | LIVER |
| **SON OF** | TRIPLE WARMER |
| **EMOTION** | ANGER, SHOUT |
| **ENERGY FLOW** | DOWN THE BODY |
| **NO. POINTS ON MERIDIAN** | 44 |
| **ORGAN** | GALLBLADDER |

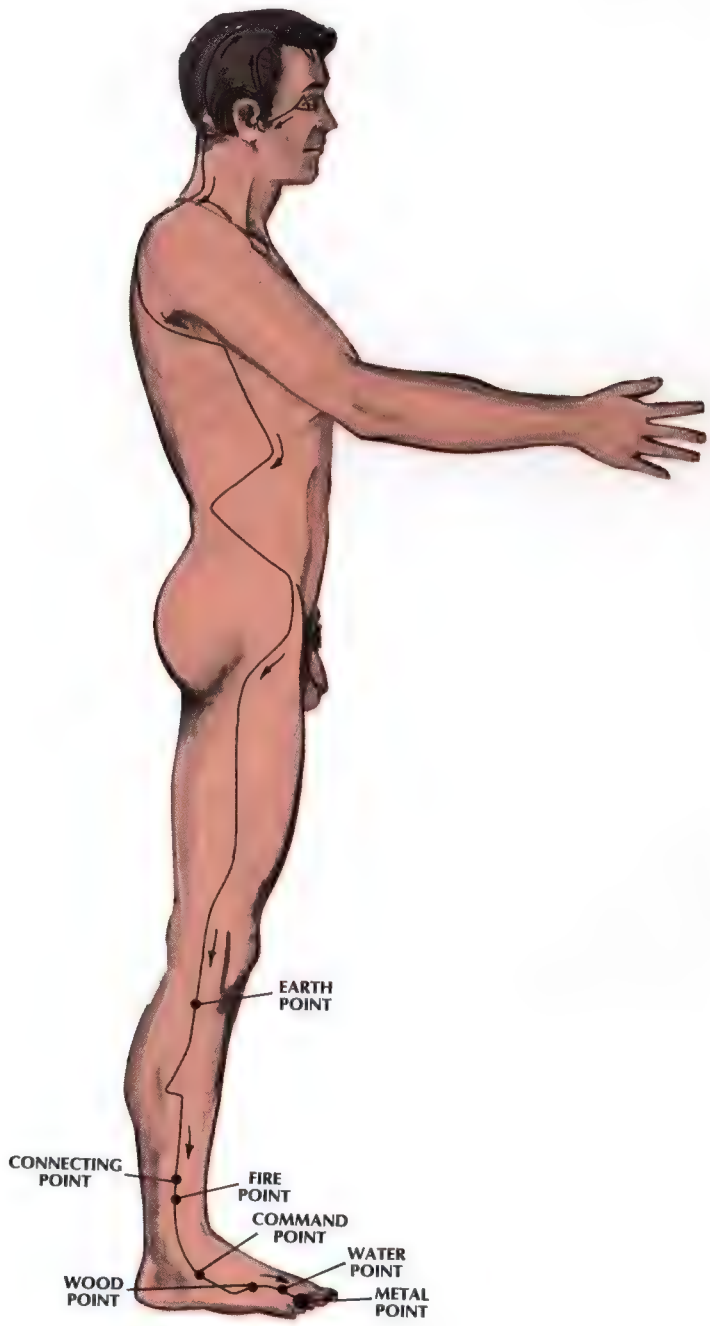


**FIG. A-34**

| | |
|---|---|
| MERIDIAN | HEART |
| ASSOCIATED MUSCLES | SUBSCAPULARIS |
| PULSE SIDE | LEFT WRIST, POSITION #1, DEEP |
| YIN OR YANG | YIN |
| ELEMENT | FIRE |
| ALARM POINT | CV-14 |
| COUPLED MERIDIAN | SMALL INTESTINE |
| MERIDIAN CONNECTOR | H-5 |
| ASSOCIATED POINT | B-15, D-5/6 |
| ENDANGERS or DOMINATES | LUNGS |
| MOTHER OF | KIDNEYS |
| SON OF | SPLEEN |
| EMOTION | JOY, LAUGH |
| ENERGY FLOW | TOWARD THE HANDS |
| NO. POINTS ON MERIDIAN | 9 |
| ORGAN | HEART |

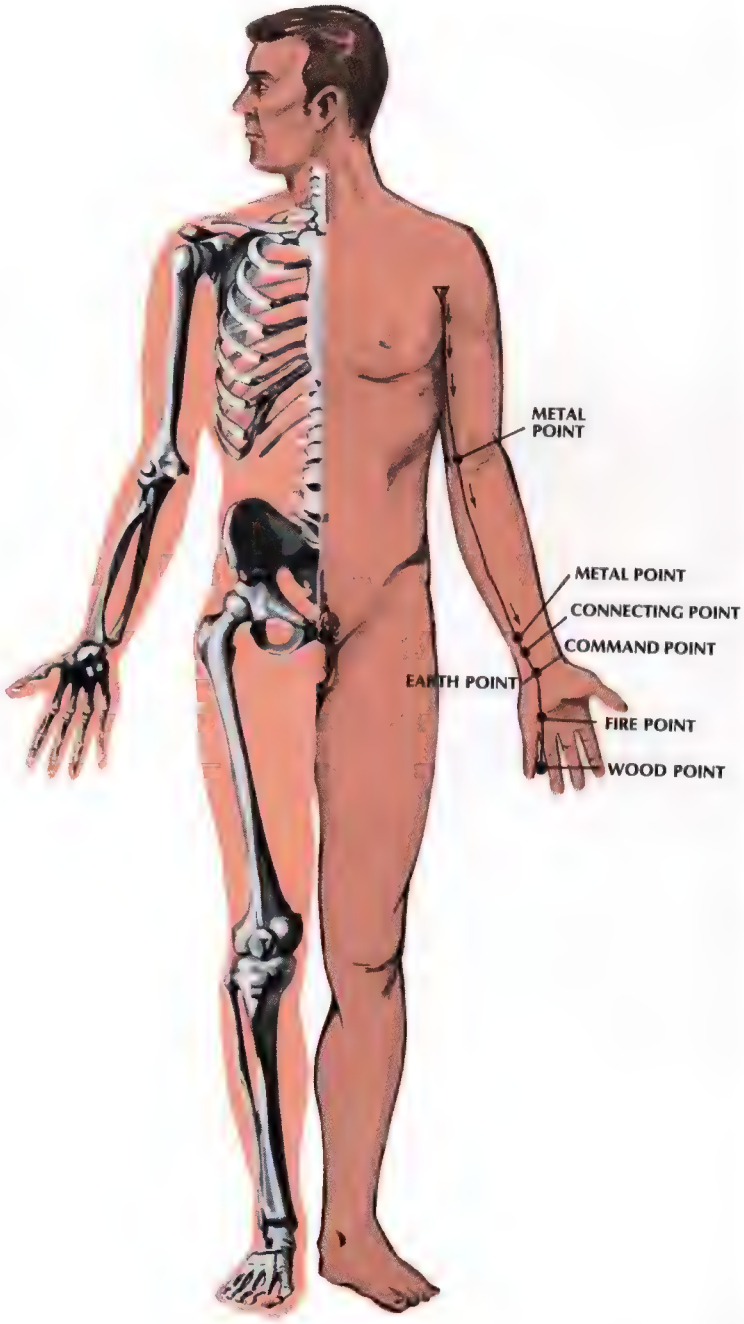


FIG. A-35

| | |
|---|---|
| MERIDIAN | KIDNEY |
| ASSOCIATED MUSCLES | PSOAS, ILIACUS, UPPER TRAPEZIUS (WRIST EXTENSORS) |
| PULSE SIDE | LEFT WRIST, POSITION #3, DEEP |
| YIN OR YANG | YIN |
| ELEMENT | WATER |
| ALARM POINT | G-25 |
| COUPLED MERIDIAN | BLADDER |
| MERIDIAN CONNECTOR | K-6 |
| ASSOCIATED POINT | B-23, L-2/3 |
| ENDANGERS or DOMINATES | CIRCULATION SEX |
| MOTHER OF | CIRCULATION SEX |
| SON OF | BLADDER |
| EMOTION | FEAR, GROAN |
| ENERGY FLOW | UP THE LEG, ABDOMEN, & CHEST |
| NO. POINTS ON MERIDIAN | 27 |
| ORGAN | KIDNEY, EYES, EARS, ILEOCECAL VALVE |

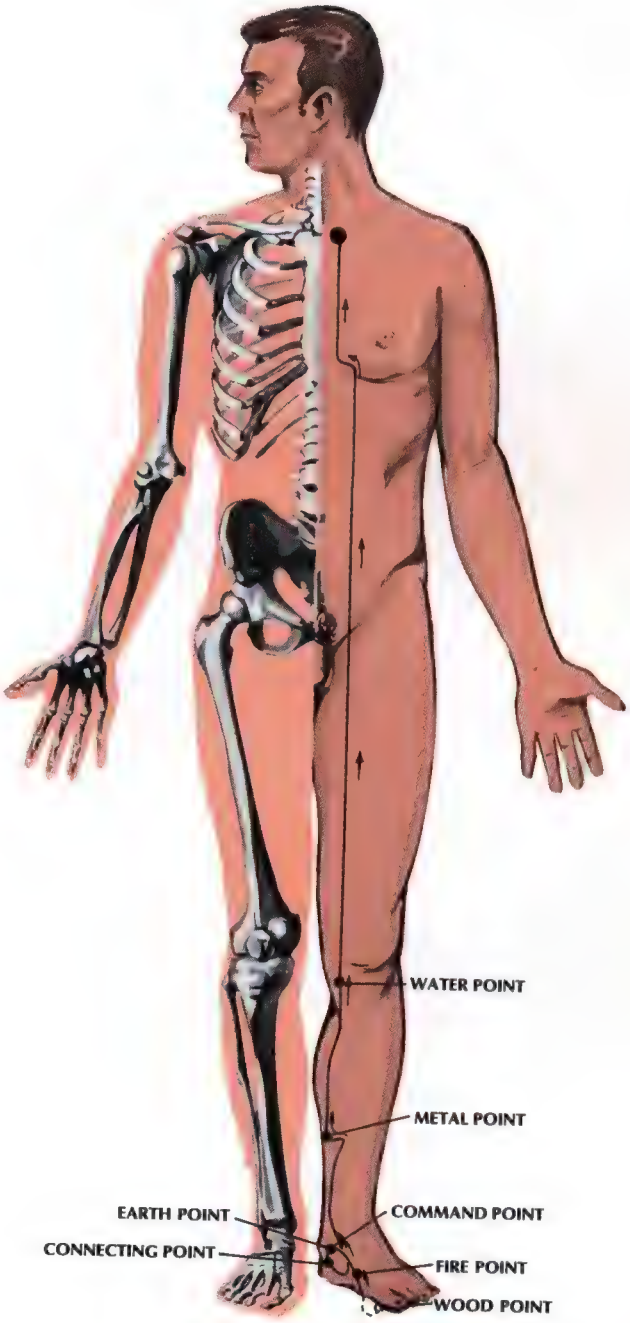


FIG. A-36

| | |
|---|---|
| MERIDIAN | LARGE INTESTINE |
| ASSOCIATED MUSCLES | TENSOR FASCIA LATA, HAMSTRINGS, QUADRATUS LUMBORUM, FOREARM PRONATORS |
| PULSE SIDE | RIGHT WRIST, POSITION #1, SUPERFICIAL |
| YIN OR YANG | YANG |
| ELEMENT | METAL |
| ALARM POINT | S-25 |
| COUPLED MERIDIAN | LUNGS |
| MERIDIAN CONNECTOR | Li-6 |
| ASSOCIATED POINT | B-25, L-4/5 |
| ENDANGERS or DOMINATES | SMALL INTESTINE |
| MOTHER OF | STOMACH |
| SON OF | LUNGS |
| EMOTION | GRIEF, WEEP |
| ENERGY FLOW | UP THE ARMS |
| NO. POINTS ON MERIDIAN | 20 |
| ORGAN | LARGE INTESTINE |

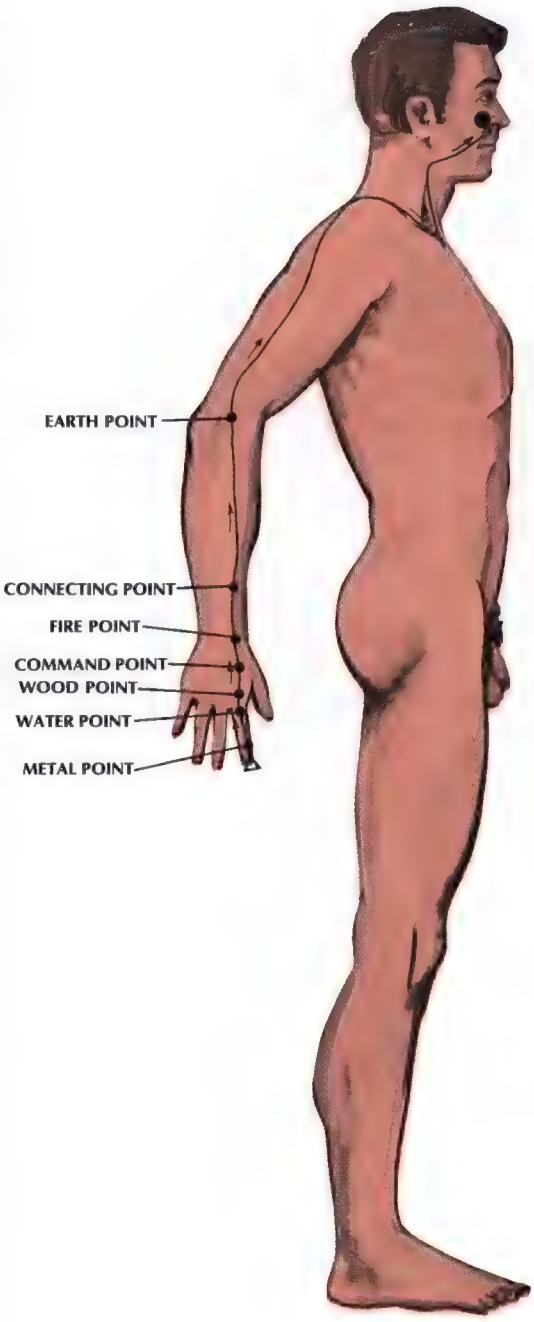


FIG. A-37

| | |
|---|---|
| **MERIDIAN** | LIVER |
| **ASSOCIATED MUSCLES** | PECTORALIS MAJOR STERNAL, POSTERIOR TIBIALIS |
| **PULSE SIDE** | LEFT WRIST, POSITION #2, DEEP |
| **YIN OR YANG** | YIN |
| **ELEMENT** | WOOD |
| **ALARM POINT** | LIV-14 |
| **COUPLED MERIDIAN** | GALLBLADDER |
| **MERIDIAN CONNECTOR** | LIV-5 |
| **ASSOCIATED POINT** | B-18, D-9/10 |
| **ENDANGERS or DOMINATES** | SPLEEN |
| **MOTHER OF** | LUNGS |
| **SON OF** | GALLBLADDER |
| **EMOTION** | ANGER, SHOUT |
| **ENERGY FLOW** | UP THE LEGS & ABDOMEN |
| **NO. POINTS ON MERIDIAN** | 14 |
| **ORGAN** | LIVER |

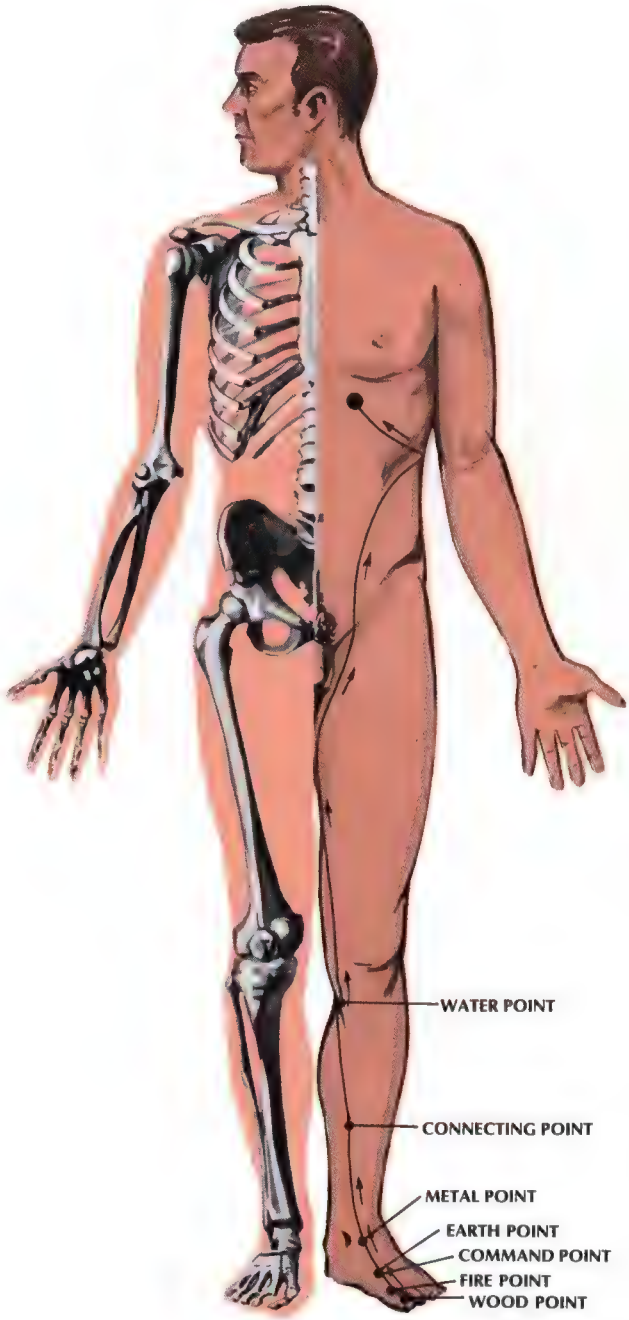


**FIG. A-38**

| | |
|---|---|
| MERIDIAN | LUNG |
| ASSOCIATED MUSCLES | ANTERIOR SERRATUS, DELTOIDS, CORACOBRACHIALIS |
| PULSE SIDE | RIGHT WRIST, POSITION #1, DEEP |
| YIN OR YANG | YIN |
| ELEMENT | METAL |
| ALARM POINT | L-1 |
| COUPLED MERIDIAN | LARGE INTESTINE |
| MERIDIAN CONNECTOR | L-7 |
| ASSOCIATED POINT | B-13, D-3/4 |
| ENDANGERS or DOMINATES | HEART |
| MOTHER OF | LARGE INTESTINE |
| SON OF | LIVER |
| EMOTION | GRIEF, WEEP |
| ENERGY FLOW | FROM CHEST DOWN THE ARMS |
| NO. POINTS ON MERIDIAN | 11 |
| ORGAN | LUNGS |

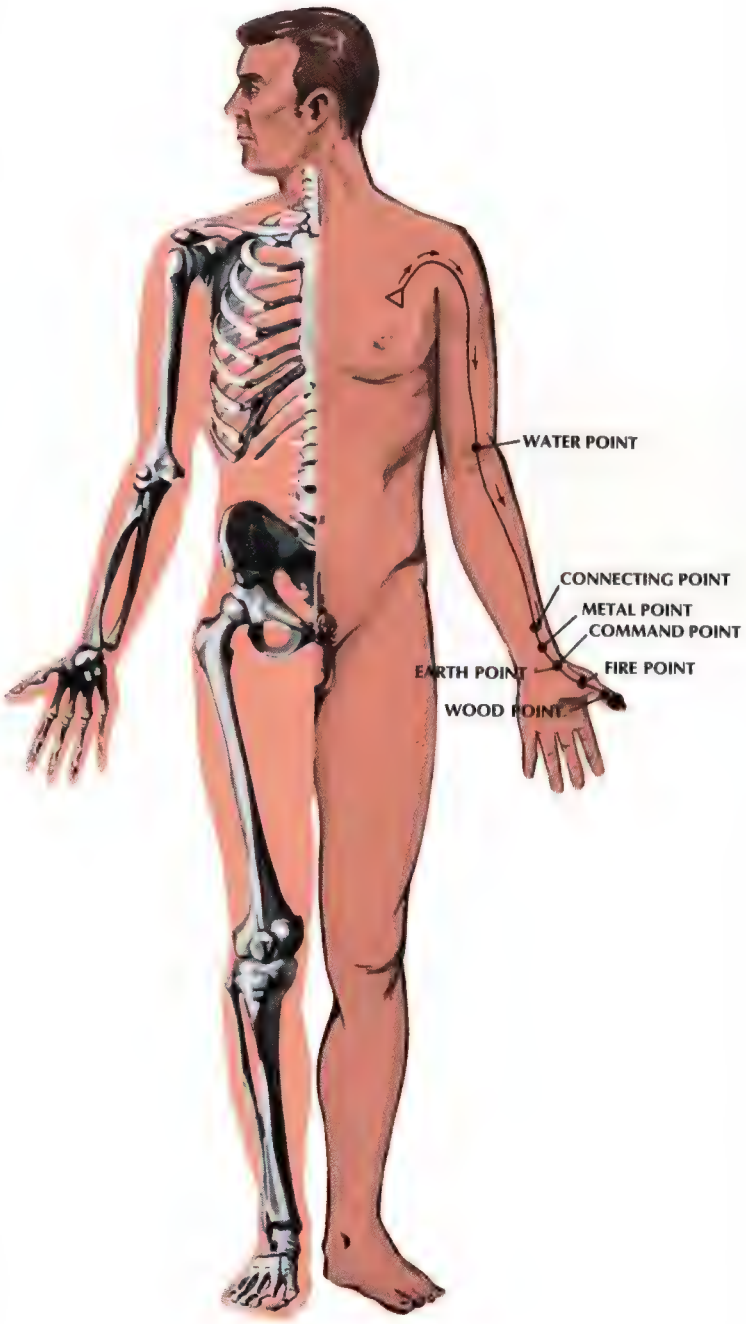


FIG. A-39

| | |
|---|---|
| MERIDIAN | SMALL INTESTINE |
| ASSOCIATED MUSCLES | ABDOMINALS, QUADRICEPS |
| PULSE SIDE | LEFT WRIST, POSITION #1, SUPERFICIAL |
| YIN OR YANG | YANG |
| ELEMENT | FIRE |
| ALARM POINT | CV-4 |
| COUPLED MERIDIAN | HEART |
| MERIDIAN CONNECTOR | SI-7 |
| ASSOCIATED POINT | B-27, FIRST SACRAL FORAMEN |
| ENDANGERS or DOMINATES | LARGE INTESTINE |
| MOTHER OF | BLADDER |
| SON OF | HEART |
| EMOTION | JOY, LAUGH |
| ENERGY FLOW | UP THE ARM |
| NO. POINTS ON MERIDIAN | 19 |
| ORGAN | SMALL INTESTINE |

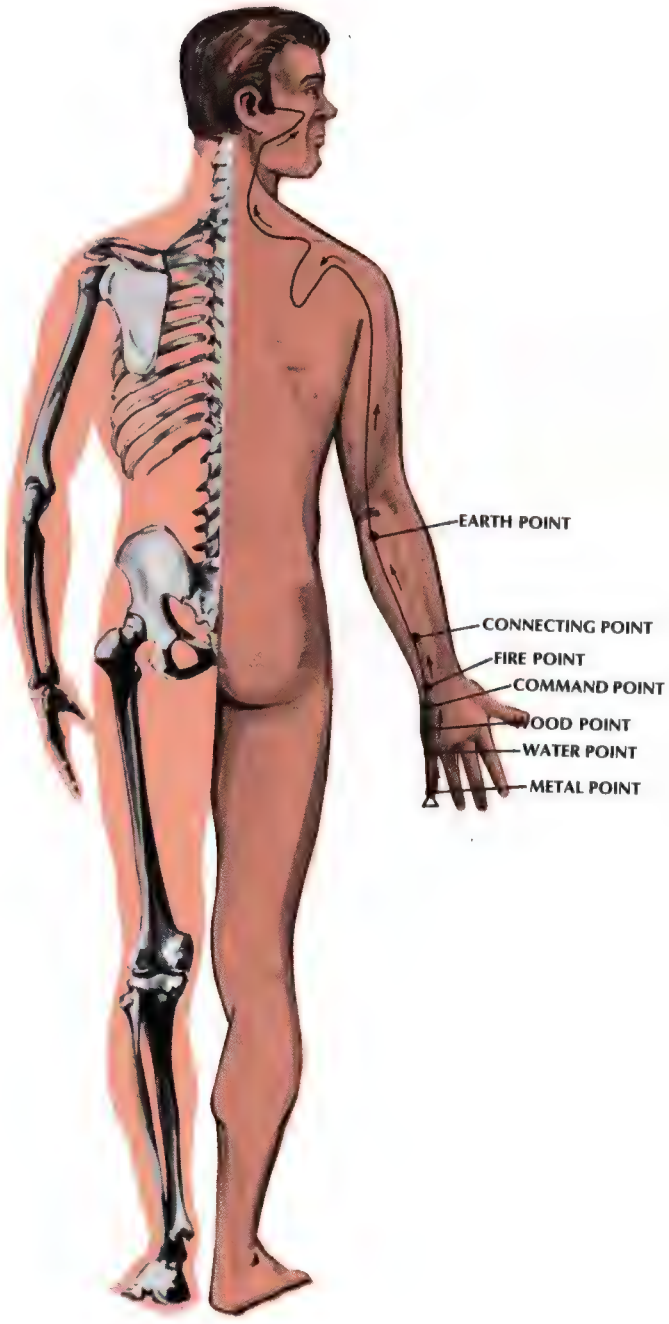


FIG. A-40

| | |
|---|---|
| MERIDIAN | SPLEEN |
| ASSOCIATED MUSCLES | ANCONEUS, MIDDLE & LOWER TRAPEZIUS, LATISSIMUS DORSI, TRICEPS BRACHII |
| PULSE SIDE | RIGHT WRIST, POSITION #2, DEEP |
| YIN OR YANG | YIN |
| ELEMENT | EARTH |
| ALARM POINT | LIV-13 |
| COUPLED MERIDIAN | STOMACH |
| MERIDIAN CONNECTOR | SP-4 |
| ASSOCIATED POINT | B-20, D-11/12 |
| ENDANGERS or DOMINATES | LIVER |
| MOTHER OF | HEART |
| SON OF | STOMACH |
| EMOTION | SYMPATHY, SING |
| ENERGY FLOW | UP THE LEGS |
| NO. POINTS ON MERIDIAN | 21 |
| ORGAN | SPLEEN |

FIG. A-41

| | |
|---|---|
| **MERIDIAN** | STOMACH |
| **ASSOCIATED MUSCLES** | ANTERIOR, POSTERIOR & LATERAL NECK FLEXORS AND EXTENSORS, LEVATOR SCAPULAE, PECTORALIS MAJOR CLAVICULAR, BRACHIORADIALIS, BICEPS BRACHII, RHOMBOIDS, MASSETERS, PTERYGOIDS, TEMPORALIS |
| **PULSE SIDE** | RIGHT WRIST, POSITION #2, SUPERFICIAL |
| **YIN OR YANG** | YANG |
| **ELEMENT** | EARTH |
| **ALARM POINT** | CV-12 |
| **COUPLED MERIDIAN** | SPLEEN |
| **MERIDIAN CONNECTOR** | S-40 |
| **ASSOCIATED POINT** | B-21, D-12, L-1 |
| **ENDANGERS or DOMINATES** | GALLBLADDER |
| **MOTHER OF** | SPLEEN |
| **SON OF** | LARGE INTESTINE |
| **EMOTION** | SYMPATHY, SING |
| **ENERGY FLOW** | DOWN THE BODY & LEGS |
| **NO. POINTS ON MERIDIAN** | 45 |
| **ORGAN** | STOMACH, SINUSES |

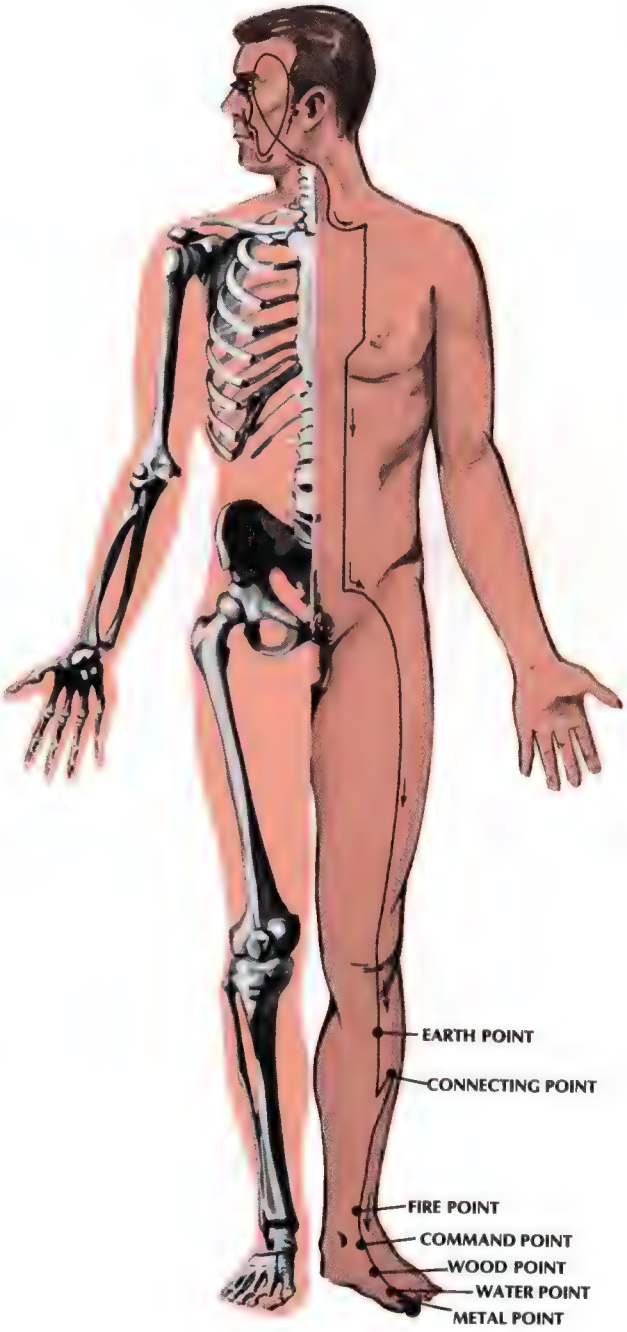


FIG. A-42

| | |
|---|---|
| **MERIDIAN** | TRIPLE WARMER |
| **ASSOCIATED MUSCLES** | TERES MINOR, INFRASPINATUS |
| **PULSE SIDE** | RIGHT WRIST, POSITION #3, SUPERFICIAL |
| **YIN OR YANG** | YANG |
| **ELEMENT** | FIRE |
| **ALARM POINT** | CV-7 |
| **COUPLED MERIDIAN** | CIRCULATION SEX |
| **MERIDIAN CONNECTOR** | T-5 |
| **ASSOCIATED POINT** | B-22, L-1/2 |
| **ENDANGERS or DOMINATES** | KIDNEY |
| **MOTHER OF** | GALLBLADDER |
| **SON OF** | CIRCULATION SEX |
| **EMOTION** | JOY, LAUGH |
| **ENERGY FLOW** | UP THE ARMS |
| **NO. POINTS ON MERIDIAN** | 23 |
| **ORGAN** | THYROID |

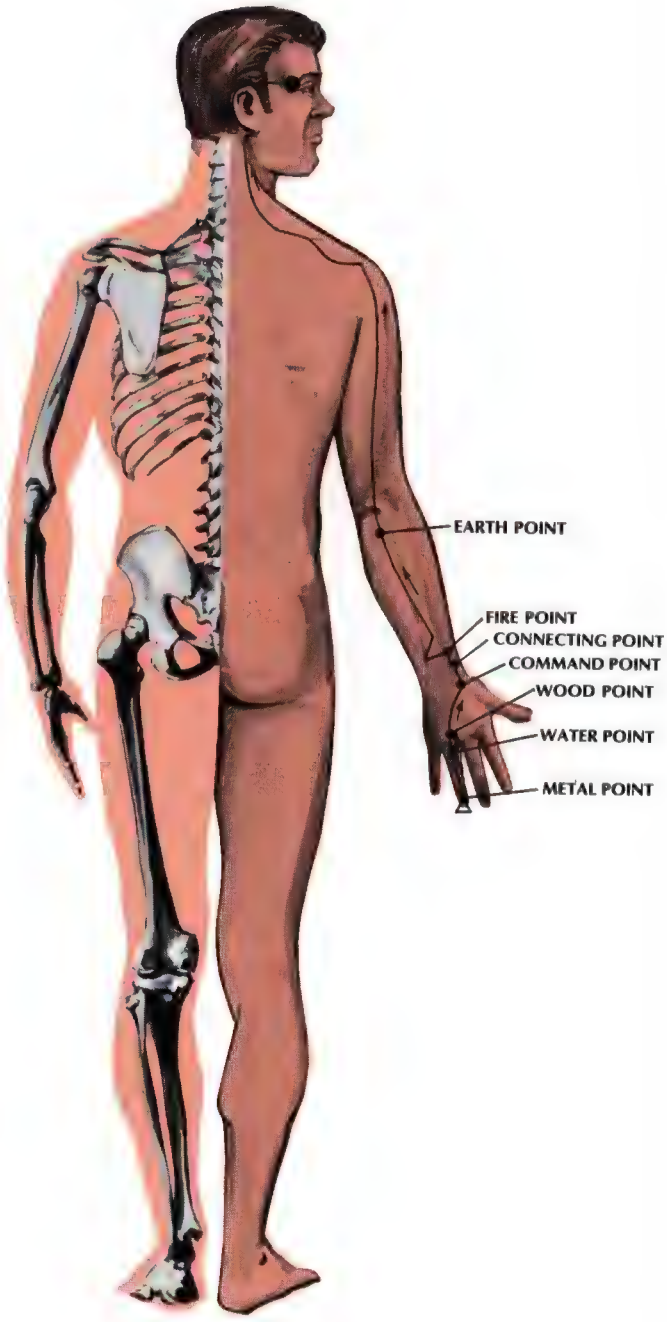


**FIG. A-43**

# CHAPTER III
## AURICULOTHERAPY

FIG. AT-1

## HISTORY AND GENERAL INFORMATION

When Dr. Bordeo was a young practicing doctor in France, he noticed that many of his patients had a burn on their ear. Upon questioning several of these patients, he was told the burn was administered by their local blacksmith as a treatment for sciatic neuritis. This peculiar method of treatment prompted Dr. Bordeo to begin his research on the ear, and today he is one of the world's leading authorities on auriculotherapy.

Auriculotherapists claim that for every organ, system and structure in the body, there is a corresponding spot on the ear. According to Dr. Nogier, who is credited as being the father of auriculotherapy, this system of healing is not acupuncture and is a separate system. Dr. Bordeo believes auriculotherapy is the link between acupuncture and the nervous system.

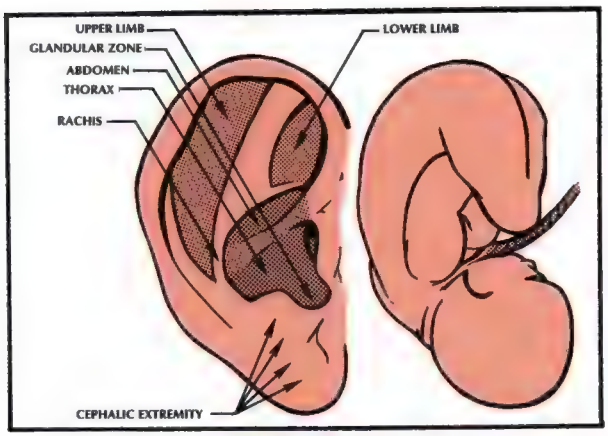


**FIG. AT-2**

The ear may be likened to a fetus which is upside down, with the head being represented by the lobule of the ear. The abdomen is facing forward and the back is toward the posterior portion of the ear. The helix and the anti-helix are representative of the cervical, dorsal and lumbar spine. C-1 begins around the concha, just past the intertragus, and then the cervicals phase into the dorsal column as the anti-helix bends around, comes up and goes forward toward the helix. The lumbar and sacral areas are the upper anterior aspect of the helix or just inferior to the fossa triangularis. (See Figure AT-2.)

Palpation of the helix and the anti-helix can be performed most effectively with a small, dull instrument with the palpating point being about one-half the size of the dull end of a straight pin. The information gained upon palpation of these areas is relatively specific and definitely correlatable to the spine. Upon palpation, it is of interest to note that increased areas of sensitivity along the helix are capable of showing referred activity of the anti-helix.

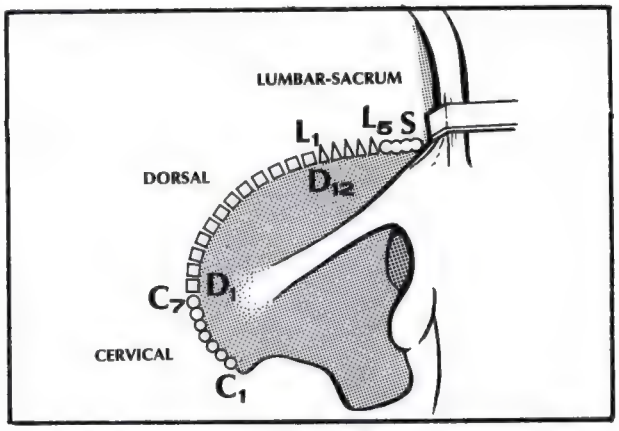


**FIG. AT-3**

According to Dr. Bordeo, "the anti-helix is the image of the spinal column and is the real keystone of the system of correspondence, and must be known with the greatest accuracy with and all its parts." Dr. Bordeo palpates with a "stirrup," beginning at the tail of the helix. If he finds a sensitive area, he then goes to the corresponding area on the spine and attempts to manipulate it. In order to therapy localize the ear using the principles of Applied Chiropractic Kinesiological Diagnosis and Technique, one must first select a strong indicator muscle. Then, have the patient place one finger from each hand on the same point on the anti-helix of each ear and retest the indicator muscle. If the indicator muscle becomes weak, ask the patient to remove one finger at a time as the indicator muscle is retested to determine which ear is involved. One should then therapy localize and challenge the corresponding part on the patient's body if the reflex point remains positive, treat accordingly. Retherapy localize the involved ear to determine if the reflex point has been abolished. If the indicator muscle remains strong, have the patient move his fingers bilaterally superior and repeat the same procedure.

When treating a patient's structural faults, simply therapy localize the ear bilaterally to determine if the corresponding point on the ear is involved. A strong indicator muscle should be retested.

Because of the relatively large size of the fingertips in comparison to the small points on the ear, therapy localization technique may not always be accurate. Therefore, the use of any one of the other diagnostic instruments outlined in this chapter may be necessary.

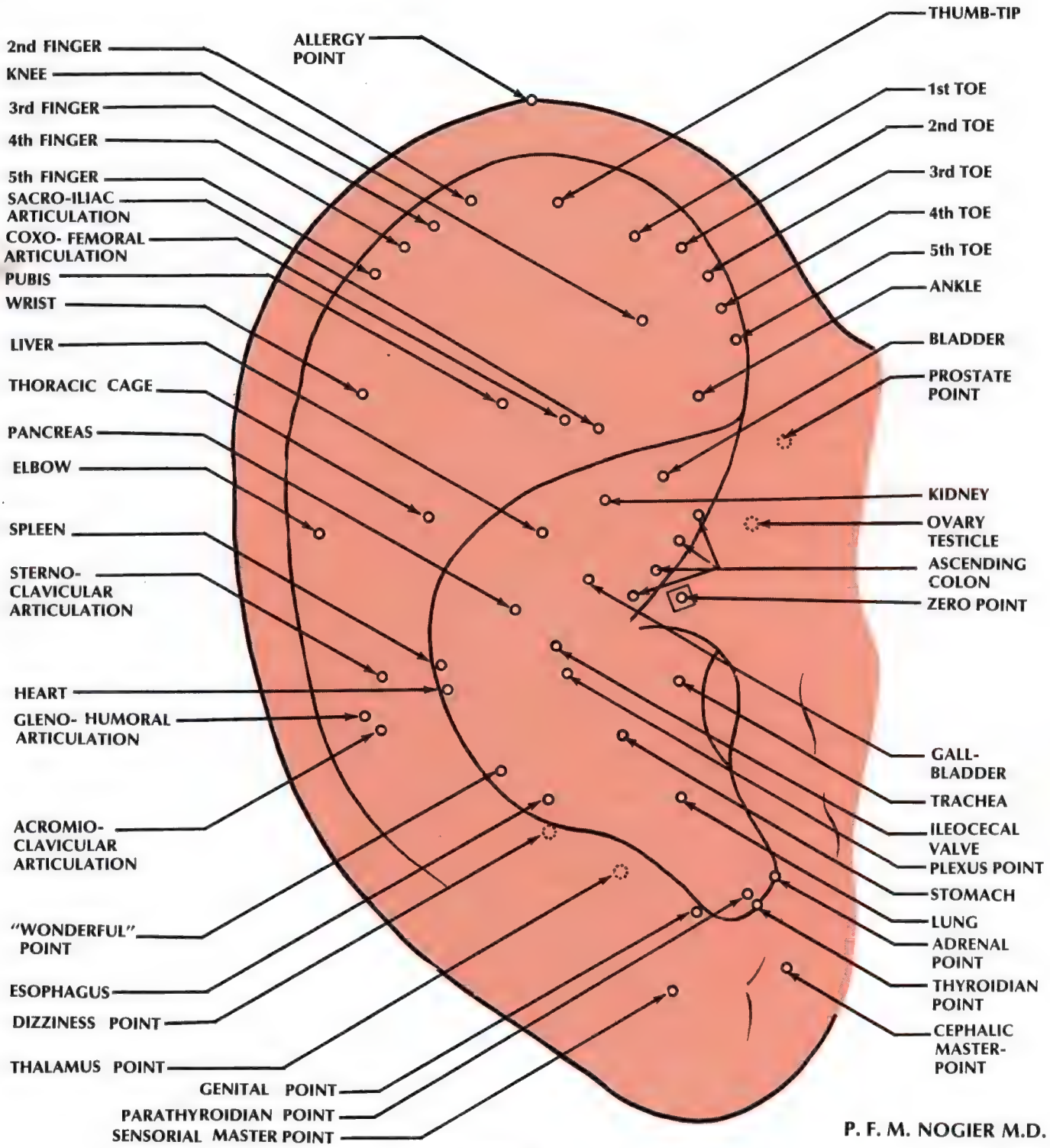
2nd FINGER
KNEE
3rd FINGER
4th FINGER
5th FINGER
SACRO-ILIAC ARTICULATION
COXO- FEMORAL ARTICULATION
PUBIS
WRIST
LIVER
THORACIC CAGE
PANCREAS
ELBOW
SPLEEN
STERNO- CLAVICULAR ARTICULATION
HEART
GLENO- HUMORAL ARTICULATION
ACROMIO- CLAVICULAR ARTICULATION
"WONDERFUL" POINT
ESOPHAGUS
DIZZINESS POINT
THALAMUS POINT
GENITAL POINT
PARATHYROIDIAN POINT
SENSORIAL MASTER POINT
ALLERGY POINT
THUMB-TIP
1st TOE
2nd TOE
3rd TOE
4th TOE
5th TOE
ANKLE
BLADDER
PROSTATE POINT
KIDNEY
OVARY TESTICLE
ASCENDING COLON
ZERO POINT
GALL- BLADDER
TRACHEA
ILEOCECAL VALVE
PLEXUS POINT
STOMACH
LUNG
ADRENAL POINT
THYROIDIAN POINT
CEPHALIC MASTER- POINT
P. F. M. NOGIER M.D.

FIG. AT-4

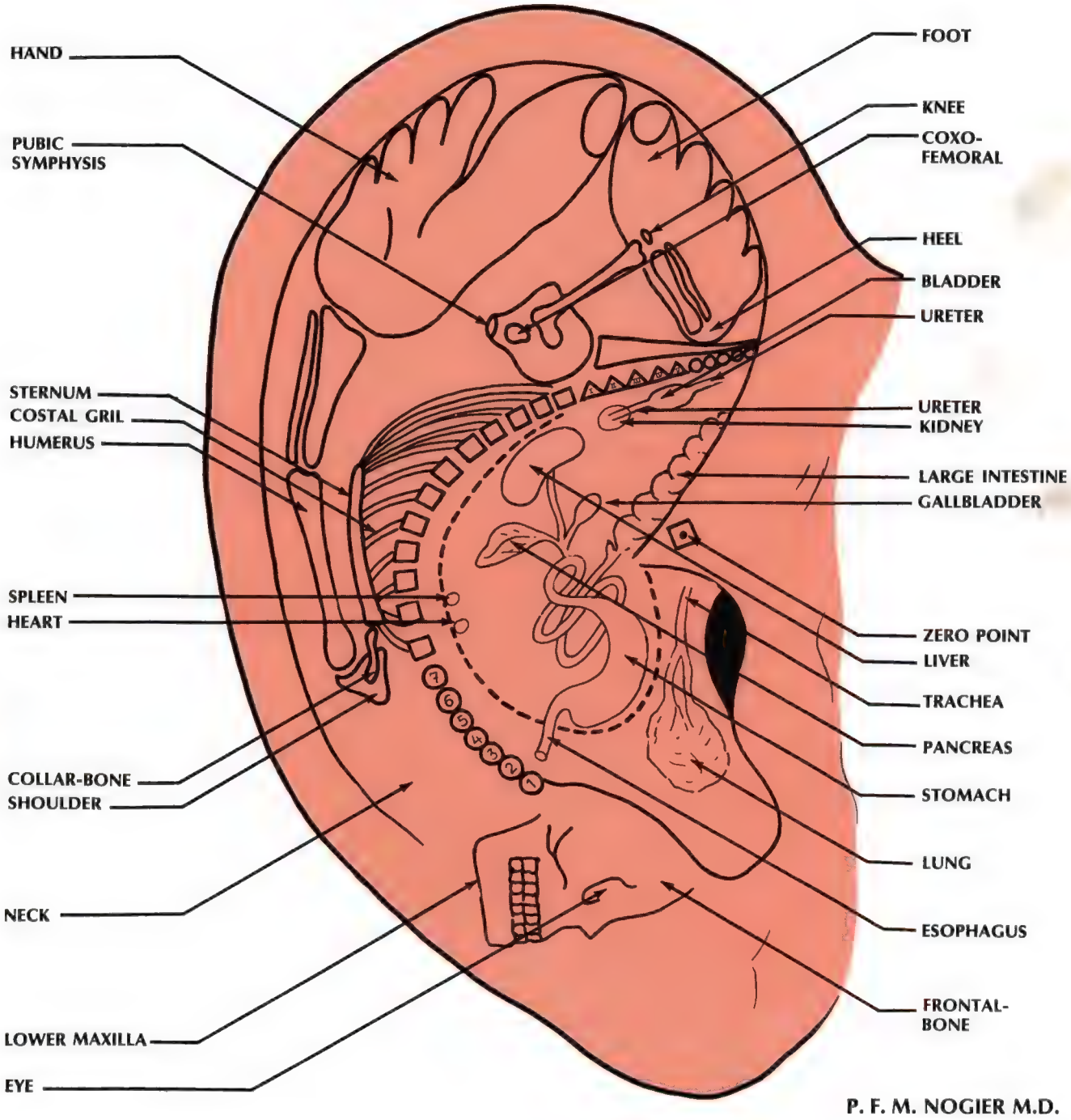
HAND
PUBIC SYMPHYSIS
STERNUM
COSTAL GRIL
HUMERUS
SPLEEN
HEART
COLLAR-BONE
SHOULDER
NECK
LOWER MAXILLA
EYE
FOOT
KNEE
COXO-FEMORAL
HEEL
BLADDER
URETER
URETER
KIDNEY
LARGE INTESTINE
GALLBLADDER
ZERO POINT
LIVER
TRACHEA
PANCREAS
STOMACH
LUNG
ESOPHAGUS
FRONTAL-BONE
P. F. M. NOGIER M.D.

FIG. AT-5

If one palpates the ear and finds a sensitive area, it may be treated locally (auriculotherapy) or the corresponding area of the body may be treated (through any one of the five foraminal elements). If the treatment is successful, it will abolish the reflex point on the ear. Therefore, it can be said that the ear is useful in diagnosis as well as in treatment.

Auriculotherapy may be performed by any one of the following methods, but the patient's comfort must always be a constant consideration.

1. **ELECTRICAL MACHINES**
   There are several electrical machines on the market today which can be used to indicate a sensitive point on the ear. Upon locating the sensitive areas, a machine may also be used to induce a small electrical current into the ear which will abolish the reflex.
2. **NEEDLES**
   The most common method of auriculotherapy practiced around the world today is through the use of an auriculotherapy needle. A gold needle is used to tonify and a silver needle is used to sedate. A stainless steel needle allows the energies of the body to balance. Auriculotherapy needles are approximately one-fourth the size of an acupuncture needle.
3. **MAGNET THERAPY**
   Magnet therapy is another popular method of treatment. Once the sensitive point on the ear has been located through palpation or an electrical instrument, the pencil magnet is placed upon that point for approximately 10-15 seconds. With a pencil magnet, one uses the north pole of the magnet to tonify the right side of the body and the south pole of the magnet to tonify the left side of the body. To sedate, the process is reversed. Use the south pole to sedate the right side of the body and the north pole to sedate the left side of the body.
4. **AURICULAR RADICULAR APPENDAGE STRETCHING TECHNIQUE**
   Through Applied Chiropractic Kinesiological Diagnosis and Technique, a patient's need for auriculotherapy can often be determined by his respiratory phase (see chapter on Respiratory Assistance Technique). The patient's respiratory phase is determined by a simple muscle test. Ask the patient to lie in a supine position and take a deep breath, raise his head, turn it to the right and hold it in this position as the muscle is being tested (the same procedure should be performed as the patient turns his head to the left). Frequently, if a patient is in need of auriculotherapy, this action will cause immediate muscle weakness on the side toward which the head is being turned. Auriculotherapy may be needed bilaterally or unilaterally, and this is why the patient must be tested when turning the head to the left and the right. If the patient's respiratory phase indicates that he is in need of auriculotherapy, and the side of involvement has been established, treatment can then be initiated. Dr. Goodheart's method of treatment is to simply go to the ear on the affected side and begin a radicular stretching and pulling of the ear along the anti-helix area. Then, the patient is retested to make sure correction has taken place. If the ear is crumpled in the area where the Auricular Radicular Appendage Stretching Technique was utilized, it will cause the original findings to reappear.
5. **K-27**
   If a muscle weakness is found and does not respond to any one of the five foraminal elements, one can contact K-27 and the appropriate spinal area on the ear simultaneously to restore muscle strength.

Dr. Robert Perolman of Hollywood Beach, Florida spent four months in France studying auriculotherapy with Dr. Bordeo, Dr. Nibiet and Dr. Nogier, the world's three leading auriculotherapists. While in France, he noticed that approximately 70% of their treatment was administered through spinal manipulation and 30% through acupuncture.

## TYPE OF ENERGY

In a demonstration before the I.C.A.K., Dr. Perolman selected a patient with an ileocecal valve syndrome, a weak right rectus abdominis and a weak right quadriceps. These weaknesses were confirmed through muscle testing and also therapy localization. Dr. Perolman then located the associated point on the ear for the ileocecal valve and inserted a stainless steel needle. This resulted in correction of the ileocecal valve syndrome and the associated weakened musculature. Dr. Goodheart, who was also present at the demonstration, then covered the stainless steel needle with a lead glove, and this action immediately resulted in muscle weakness and the return of the ileocecal valve syndrome. When the lead glove was removed, the muscles regained their strength, and the ileocecal valve correction reoccurred. This demonstration illustrates, once again, that the needle acts as an antenna and draws electromagnetic energy from the environment.

Dr. Goodheart's research has contributed substantially to our understanding of auriculotherapy in many areas. He found that if a lead glove was placed over the ear in the absence of a needle, it would also often result in the weakening of all the muscles on that side of the patient's body. Apparently, on some people, the ear acts as an auxillary antenna to draw supplementary energy. Approximately 95% of those people who exhibit cranial respiratory faults will also respond to the lead glove effect. It has been found that the use of this additional source of energy and the cranial respiratory fault can be corrected through the Auricular Radicular Appendage Stretching Technique.

Keep in mind that not all people who are in need of auriculotherapy display a cranial respiratory fault or respond to the lead glove effect. For those who do not, it is necessary to utilize therapy localization, palpate the ear or use electrical instrumentation to make this determination.

For additional information on Auriculotherapy, read "A Treatise of Auriculotherapy," P.F.M. Nogier, M.D., Maisonnerve 57160 Moulins les Metz, France.

# CHAPTER IV

# MUSCLES, STRUCTURAL FAULTS AND CORRECTION

The following chapter illustrates the muscles most frequently examined in an Applied Chiropractic Kinesiological practice. A chart is provided on each muscle which outlines the information necessary for the location, examination and treatment of that particular muscle. Pictorial muscle testing instructions are also provided which show the arc of motion of the weak member as it is being tested. The neurovascular holding points (abbreviated N.V.), neurolymphatics (abbreviated N.L.), acupuncture meridian, acupuncture points of sedation and tonification and the cranial stress centers, which are associated with each muscle, are clearly illustrated. In most cases, the mannequin has been designed to display one-half of the posterior and one-half of the anterior views of the body, so that all points which are associated with each muscle may be illustrated simultaneously. However, keep in mind that the N.V.'s and N.L.'s are bilateral unless otherwise indicated.

On the strengthening and weakening photos (points of sedation and tonification) located next to the mannequin, contact points "1" simultaneously and then points "2" simultaneously; hold each set of points from 20-30 seconds. The blank, red circle included on one of these photos is the acu-therapy connecting point.

## GRADING OF MUSCLE STRENGTH

| TEST PERFORMANCE | GRADE | % |
|---|---|---|
| The ability to hold the test position against gravity and maximum pressure, or the ability to move the part into test position and hold against gravity and maximum pressure. | 5 | 100 |
| | 5— | 95 |
| Same as above except holding against moderate pressure. | 4+ | 90 |
| | 4 | 80 |
| Same as above except holding against minimum pressure. | 4— | 70 |
| | 3+ | 60 |
| The ability to hold the test position against gravity, or the ability to move the part into test position and hold against gravity. | 3 | 50 |
| The gradual release from test position against gravity; or, the ability to move the part toward test position against gravity almost to completion, or to completion with slight assistance; or, the ability to complete the arc of motion with gravity lessened. | 3— | 40 |
| The ability to move the part through partial arc of motion with gravity lessened: Moderate arc, 30% or poor +; small arc, 20% or poor. To avoid moving a patient into gravity-lessened position, these grades may be estimated on the basis of the amount of assistance given during anti-gravity test movements: A 30% or poor + muscle requires moderate assistance, a 20% or poor muscle requires more assistance. | 2+ | 30 |
| | 2 | 20 |
| In muscles that can be seen or palpated, a feeble contraction may be felt in the muscle, or the tendon may become prominent during the muscle contraction; but there is no visible movement of the part. | 2— | 10 |
| | 1 | 5 |
| No contraction felt in the muscle. | 0 | 0 |

# ABDOMINAL MUSCLES - SMALL INTESTINE

## EXTERNAL ABDOMINAL OBLIQUE

| | |
|---|---|
| STRUCTURAL WEAKNESS | Spondylolisthesis, weak back, neck problems, shoulder problems, jammed sagittal suture, internally rotated ilium, occasional shoulder problems. |
| INTERNAL MANIFESTATIONS | Respiratory problems, stomach aches, stomach pains, narcolepsy. |
| NEUROLYMPHATICS | **ANTERIOR:** Inside of thighs, lower one-half of thigh, medial one-fifth.<br>**POSTERIOR:** The posterior iliac crest. |
| MERIDIAN | Small Intestine. |
| NUTRITION | Vitamin E, natural intestinal extracts. |
| ASSOCIATED MUSCLES | Sacrospinalis, quadriceps, hamstrings, diaphragm, psoas, gluteus maximus, latissimus dorsi. |
| LAB TESTS | CBC, ESR, blood eosinophil count, sputum eosinophil count, erythrocyte count, sputum culture, stool culture for mucus and pus cells and blood, diagnex blue. |
| EXERCISE | Sit-ups, leg raises, standing alternating toe touch, side bends, lateral twists. |
| ACTION | Compresses abdominal contents, active in forced expiration, supports viscera. |
| ORIGIN | Interdigitating slips from the external surface of the lower eight ribs. |
| INSERTION | Anterior superior iliac spine and pubic tubercle, into external lip of anterior one-half of iliac crest, inguinal ligament and linea alba. |
| NERVE SUPPLY | T-8 through T-12, intercostals, iliohypogastric and the ilio-inguinal nerves. |
| PALPATE | Lateral side of abdomen. |

NV IN RESEARCH

# ABDOMINAL MUSCLES - SMALL INTESTINE

## EXTERNAL ABDOMINAL OBLIQUE

**TO STRENGTHEN:**

**TO WEAKEN:**

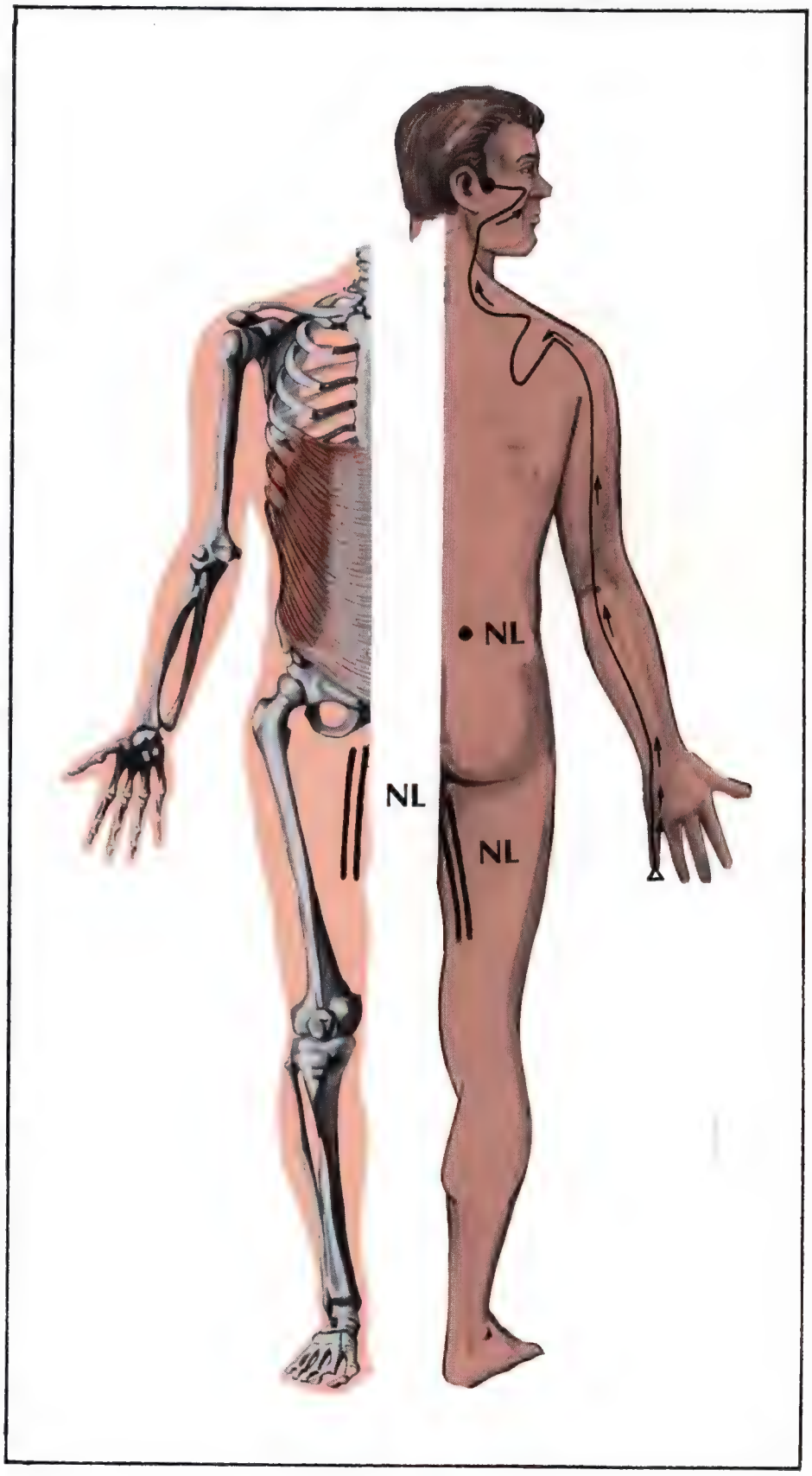

# ABDOMINAL MUSCLES - SMALL INTESTINE

## INTERNAL ABDOMINAL OBLIQUE

| | |
|---|---|
| STRUCTURAL WEAKNESS | Spondylolisthesis, weak back, neck problems, shoulder problems, jammed sagittal suture, internally rotated ilium, occasional shoulder problems. |
| INTERNAL MANIFESTATIONS | Respiratory problems, stomach aches, stomach pains, narcolepsy. |
| NEUROLYMPHATICS | **ANTERIOR:** Inside of thighs, lower one-half of thigh, medial one-fifth.<br>**POSTERIOR:** The posterior iliac crest. |
| MERIDIAN | Small Intestine. |
| NUTRITION | Vitamin E, natural intestinal extracts. |
| ASSOCIATED MUSCLES | Sacrospinalis, quadriceps, hamstrings, diaphragm, psoas, gluteus maximus, latissimus dorsi. |
| LAB TESTS | CBC, ESR, blood eosinophil count, sputum eosinophil count, erythrocyte count, sputum culture, stool culture for mucus and pus cells and blood, diagnex blue. |
| EXERCISE | Sit-ups, leg raises, standing alternating toe touch, side bends, lateral twists. |
| ACTION | Compresses abdominal contents, helps rotate the vertebral column, active in forced expiration. |
| ORIGIN | Lateral one-half of the inguinal ligament, anterior two-thirds of middle lip of the crest of the ilium and the lower lumbar aponeurosis. |
| INSERTION | Inferior borders of the cartilages of the lower 3-4 ribs and the linea alba. |
| NERVE SUPPLY | Branches of the T-8 through T-12 intercostal, iliohypogastric and ilio-inguinal nerves. |
| PALPATE | Lateral side of the abdomen. |

NV IN RESEARCH

# ABDOMINAL MUSCLES - SMALL INTESTINE

## INTERNAL ABDOMINAL OBLIQUE

**TO STRENGTHEN:**

**TO WEAKEN:**

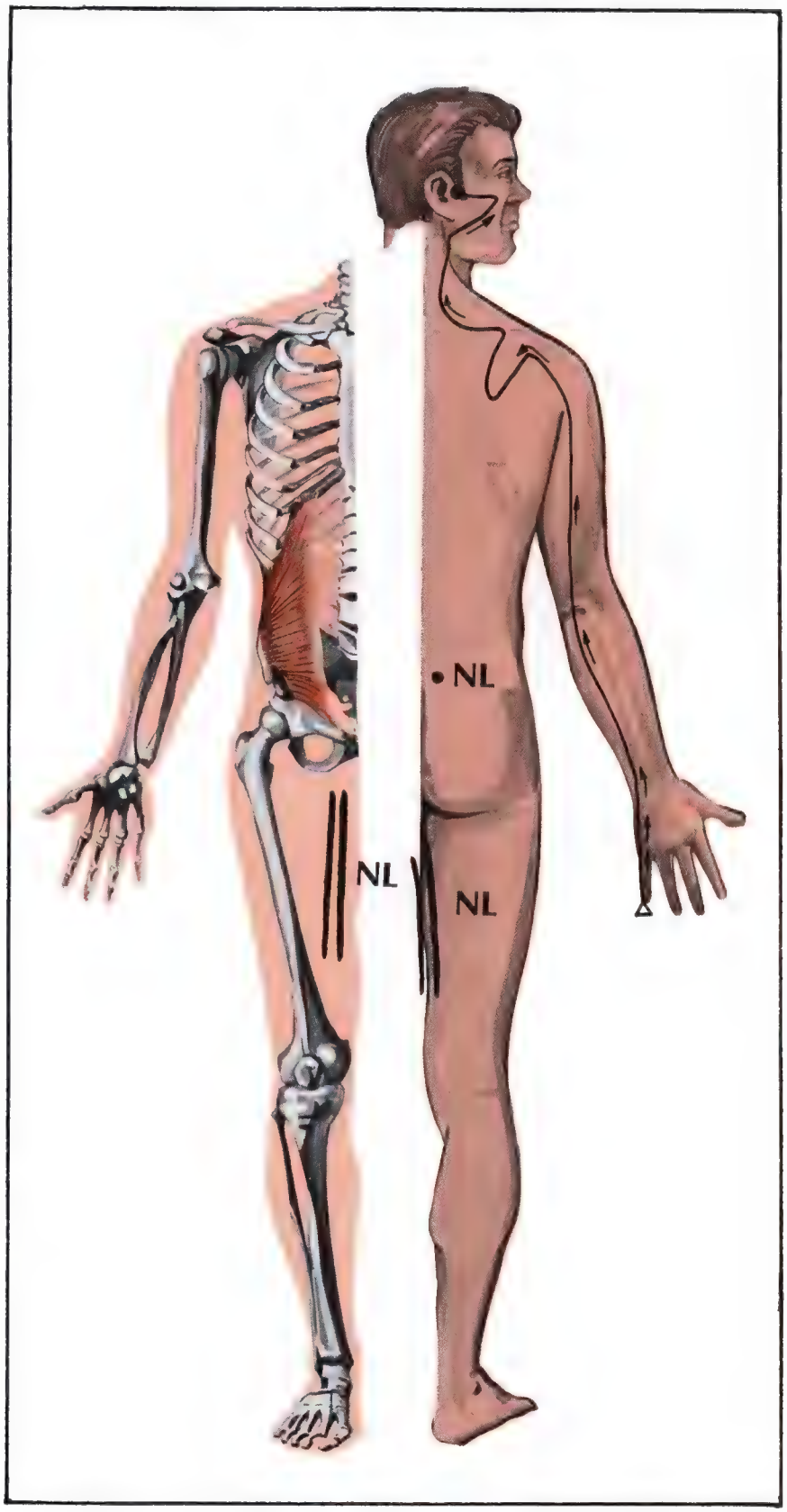

# ABDOMINAL MUSCLES - SMALL INTESTINE

## RECTUS ABDOMINIS

| | |
|---|---|
| STRUCTURAL WEAKNESS | Spondylolisthesis, weak back, neck problems, shoulder problems, jammed sagittal suture, internally rotated ilium, occasional shoulder problems. |
| INTERNAL MANIFESTATIONS | Respiratory problems, stomach aches, stomach pains, narcolepsy. |
| NEUROLYMPHATICS | **ANTERIOR:** Entire inside of upper one-half of thigh, medial one-fifth.<br>**POSTERIOR:** The posterior iliac crest. |
| MERIDIAN | Small Intestine. |
| NUTRITION | Vitamin E, natural intestinal extracts. |
| ASSOCIATED MUSCLES | Sacrospinalis, quadriceps, hamstrings, diaphragm, psoas, gluteus maximus, latissimus dorsi. |
| LAB TESTS | CBC, ESR, blood eosinophil count, sputum eosinophil count, erythrocyte count, sputum culture, stool culture for mucus and pus cells and blood, diagnex blue. |
| EXERCISE | Sit-ups, leg raises, standing alternating toe touch, side bends, lateral twists. |
| ACTION | Compresses abdominal contents, flexes pelvis and vertebral column, draws sternum toward pubis. |
| ORIGIN | Medial tendon from pubic symphysis, crest of the pubic bone. |
| INSERTION | Cartilages of the 5th, 6th & 7th ribs and xiphoid process. |
| NERVE SUPPLY | T-7 through T-12, intercostal nerves. |
| PALPATE | Anterior medial surface of abdomen. |

Photo illustrates bilateral muscle testing.

NV IN RESEARCH

# ABDOMINAL MUSCLES - SMALL INTESTINE

## RECTUS ABDOMINIS

**TO STRENGTHEN:**

**TO WEAKEN:**

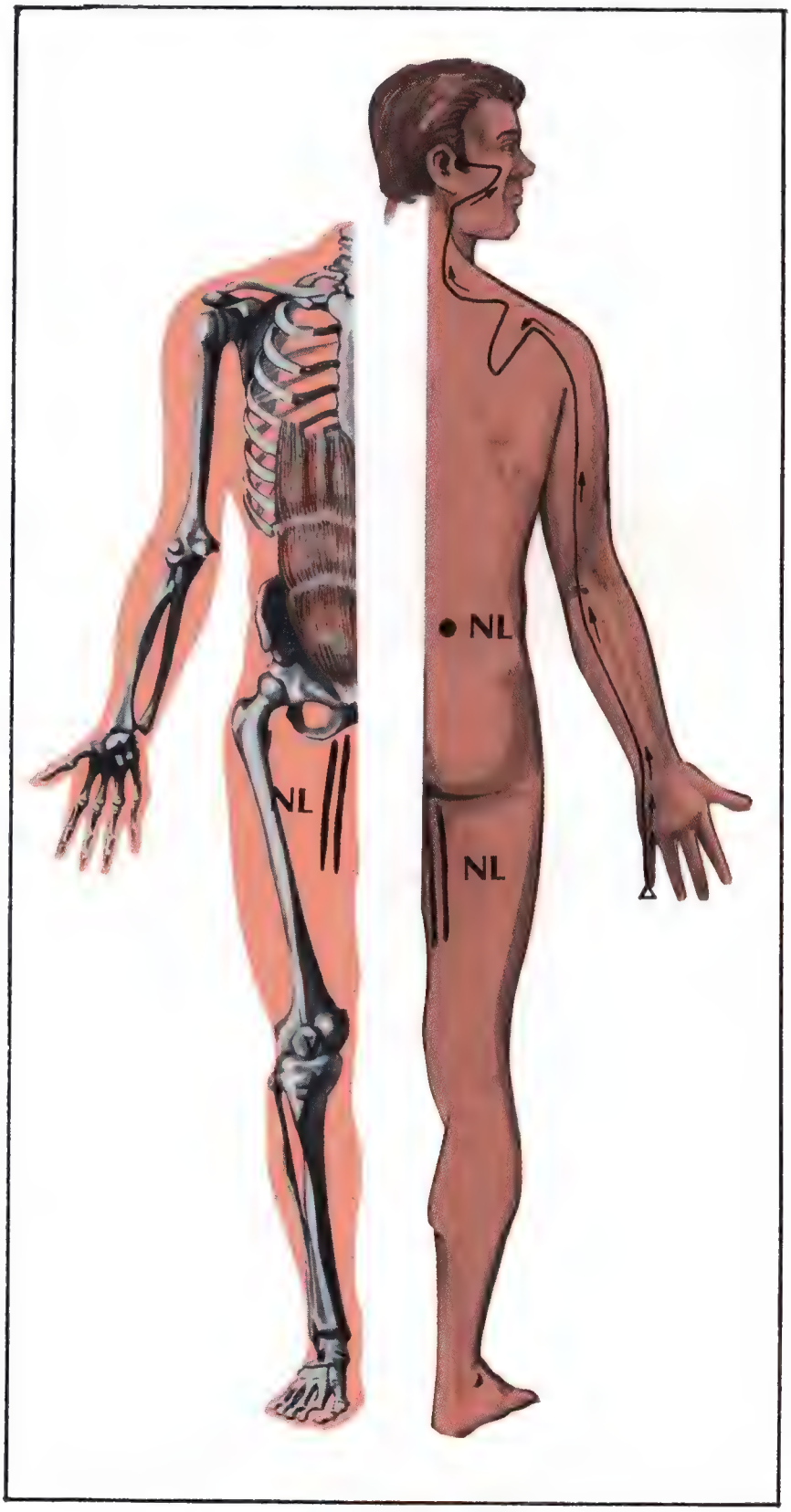

# ABDOMINAL MUSCLES - SMALL INTESTINE

## TRANSVERSUS ABDOMINIS

| | |
|---|---|
| STRUCTURAL WEAKNESS | Spondylolisthesis, weak back, neck problems, shoulder problems, jammed sagittal suture, internally rotated ilium, occasional shoulder problems. |
| INTERNAL MANIFESTATIONS | Respiratory problems, stomach aches, stomach pains, narcolepsy. |
| NEUROLYMPHATICS | **ANTERIOR:** Entire inside of upper one-half of thigh, medial one-fifth.<br>**POSTERIOR:** The posterior iliac crest. |
| MERIDIAN | Small Intestine. |
| NUTRITION | Vitamin E, natural intestinal extracts. |
| ASSOCIATED MUSCLES | Sacrospinalis, quadriceps, hamstrings, diaphragm, psoas, gluteus maximus, latissimus dorsi. |
| LAB TESTS | CBC, ESR, blood eosinophil count, sputum eosinophil count, erythrocyte count, sputum culture, stool culture for mucus and pus cells and blood, diagnex blue. |
| EXERCISE | Sit-ups, leg raises, standing alternating toe touch, side bends, lateral twists. |
| ACTION | Flattens the abdomen, active in forced expiration, compresses contents of abdomen. |
| ORIGIN | Inner surfaces of costal cartilages of lower six ribs, lumbodorsal fascia, anterior two-thirds of the inner lip of the iliac crest, lateral third of inguinal ligament. |
| INSERTION | Into the linea alba and crest of pubis. |
| NERVE SUPPLY | T-7 through T-12, iliohypogastric, ilio-inguinal. |
| PALPATE | Cannot be palpated. |

NV IN RESEARCH

# ABDOMINAL MUSCLES - SMALL INTESTINE

## TRANSVERSUS ABDOMINIS

**TO STRENGTHEN:**

**TO WEAKEN:**

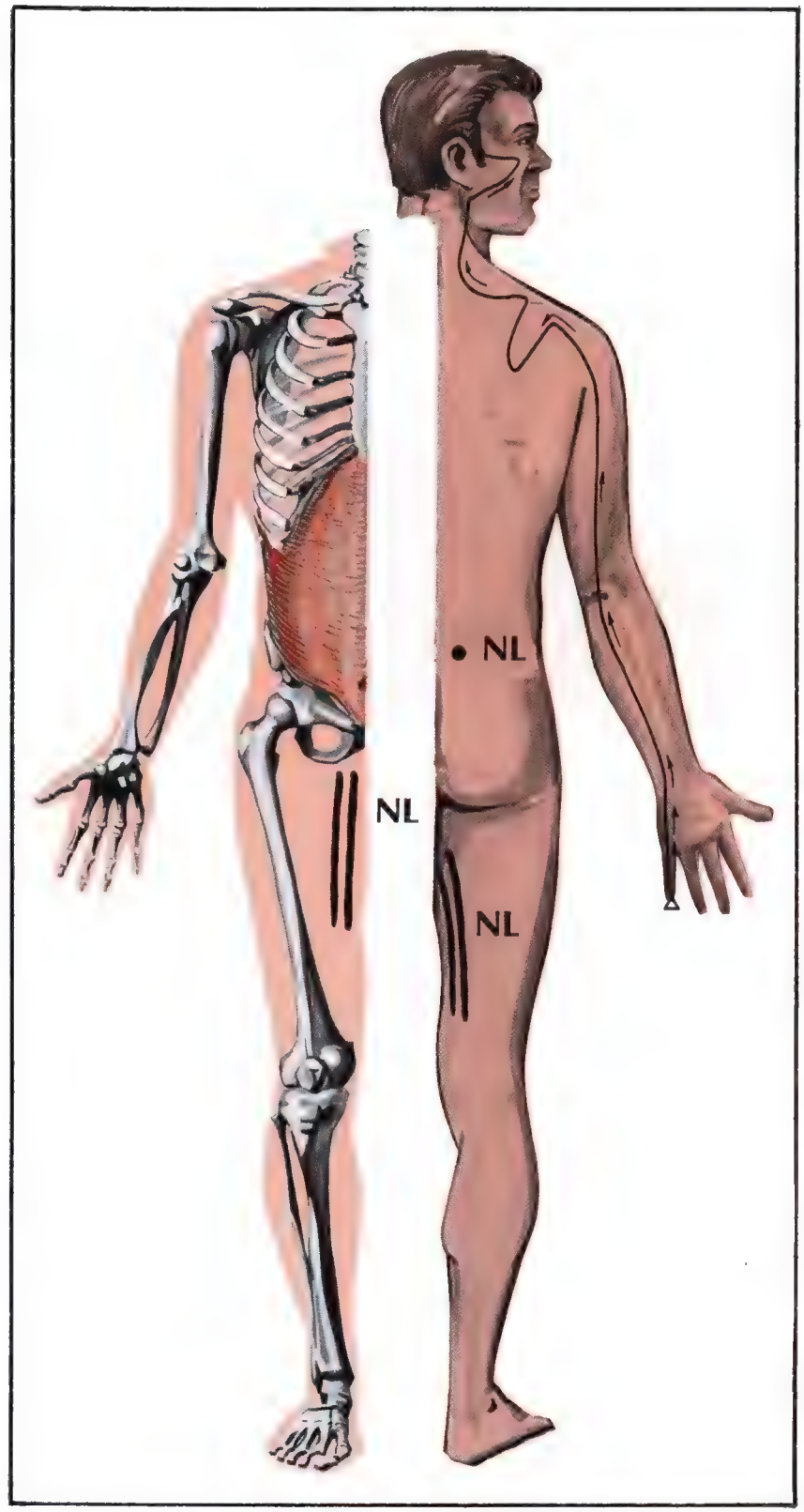

# ADDUCTORS - CLIMACTERIC
## ADDUCTOR BREVIS

| | |
|---|---|
| STRUCTURAL WEAKNESS | Pelvic tilt with the pelvis low on the side of the weakness, bowed legs, elbow pain, stiff shoulders. |
| INTERNAL MANIFESTATIONS | Reproductive organ disorders, hormone imbalances, menopausal problems. |
| NEUROLYMPHATICS | **ANTERIOR:** Behind the nipple on the chest wall, between 4th & 5th ribs.<br>**POSTERIOR:** Just below the points of the shoulder blades, between 8th & 9th ribs. |
| MERIDIAN | Circulation Sex. |
| NUTRITION | Vitamin E, wheat germ, natural endocrine extracts. |
| ASSOCIATED MUSCLES | Tensor fascia lata, hamstrings. |
| LAB TESTS | CBC, neutrophil count, ESR, urine erythrocytes, pus cells, total and fractionated estrogens, 17-ketosteroids, sperm count, T-3, T-4, adrenal cortical function test. |
| EXERCISE | Horseback riding, jumping jacks, swimming, jogging. |
| ACTION | Adducts and assists in flexing and medially rotating the hip joint. |
| ORIGIN | Outer surface of the inferior ramus of the pubis. |
| INSERTION | The line leading from lesser trochanter to linea aspera and into upper half of the linea aspera. |
| NERVE SUPPLY | Obutrator (usually from its anterior division), L-2, 3 & 4. |
| PALPATE | Cannot be palpated. |

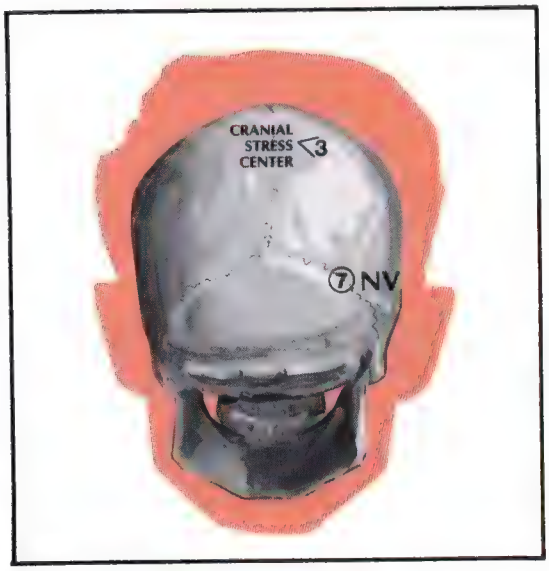

# ADDUCTORS - CLIMACTERIC
## ADDUCTOR BREVIS

**TO STRENGTHEN:**

**TO WEAKEN:**

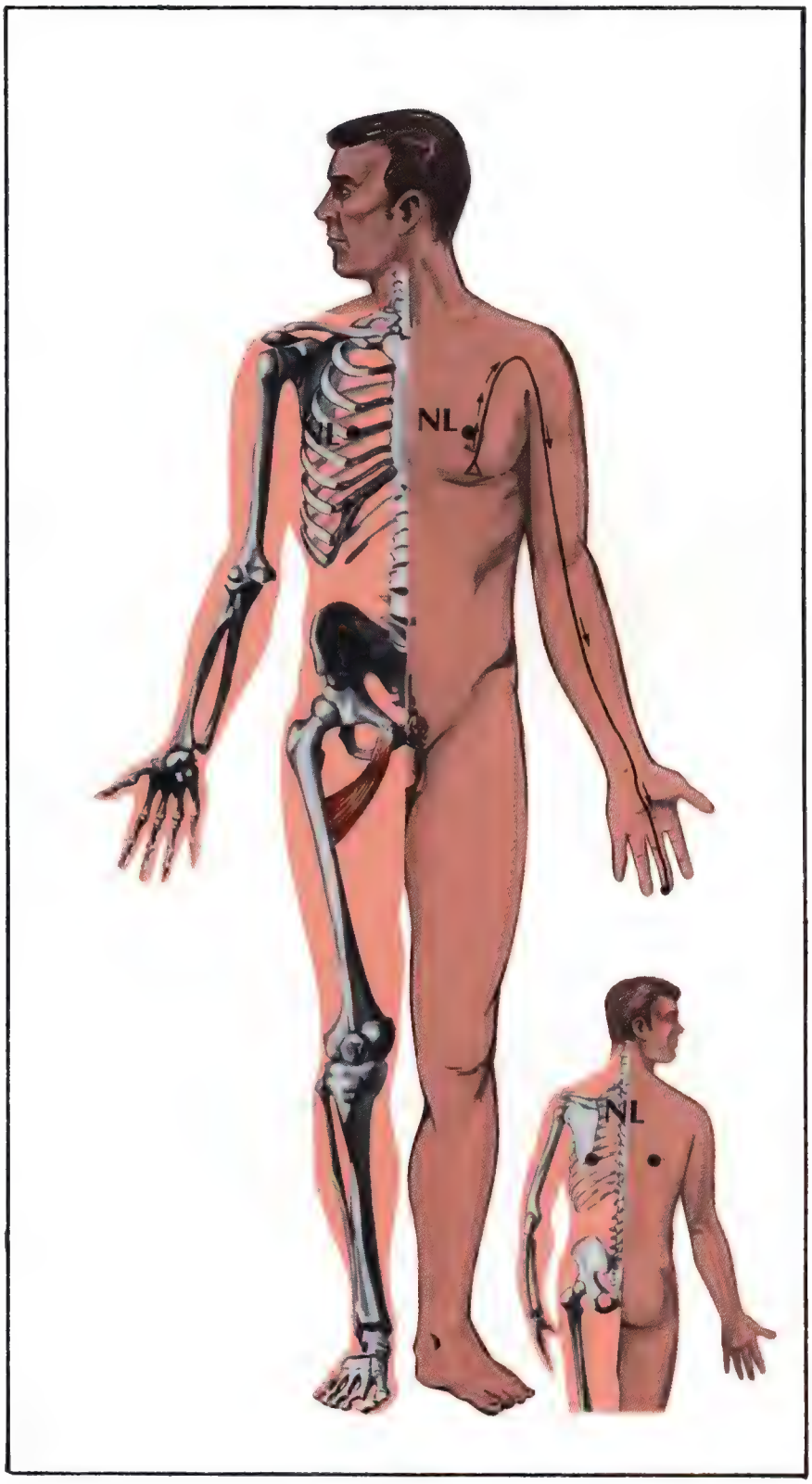

# ADDUCTORS - CLIMACTERIC

## ADDUCTOR LONGUS

| | |
|---|---|
| STRUCTURAL WEAKNESS | Pelvic tilt with the pelvis low on the side of the weakness, bowed legs, elbow pain, stiff shoulders. |
| INTERNAL MANIFESTATIONS | Reproductive organ disorders, hormone imbalances, menopausal problems. |
| NEUROLYMPHATICS | **ANTERIOR:** Behind the nipple on the chest wall, between 4th & 5th ribs.<br>**POSTERIOR:** Just below the points of the shoulder blades, between 8th & 9th ribs. |
| MERIDIAN | Circulation Sex. |
| NUTRITION | Vitamin E, wheat germ, natural endocrine extracts. |
| ASSOCIATED MUSCLES | Tensor fascia lata, hamstrings. |
| LAB TESTS | CBC, neutrophil count, ESR, urine erythrocytes, pus cells, total & fractionated estrogens, 17-ketosteroids, sperm count, T-3, T-4, adrenal cortical function test. |
| EXERCISE | Horseback riding, jumping jacks, swimming, jogging. |
| ACTION | Adducts and flexes the hip and rotates thigh medially. |
| ORIGIN | Front of pubis at the angle between the junction of the crest and the symphysis. |
| INSERTION | Middle third of linea aspera. |
| NERVE SUPPLY | Anterior division of obturator, L-2, 3 & 4. |
| PALPATE | Just below the pubic bone. |

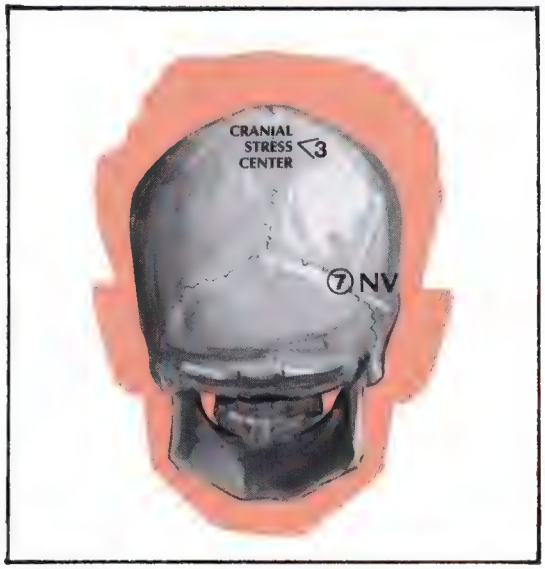

# ADDUCTORS - CLIMACTERIC
## ADDUCTOR LONGUS

**TO STRENGTHEN:**

**TO WEAKEN:**

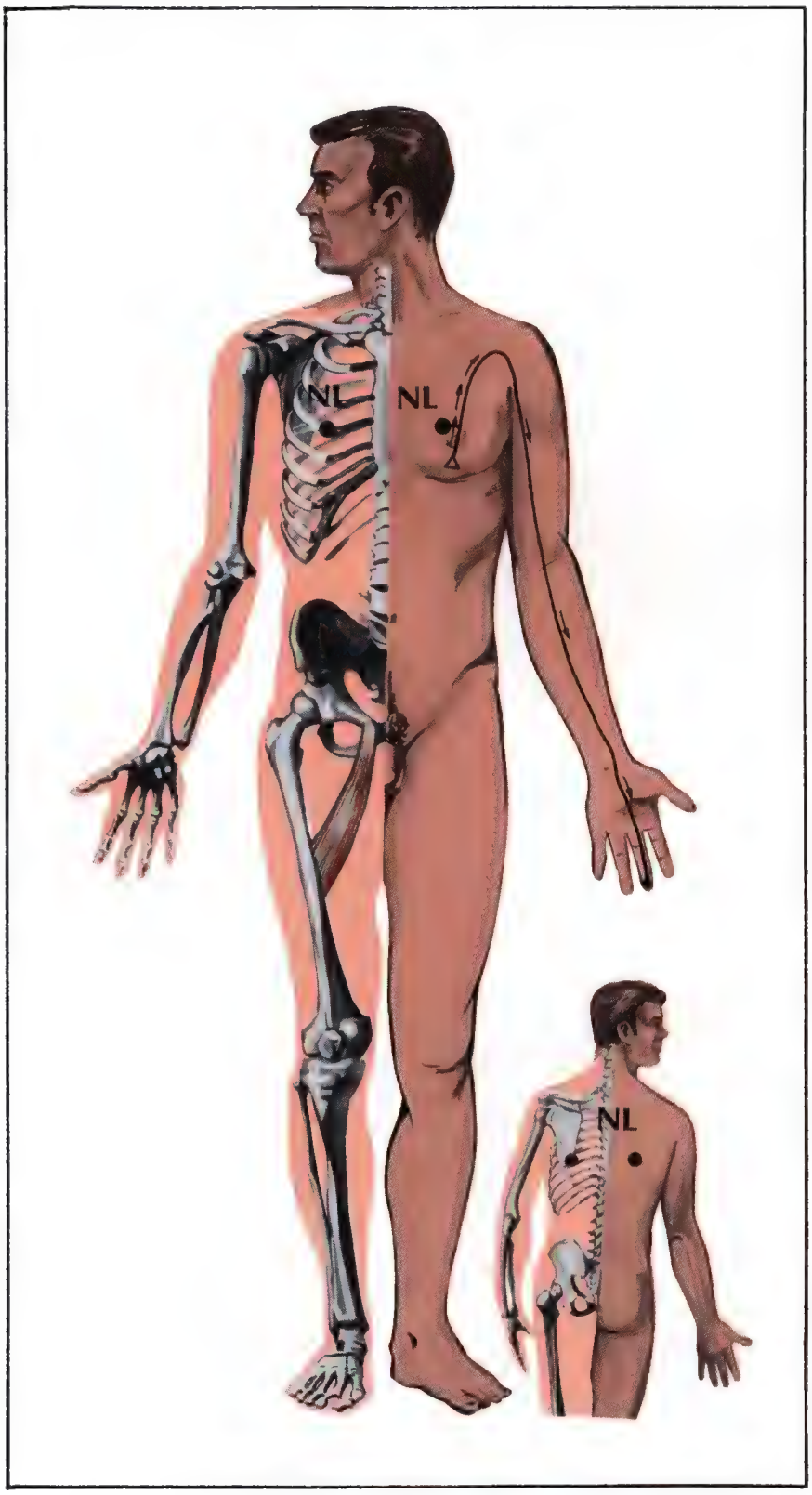

# ADDUCTORS - CLIMACTERIC

## ADDUCTOR MAGNUS

| | |
|---|---|
| **STRUCTURAL WEAKNESS** | Pelvic tilt with the pelvis low on the side of the weakness, bowed legs, elbow pain, stiff shoulders. |
| **INTERNAL MANIFESTATIONS** | Reproductive organ disorders, hormone imbalances, menopausal problems. |
| **NEUROLYMPHATICS** | **ANTERIOR:** Behind the nipple on the chest wall, between 4th & 5th ribs.<br>**POSTERIOR:** Just below the points of the shoulder blades, between 8th & 9th ribs. |
| **MERIDIAN** | Circulation Sex. |
| **NUTRITION** | Vitamin E, wheat germ, natural endocrine extracts. |
| **ASSOCIATED MUSCLES** | Tensor fascia lata, hamstrings. |
| **LAB TESTS** | CBC, neutrophil count, ESR, urine erythrocytes, pus cells, total and fractionated estrogens, 17-ketosteroids, sperm count, T-3, T-4, adrenal cortical function test. |
| **EXERCISE** | Horseback riding, jumping jacks, swimming, jogging. |
| **ACTION** | Adduction of the thigh.<br>**NOTE:** Upper portion rotates thigh medially and flexes it.<br>Lower portion extends and rotates it laterally. |
| **ORIGIN** | Inferior ramus of pubis, inferior ramus of ischium and outer margin of inferior part of tuberosity of ischium. |
| **INSERTION** | Entire length of the linea aspera and the inner condyloid ridge. |
| **NERVE SUPPLY** | Posterior division of obturator and sciatic, L-2, 3, 4, 5 & S-1. |
| **PALPATE** | Medial, posterior surface of femur. |

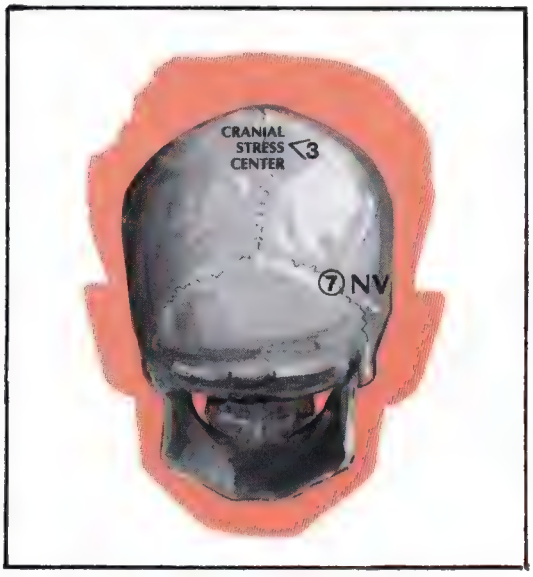

# ADDUCTORS - CLIMACTERIC
## ADDUCTOR MAGNUS

**TO STRENGTHEN:**

**TO WEAKEN:**

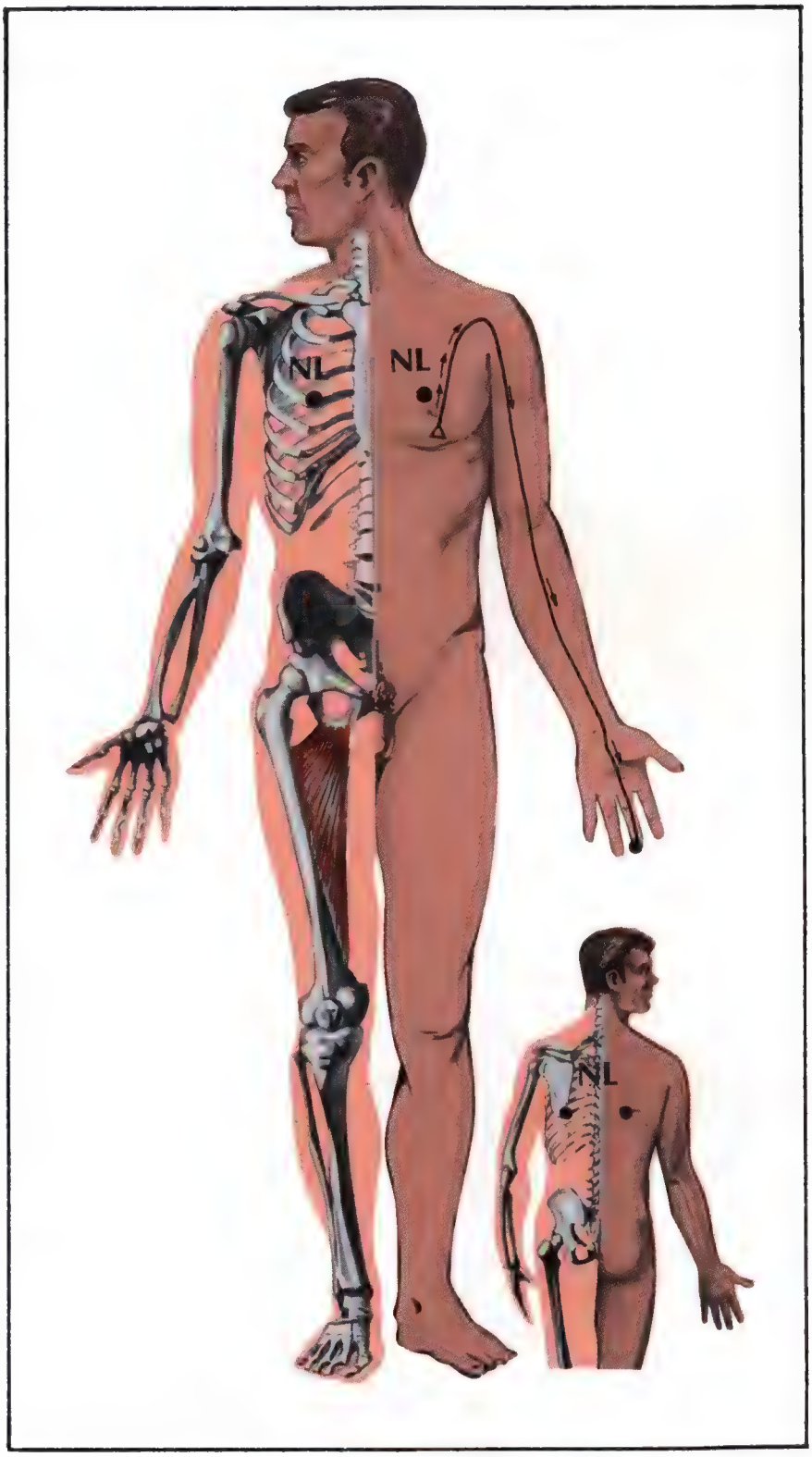

# ADDUCTORS - CLIMACTERIC

## PECTINEUS ADDUCTOR

| | |
|---|---|
| STRUCTURAL WEAKNESS | Pelvic tilt with the pelvis low on the side of the weakness, bowed legs, elbow pain, stiff shoulders. |
| INTERNAL MANIFESTATIONS | Reproductive organ disorders, hormone imbalances, menopausal problems. |
| NEUROLYMPHATICS | **ANTERIOR:** Behind the nipple on the chest wall, between 4th & 5th ribs.<br>**POSTERIOR:** Just below the points of the shoulder blades, between 8th & 9th ribs. |
| MERIDIAN | Circulation Sex. |
| NUTRITION | Vitamin E, wheat germ, natural endocrine extracts. |
| ASSOCIATED MUSCLES | Tensor fascia lata, hamstrings. |
| LAB TESTS | CBC, neutrophil count, ESR, urine erythrocytes, pus cells, total and fractionated estrogens, 17-ketosteroids, sperm count, T-3, T-4, adrenal cortical function test. |
| EXERCISE | Horseback riding, jumping jacks, swimming, jogging. |
| ACTION | Adducts, medially rotates and flexes the hip. |
| ORIGIN | Pectineal line on superior ramus of pubis between iliopectineal eminence and pubic tubercle. |
| INSERTION | Into a rough line leading from lesser trochanter to linea aspera. |
| NERVE SUPPLY | Femoral and Obturator Nerve, L-2, 3 & 4. |
| PALPATE | Just below pubic bone on medial side, difficult to distinguish from adductor longus. |

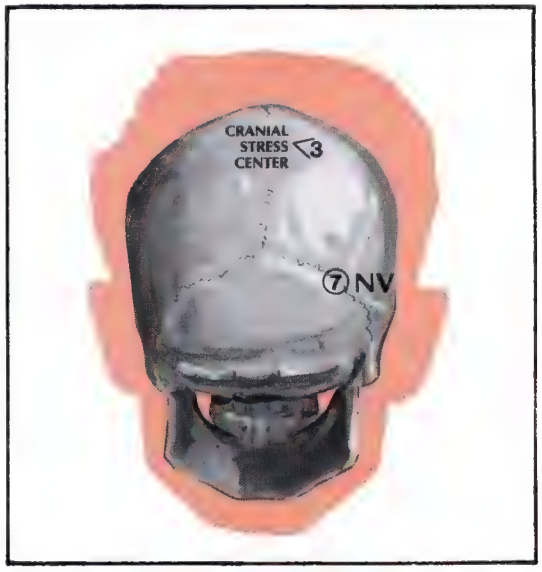

# ADDUCTORS - CLIMACTERIC
## PECTINEUS ADDUCTOR

**TO STRENGTHEN:**

**TO WEAKEN:**

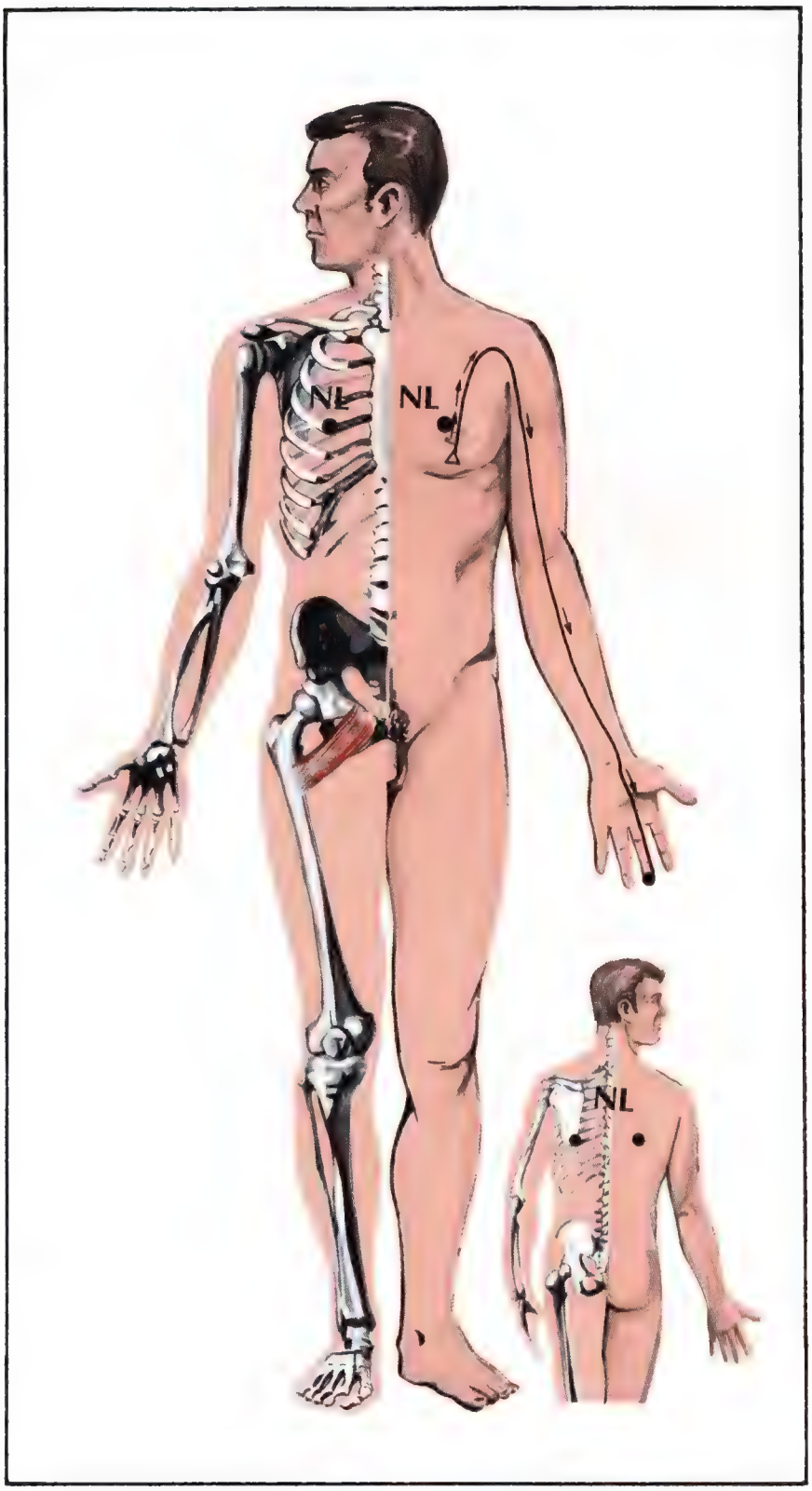

# ANCONEUS - PANCREAS

| | |
|---|---|
| STRUCTURAL WEAKNESS | Elbow and shoulder problems. |
| INTERNAL MANIFESTATIONS | Carbohydrate sensitivity. |
| NEUROLYMPHATICS | Humeral head, posterior surface. |
| MERIDIAN | Spleen. |
| NUTRITION | Vitamin A, Vitamin F, betaine hydrochloride concentrates. |
| ASSOCIATED MUSCLES | Latissimus dorsi, rhomboids, levator scapulae. |
| LAB TESTS | 5-hour glucose tolerance, T-3, T-4, serum amylase. |
| EXERCISE | Dips on parallel bar, push-ups, pressing a barbell or dumbell upward. |
| ACTION | Extends the forearm, assists the triceps. |
| ORIGIN | Back part of the lateral epicondyle of the humerus, posterior surface. |
| INSERTION | Lateral side of the olecranon, upper one-fourth of posterior surface of ulna. |
| NERVE SUPPLY | Radial, C-7 & 8. |
| PALPATE | Posterior lateral aspect of the olecranon process. |

CSC IN RESEARCH
NV IN RESEARCH

# ANCONEUS - PANCREAS

**TO STRENGTHEN:**

**TO WEAKEN:**

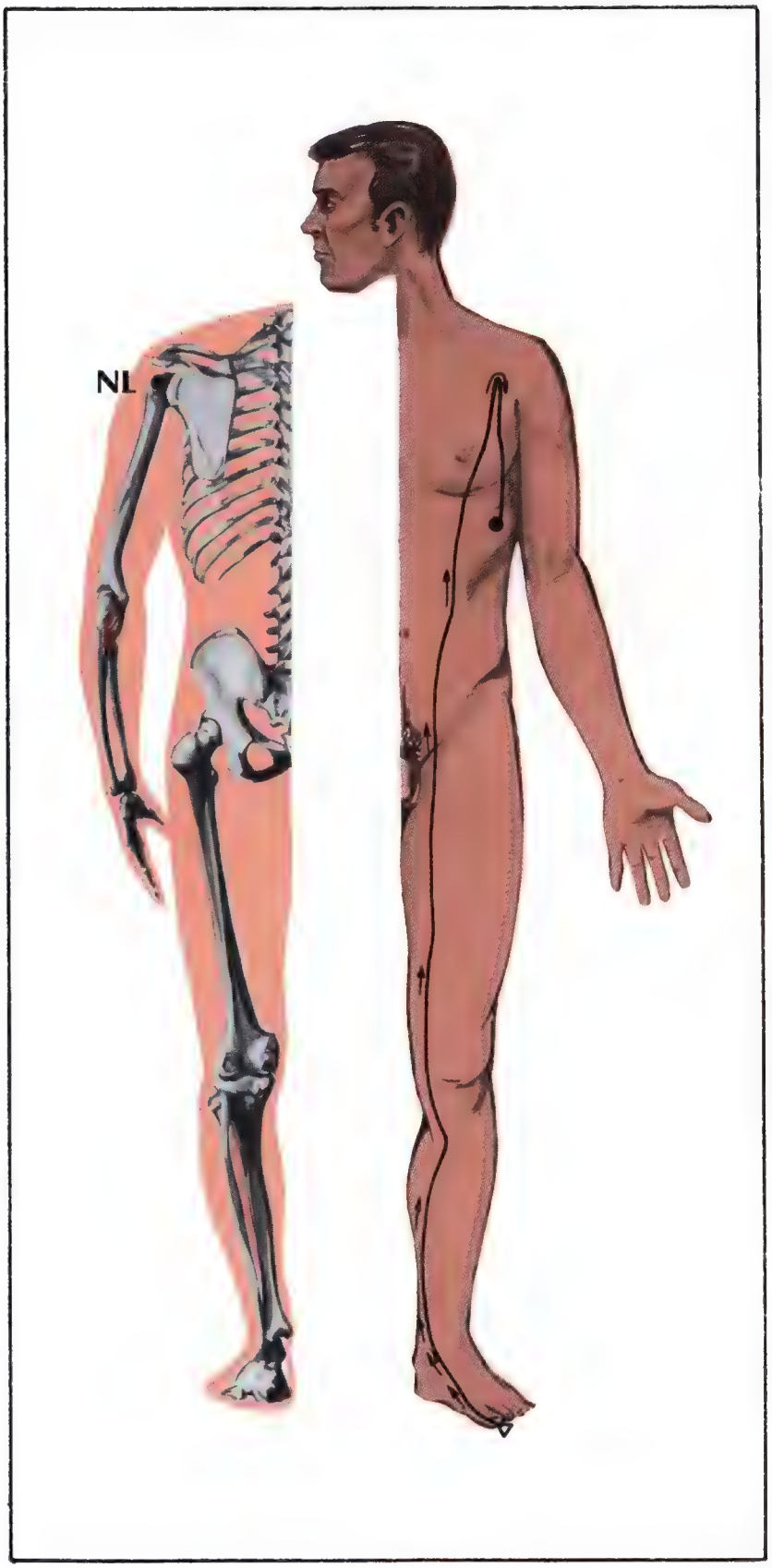

# BICEPS BRACHII - STOMACH

| | |
|---|---|
| STRUCTURAL WEAKNESS | Shoulder problems, IN RESEARCH. |
| INTERNAL MANIFESTATIONS | Stomach disorders, possible carbohydrate sensitivity, IN RESEARCH. |
| NEUROLYMPHATICS | **ANTERIOR:** Approximately 3-3½" from the sternum between the 2nd and 3rd ribs.<br>**POSTERIOR:** Lamina pedicle junction on C-2, bilaterally. |
| MERIDIAN | Stomach. |
| NUTRITION | Betaine hydrochloride. |
| ASSOCIATED MUSCLES | Rhomboids, neck flexors, teres major, teres minor, pectoralis major clavicular, latissimus dorsi. |
| LAB TESTS | Diagnex blue, pH of saliva and bowel, CBC. |
| EXERCISE | Flexion of forearm with weights, push-ups, chinning. |
| ACTION | Flexes the arm and forearm, supinates the hand. |
| ORIGIN | **SHORT HEAD:** From the tip or coracoid process of scapula.<br>**LONG HEAD:** From the supraglenoid tuberosity at upper margin of glenoid cavity of scapula. |
| INSERTION | Radial tuberosity and by the lacertus fibers to the forearm flexors. |
| NERVE SUPPLY | Musculocutaneous, C-5 & 6. |
| PALPATE | Anterior surface of humerus. |

NV IN RESEARCH

# BICEPS BRACHII - STOMACH

**TO STRENGTHEN:**

**TO WEAKEN:**

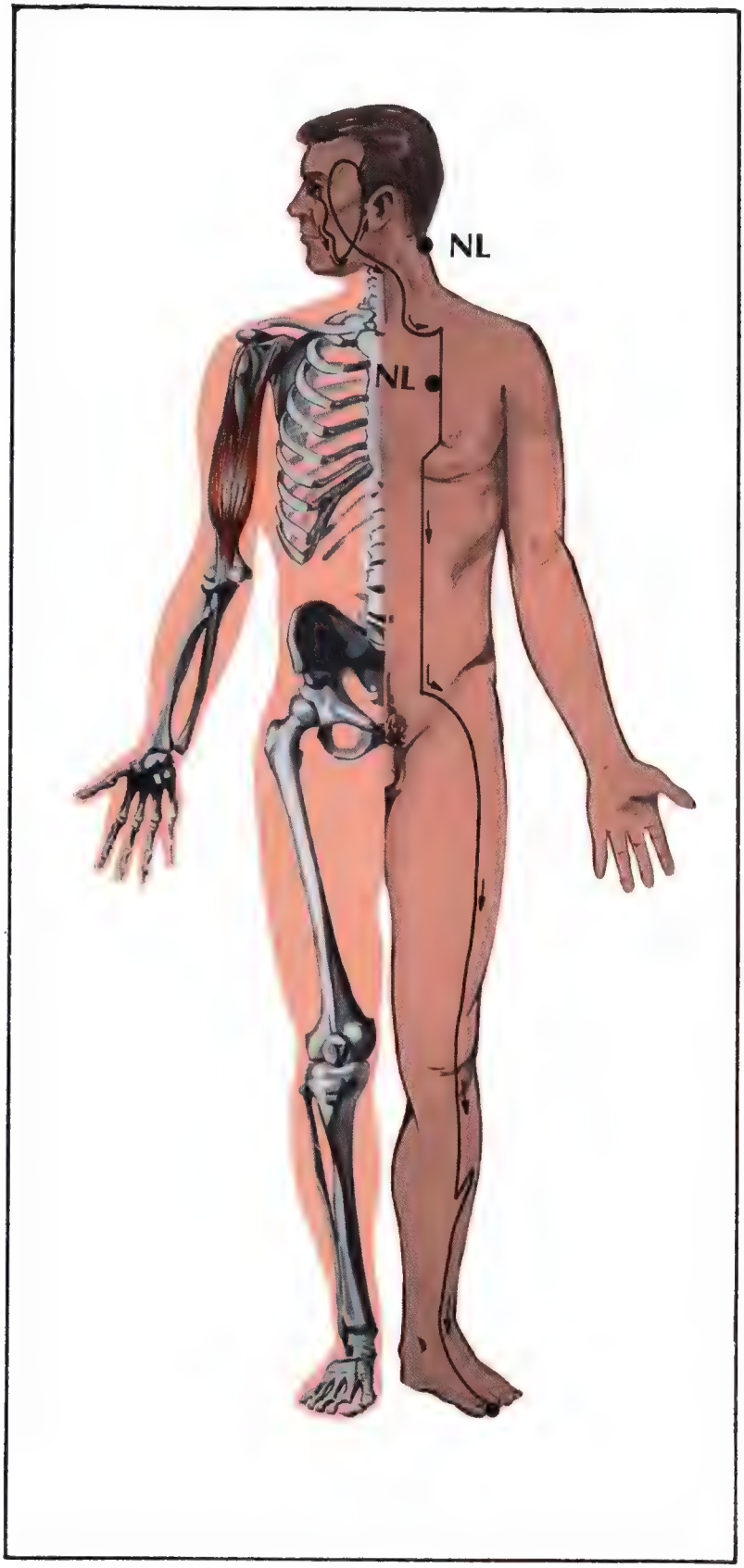

# BRACHIORADIALIS - STOMACH

| | |
|---|---|
| STRUCTURAL WEAKNESS | Shoulder problems, IN RESEARCH. |
| INTERNAL MANIFESTATIONS | Stomach disorders, possible carbohydrate sensitivity, IN RESEARCH. |
| NEUROLYMPHATICS | **ANTERIOR:** Entire pectoralis major clavicular muscle.<br>**POSTERIOR:** IN RESEARCH. |
| MERIDIAN | Stomach. |
| NUTRITION | Betaine hydrochloride. |
| ASSOCIATED MUSCLES | Rhomboids, neck flexors, teres major, teres minor, pectoralis major clavicular, latissimus dorsi. |
| LAB TESTS | Diagnex blue, pH of saliva and bowel, CBC. |
| EXERCISE | Flexion of forearm with weights, push-ups, chinning. |
| ACTION | Helps biceps flex forearm, assists in pronation and supination. |
| ORIGIN | Proximal two-thirds of lateral supracondylar ridge of humerus, lateral intermuscular septum. |
| INSERTION | Lateral side of base of styloid process of radius. |
| NERVE SUPPLY | Radial, C-5 & 6. |
| PALPATE | Lateral anterior side of forearm. |

NV IN RESEARCH

CSC IN RESEARCH

# BRACHIORADIALIS - STOMACH

TO STRENGTHEN:

TO WEAKEN:

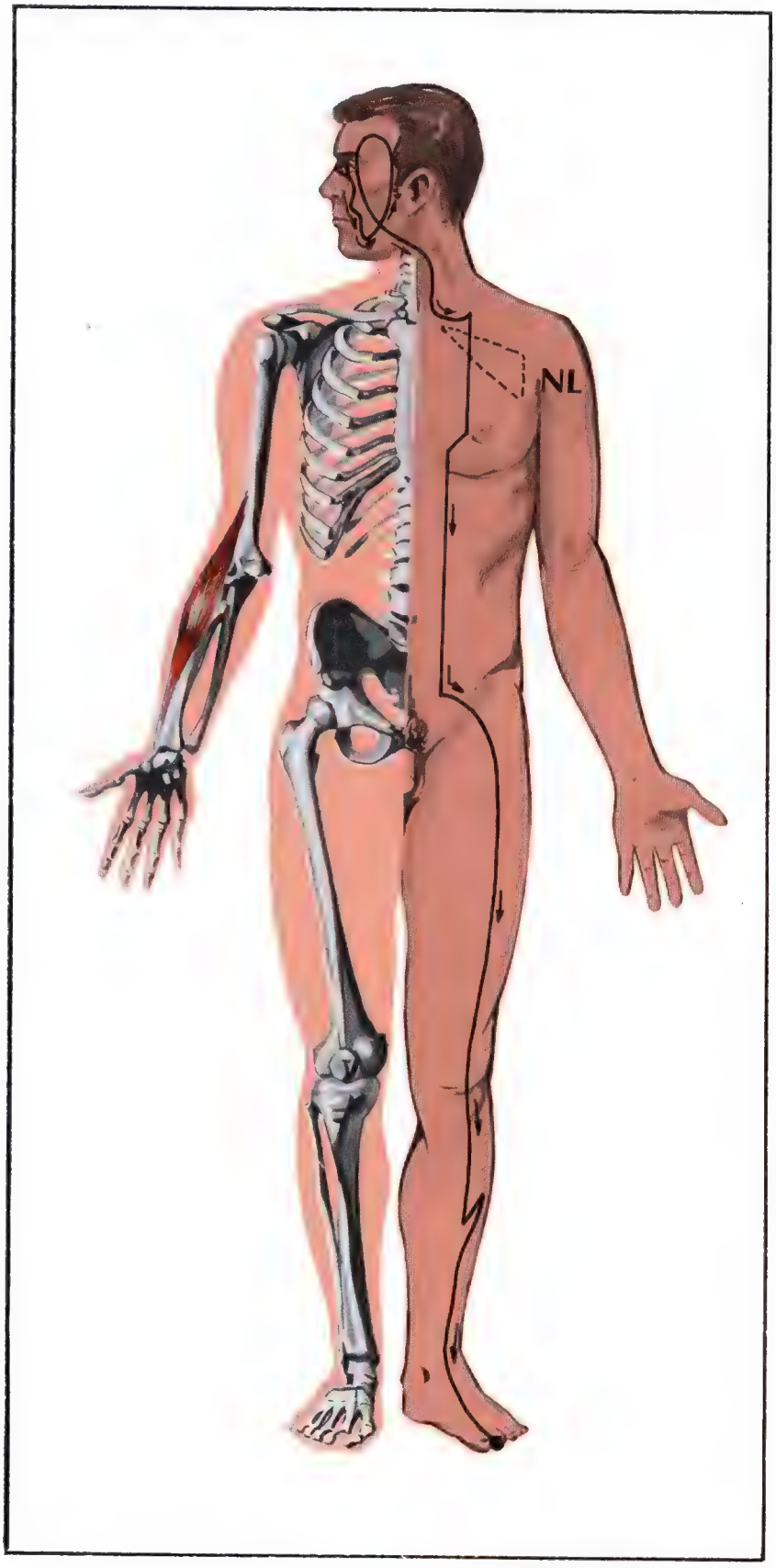

# CORACOBRACHIALIS - LUNGS

| | |
|---|---|
| STRUCTURAL WEAKNESS | Shoulder problems and arm fatigue. This weakness is often pronounced when combing the hair. |
| INTERNAL MANIFESTATIONS | Nervousness, insomnia, chronic cough and related lung conditions. |
| NEUROLYMPHATICS | **ANTERIOR:** Between the 3rd through the 5th ribs, adjacent to the sternum.<br>**POSTERIOR:** Interspinous-transverse space of T-3 & T-4. |
| MERIDIAN | Lung. |
| NUTRITION | Lung cytotropic extract, Vitamin C. |
| ASSOCIATED MUSCLES | Deltoids, anterior serratus, diaphragm. |
| LAB TESTS | CBC, HGB, hematocrit, ESR, sputum culture. |
| EXERCISE | Dips on parallel bars, raising the arms anteriorly and laterally above the head with weights. |
| ACTION | Flexes and adducts the arm. |
| ORIGIN | Tip of the coracoid process of the scapula. |
| INSERTION | Impression at middle of medial border of body of humerus. |
| NERVE SUPPLY | Musculocutaneous nerve, C-6 & 7. |
| PALPATE | Difficult to palpate, except on extremely thin individuals. |

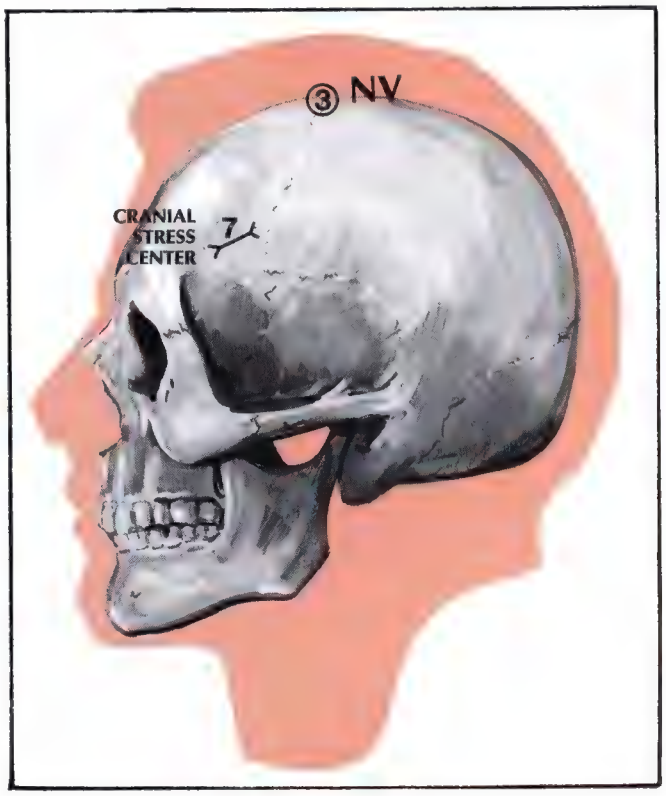

# CORACOBRACHIALIS - LUNGS

**TO STRENGTHEN:**

**TO WEAKEN:**

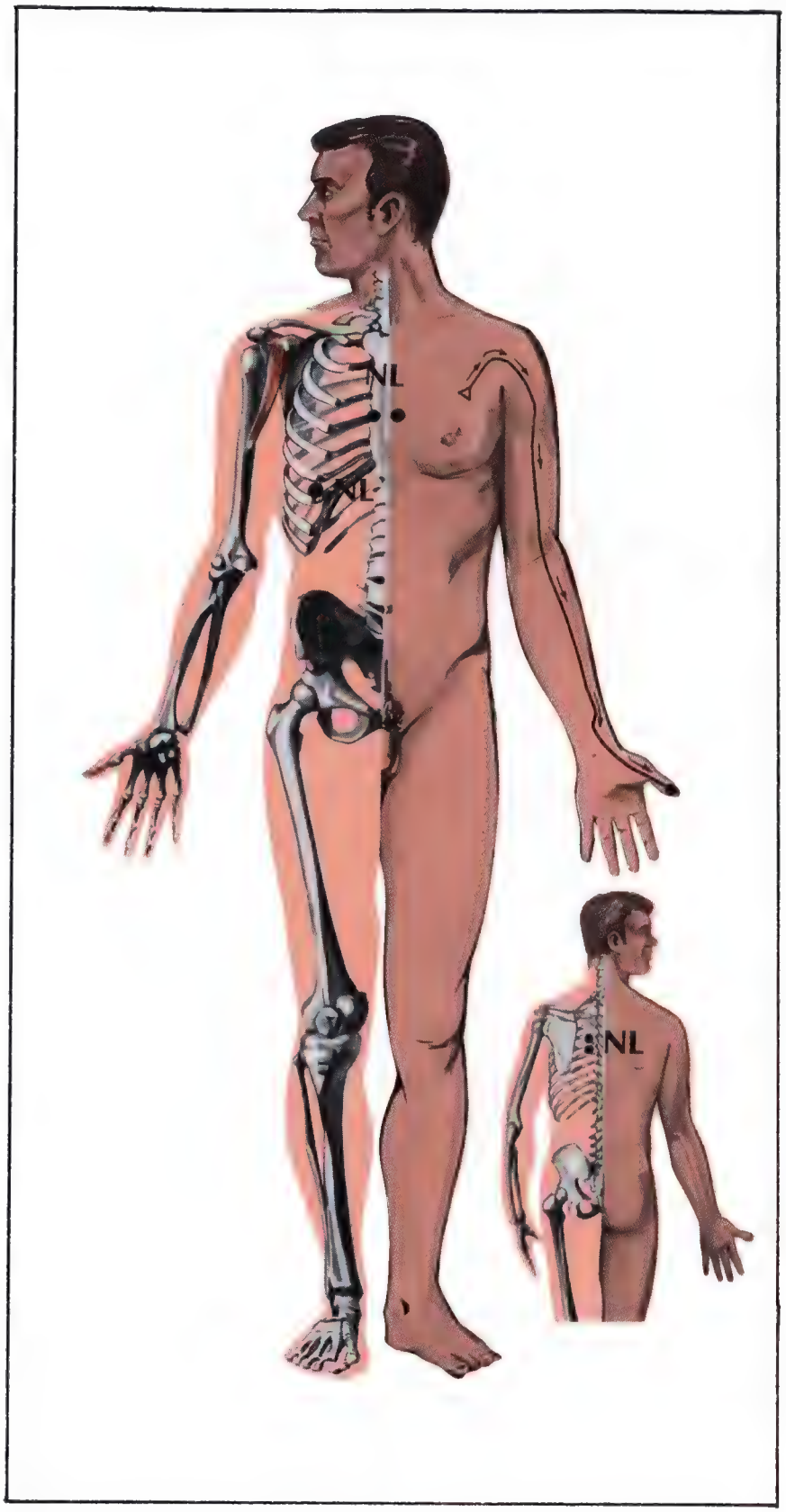

# DELTOIDS - LUNGS

| | |
|---|---|
| STRUCTURAL WEAKNESS | Inability to lift the arm, shoulder cramps, rib fixation. If the medial head is bilaterally weak, it indicates a cervical/dorsal junction fixation. |
| INTERNAL MANIFESTATIONS | Bronchitis, pleurisy, pneumonia, congestion, flu. |
| NEUROLYMPHATICS | **ANTERIOR:** Intercostal space of the 3rd through the 5th ribs, adjacent to the sternum.<br>**POSTERIOR:** Interspinous-transverse space between T-3 & T-4. |
| MERIDIAN | Lung. |
| NUTRITION | Vitamin C, lung cytotropic extract. |
| ASSOCIATED MUSCLES | Teres major, supraspinatus, pectoralis major clavicular, pectoralis major sternal, levator costalis. |
| LAB TESTS | CBC, blood erythrocyte count, bacteria in sputum and culture. |
| EXERCISE | Dips, dumbell or barbell extensions above the head. |
| ACTION | Abducts the arm. |
| ORIGIN | **ANTERIOR HEAD:** Anterior border and superior surface of the lateral one-third of the clavicle.<br>**MEDIAL HEAD:** Superior surface and lateral margin of the acromion of scapula.<br>**POSTERIOR HEAD:** Inferior lip of the posterior border of the spine of scapula. |
| INSERTION | Into the deltoid tuberosity on the middle of the lateral side of the humerus. |
| NERVE SUPPLY | Axillary, C-5 & 6. |
| PALPATE | Over the head of the humerus. |

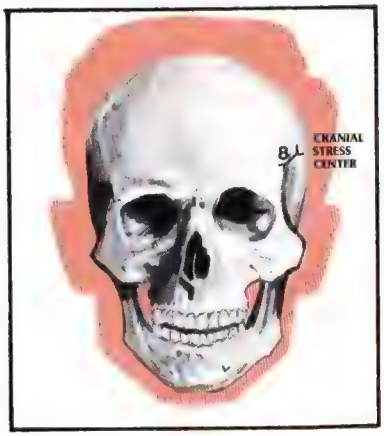


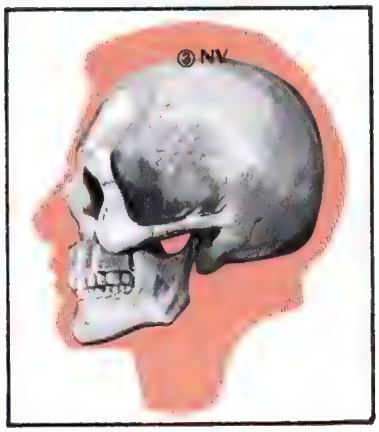

# DELTOIDS - LUNGS

**TO STRENGTHEN:**

**TO WEAKEN:**

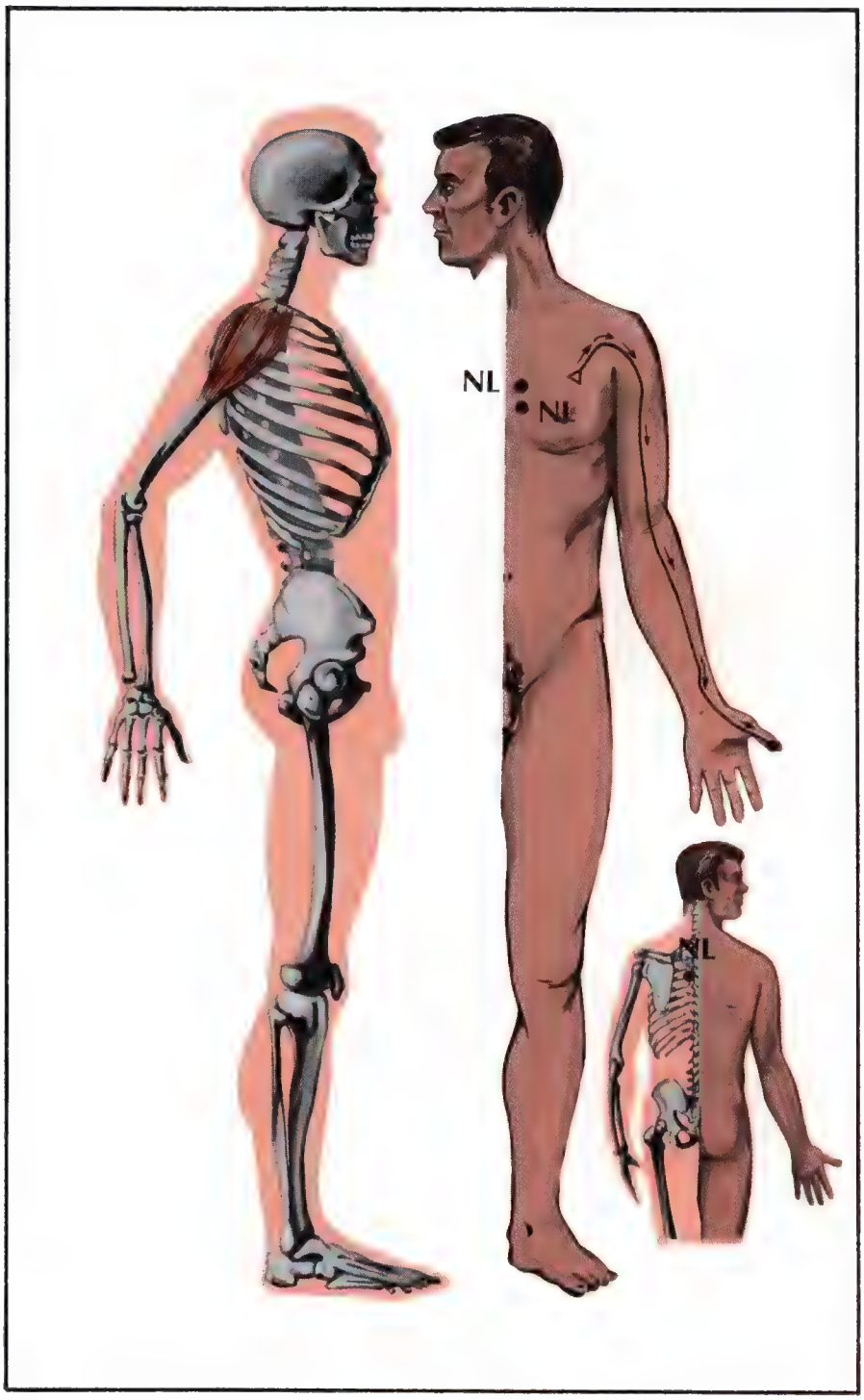

# DIAPHRAGM

| | |
|---|---|
| STRUCTURAL WEAKNESS | Rib fixation, abdominal weakness. |
| INTERNAL MANIFESTATIONS | Hiatal hernia, emphysema, bronchiectasis. |
| NEUROLYMPHATICS | **ANTERIOR:** The entire sternal area.<br>**POSTERIOR:** Junction of the 10th rib and dorsal vertebrae — right side only. |
| MERIDIAN | IN RESEARCH. Possibly conception vessel. |
| NUTRITION | Vitamin C. |
| ASSOCIATED MUSCLES | Teres minor, psoas, abdominals, neck muscles. |
| LAB TESTS | IN RESEARCH. |
| EXERCISE | Diaphragmatic abdominal breathing exercises. |
| ACTION | Respiration, contraction, increases capacity of the thoracic cavity. |
| ORIGIN | This muscle has three origins: sternal, costal and lumbar. It arises from the whole of the inner circumference of the thorax, being attached to the xiphoid of the sternum, costal cartilages of the lower 6 ribs, and by tendinous arches from the tip of the last rib to the transverse processes and body of the first lumbar vertebrae. Posteriorly it is anchored to the vertebral column by two muscular slips or crura, the right crus attaching to the bodies of upper three lumbars and the left to the bodies of the upper two lumbars. |
| INSERTION | Muscular fibers arch upward and inward to end in the tendinous fibers which form the central tendon. |
| NERVE SUPPLY | Phrenic, C-3, 4 & 5. |
| PALPATE | Not palpable. |



Diaphragm is tested by asking patient to hold breath for 40 seconds. Less than 40 seconds holding time indicates diaphragmatic disorder.

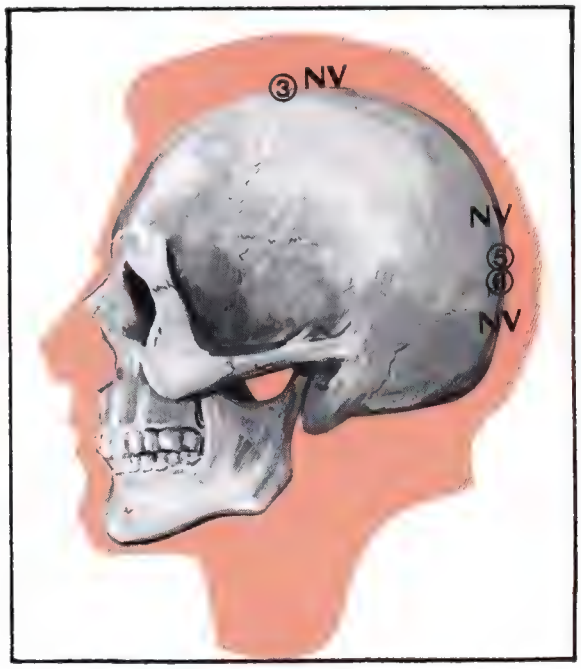


CSC IN RESEARCH

# DIAPHRAGM

**TO STRENGTHEN:**

**TO WEAKEN:**

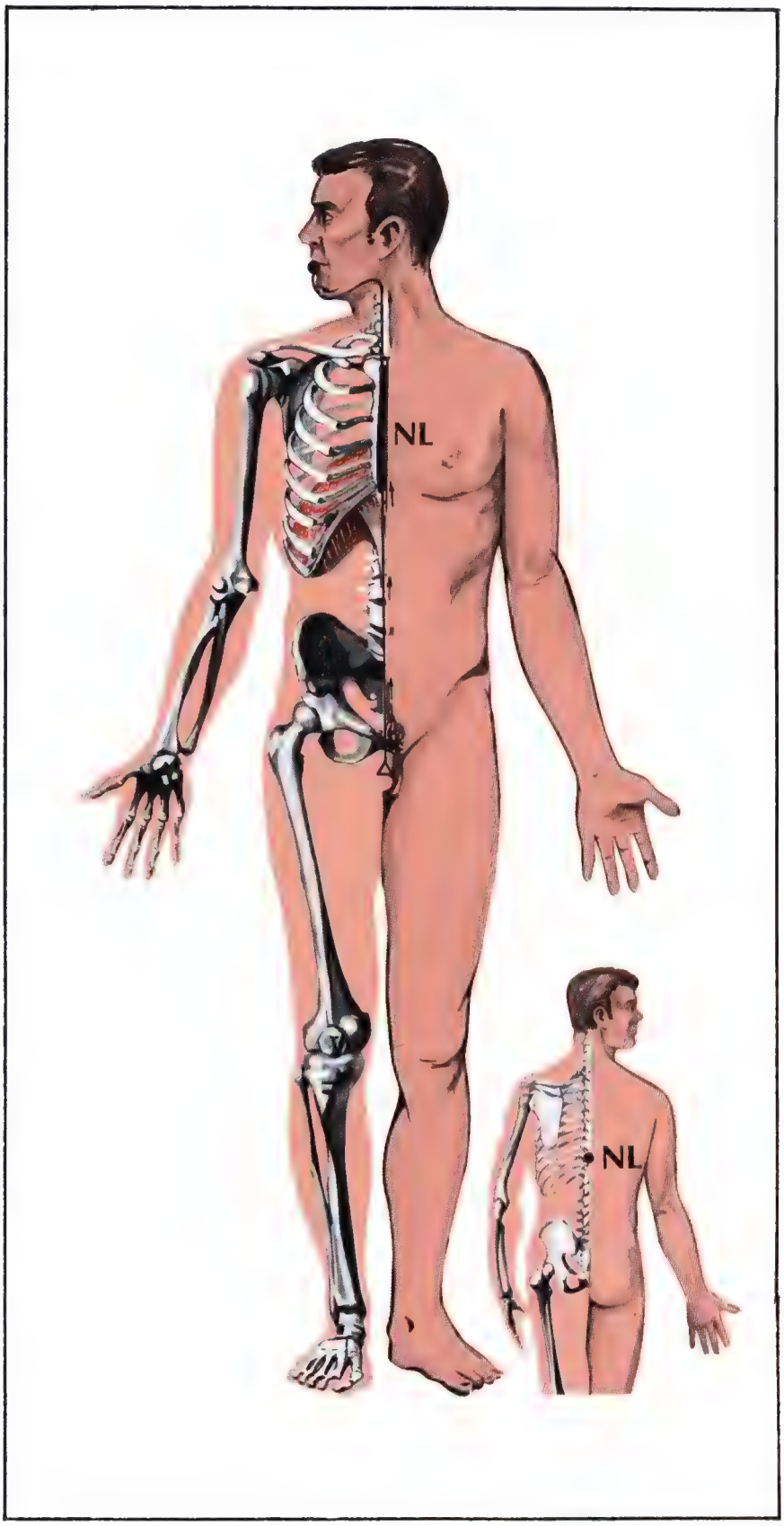

# GASTROCNEMIUS - ADRENALS

| | |
|---|---|
| **STRUCTURAL WEAKNESS** | Pain in the calves of the legs, posterior ilium, inability to rise upon the toes, knee problems. |
| **INTERNAL MANIFESTATIONS** | Allergies, asthma, hypoglycemia, emotional fatigue, morning tiredness, mild shock conditions. |
| **NEUROLYMPHATICS** | **ANTERIOR:** 1″ on either side and 2″ above umbilicus.<br>**POSTERIOR:** Interspinous-transverse space between T-11 & T-12, and occasionally L-1. |
| **MERIDIAN** | Circulation sex. |
| **NUTRITION** | Vitamin C, B complex, natural adrenal extracts, betaine hydrochloride. |
| **ASSOCIATED MUSCLES** | Gracilis, sartorius, soleus, pectoralis major clavicular, latissimus dorsi, triceps, adductors, cervical flexors and extensors. |
| **LAB TESTS** | Eosinophil count, sputum eosinophil culture, 5-hour glucose tolerance test, T-3, T-4, RBC count, hematocrit, HGB, serum chloride, serum potassium. |
| **EXERCISE** | Running, jumping, hopping, skipping, toe walking. |
| **ACTION** | Plantar flexes foot, flexes femur on the tibia. |
| **ORIGIN** | **MEDIAL HEAD:** Depression at upper part of the medial condyle and adjacent part of femur, capsule of knee joint.<br>**LATERAL HEAD:** From the impression on the side of the lateral condyle and adjacent part of the femur, capsule of knee joint. |
| **INSERTION** | Into the calcaneus from the calcaneus tendon. |
| **NERVE SUPPLY** | Tibial, S-1 & 2. |
| **PALPATE** | Very easy to palpate the upper posterior aspect of the lower leg. |

NV IN RESEARCH

# GASTROCNEMIUS - ADRENALS

**TO STRENGTHEN:**

**TO WEAKEN:**

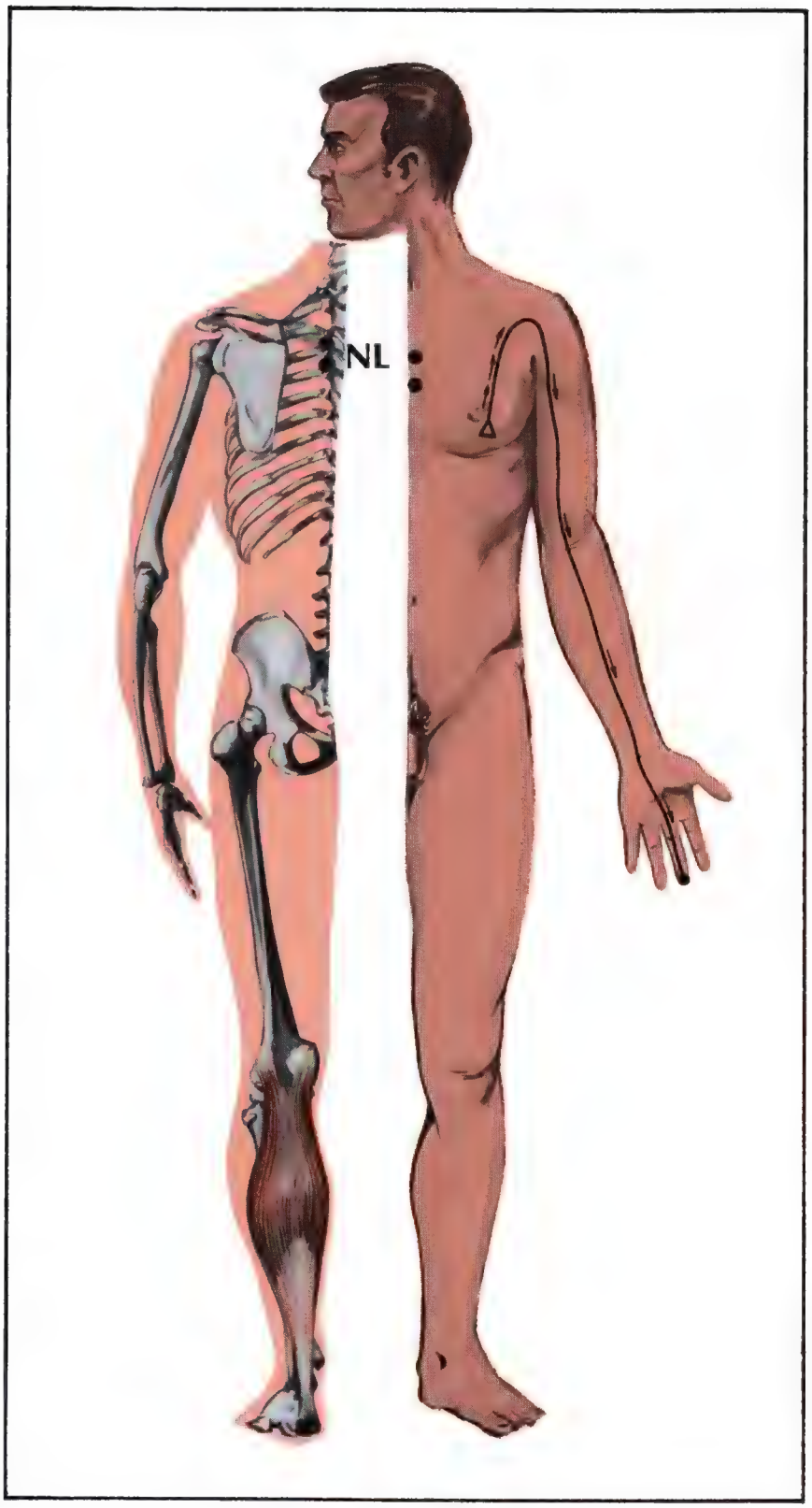

# GLUTEUS MAXIMUS - SEX GLANDS, PROSTATE, BROAD LIGAMENT

| | |
|---|---|
| **STRUCTURAL WEAKNESS** | Anterior ilium, low back conditions, pelvic tilts or rotations, difficulty walking, when bilaterally weak check for upper cervical fixation, low buttocks in prone position. |
| **INTERNAL MANIFESTATIONS** | Menstrual disorders, prostatic conditions and sexual impotency. |
| **NEUROLYMPHATICS** | **ANTERIOR:** Extending from the top of the thigh, running down the outer front of the thigh, ending just above the knee.<br>**POSTERIOR:** Between the posterior superior iliac spine and the spinous of L-5. |
| **MERIDIAN** | Circulation Sex. |
| **NUTRITION** | Vitamin E, wheat germ, natural extracts from the male or female reproductive organs. |
| **ASSOCIATED MUSCLES** | Adductors, piriformis, gluteus medius and gluteus minimus, neck flexors and extensors. |
| **LAB TESTS** | Serum hemoglobin, total and fractionated estrogens, 17-ketosteroids, sperm count, T-3, T-4, adrenal cortical function test. |
| **EXERCISE** | Running, hopping, skipping, jumping, squats. |
| **ACTION** | Extends, assists in adduction and laterally rotates the thigh, extends the trunk. |
| **ORIGIN** | Posterior part of ilium between the crest and the posterior gluteal line, tendon of sacrospinalis, dorsal surface of sacrum and coccyx, sacrotuberous ligament. |
| **INSERTION** | Gluteal tuberosity on lateral aspect of the femur, iliotibial tract. |
| **NERVE SUPPLY** | Inferior gluteal nerve, L-5, S-1 & 2. |
| **PALPATE** | Posterior surface of the pelvis (the wide area). |

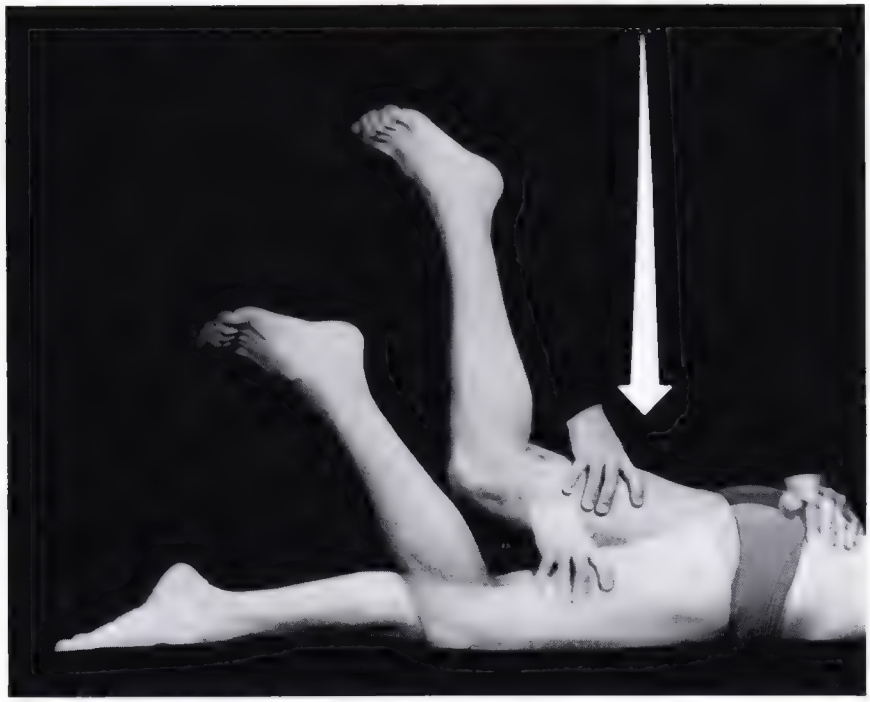




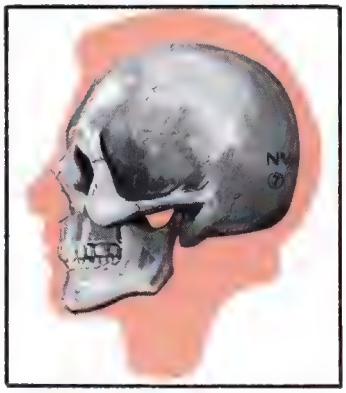

# GLUTEUS MAXIMUS - SEX GLANDS, PROSTATE, BROAD LIGAMENT

**TO STRENGTHEN:**

**TO WEAKEN:**

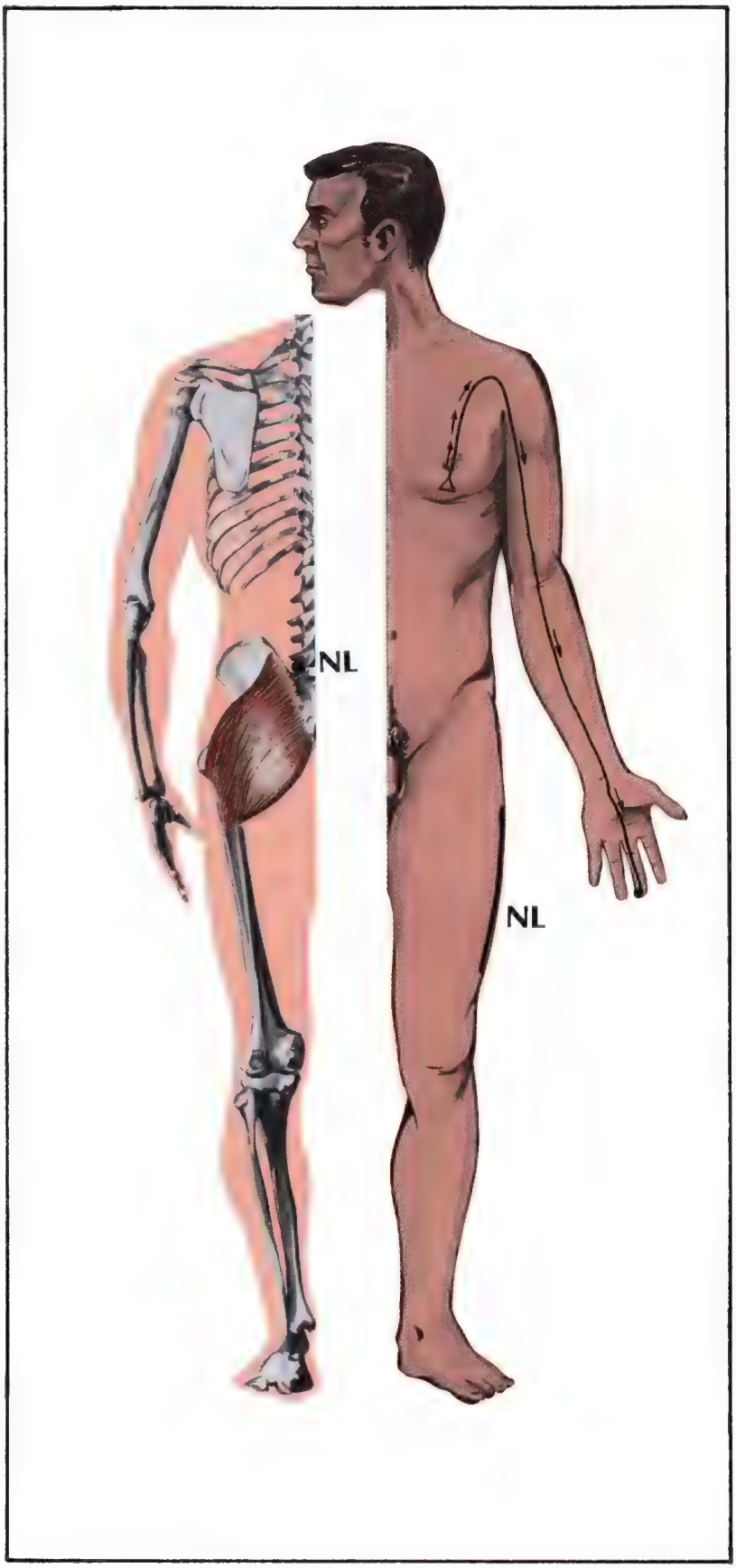

# GLUTEUS MEDIUS - UTERUS & SEMINAL VESICLES

| | |
|---|---|
| **STRUCTURAL WEAKNESS** | High hip, high shoulder and high occiput on the same side, lumbar rotation, external rotation of ilium, bowed legs, a peculiar limp. |
| **INTERNAL MANIFESTATIONS** | Menstrual cramps, prostate problems, impotency, occasional breast soreness. |
| **NEUROLYMPHATICS** | **ANTERIOR:** ½" superior to the ramus of the pubic bones.<br>**POSTERIOR:** Between the spinous process of L-5 and the posterior superior spine of the ilium. |
| **MERIDIAN** | Circulation Sex. |
| **NUTRITION** | Vitamin E, wheat germ, natural extracts from the male or female reproductive organs. |
| **ASSOCIATED MUSCLES** | Psoas, tensor fascia lata, piriformis. |
| **LAB TESTS** | CBC, urinalysis, pap test, sperm count, neutrophil count, ESR, 17-ketosteroids, total and fractionated estrogens. |
| **EXERCISE** | Running, hopping, skipping, hopping on one foot. |
| **ACTION** | Abducts and rotates thigh medially when leg is extended.<br>**NOTE:** Anterior portion flexes and rotates medially.<br>Posterior portion extends and rotates laterally. |
| **ORIGIN** | External surface of ilium between iliac crest and posterior gluteal line and anterior gluteal line below. |
| **INSERTION** | Lateral surface of greater trochanter. |
| **NERVE SUPPLY** | Superior gluteal, L-4, 5 & S-1. |
| **PALPATE** | Slightly in front and above greater trochanter. |

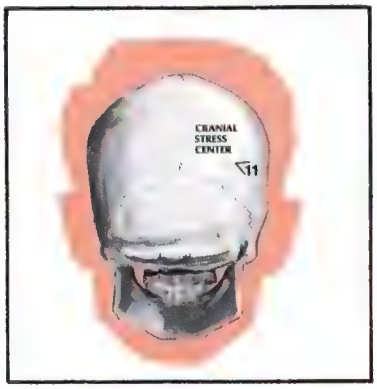


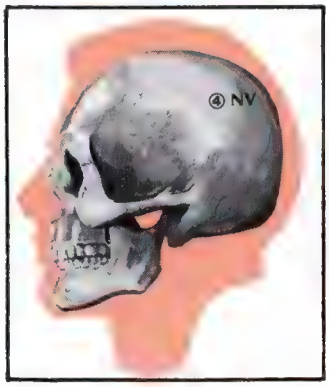

# GLUTEUS MEDIUS - UTERUS & SEMINAL VESICLES

**TO STRENGTHEN:**

**TO WEAKEN:**

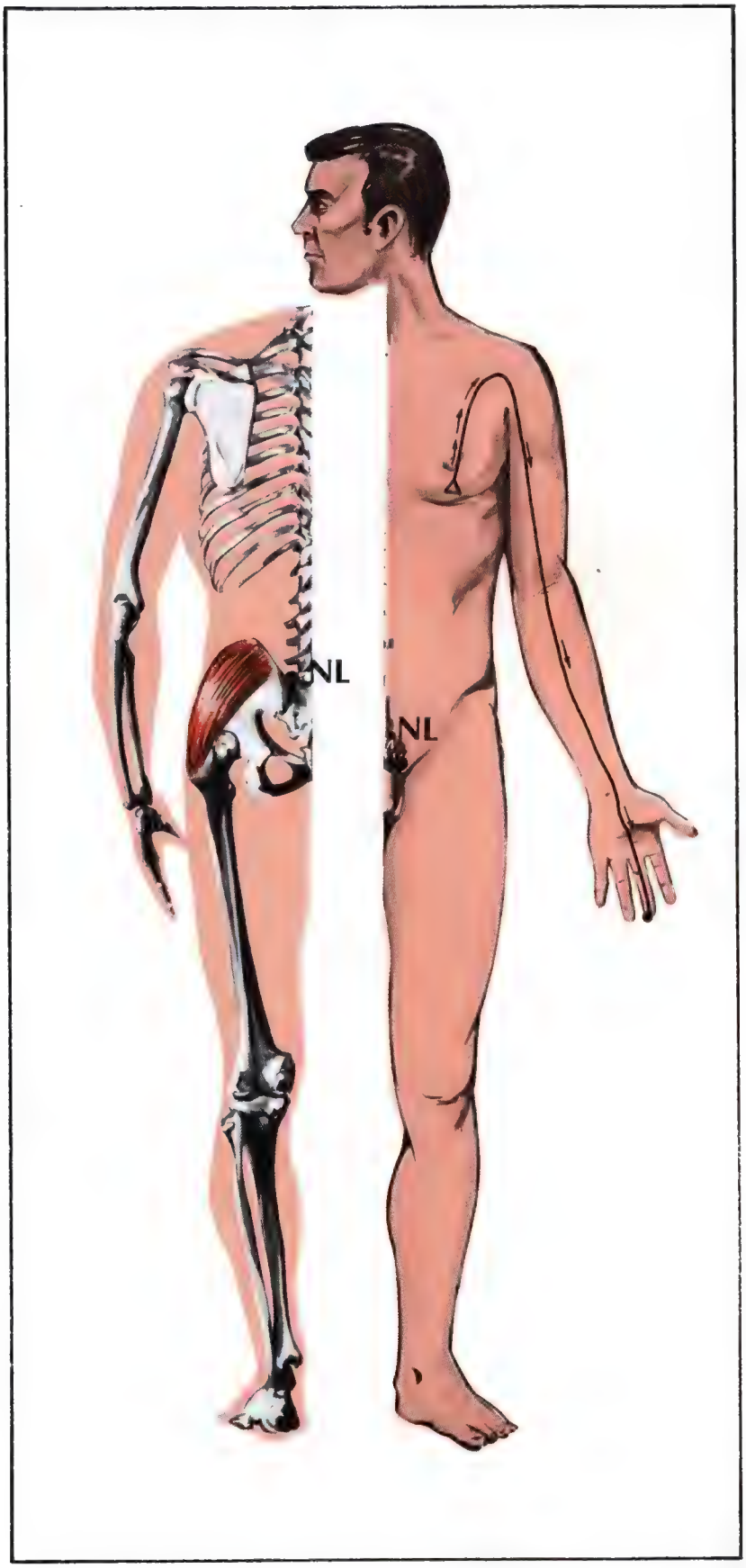

# GLUTEUS MINIMUS - UTERUS & SEMINAL VESICLES

| | |
|---|---|
| **STRUCTURAL WEAKNESS** | High hip, high shoulder and high occiput on the same side, lumbar rotation, external rotation of ilium, bowed legs, a peculiar limp. |
| **INTERNAL MANIFESTATIONS** | Menstrual cramps, prostate problems, impotency, occasional breast soreness. |
| **NEUROLYMPHATICS** | **ANTERIOR:** ½" superior to the ramus of the pubic bones.<br>**POSTERIOR:** Between the spinous process of L-5 and the posterior superior spine of the ilium. |
| **MERIDIAN** | Circulation Sex. |
| **NUTRITION** | Vitamin E, wheat germ, natural extracts from the male or female reproductive organs. |
| **ASSOCIATED MUSCLES** | Psoas, tensor fascia lata, piriformis. |
| **LAB TESTS** | CBC, urinalysis, pap test, sperm count, neutrophil count, ESR, 17-ketosteroids, total and fractionated estrogens. |
| **EXERCISE** | Running, hopping, skipping, hopping on one foot. |
| **ACTION** | Abducts and rotates thigh medially when leg is extended. |
| **ORIGIN** | External surface of ilium between anterior and inferior gluteal lines, margin of sciatic notch. |
| **INSERTION** | Anterior border of greater trochanter of femur and hip joint capsule. |
| **NERVE SUPPLY** | Superior gluteal, L-4, 5 & S-1. |
| **PALPATE** | Cannot be palpated. |

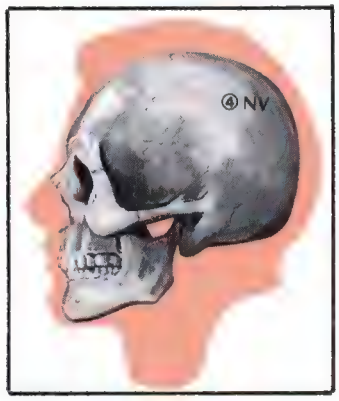

# GLUTEUS MINIMUS - UTERUS & SEMINAL VESICLES

**TO STRENGTHEN:**

**TO WEAKEN:**

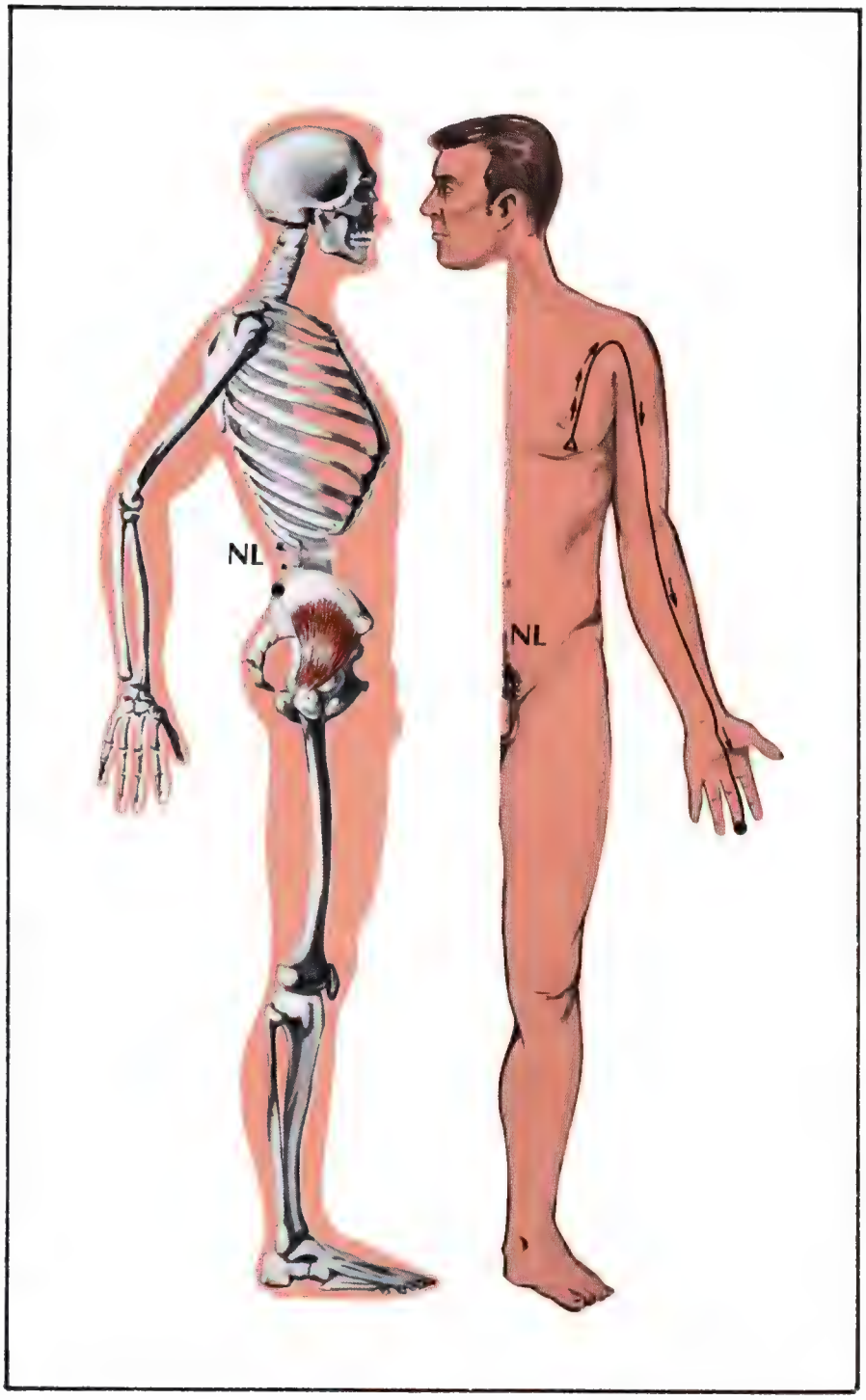

# GRACILIS - ADRENAL

| | |
|---|---|
| STRUCTURAL WEAKNESS | Posterior ilium, knee problems, external rotation of lower leg on femur. |
| INTERNAL MANIFESTATIONS | Allergies, asthma, hypofunction of adrenals, infections, carbohydrate sensitivity. |
| NEUROLYMPHATICS | **ANTERIOR:** 2" above and 1" on either side of the umbilicus.<br>**POSTERIOR:** Between T-10 & T-12, interspinous-transverse space. |
| MERIDIAN | Circulation Sex. |
| NUTRITION | Vitamin C, Vitamin A, Vitamin E, natural concentrates of adrenal extracts. |
| ASSOCIATED MUSCLES | Adductors, hamstrings, latissimus dorsi, pectoralis major clavicular, psoas, neck muscles, sacrospinalis. |
| LAB TESTS | CBC, eosinophil count, sputum eosinophil culture, 5-hour glucose tolerance, serum chloride, serum potassium, 2-hour postprandial test, fasting blood sugar. |
| EXERCISE | Swimming, jogging, skating, horseback riding. |
| ACTION | Adducts the thigh, flexes and medially rotates the knee. |
| ORIGIN | Inner edge of the descending ramus of the pubis, inferior half of symphysis pubis. |
| INSERTION | Upper part of medial surface of tibia, distal to the condyle. |
| NERVE SUPPLY | Anterior division of obturator, L-2, 3 & 4. |
| PALPATE | Medial side of thigh, approximately 2" below the pubic bone. |

CSC IN RESEARCH

DOWN AND SLIGHTLY OUT

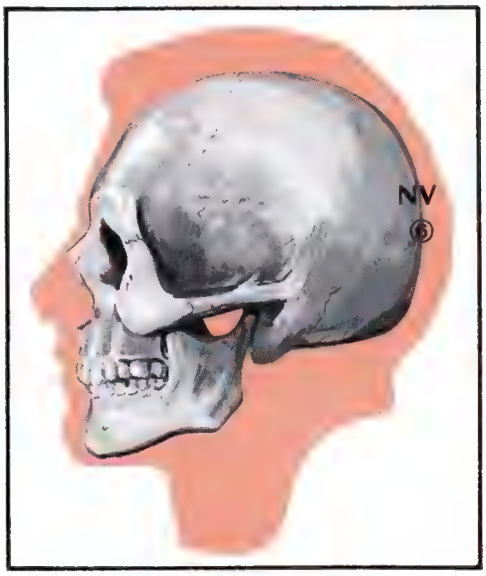

# GRACILIS - ADRENAL

**TO STRENGTHEN:**

**TO WEAKEN:**

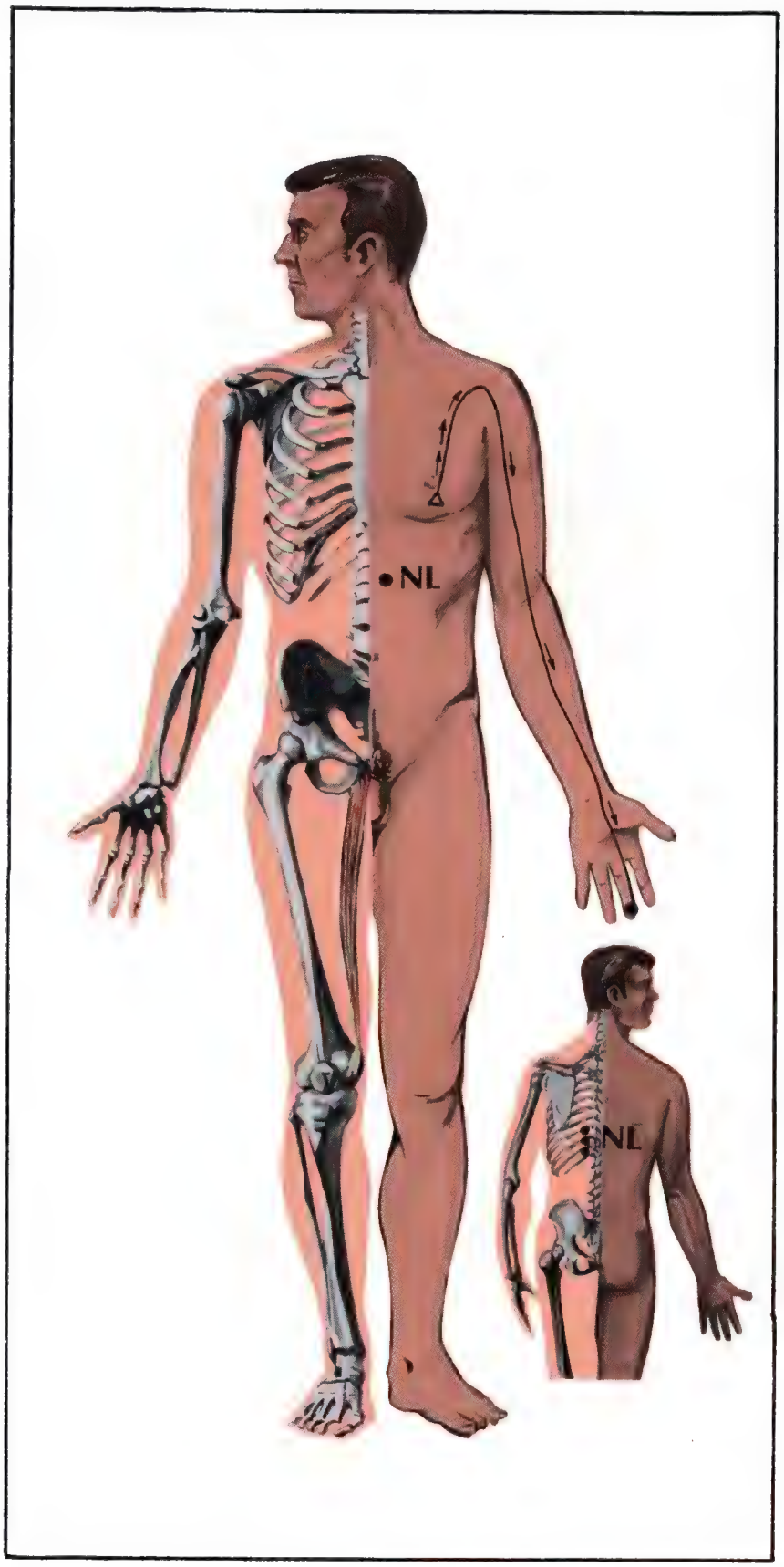

# HAMSTRINGS - RECTUM

## LATERAL - BICEPS FEMORIS

| | |
|---|---|
| STRUCTURAL WEAKNESS | Sacral fault, low back problems, weakness of the legs, knee problems, knocked knees, bowed legs, posterior ischium. |
| INTERNAL MANIFESTATIONS | Hemorrhoids, restlessness, fatigue, toxic headaches, constipation, colitis. |
| NEUROLYMPHATICS | **ANTERIOR:** Inside of upper one-half of the thigh.<br>**POSTERIOR:** The posterior iliac crest, and lateral to the ischial tuberosities. |
| MERIDIAN | Large Intestine. |
| NUTRITION | Vitamin E, wheat germ, betaine hydrochloride concentrates. |
| ASSOCIATED MUSCLES | Latissimus dorsi, pectoralis major clavicular. |
| LAB TESTS | CBC, ESR, neutrophil count, RBC, HGB, stool examination for blood, pus and mucus. |
| EXERCISE | Running, jumping, skipping and hopping. |
| ACTION | Flexes the leg, extends the thigh, rotates the leg laterally when knee is semiflexed. |
| ORIGIN | **LONG HEAD:** From the ischial tuberosity and the sacrotuberous ligament.<br>**SHORT HEAD:** From the lateral lip of the linea aspera, lateral supracondyle of femur, lateral to intermuscular septum. |
| INSERTION | Lateral side of head of fibula and lateral condyle of tibia, deep fascia on lateral side of leg. |
| NERVE SUPPLY | Tibial portion of sciatic, L-5, S-1 & 2. |
| PALPATE | Lateral posterior side of femur (near the knee). |

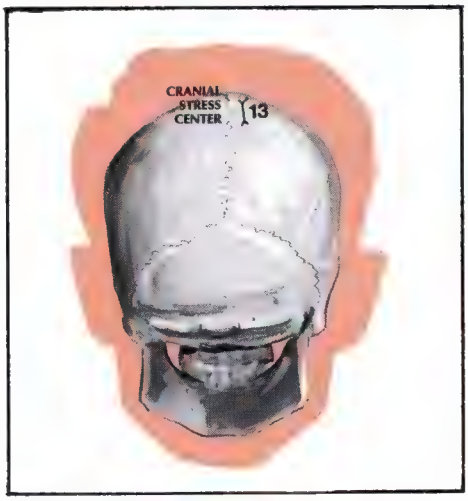


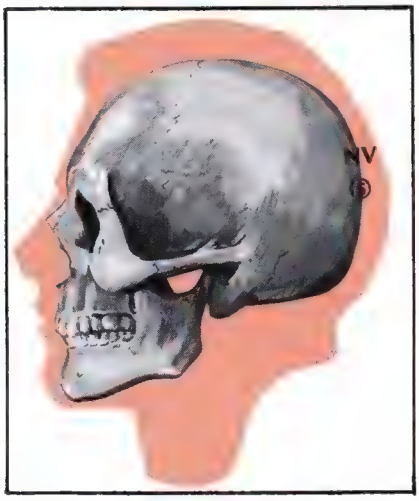

# HAMSTRINGS - RECTUM
## LATERAL - BICEPS FEMORIS

**TO STRENGTHEN:**

**TO WEAKEN:**

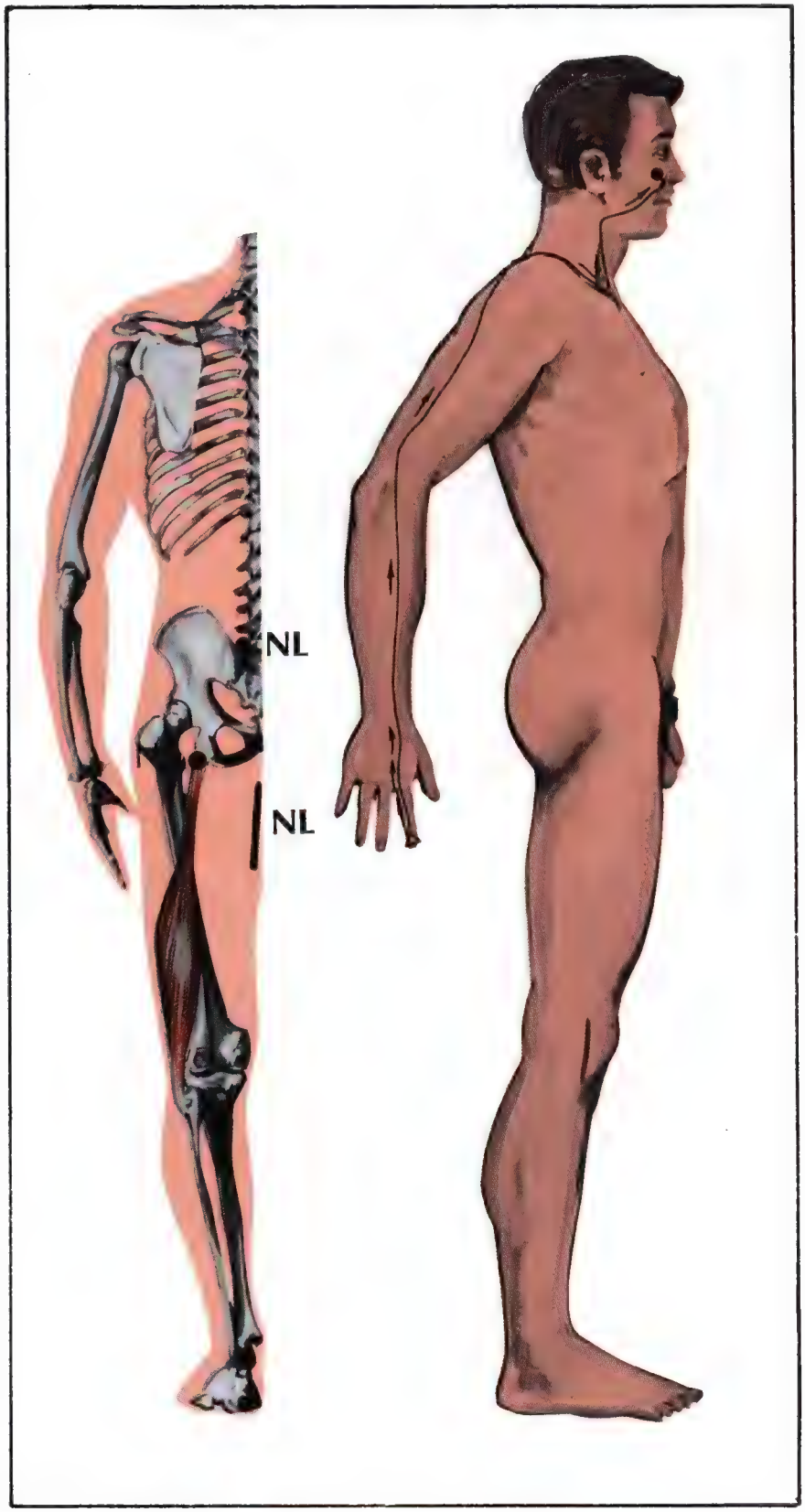

# HAMSTRINGS - RECTUM
## MEDIAL - SEMIMEMBRANOSUS

| | |
|---|---|
| STRUCTURAL WEAKNESS | Sacral fault, low back problems, weakness of the legs, knee problems, knocked knees, bowed legs, posterior ischium. |
| INTERNAL MANIFESTATIONS | Hemorrhoids, restlessness, fatigue, toxic headaches, constipation, colitis. |
| NEUROLYMPHATICS | **ANTERIOR:** Inside of upper one-half of the thigh.<br>**POSTERIOR:** The posterior iliac crest, and lateral to the ischial tuberosities. |
| MERIDIAN | Large Intestine. |
| NUTRITION | Vitamin E, wheat germ, betaine hydrochloride concentrates. |
| ASSOCIATED MUSCLES | Latissimus dorsi, pectoralis major clavicular. |
| LAB TESTS | CBC, ESR, neutrophil count, RBC, HGB, stool examination for blood, pus and mucus. |
| EXERCISE | Running, jumping, skipping and hopping. |
| ACTION | Flexes the leg, extends the thigh, rotates the leg medially when knee is semiflexed. |
| ORIGIN | Upper and outer impression of ischial tuberosity. |
| INSERTION | Into the horizontal groove on the medial posterior surface of the medial condyle of the tibia. |
| NERVE SUPPLY | Tibial portion of sciatic, L-5, S-1 & 2. |
| PALPATE | Only the tendon is palpable on the posterior aspect of the tibia (medial side). |

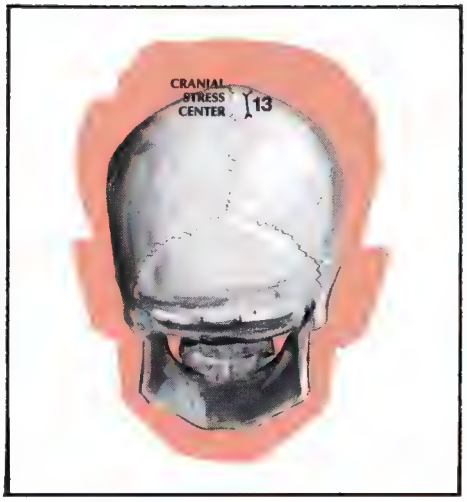


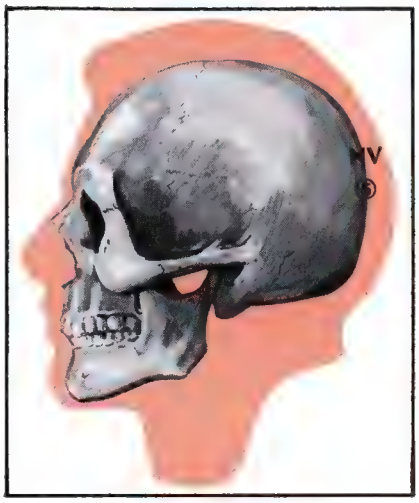

# HAMSTRINGS - RECTUM
## MEDIAL - SEMIMEMBRANOSUS

**TO STRENGTHEN:**

**TO WEAKEN:**

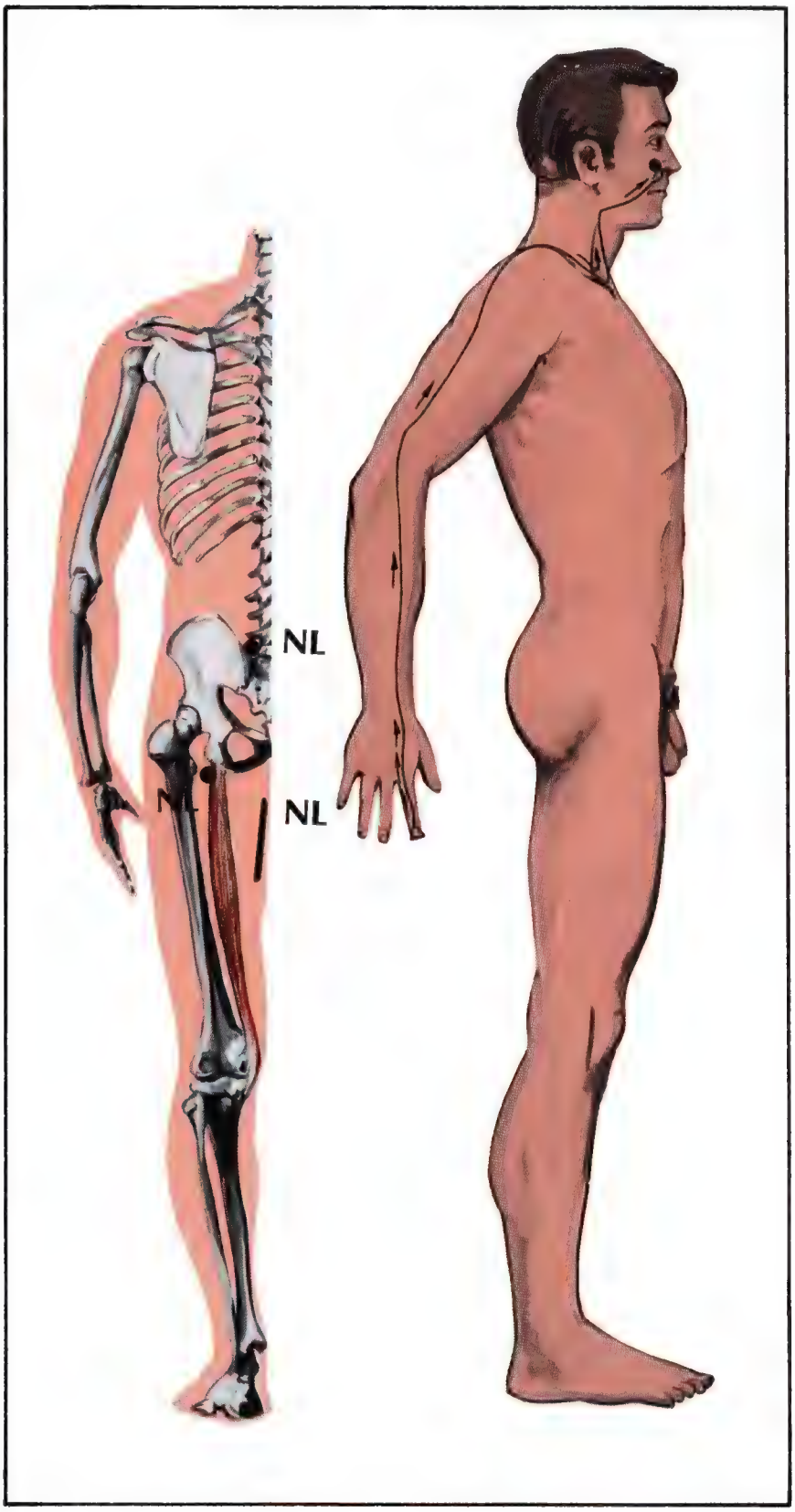

# HAMSTRINGS - RECTUM

## MEDIAL - SEMITENDINOSUS

| | |
|---|---|
| STRUCTURAL WEAKNESS | Sacral fault, low back problems, weakness of the legs, knee problems, knocked knees, bowed legs, posterior ischium. |
| INTERNAL MANIFESTATIONS | Hemorrhoids, restlessness, fatigue, toxic headaches, constipation, colitis. |
| NEUROLYMPHATICS | **ANTERIOR:** Inside of upper one-half of the thigh.<br>**POSTERIOR:** The posterior iliac crest, and lateral to the ischial tuberosities. |
| MERIDIAN | Large Intestine. |
| NUTRITION | Vitamin E, wheat germ, betaine hydrochloride concentrates. |
| ASSOCIATED MUSCLES | Latissimus dorsi, pectoralis major clavicular. |
| LAB TESTS | CBC, ESR, neutrophil count, RBC, HGB, stool examination for blood, pus and mucus. |
| EXERCISE | Running, jumping, skipping and hopping. |
| ACTION | Flexes the leg, extends the thigh, rotates the leg medially when knee is semiflexed. |
| ORIGIN | Lower and medial impression on tuberocity of the ischium. |
| INSERTION | Upper part of the medial surface of tibia and deep fascia of the leg. |
| NERVE SUPPLY | Tibial portion of sciatic nerve, L-5, S-1 & 2. |
| PALPATE | Near the knee on the posterior medial side. |

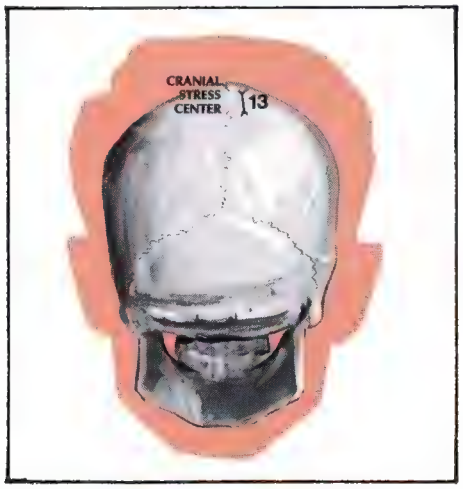


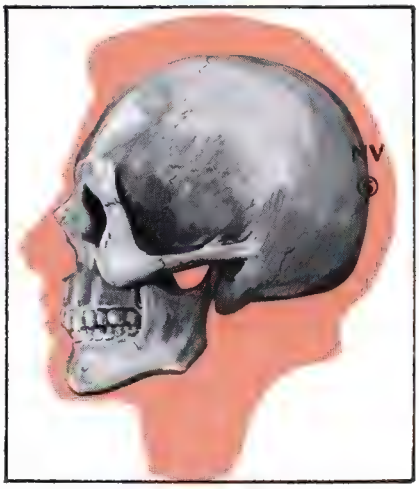

# HAMSTRINGS - RECTUM
## MEDIAL - SEMITENDINOSUS

TO STRENGTHEN:

TO WEAKEN:

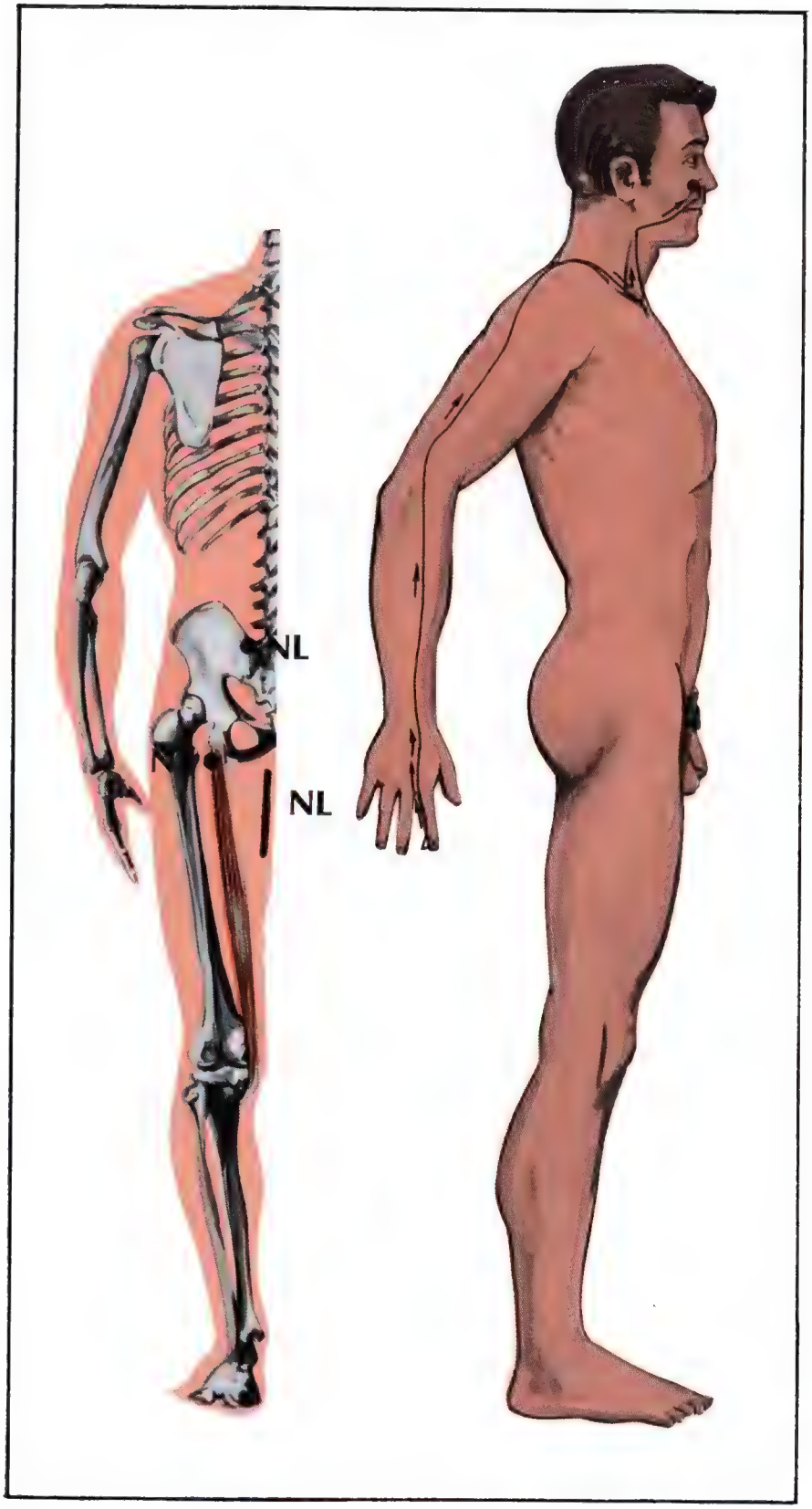

# ILIACUS - KIDNEY

| | |
|---|---|
| STRUCTURAL WEAKNESS | Hypertonic psoas. |
| INTERNAL MANIFESTATIONS | Ileocecal valve syndrome. |
| NEUROLYMPHATICS | **ANTERIOR:** 1″ to the sides and 1″ above the navel, anterior upper one-third of the right humerus.<br>**POSTERIOR:** Just below the level of the last ribs, 1″ lateral to the spine, lamina of the third cervical on the right. |
| MERIDIAN | Kidney. |
| NUTRITION | Vitamin A, Vitamin E chlorophyll complex, lactic acid yeast preparation, betaine hydrochloride. |
| ASSOCIATED MUSCLES | Tensor fascia lata, upper trapezius, gluteus medius, gluteus minimus, psoas. |
| LAB TESTS | Check pH of stool and saliva. |
| EXERCISE | Leg raises and leg lowerings while supine, running, jogging, lifting the legs high. |
| ACTION | Flexes and medially rotates the thigh, tilts pelvis forward when leg is fixed. |
| ORIGIN | Upper two-thirds of iliac fossa and inner lip of iliac crest, behind; anterior sacro-iliac and iliolumbar ligaments and base of sacrum, in front. |
| INSERTION | Tendon of the psoas major. |
| NERVE SUPPLY | Femoral, L-1, 2, 3 & 4. |
| PALPATE | Almost impossible to palpate, even with complete relaxation of the rectus abdominis. |

NV IN RESEARCH
CSC IN RESEARCH

Test is performed with patient in prone position.

# ILIACUS - KIDNEY

**TO STRENGTHEN:**

**TO WEAKEN:**

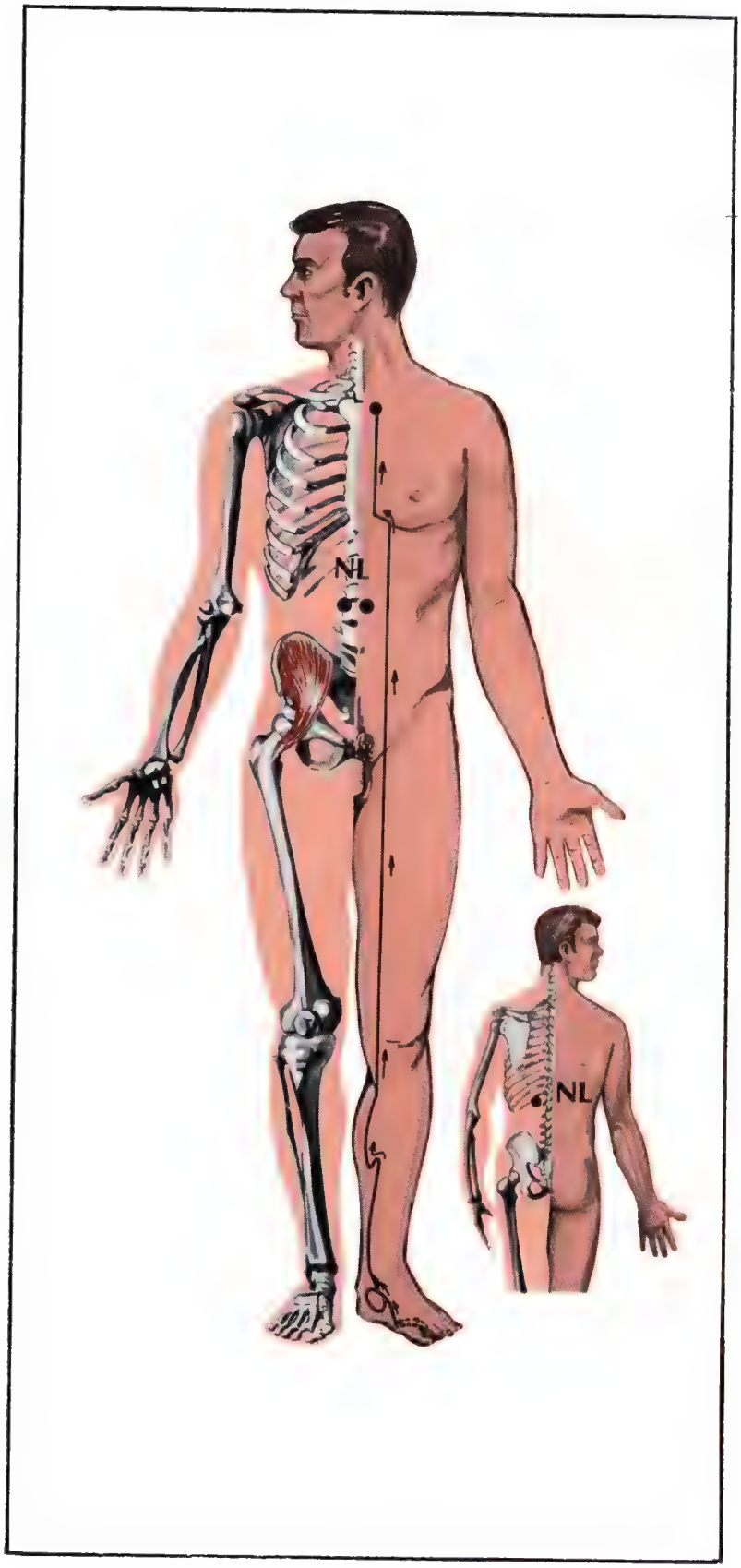

# INFRASPINATUS - THYROID

| | |
|---|---|
| STRUCTURAL WEAKNESS | Elbow and wrist problems, shoulder difficulties. |
| INTERNAL MANIFESTATIONS | Thyroid conditions, digestive disturbances, infections, weight changes, unwarranted and uncontrolled crying. |
| NEUROLYMPHATICS | **ANTERIOR:** Between 2nd & 3rd ribs, adjacent to sternum.<br>**POSTERIOR:** Transverse space between T-2 & T-3. |
| MERIDIAN | Triple-warmer. |
| NUTRITION | Organic iodine, kelp, thyroid extract. |
| ASSOCIATED MUSCLES | Teres minor, trapezius, rhomboids. |
| LAB TESTS | T-3, T-4, cholesterol, diagnex blue, WBC. |
| EXERCISE | Jumping jacks, push-ups, jumping rope, swimming. |
| ACTION | Adducts and laterally rotates head of humerus with assistance from the teres minor. |
| ORIGIN | Infraspinatus fossa of the scapula. |
| INSERTION | Middle impression of the greater tuberosity of the humerus and shoulder joint capsule. |
| NERVE SUPPLY | Suprascapular, C-5 & 6. |
| PALPATE | Between scapula and humerus on the posterior side, just below the fibers of the deltoid. |

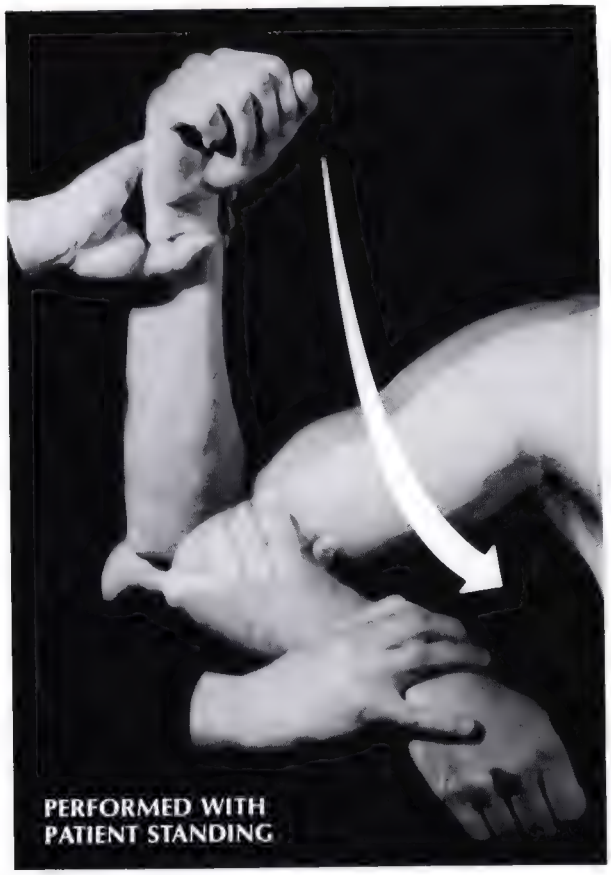


CSC IN RESEARCH

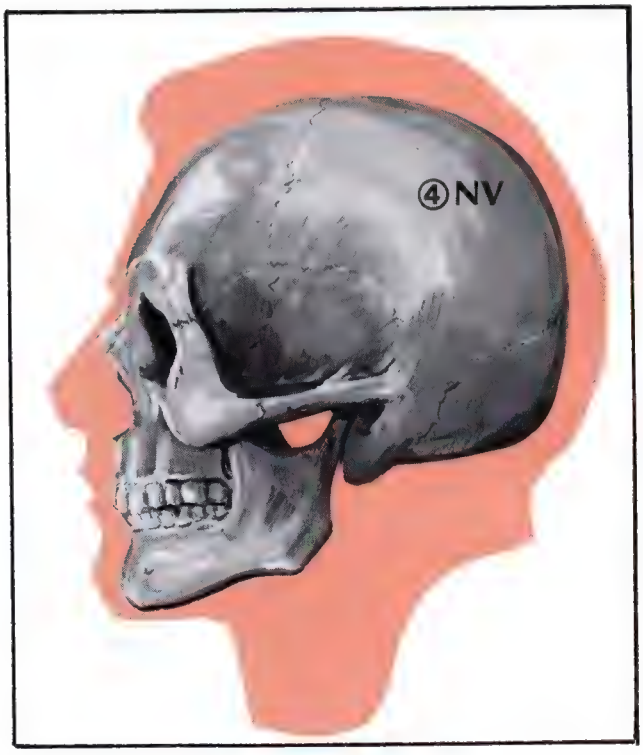

# INFRASPINATUS - THYROID

**TO STRENGTHEN:**

**TO WEAKEN:**

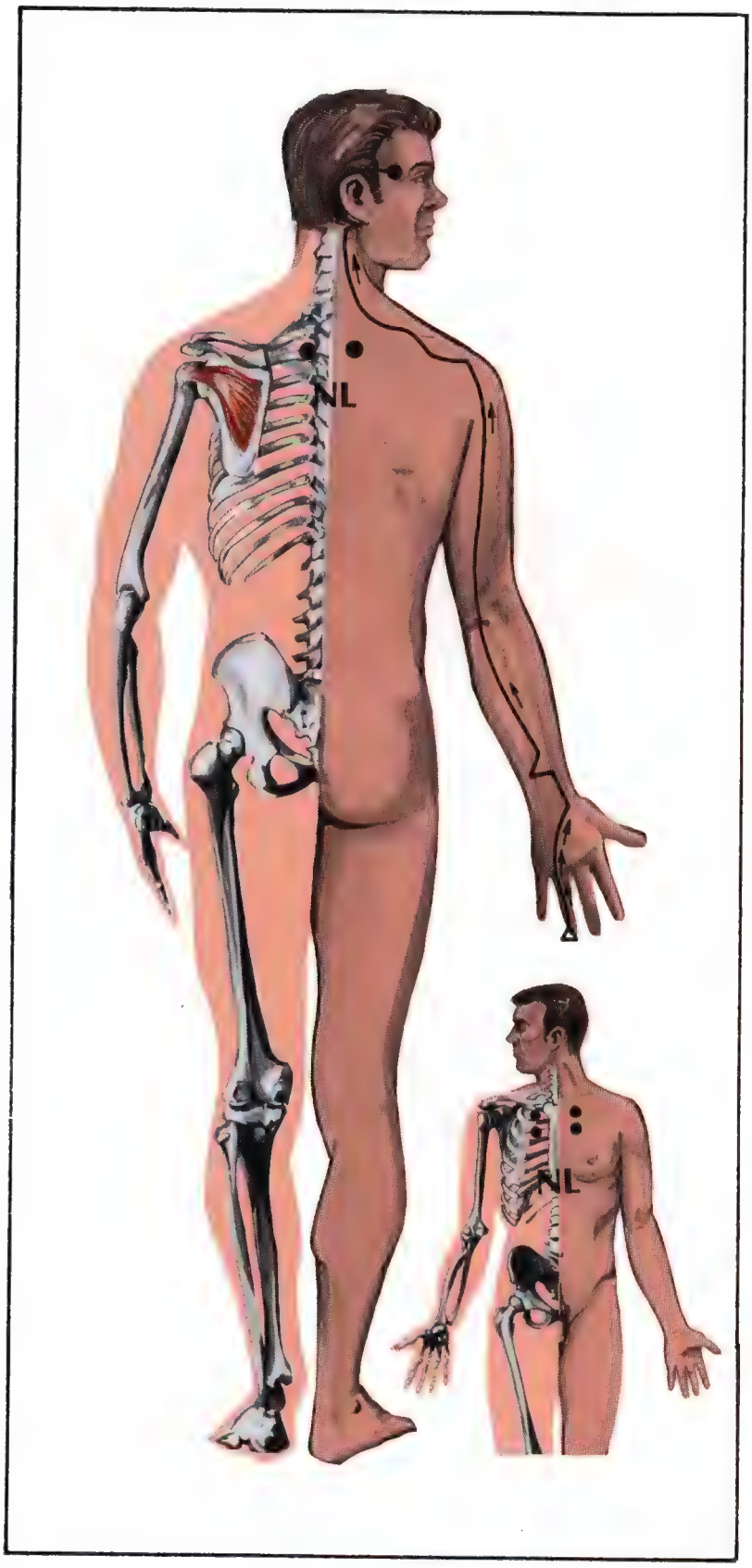

# LATISSIMUS DORSI - PANCREAS

| | |
|---|---|
| **STRUCTURAL WEAKNESS** | Shoulder problems, low back conditions. |
| **INTERNAL MANIFESTATIONS** | Diabetes mellitus, hypoglycemia, hyperinsulinism and occasionally allergies. |
| **NEUROLYMPHATICS** | **ANTERIOR:** Between the 7th & 8th ribs, close to the border of the sternum, adjacent to the cartilages.<br>**POSTERIOR:** Between T-7 & 8, 1" to each side of the spine.. |
| **MERIDIAN** | Spleen. |
| **NUTRITION** | Vitamin A, Vitamin F, betaine hydrochloride concentrates, natural adrenal extracts, high protein diet may be indicated. |
| **ASSOCIATED MUSCLES** | Upper trapezius, triceps, sartorius, gracilis, pectoralis major clavicular. |
| **LAB TESTS** | HGB, Eosinophils in sputum, 5-hour glucose tolerance test, T-3, T-4, cholesterol, adrenal cortical function test. |
| **EXERCISE** | Chinning, dips on parallel bar, any movement in which the arms are pulled downward employing the lattissimus dorsi. |
| **ACTION** | Rotates medially and adducts, holds shoulder and arm down. |
| **ORIGIN** | Posterior crest of ilium, sacrum and spinous processes of the lumbar and lower five dorsal vertebrae and muscular slips from the lower 3 or 4 ribs. |
| **INSERTION** | Intertubercular groove of humerus. |
| **NERVE SUPPLY** | Thoracodorsal nerve, C-6, 7 & 8. |
| **PALPATE** | Lateral, posterior aspect of the trunk below the armpit. |

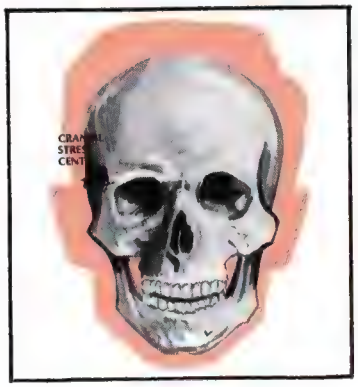

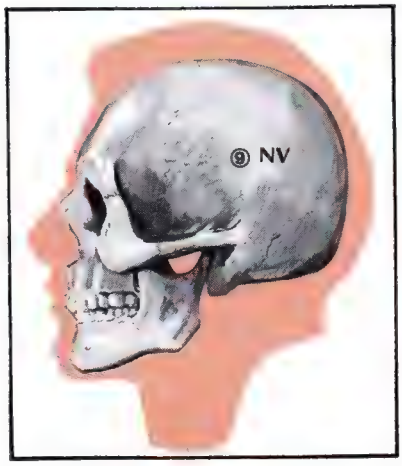

# LATISSIMUS DORSI - PANCREAS

**TO STRENGTHEN:**

**TO WEAKEN:**

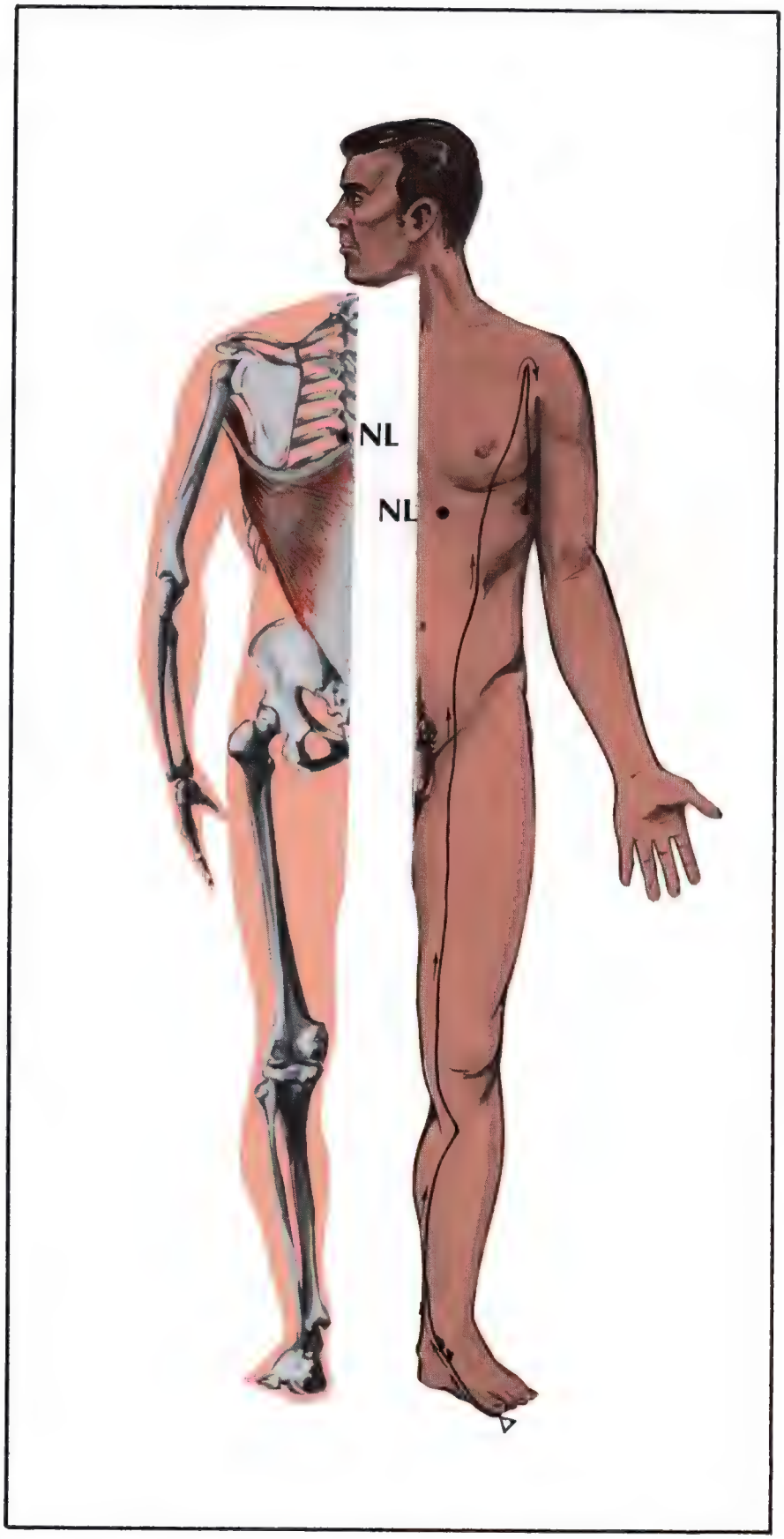

# LEVATOR ANI - UTERUS & RECTUM

| | |
|---|---|
| STRUCTURAL WEAKNESS | It is involved with all basic pelvic and lumbo-sacral subluxations. |
| INTERNAL MANIFESTATIONS | Prolapse of the uterus. |
| NEUROLYMPHATICS | **ANTERIOR:** Anterior medial fascia of the thigh.<br>**POSTERIOR:** Junction of the transverse process of L-5 and posterior medial fascia of the thigh. |
| MERIDIAN | Circulation Sex. |
| NUTRITION | Vitamin E. |
| ASSOCIATED MUSCLES | Abdominals, adductors. |
| LAB TESTS | IN RESEARCH. |
| EXERCISE | Isometric contractions of the rectal, vaginal and perineal muscles. |
| ACTION | Forms floor of the pelvic cavity, constricts lower end of the rectum and vagina, retains viscera in its normal position. |
| ORIGIN | Anteriorly, from the inner surface of superior ramus of pubis, lateral to the symphysis, posteriorly from the inner surface of the ischeal spine and between these origins from the obturator fascia. |
| INSERTION | Into the front and sides of the last two segments of the coccyx. |
| NERVE SUPPLY | Perineal or rectal branches of the pudendal, direct branches from the 3rd, 4th & 5th sacral nerves. |
| PALPATE | Not palpable. |

NV IN RESEARCH
CSC IN RESEARCH

# LEVATOR ANI - UTERUS & RECTUM

**TO STRENGTHEN:**

**TO WEAKEN:**

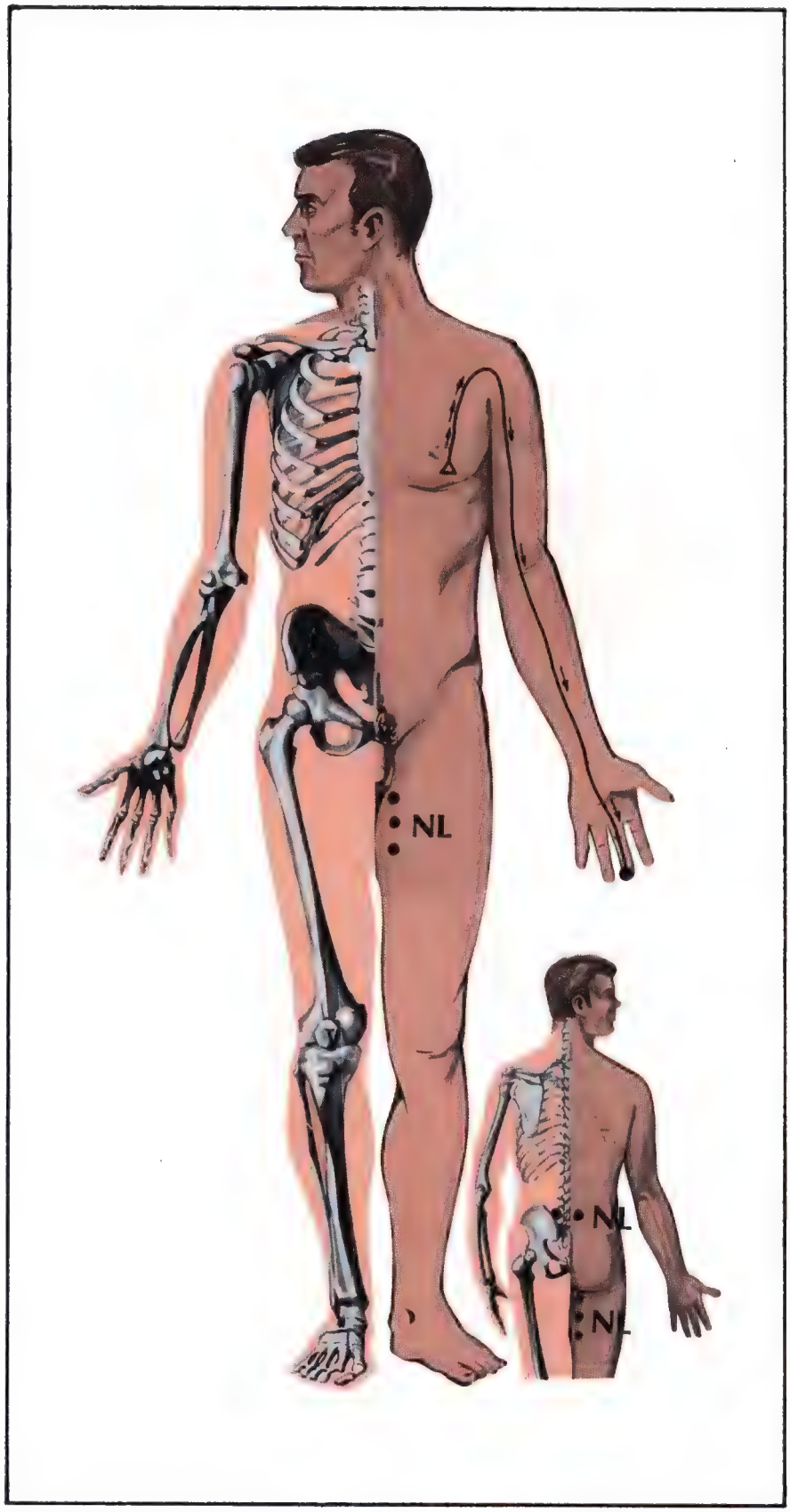

# LEVATOR SCAPULAE - STOMACH

| | |
|---|---|
| STRUCTURAL WEAKNESS | Rotation of the cervical spine with a level occiput. |
| INTERNAL MANIFESTATIONS | Dyspepsia. |
| NEUROLYMPHATICS | **ANTERIOR:** Each side of the sternum between the 2nd & 3rd ribs.<br>**POSTERIOR:** Between C-7 & T-1, 1" to each side of the spine and firm pressure to the belly of the teres minor muscle. |
| MERIDIAN | Stomach. |
| NUTRITION | Vitamin B, wheat germ. |
| ASSOCIATED MUSCLES | Rhomboids, neck muscles, teres major, teres minor, pectoralis major clavicular, latissimus dorsi. |
| LAB TESTS | Check pH of saliva, bowel and urine, diagnex blue. |
| EXERCISE | Dips, general cervical exercises. |
| ACTION | Raises scapula or inclines the neck to the corresponding side as fixed. |
| ORIGIN | Transverse processes of atlas, axis, 3rd & 4th cervical. |
| INSERTION | Superior vertebral border of the scapula between the medial angle and the triangular smooth surface at the root of the spine. |
| NERVE SUPPLY | Dorsal scapular, C-3, 4 & 5. |
| PALPATE | Cannot be palpated. |

NV IN RESEARCH

# LEVATOR SCAPULAE - STOMACH

**TO STRENGTHEN:**

**TO WEAKEN:**

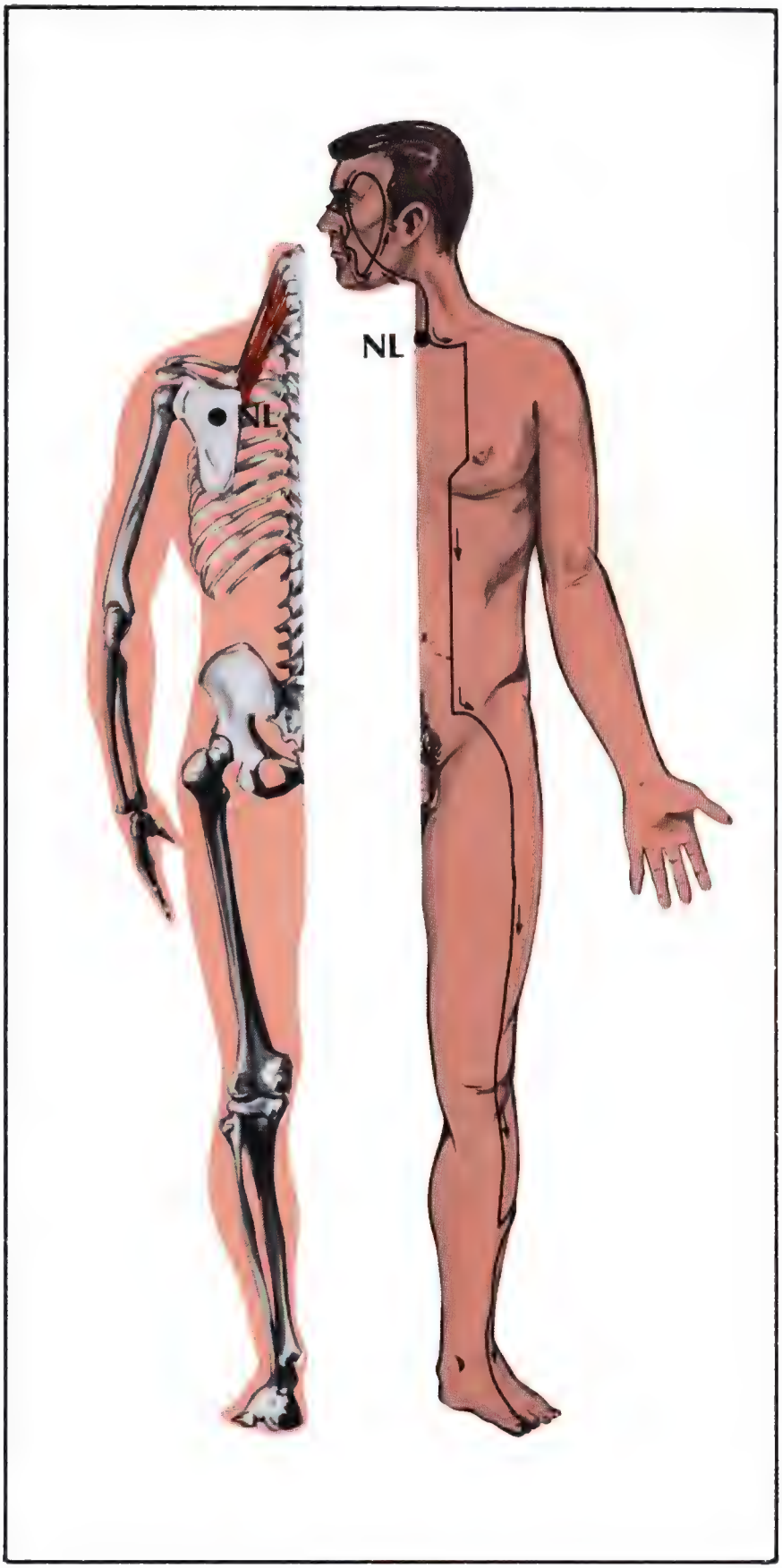

# MASSETER

| | |
|---|---|
| STRUCTURAL WEAKNESS | Jaw problems. |
| INTERNAL MANIFESTATIONS | Headaches. |
| NEUROLYMPHATICS | IN RESEARCH (possibly anterior tip of shoulder). |
| MERIDIAN | Stomach. |
| NUTRITION | IN RESEARCH. |
| ASSOCIATED MUSCLES | Neck flexors and extensors. |
| LAB TESTS | IN RESEARCH. |
| EXERCISE | IN RESEARCH. |
| ACTION | Elevates jaw, clenches teeth, closes the jaw. |
| ORIGIN | **SUPERFICIAL PORTION:** The anterior two-thirds of the lower border of the zygomatic arch.<br>**DEEP PORTION:** Posterior one-third of lower border and from the whole of the medial surface of the zygomatic arch. |
| INSERTION | **SUPERFICIAL PORTION:** Angle and lower one-half of the internal surface of the ramus of the mandible.<br>**DEEP PORTION:** Upper one-half of the ramus and lateral surface of coronoid process of the mandible. |
| NERVE SUPPLY | Masseteric nerve from the mandibular division of the trigeminal nerve. |
| PALPATE | Lateral side of the jaw. |

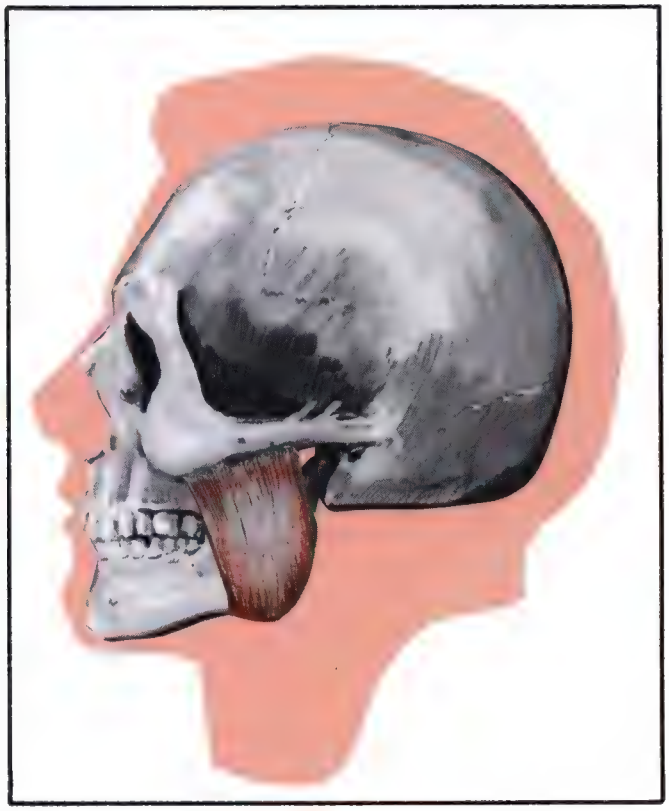

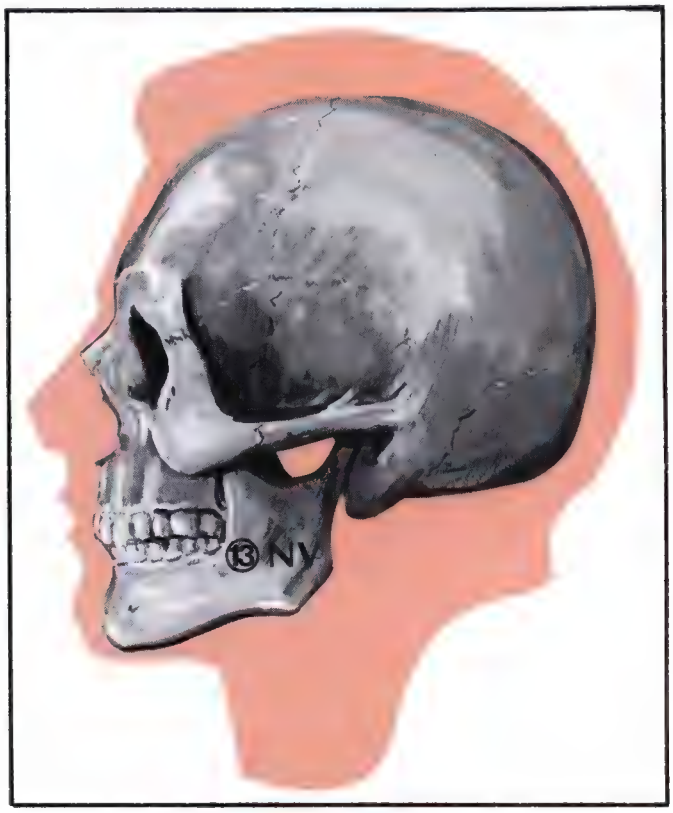

# MASSETER

**TO STRENGTHEN:**

**TO WEAKEN:**

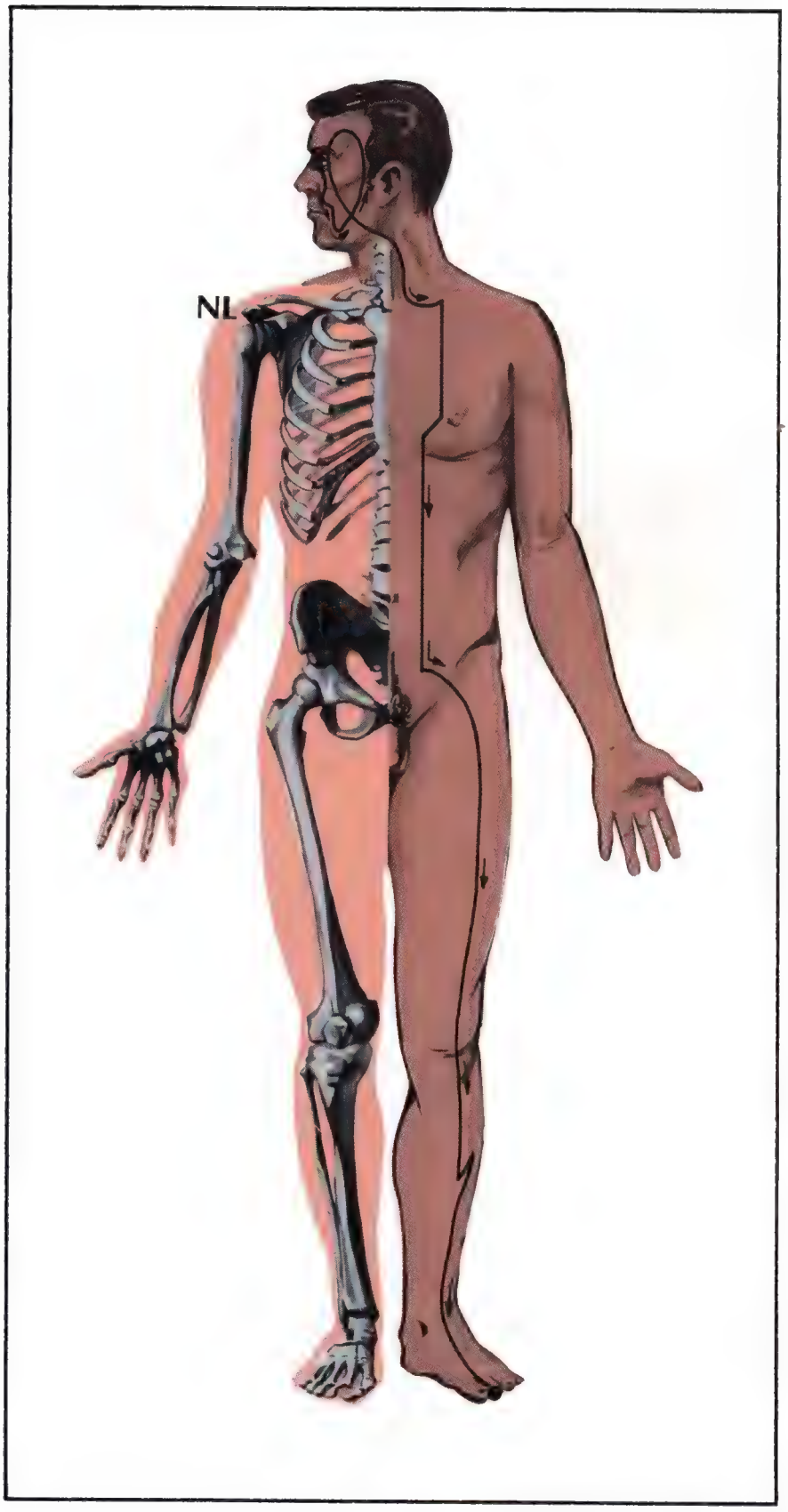

# POSTERIOR & LATERAL NECK EXTENSORS - SINUSES

## SPLENIUS CAPITIS & SPLENIUS CERVICIS

| | |
|---|---|
| STRUCTURAL WEAKNESS | Neck problems, whiplash, high occiput. The sacrum is in a state of fixation when the left and right neck extensors test individually weak. When they are bilaterally weak, this is an indication that the lumbars are in fixation. |
| INTERNAL MANIFESTATIONS | Sinusitis, headaches, allergies, respiratory pattern involved with the piriformis and iliac fixation. |
| NEUROLYMPHATICS | **ANTERIOR:** Intercostal space, 3½" from the sternum on the upper ridge of the 2nd rib.<br>**POSTERIOR:** Interspinous-transverse space of C-2. |
| MERIDIAN | Stomach. |
| NUTRITION | Niacinamide and B-6, organic iodine, Vitamin B. |
| ASSOCIATED MUSCLES | Pectoralis major clavicular, sartorius, gracilis, soleus, gastrocnemius, piriformis. |
| LAB TESTS | Eosinophil count, eosinophil sputum culture, WBC, diagnex blue. |
| EXERCISE | Isometric cervical exercises and bridging. |
| ACTION | Together they extend and laterally flex the head and neck, rotate the head slightly. |
| ORIGIN | **SPLENIUS CAPITIS:** From the lower half of the ligamentum nuchae and spine of the 7th cervical and upper 3 or 4 thoracic vertebrae.<br>**SPLENIUS CERVICIS:** From the spine of the 3rd through the 6th thoracic vertebrae. |
| INSERTION | **SPLENIUS CAPITIS:** Into the mastoid process of the temporal bone and the lateral part of the superior nuchal line.<br>**SPLENIUS CERVICIS:** Into the posterior tubercle of the transverse processes of the upper 2 or 3 cervical vertebrae. |
| NERVE SUPPLY | Lateral branches of the posterior division of the middle and lower cervical nerves. |
| PALPATE | Not palpable. |

Photo illustrates bilateral muscle testing. To test individually turn patient's head to 45°.

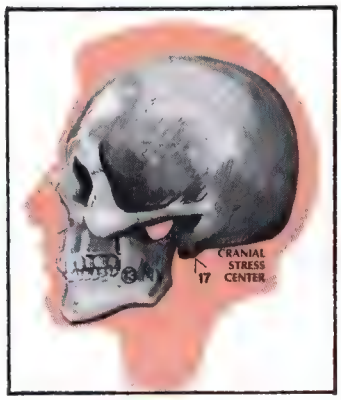

# POSTERIOR & LATERAL NECK EXTENSORS - SINUSES

## SPLENIUS CAPITIS & SPLENIUS CERVICIS

**TO STRENGTHEN:**

**TO WEAKEN:**

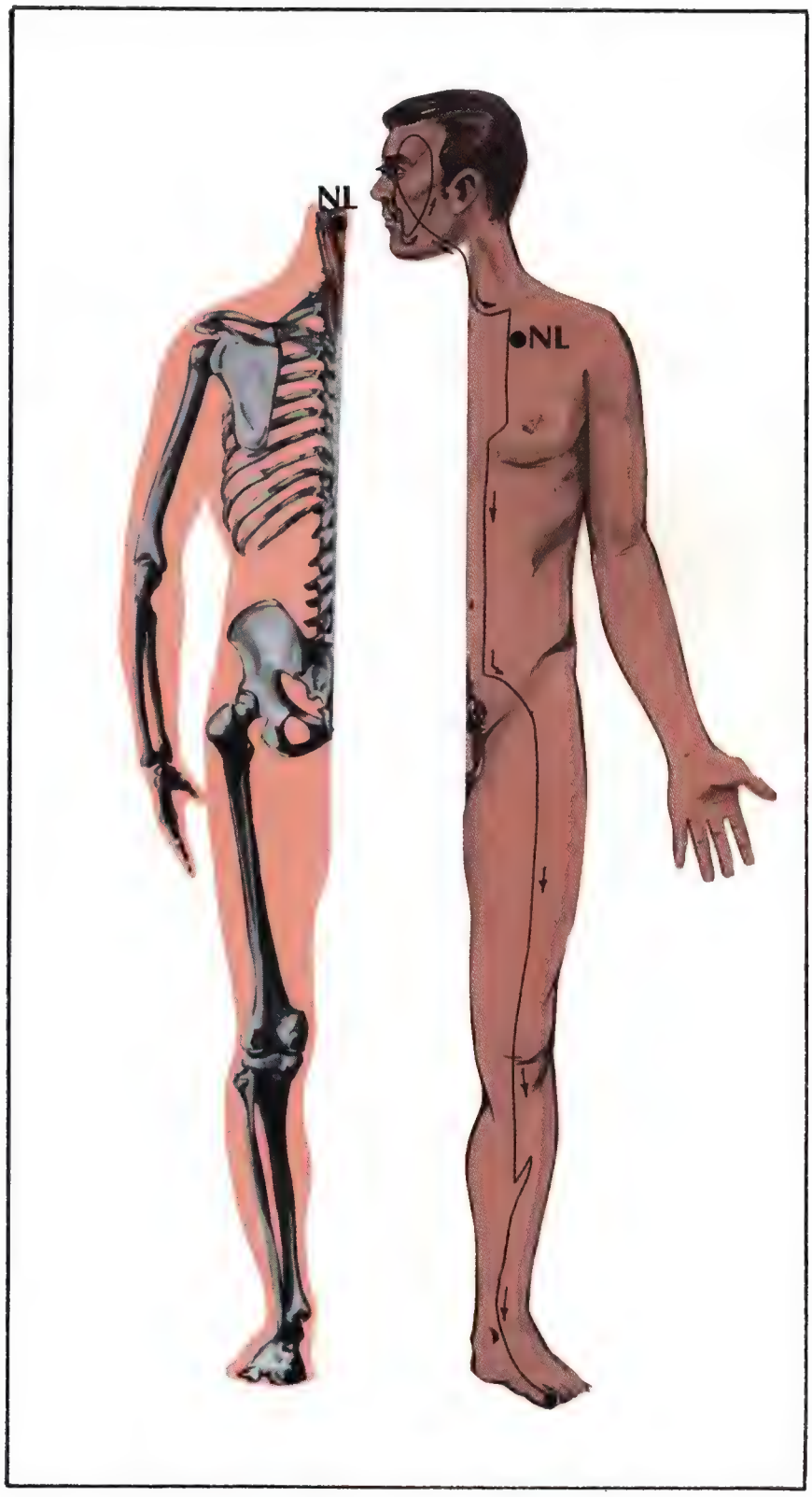

# ANTERIOR & LATERAL NECK FLEXORS - SINUSES

## SCALENUS ANTERIOR

| | |
|---|---|
| STRUCTURAL WEAKNESS | Whiplash, examine for frontal bone rotation when bilaterally weak, check for parietal bone jamming of the temporal bone when the anterior scalene is weak on the left or right individually. |
| INTERNAL MANIFESTATIONS | Sinusitis, headaches, vertigo, tinnitus, asthma, allergies, vision problems. |
| NEUROLYMPHATICS | **ANTERIOR:** Intercostal space, 3½" from the sternum on the upper ridge of the 2nd rib.<br>**POSTERIOR:** Interspinous-transverse space of C-2. |
| MERIDIAN | Stomach. |
| NUTRITION | Niacinamide and B-6, muscular cytotropic extract. |
| ASSOCIATED MUSCLES | Pectoralis major clavicular, sartorius, soleus, gastrocnemius, gracilis. |
| LAB TESTS | ESR, WBC, eosinophil count, sputum eosinophil culture. |
| EXERCISE | Isometric cervical exercises, flexion/extension exercises of the cervical spine, head rolls. |
| ACTION | Elevates the first rib, flexes and rotates the cervical column. |
| ORIGIN | Anterior tubercles of the transverse processes of the 3rd through the 6th cervical vertebrae. |
| INSERTION | The scalene tubercle and ridge on the upper and inner surface of the first rib. |
| NERVE SUPPLY | Branches of the anterior rami of the 5th through the 8th cervical nerve. |
| PALPATE | The scaleni muscles must be palpated very gently on the anterior and medial aspect of the neck. |

BILATERAL MUSCLE TEST

UNILATERAL MUSCLE TEST

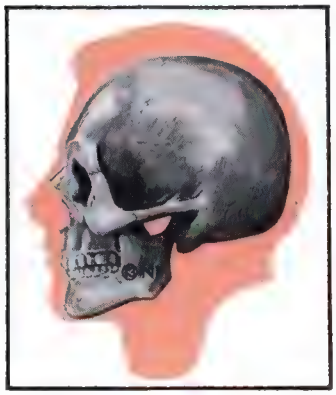

# ANTERIOR & LATERAL NECK FLEXORS - SINUSES

## SCALENUS ANTERIOR

**TO STRENGTHEN:**

**TO WEAKEN:**

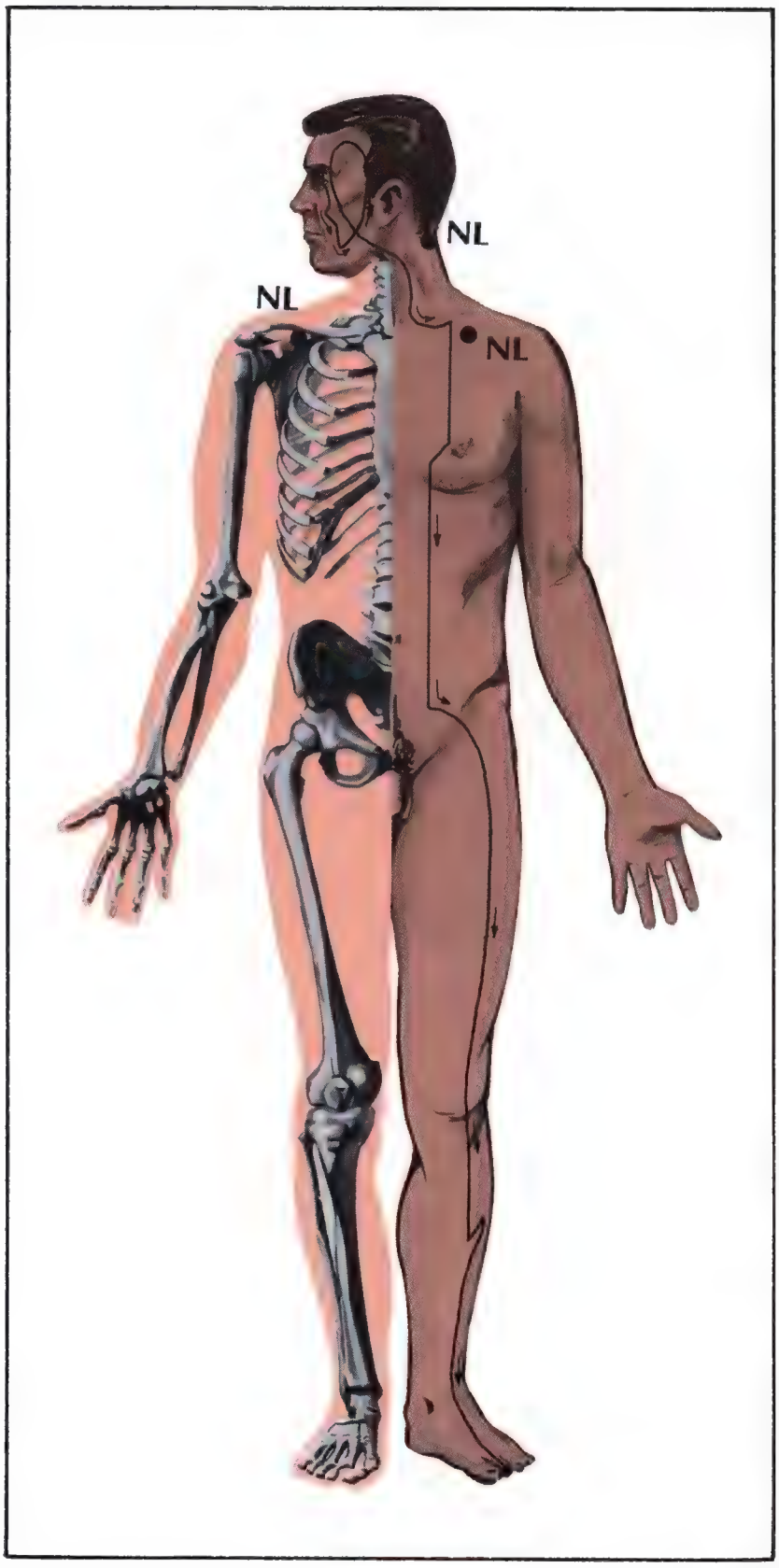

# ANTERIOR & LATERAL NECK FLEXORS - SINUSES

## SCALENUS MEDIUS

| | |
|---|---|
| **STRUCTURAL WEAKNESS** | Whiplash, examine for frontal bone rotation when bilaterally weak, check for parietal bone jamming of the temporal bone when the anterior scalene is weak on the left or right individually. |
| **INTERNAL MANIFESTATIONS** | Sinusitis, headaches, vertigo, tinnitus, asthma, allergies, vision problems. |
| **NEUROLYMPHATICS** | **ANTERIOR:** Intercostal space, 3½" from the sternum on the upper ridge of the 2nd rib.<br>**POSTERIOR:** Interspinous-transverse space of C-2. |
| **MERIDIAN** | Stomach. |
| **NUTRITION** | Niacinamide and B-6, muscular cytotropic extract. |
| **ASSOCIATED MUSCLES** | Pectoralis major clavicular, sartorius, soleus, gastrocnemius, gracilis. |
| **LAB TESTS** | ESR, WBC, eosinophil count, sputum eosinophil culture. |
| **ACTION** | Isometric cervical exercises, flexion/extension exercises of the cervical spine, head rolls. |
| **EXERCISE** | Raises the 2nd rib, bends and slightly rotates the neck. |
| **ORIGIN** | Posterior tubercles of the transverse processes of the lower 2 or 3 cervical vertebrae. |
| **INSERTION** | Upper surface of first rib behind the subclavian groove. |
| **NERVE SUPPLY** | Ventral primary divisions of the last 3 cervical nerves. |
| **PALPATE** | The scaleni muscles must be palpated very gently on the anterior and medial aspect of the neck. |

BILATERAL MUSCLE TEST

UNILATERAL MUSCLE TEST

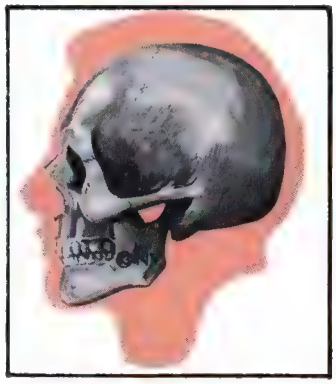

# ANTERIOR & LATERAL NECK FLEXORS - SINUSES

## SCALENUS MEDIUS

**TO STRENGTHEN:**

**TO WEAKEN:**

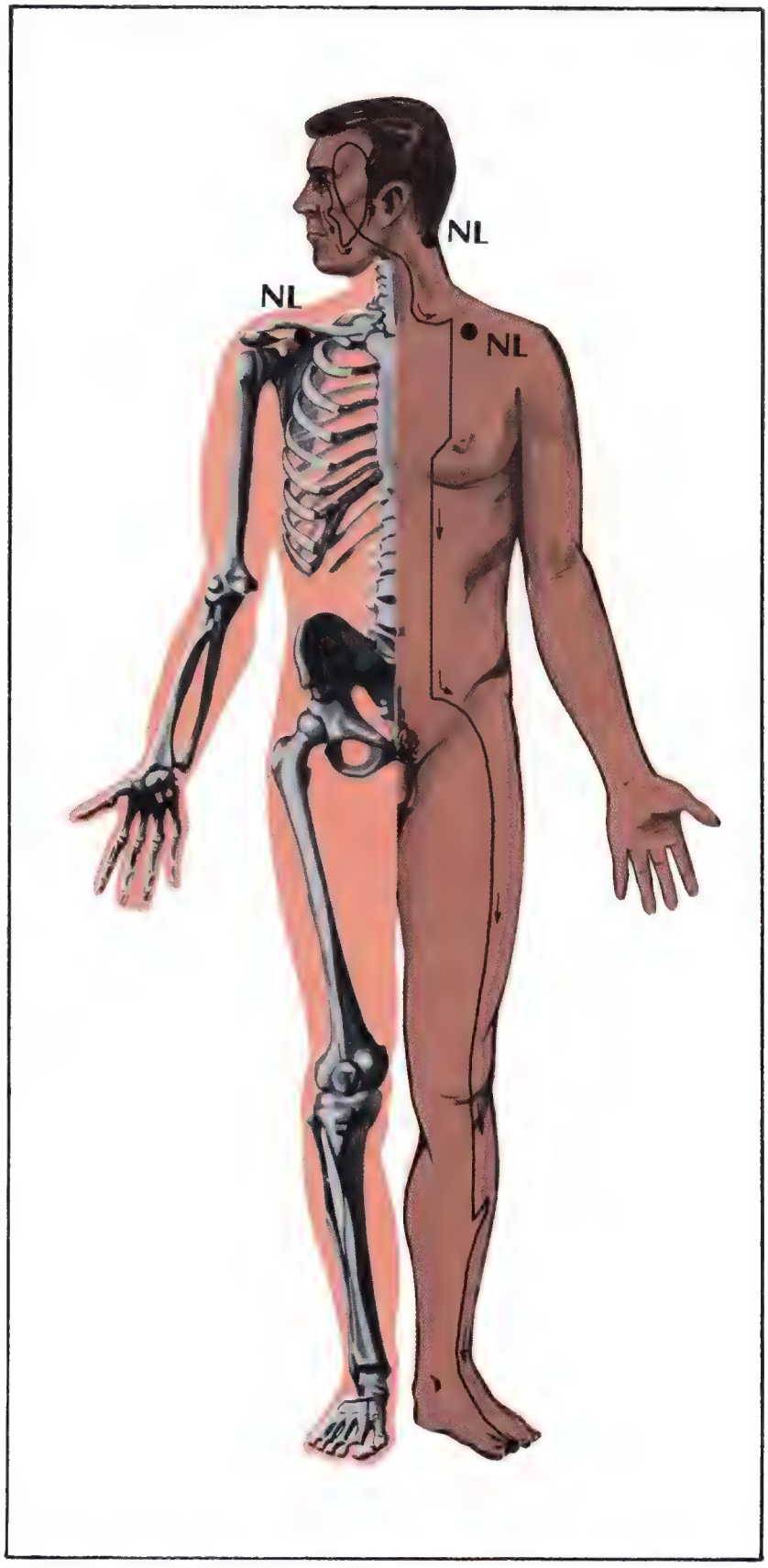

# ANTERIOR & LATERAL NECK FLEXORS - SINUSES

## SCALENUS POSTERIOR

| | |
|---|---|
| **STRUCTURAL WEAKNESS** | Whiplash, examine for frontal bone rotation when bilaterally weak, check for parietal bone jamming of the temporal bone when the anterior scalene is weak on the left or right individually. |
| **INTERNAL MANIFESTATIONS** | Sinusitis, headaches, vertigo, tinnitus, asthma, allergies, vision problems. |
| **NEUROLYMPHATICS** | **ANTERIOR:** Intercostal space, 3½" from the sternum on the upper ridge of the 2nd rib.<br>**POSTERIOR:** Interspinous-transverse space of C-2. |
| **MERIDIAN** | Stomach. |
| **NUTRITION** | Niacinamide and B-6, muscular cytotropic extract. |
| **ASSOCIATED MUSCLES** | Pectoralis major clavicular, sartorius, soleus, gastrocnemius, gracilis. |
| **LAB TESTS** | ESR, WBC, eosinophil count, sputum eosinophil culture. |
| **EXERCISE** | Isometric cervical exercises, flexion/extension exercises of the cervical spine, head rolls. |
| **ACTION** | Flexes the neck forward. |
| **ORIGIN** | Posterior tubercles of the transverse processes of the 4th through 6th cervical vertebrae. |
| **INSERTION** | Outer surface of the 2nd rib, behind attachment of serratus anterior. |
| **NERVE SUPPLY** | Lateral branches of C-3 & C-4. |
| **PALPATE** | The scaleni muscles must be palpated very gently on the anterior and medial aspect of the neck. |

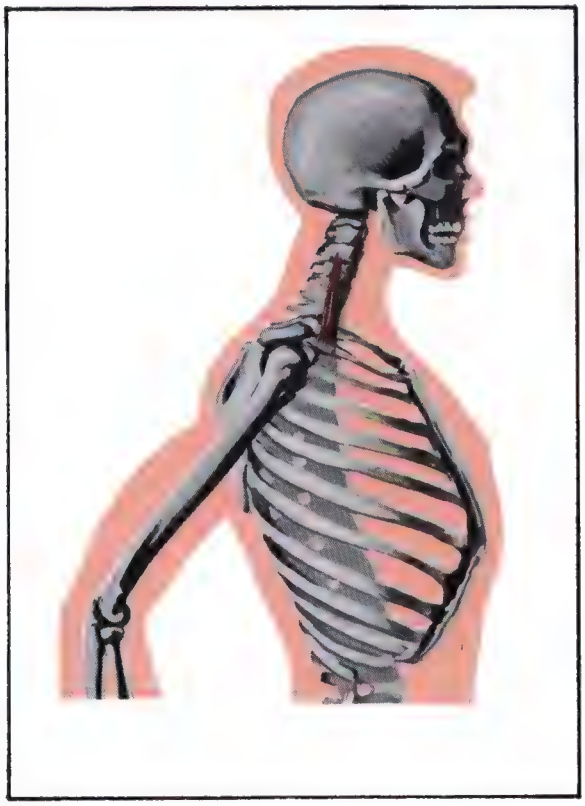

BILATERAL MUSCLE TEST

UNILATERAL MUSCLE TEST

# ANTERIOR & LATERAL NECK FLEXORS - SINUSES

## SCALENUS POSTERIOR

**TO STRENGTHEN:**

**TO WEAKEN:**

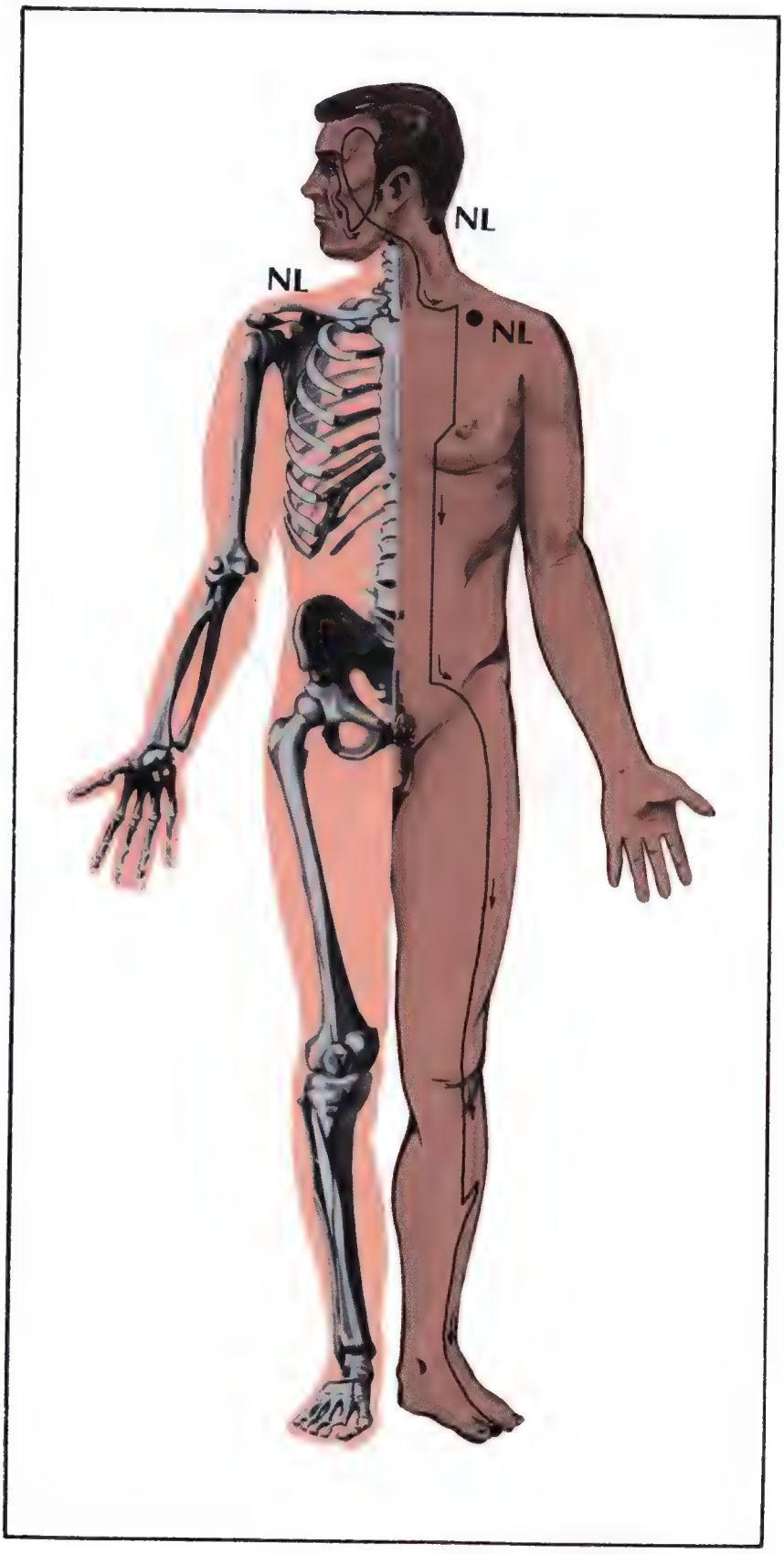

# ANTERIOR & LATERAL NECK FLEXORS - SINUSES

## STERNOCLEIDOMASTOID

| | |
|---|---|
| STRUCTURAL WEAKNESS | Whiplash, examine for frontal bone rotation when bilaterally weak, check for parietal bone jamming of the temporal bone when the anterior scalene is weak on the left or right individually. |
| INTERNAL MANIFESTATIONS | Sinusitis, headaches, vertigo, tinnitus, asthma, allergies, vision problems. |
| NEUROLYMPHATICS | **ANTERIOR:** Intercostal space, 3½" from the sternum on the upper ridge of the 2nd rib.<br>**POSTERIOR:** Interspinous-transverse space of C-2. |
| MERIDIAN | Stomach. |
| NUTRITION | Niacinamide and B-6. |
| ASSOCIATED MUSCLES | Splenius capitis, splenius cervicis, scalenus anterior, scalenus medius, scalenus posterior, hamstrings. |
| LAB TESTS | Eosinophil count, eosinophil sputum culture, WBC. |
| EXERCISE | Isometric cervical exercise, head rolls. |
| ACTION | Draws the head downward toward the shoulder and rotates it, flexes the head, raises the thoracic cavity when the head is fixed. |
| ORIGIN | **STERNAL HEAD:** Anterior surface of the manubrium.<br>**CLAVICULAR HEAD:** Upper surface of medial third of the clavicle. |
| INSERTION | Lateral surface of the mastoid, lateral half of the superior-nuchal line of the occipital bone. |
| NERVE SUPPLY | Second and third cervical and spinal portion of the accessory nerve. |
| PALPATE | Easily palpated when patient rotates the chin to one side or the other. |

CSC IN RESEARCH

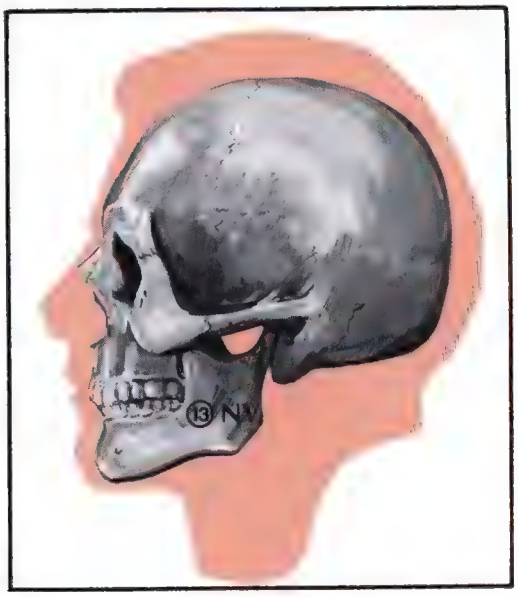

# ANTERIOR & LATERAL NECK FLEXORS - SINUSES

## STERNOCLEIDOMASTOID

**TO STRENGTHEN:**

**TO WEAKEN:**

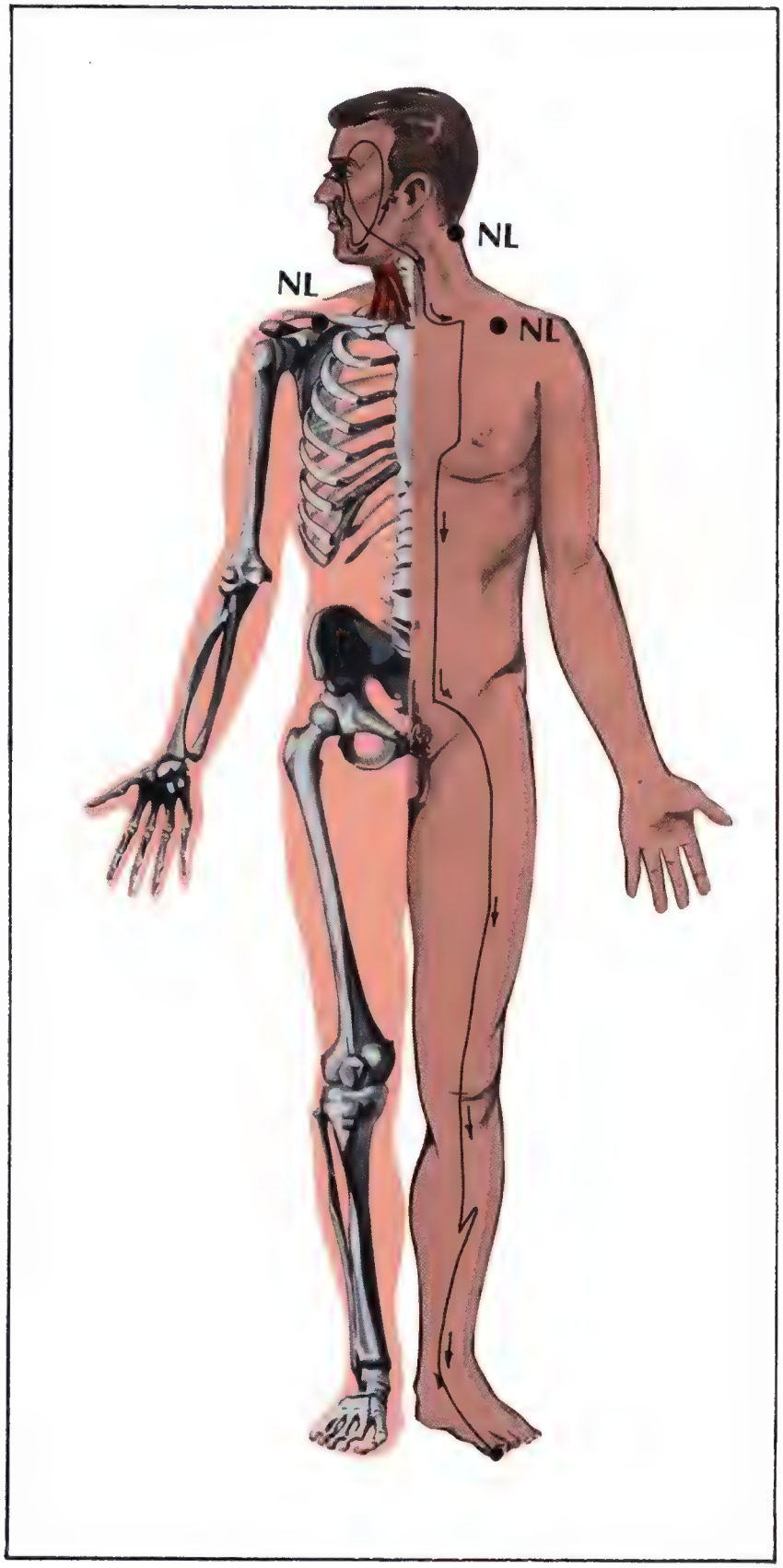

# PECTORALIS MAJOR CLAVICULAR - STOMACH

| | |
|---|---|
| **STRUCTURAL WEAKNESS** | Shoulder problems, chest pains, bilateral weakness may indicate an allergenic condition. |
| **INTERNAL MANIFESTATIONS** | Digestive disorders, allergies, liver, gallbladder and pancreatic problems, ulcers, emotional problems. |
| **NEUROLYMPHATICS** | **ANTERIOR:** On the left side, between the 6th & 7th ribs, from the mid-mammillary line to the sternum.<br>**POSTERIOR:** Between T-6 & T-7 on the left, interspinous-transverse space. |
| **MERIDIAN** | Stomach. |
| **NUTRITION** | Vitamin B, Vitamin G, betaine hydrochloride concentrates. |
| **ASSOCIATED MUSCLES** | Pectoralis major sternal, latissimus dorsi, sartorius. |
| **LAB TESTS** | Eosinophil count and eosinophil sputum culture, diagnex blue, serum amylase, SGPT, SGOT, bilirubin direct and indirect, cephalin flocculation, stool occult blood. |
| **EXERCISE** | Push-ups, pull-ups, throwing, bench presses. |
| **ACTION** | Adducts arm, draws it forward and rotates it medially. |
| **ORIGIN** | Sternal half of the clavicle, anterior surface of the sternum, cartilages of the first 3 ribs. |
| **INSERTION** | Into the crest of the lateral margin of the intertubercular groove of the humerus. |
| **NERVE SUPPLY** | Anterior thoracic nerves, C-5, 6, 7, 8 & T-1. |
| **PALPATE** | Broad area over the chest region between the clavicle & 6th rib. |

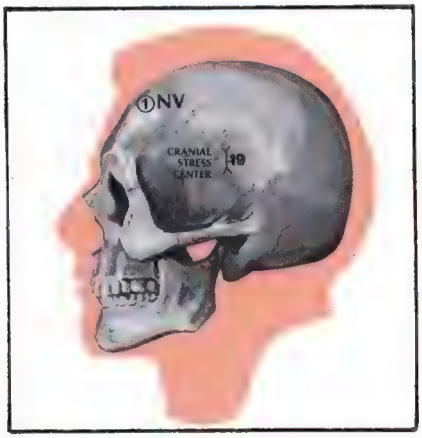


**CRANIAL STRESS CENTER #18 FOR BILATERAL WEAKNESS**

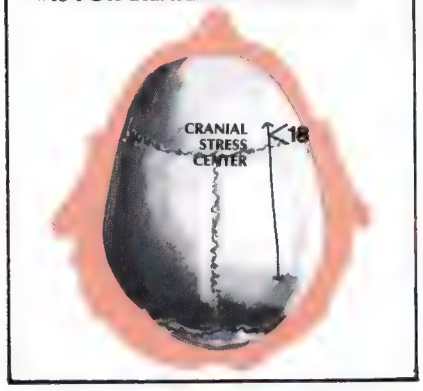

# PECTORALIS MAJOR CLAVICULAR - STOMACH

**TO STRENGTHEN:**

**TO WEAKEN:**

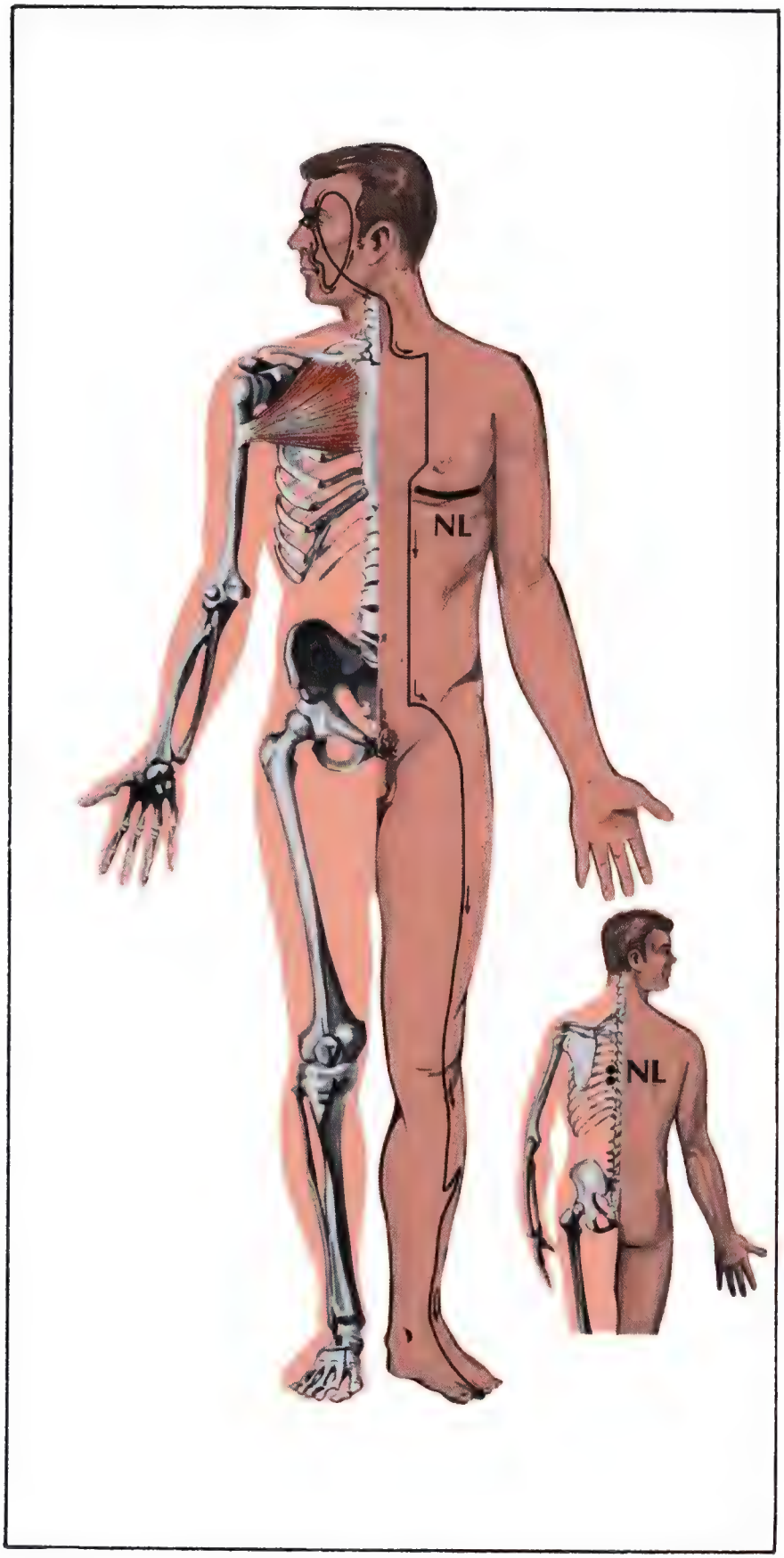

# PECTORALIS MAJOR STERNAL - LIVER

| | |
|---|---|
| STRUCTURAL WEAKNESS | Chest pain and shoulder disturbances. |
| INTERNAL MANIFESTATIONS | Glaucoma, spots before the eyes, liver conditions. |
| NEUROLYMPHATICS | **ANTERIOR:** On the right between the 5th & 6th ribs, from the nipple to the sternum.<br>**POSTERIOR:** Between T-5 & T-6, 1" to the right of the spine. |
| MERIDIAN | Liver. |
| NUTRITION | Vitamin A. |
| ASSOCIATED MUSCLES | Anterior deltoid, popliteus. |
| LAB TESTS | CBC, BUN, thymol turbidity, urinalysis, bilirubin total (direct and indirect), alkaline phosphatase, SGOT, total protein, albumin, A/G ration, LDH, cholesterol. |
| EXERCISE | Push-ups, pull-ups, throwing, bench presses. |
| ACTION | Adducts the arm, draws it downward, rotates it medially. |
| ORIGIN | The anterior surface of the sternal one-half of the clavicle, costal cartilages of the upper seven ribs, external oblique aponeurosis. |
| INSERTION | Into the crest of the greater tubercle of the humerus, lateral margin of the intertubercular groove. |
| NERVE SUPPLY | Medial and lateral anterior thoracic, C-5, 6, 7, 8 & T-1. |
| PALPATE | Palpate the coracoid process of the scapula in the lower aspect of the margin of the 3rd & 4th ribs. |

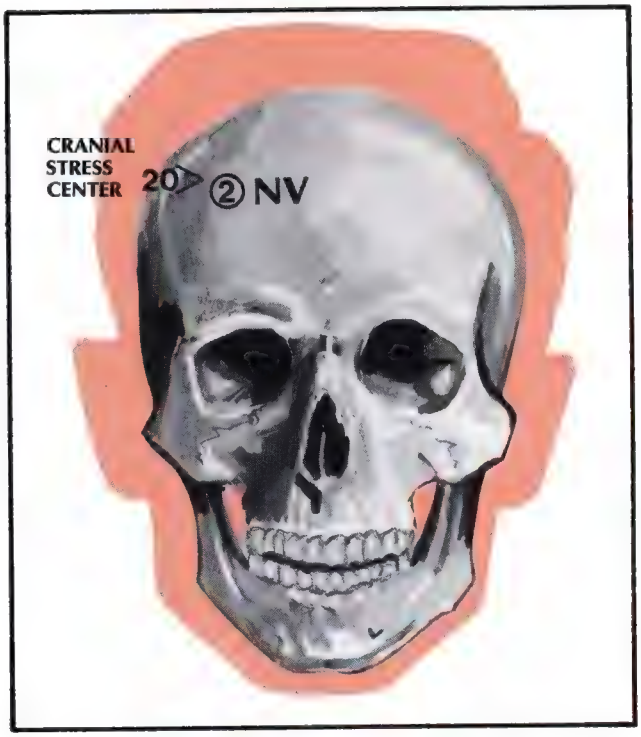

# PECTORALIS MAJOR STERNAL - LIVER

**TO STRENGTHEN:**

**TO WEAKEN:**

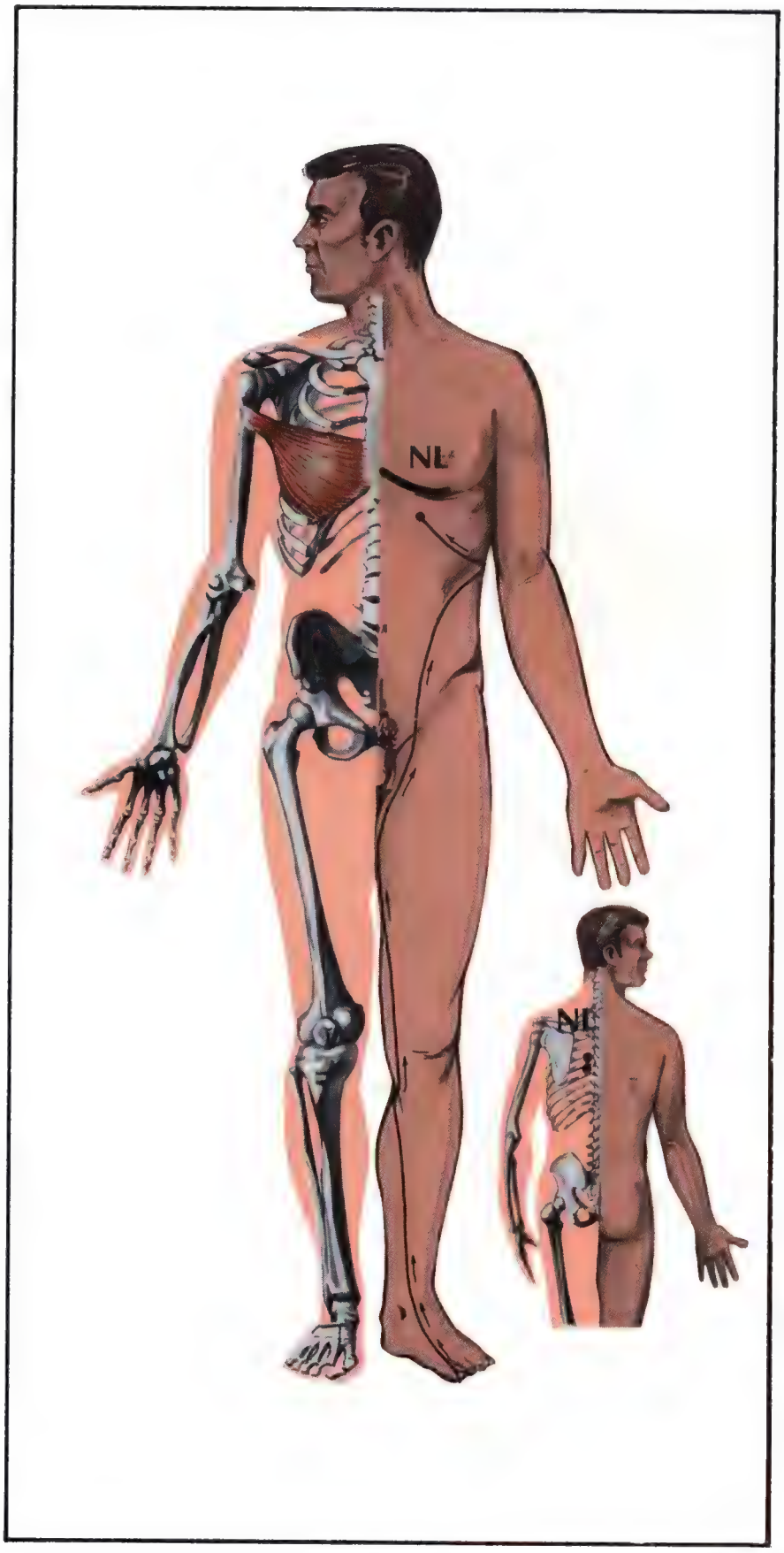

# PERONEUS - BLADDER

## PERONEUS BREVIS

| | |
|---|---|
| STRUCTURAL WEAKNESS | Foot drop, gait problems, ankle problems in children especially. |
| INTERNAL MANIFESTATIONS | IN RESEARCH. |
| NEUROLYMPHATICS | **ANTERIOR:** Inferior ramus of the pubic bones, center of the umbilicus.<br>**POSTERIOR:** Junction of 5th lumbar transverse process and sacrum. |
| MERIDIAN | Bladder. |
| NUTRITION | Calcium, Vitamin B, avoidance of foods containing oxalic acid may be necessary, e.g., coffee, chocolate, cranberries, purple fruit. |
| ASSOCIATED MUSCLES | Piriformis, sacrospinalis. |
| LAB TESTS | IN RESEARCH. |
| EXERCISE | Running, jumping, hopping, skipping. |
| ACTION | Plantar flexes the foot and everts it. |
| ORIGIN | Distal two-thirds of lateral surface of body of the fibula and adjacent intermuscular septa. |
| INSERTION | Base of the tuberocity of the 5th metatarsal, lateral side. |
| NERVE SUPPLY | Peroneal, L-4, 5 & S-1. |
| PALPATE | The tendon of the muscle may be palpated at the head of the 5th metatarsal. |

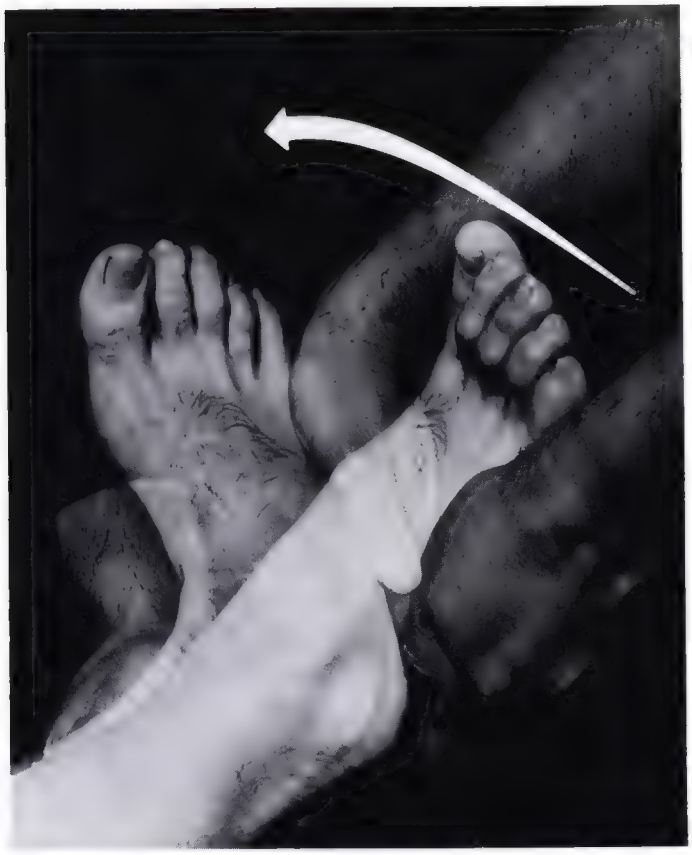

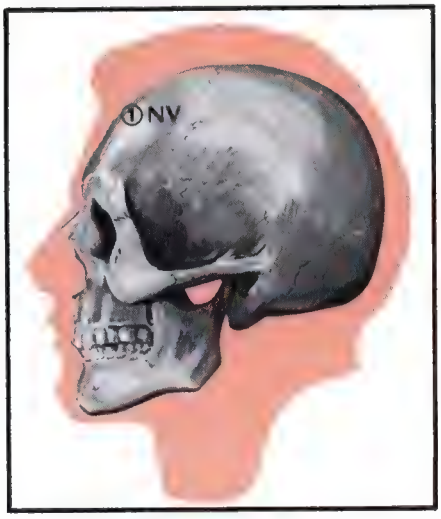


CSC IN RESEARCH

# PERONEUS - BLADDER
## PERONEUS BREVIS

**TO STRENGTHEN:**

**TO WEAKEN:**

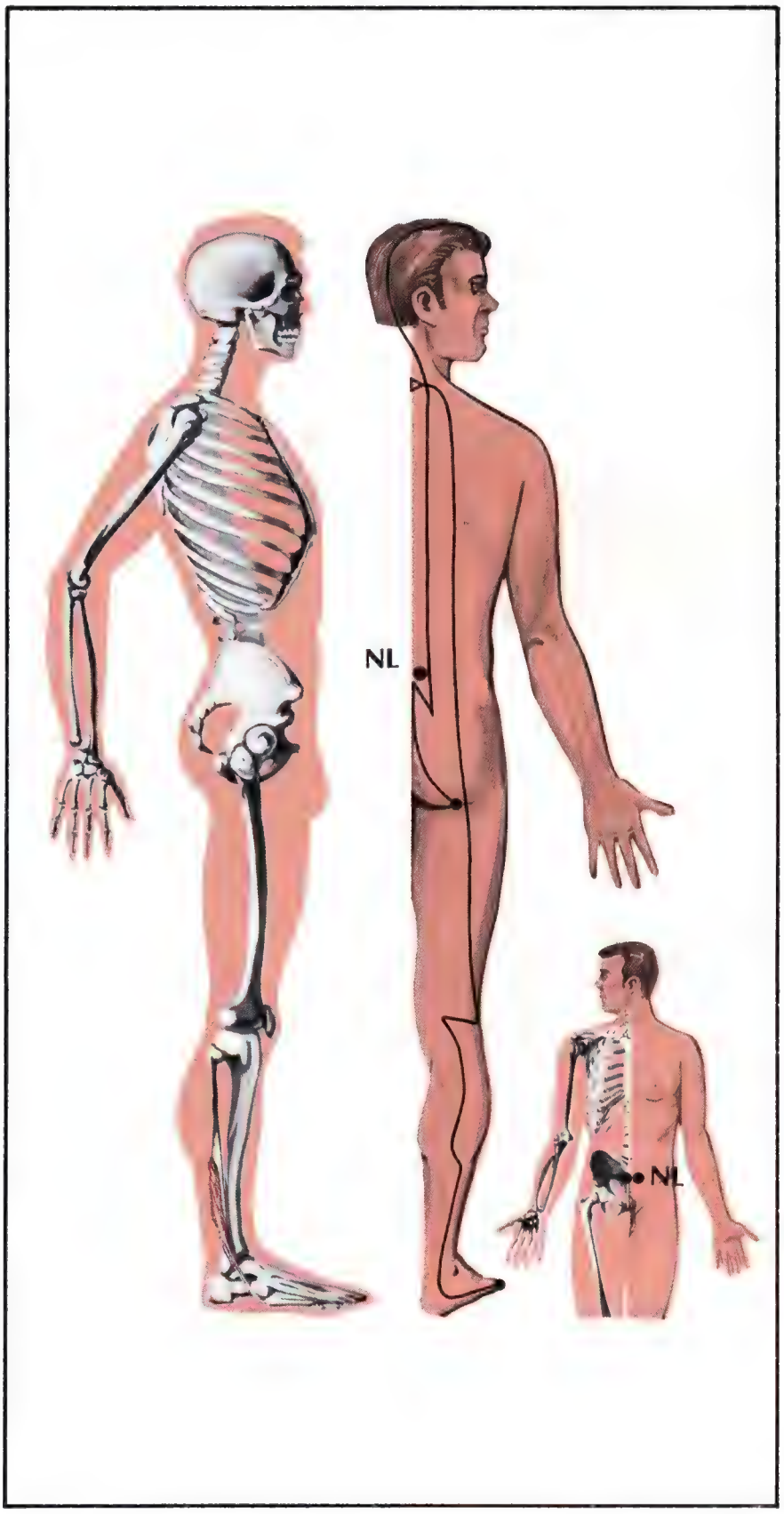

# PERONEUS - BLADDER

## PERONEUS LONGUS

| | |
|---|---|
| STRUCTURAL WEAKNESS | Foot drop, gait problems, ankle problems in children especially. |
| INTERNAL MANIFESTATIONS | IN RESEARCH. |
| NEUROLYMPHATICS | **ANTERIOR:** Inferior ramus of the pubic bones, center of the umbilicus.<br>**POSTERIOR:** Junction of 5th lumbar transverse process and sacrum. |
| MERIDIAN | Bladder. |
| NUTRITION | Calcium, Vitamin B, avoidance of foods containing oxalic acid may be necessary, e.g., coffee, chocolate, cranberries, purple fruit. |
| ASSOCIATED MUSCLES | Piriformis, sacrospinalis. |
| LAB TESTS | IN RESEARCH. |
| EXERCISE | Running, jumping, hopping, skipping. |
| ACTION | Plantar flexes the foot and everts it. |
| ORIGIN | Lateral condyle of tibia, head and upper two-thirds of the lateral side of the fibula, intermuscular septa and fascia. |
| INSERTION | Lateral side of base of the first metatarsal and the lateral side of the medial cuneiform. |
| NERVE SUPPLY | Peroneal, L-4, 5 & S-1. |
| PALPATE | The tendon of the muscle may be palpated at the head of the 5th metatarsal. |

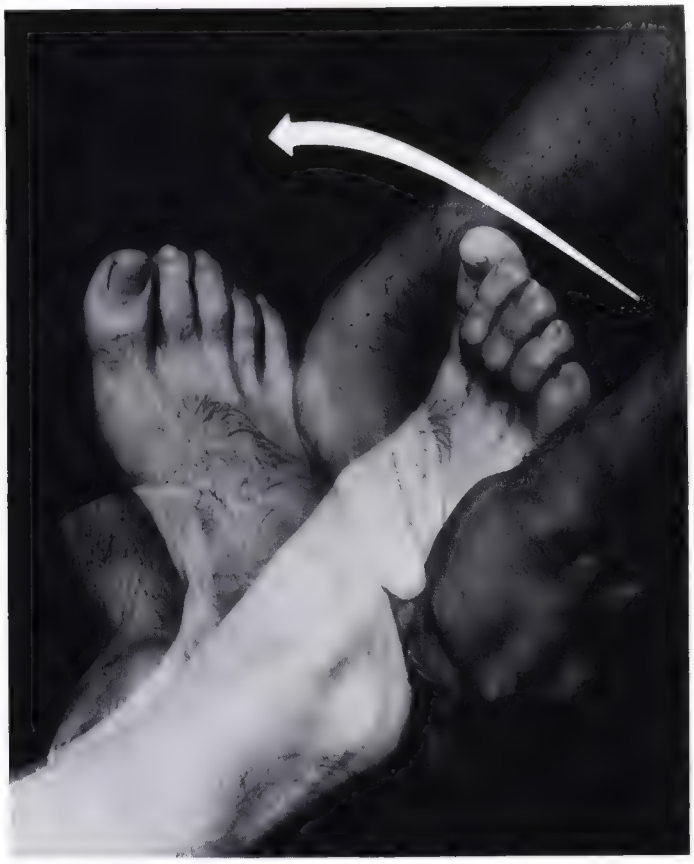

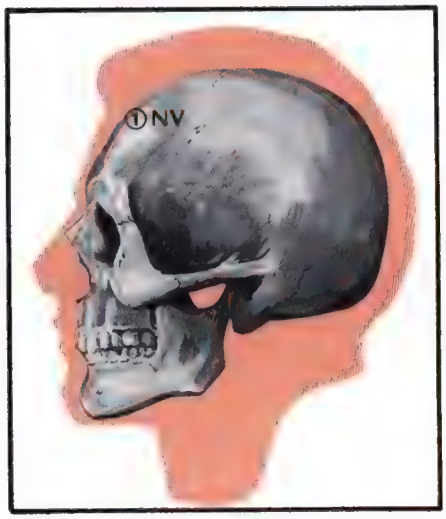


CSC IN RESEARCH

# PERONEUS - BLADDER
## PERONEUS LONGUS

**TO STRENGTHEN:**

**TO WEAKEN:**

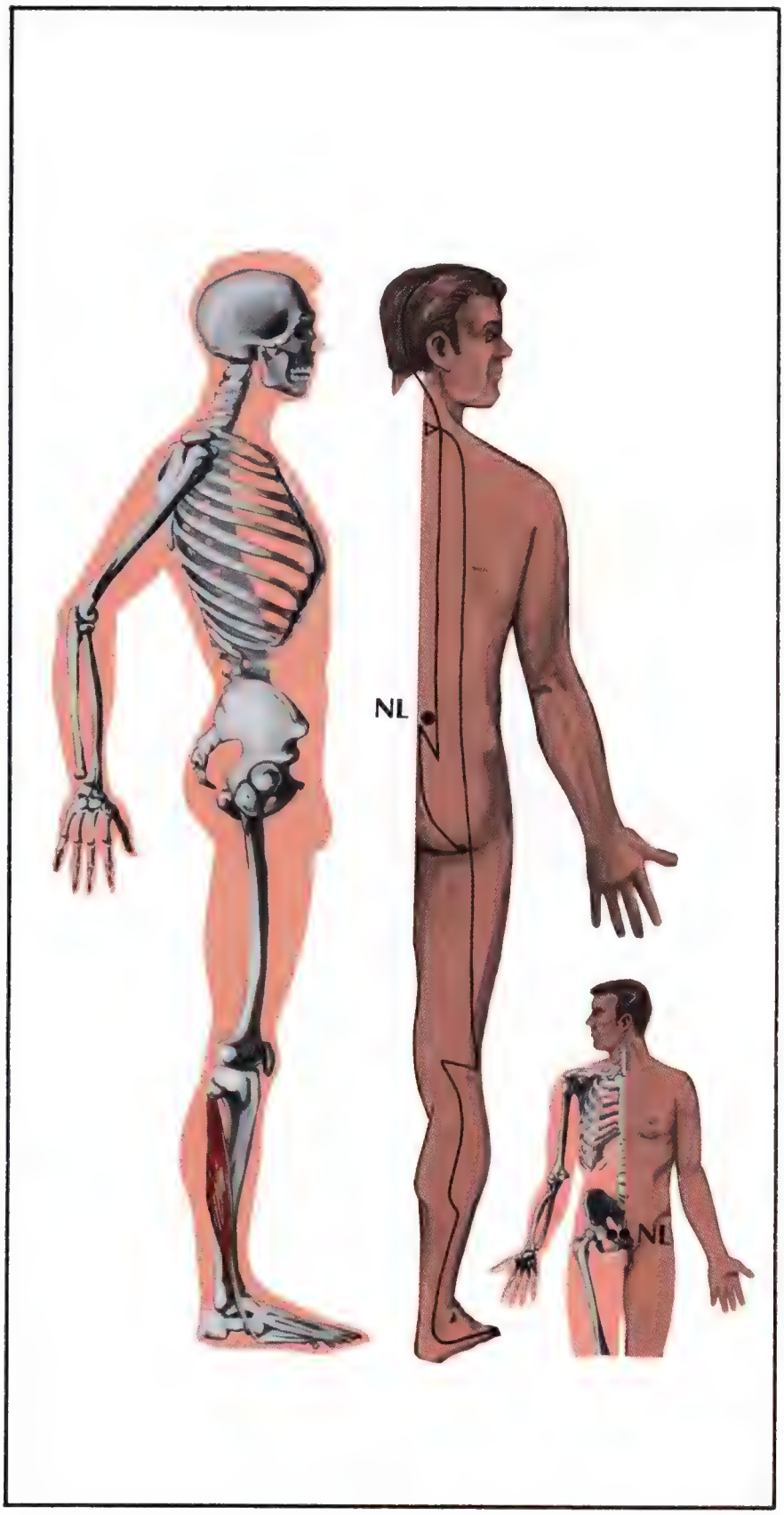

# PERONEUS TERTIUS (5th TENDON) - BLADDER

| | |
|---|---|
| STRUCTURAL WEAKNESS | Foot drop, gait problems, ankle problems in children especially. |
| INTERNAL MANIFESTATIONS | IN RESEARCH. |
| NEUROLYMPHATICS | **ANTERIOR:** Inferior ramus of the pubic bones, center of the umbilicus.<br>**POSTERIOR:** Junction of 5th lumbar transverse process and sacrum. |
| MERIDIAN | Bladder. |
| NUTRITION | Calcium, Vitamin B, avoidance of foods containing oxalic acid may be necessary, e.g., coffee, chocolate, cranberries, purple fruit. |
| ASSOCIATED MUSCLES | Piriformis, sacrospinalis. |
| LAB TESTS | IN RESEARCH. |
| EXERCISE | Running, jumping, hopping, skipping. |
| ACTION | Dorsiflexes and everts the foot. |
| ORIGIN | Lower one-third of the anterior surface of fibula, lower interosseous membrane and adjacent intermuscular septum between it and peroneus brevis. |
| INSERTION | Dorsal surface of the base of the 5th metatarsal. |
| NERVE SUPPLY | Peroneal, L-4, 5 & S-1. |
| PALPATE | Lateral side of the foot. |

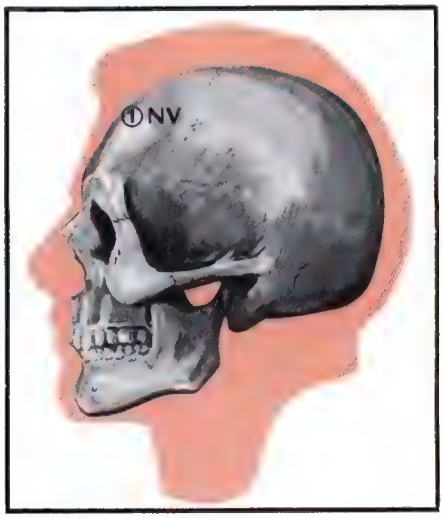


CSC IN RESEARCH

# PERONEUS TERTIUS (5th TENDON) - BLADDER

**TO STRENGTHEN:**

**TO WEAKEN:**

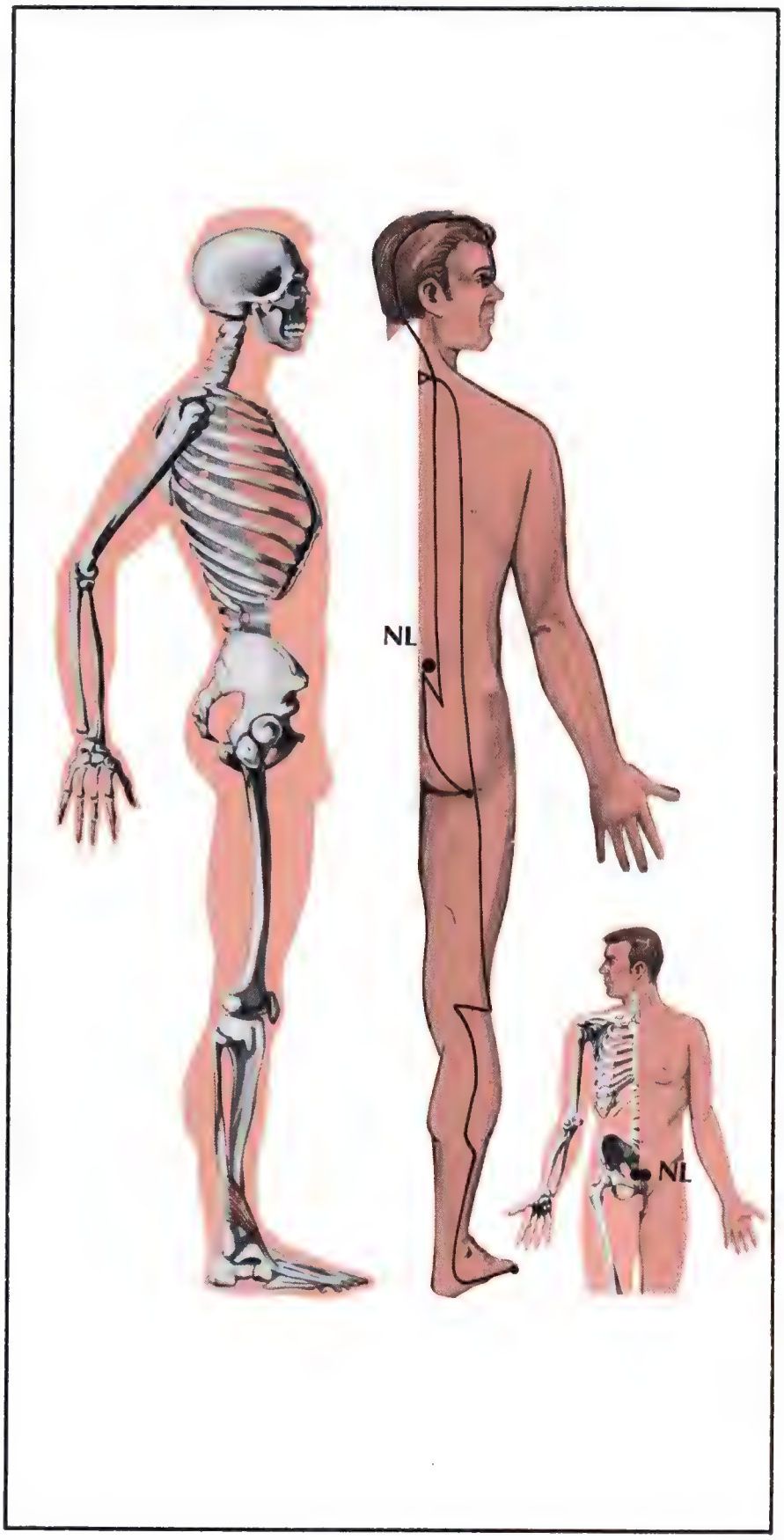

# PIRIFORMIS - UTERUS & SEMINAL VESICLES

| | |
|---|---|
| STRUCTURAL WEAKNESS | Sciatic pain, tingling or numbness in the leg, sacral twist or rotation, iliac fixation, posterior sacrum, important in posture (may cause one foot to turn out). |
| INTERNAL MANIFESTATIONS | Burning on urination and related bladder problems, tipped uterus. |
| NEUROLYMPHATICS | **ANTERIOR:** Upper edge of the ramus of the pubic bones.<br>**POSTERIOR:** Between the spinous process of L-5 and the posterior superior iliac spine. |
| MERIDIAN | Circulation Sex. |
| NUTRITION | Vitamin E, wheat germ, natural uterine and testicular tissue extracts. |
| ASSOCIATED MUSCLES | Hamstrings, gluteus medius, adductors. |
| LAB TESTS | CBC, urinalysis, creatinine, sperm count, 17-ketosteroids, ESR, total and fractionated estrogens. |
| EXERCISE | While standing on one leg, forcefully turn the body laterally from the femur, repeat on opposite side. |
| ACTION | Rotates thigh laterally, abducts thigh when limb is flexed. |
| ORIGIN | Anterior pelvic surface of sacrum, three fleshy digitations attached to the portions of the bone between the first 4 sacral foramen, margin of the greater sciatic foramina. |
| INSERTION | Superior border of greater trochanter of femur. |
| NERVE SUPPLY | Sacral plexus, L-5, S-1 & 2. |
| PALPATE | Cannot be palpated. |

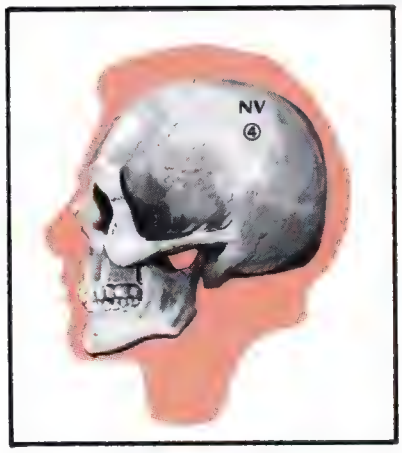

# PIRIFORMIS - UTERUS & SEMINAL VESICLES

**TO STRENGTHEN:**

**TO WEAKEN:**

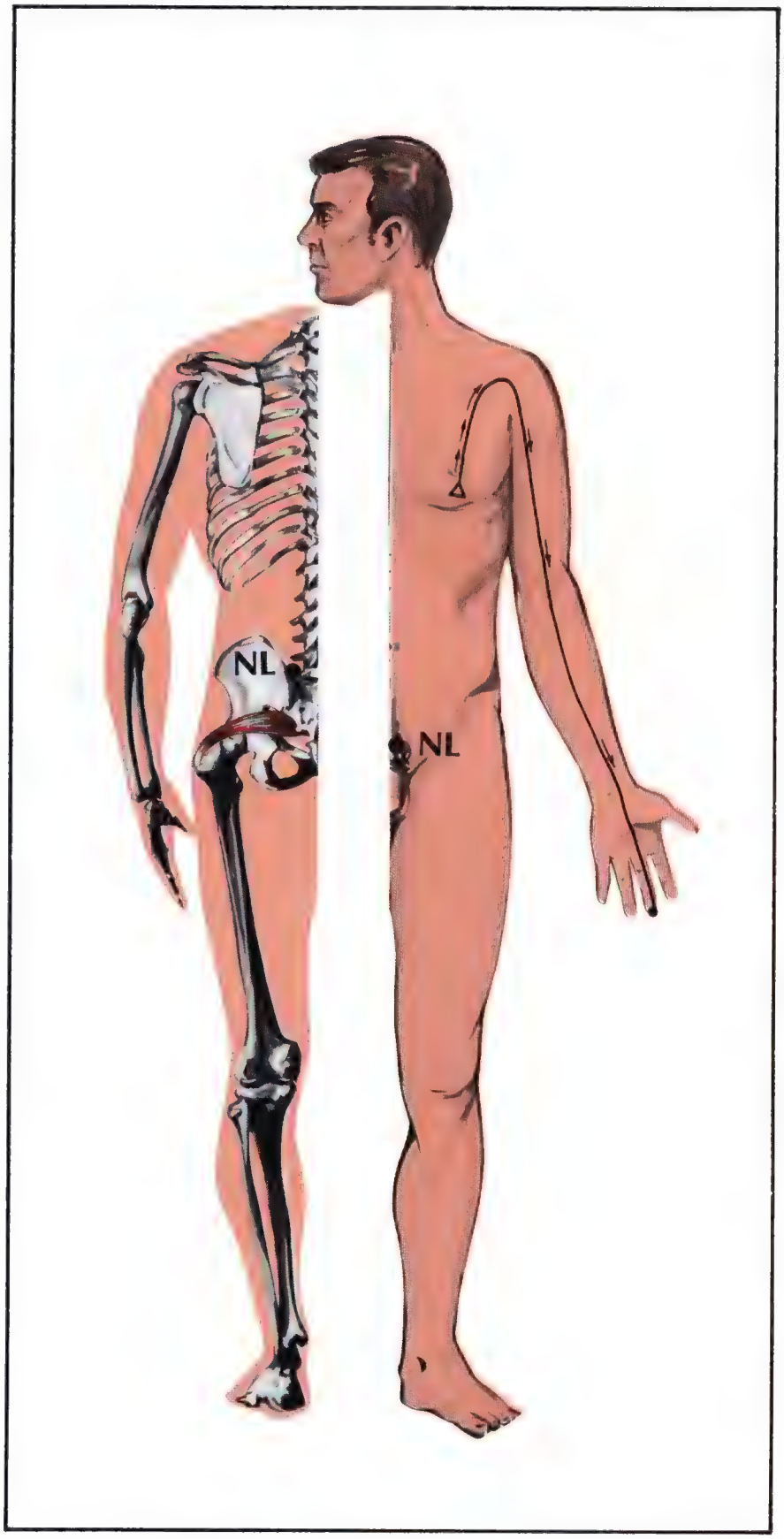

# POPLITEUS - GALL BLADDER

| | |
|---|---|
| STRUCTURAL WEAKNESS | Knee problems (including hyperextension and difficult flexion), rib fixation, fixation of the lower three cervicals will cause bilateral weakness. |
| INTERNAL MANIFESTATIONS | Gallbladder conditions, jaundice, shingles, unilateral headaches, constipation, drowsiness after eating fatty foods. |
| NEUROLYMPHATICS | **ANTERIOR:** Between the 5th & 6th ribs, from the nipple to the sternum on the right side.<br>**POSTERIOR:** Between T-5 & 6, 1" to the right side of the spine. |
| MERIDIAN | Gallbladder. |
| NUTRITION | Vitamin A. |
| ASSOCIATED MUSCLES | Quadriceps, pectoralis major clavicular, levator costalis, anterior deltoid. |
| LAB TESTS | CBC, serum bilirubin, ESR, cephalin flocculation, hematocrit. |
| EXERCISE | Walking, running, leg lifts with weights. |
| ACTION | Inward rotation of the tibia, flexes the leg. |
| ORIGIN | Lateral condyle of the femur, oblique popliteal ligament of knee. |
| INSERTION | Triangular area of the posterior surface of the tibia above the popliteal line. |
| NERVE SUPPLY | Tibial nerve, L-4, 5 & S-1. |
| PALPATE | Cannot be palpated. |

Patient in prone position with knee bent, leg at 45 degree angle.

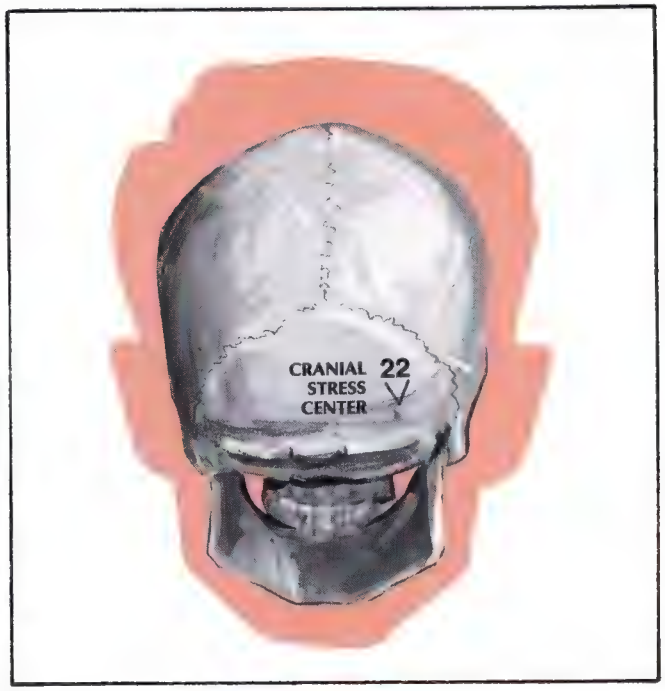

# POPLITEUS - GALL BLADDER

**TO STRENGTHEN:**

**TO WEAKEN:**

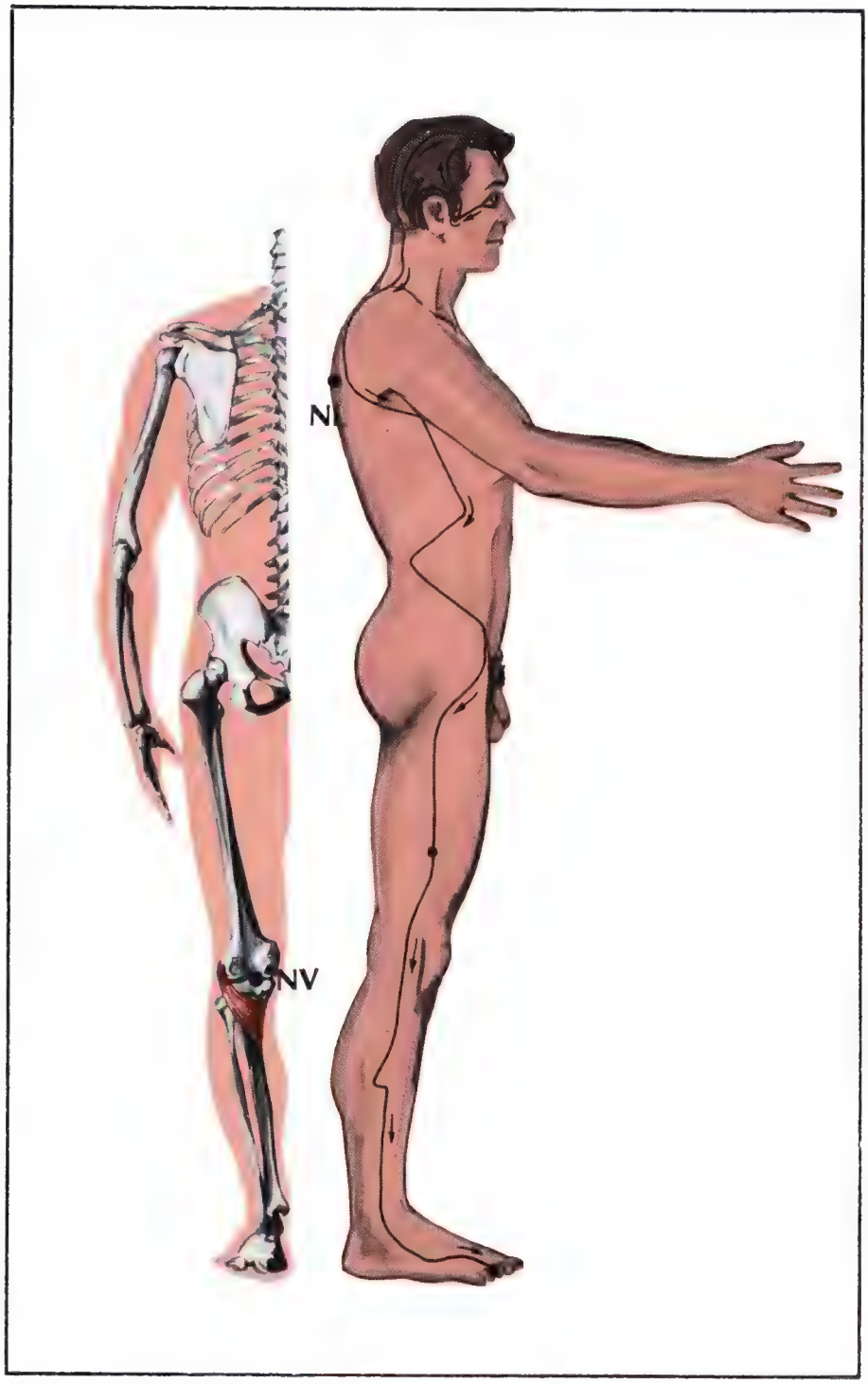

# PSOAS MAJOR - KIDNEY

| | |
|---|---|
| STRUCTURAL WEAKNESS | Low hip while standing, nagging low back pain, early morning backaches, if bilaterally weak, check for occiput/atlas subluxation, tarsal tunnel syndrome. |
| INTERNAL MANIFESTATIONS | Kidney infections and other related kidney disorders, skin conditions, heart conditions, restlessness. |
| NEUROLYMPHATICS | **ANTERIOR:** 1" to the sides and 1" above the navel.<br>**POSTERIOR:** Just below the level of the last ribs, 1" lateral to the spine. |
| MERIDIAN | Kidney. |
| NUTRITION | Vitamin A, Vitamin E, kidney extracts. |
| ASSOCIATED MUSCLES | Tensor fascia lata, upper trapezius, gluteus medius, gluteus minimus, sacrospinalis. |
| LAB TESTS | WBC, blood and urine creatinine level, NPN, BUN, cardiac enzymes, RBC, hematocrit, HGB. |
| EXERCISE | Leg raises and leg lowerings while supine, running, jogging, lifting the legs high. |
| ACTION | Flexes femur on the pelvis and rotates femur medially. When the femur is fixed, the iliopsoas muscle pulls on the vertebrae and flexes the spine and pelvis on the femur. |
| ORIGIN | Anterior surfaces of the transverse processes and bodies of all lumbar vertebrae, T-12 and corresponding discs. |
| INSERTION | Lesser trochanter of femur. |
| NERVE SUPPLY | Lumbar plexus, L-1, 2, 3 & 4. |
| PALPATE | Almost impossible to palpate, even with complete relaxation of the rectus abdominis. |

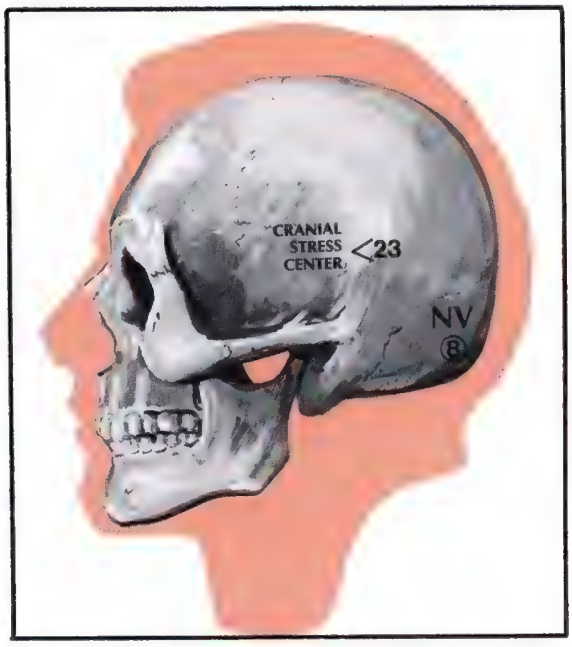

# PSOAS MAJOR - KIDNEY

**TO STRENGTHEN:**

**TO WEAKEN:**

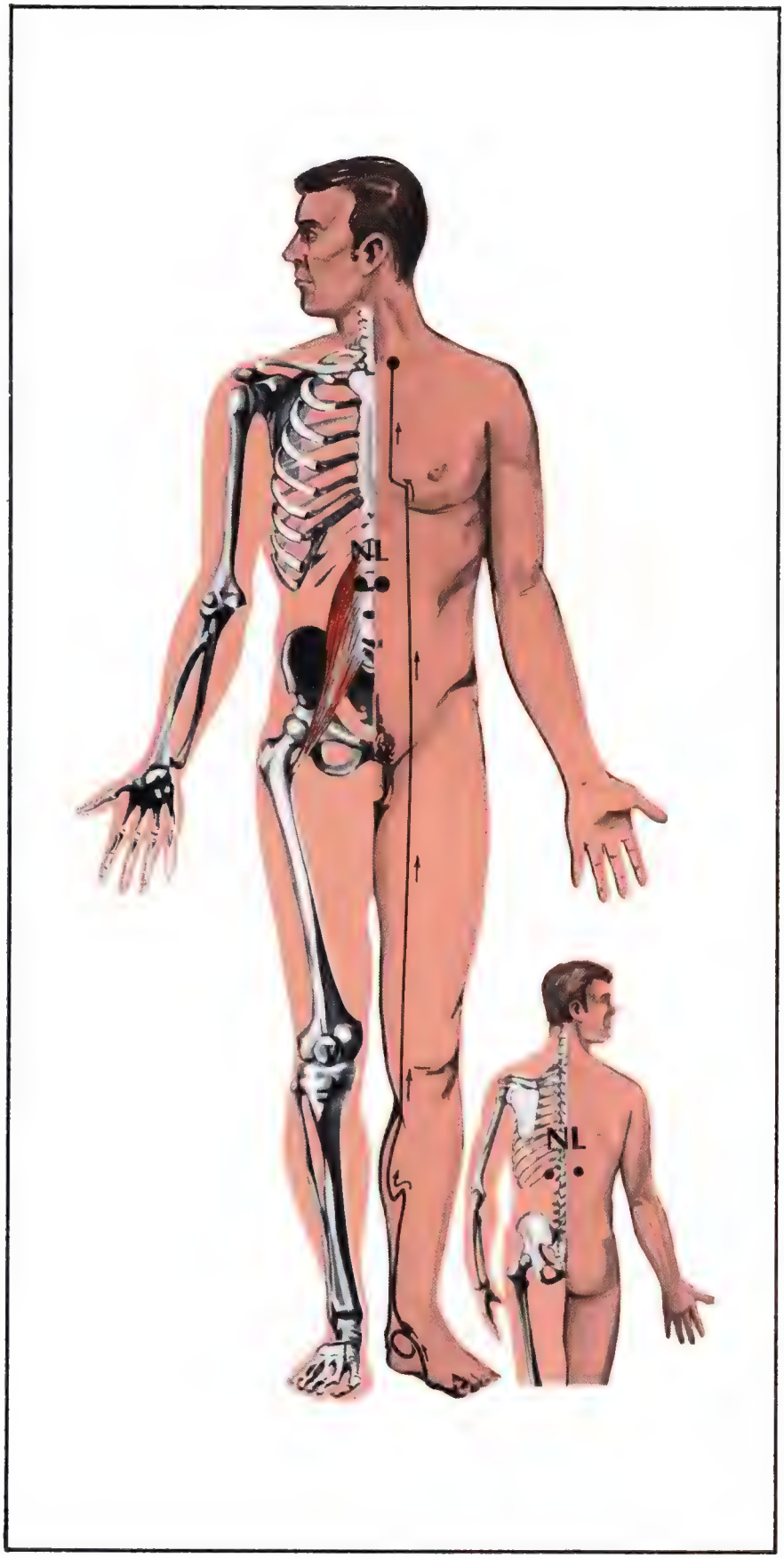

# EXTERNAL PTERYGOID

## LATERAL

| | |
|---|---|
| STRUCTURAL WEAKNESS | External or internal frontal bone rotation, whiplash, cervical trauma, jaw problems. |
| INTERNAL MANIFESTATIONS | Headaches, vision problems, vertigo, tinnitus, asthma, allergies, sinusitis. |
| NEUROLYMPHATICS | **ANTERIOR:** Bilaterally, lateral to the coracoid process, and possibly the 2nd & 3rd intercostal space adjacent to the sternum.<br>**POSTERIOR:** Atlas interspinous-transverse space. |
| MERIDIAN | Stomach. |
| NUTRITION | Niacinamide and B-6, muscular cytotropic extract. This is being researched further. |
| ASSOCIATED MUSCLES | Anterior and posterior cervical muscles. |
| LAB TESTS | WBC, eosinophil count, eosinophil sputum culture. |
| EXERCISE | Opening and closing movements of the mouth, lateral motion of the mouth. |
| ACTION | Opens the jaw. |
| ORIGIN | **UPPER HEAD:** Lower part of lateral surface of the great wing of the sphenoid and from the infratemporal crest.<br>**LOWER HEAD:** From the lateral surface of the lateral pterygoid plate. |
| INSERTION | Anterior part of condyle of mandible, capsule of the mandibular joint. |
| NERVE SUPPLY | External pterygoid nerve from the mandibular division of the trigeminal nerve. |
| PALPATE | Just lateral to and above the last molar. |

CSC IN RESEARCH

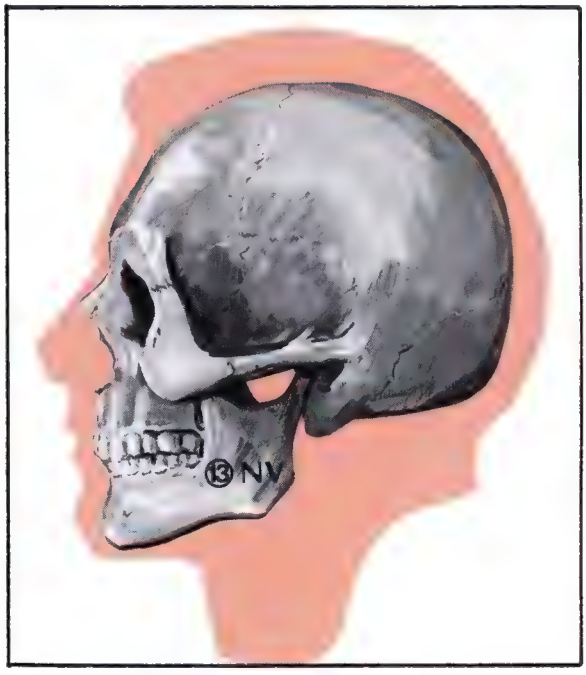

# EXTERNAL PTERYGOID
## LATERAL

TO STRENGTHEN:

TO WEAKEN:

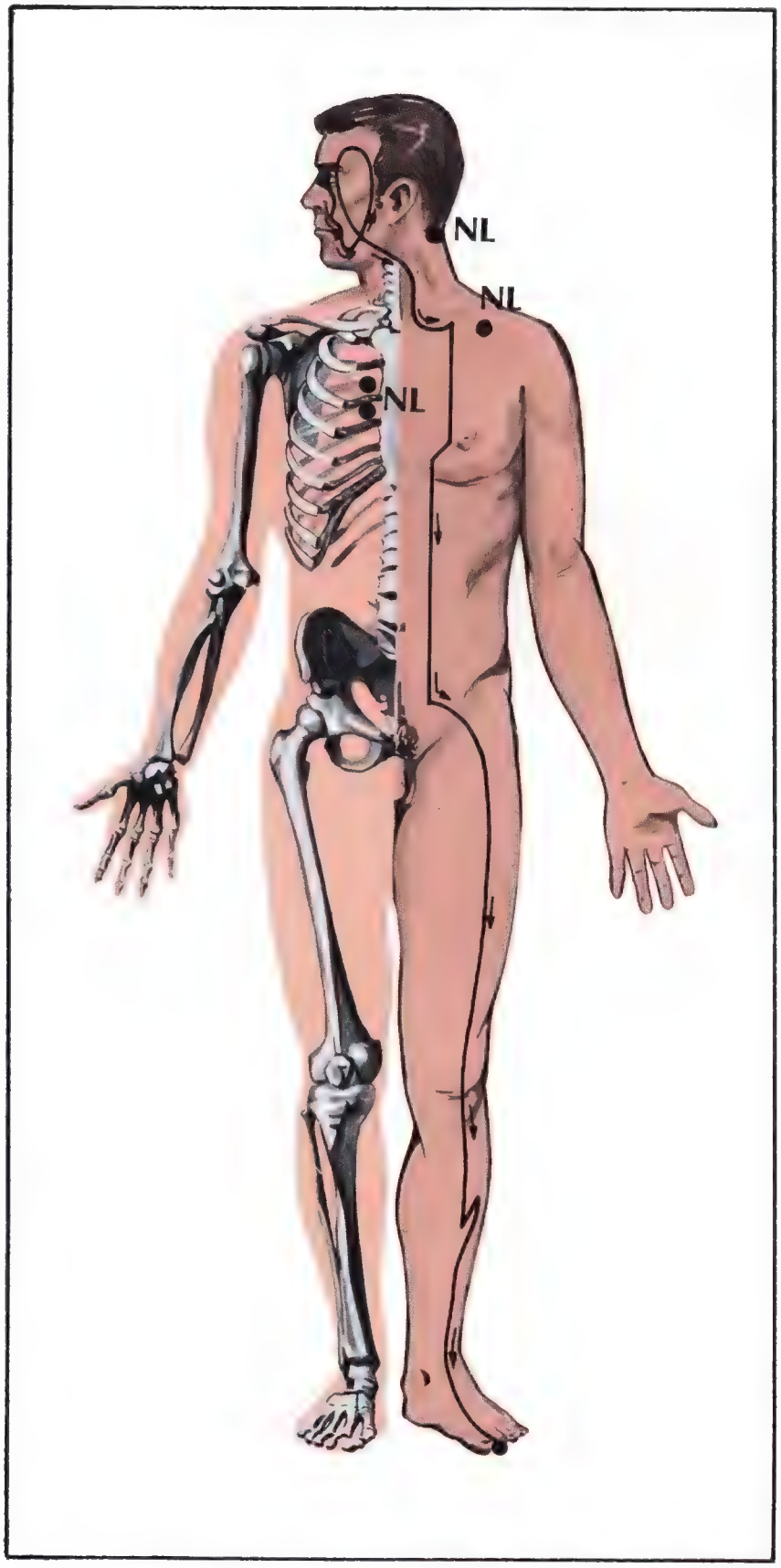

# INTERNAL PTERYGOID

## MEDIAL

| | |
|---|---|
| STRUCTURAL WEAKNESS | External or internal frontal bone rotation, whiplash, cervical trauma, jaw problems. |
| INTERNAL MANIFESTATIONS | Headaches, vision problems, vertigo, tinnitus, asthma, allergies, sinusitis. |
| NEUROLYMPHATICS | **ANTERIOR:** Bilaterally, lateral to the coracoid process.<br>**POSTERIOR:** Atlas interspinous-transverse space. |
| MERIDIAN | Stomach. |
| NUTRITION | Niacinamide and B-6, muscular cytotropic extract. This is being researched further. |
| ASSOCIATED MUSCLES | Anterior and posterior cervical muscles. |
| LAB TESTS | WBC, eosinophil count, eosinophil sputum culture. |
| EXERCISE | Opening and closing movements of the mouth, lateral motion of the mouth. |
| ACTION | Protracts and elevates lower jaw, assists in rotary motion while chewing, closes the jaw. |
| ORIGIN | Medial surface of the lateral pterygoid plate, small slip from the tuberosity of the maxilla and pyramidal process of the palatine bone. |
| INSERTION | Lower and back part of the medial surface of the ramus and angle of the mandible. |
| NERVE SUPPLY | Internal pterygoid from the mandibular division of the trigeminal. |
| PALPATE | Place finger along the lateral border of the molar teeth until you palpate the pterygoid process of sphenoid. |

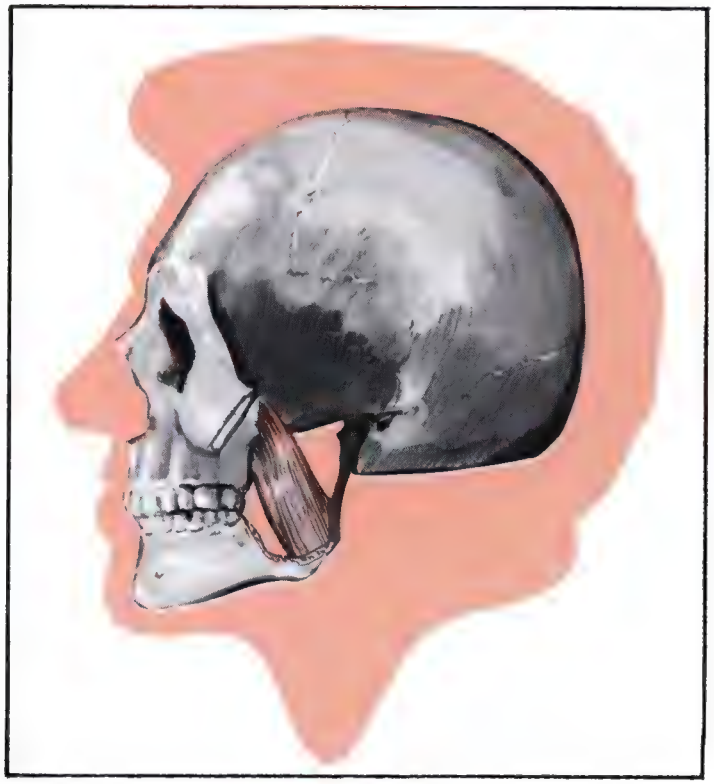

CSC IN RESEARCH

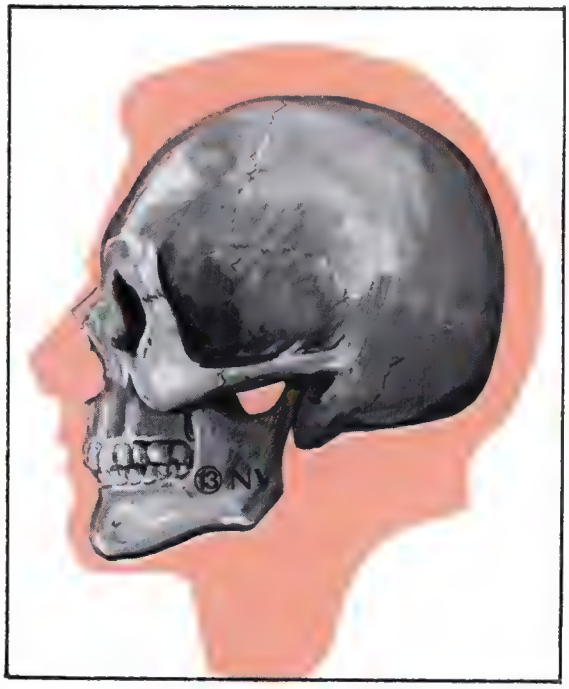

# INTERNAL PTERYGOID
## MEDIAL

TO STRENGTHEN:

TO WEAKEN:

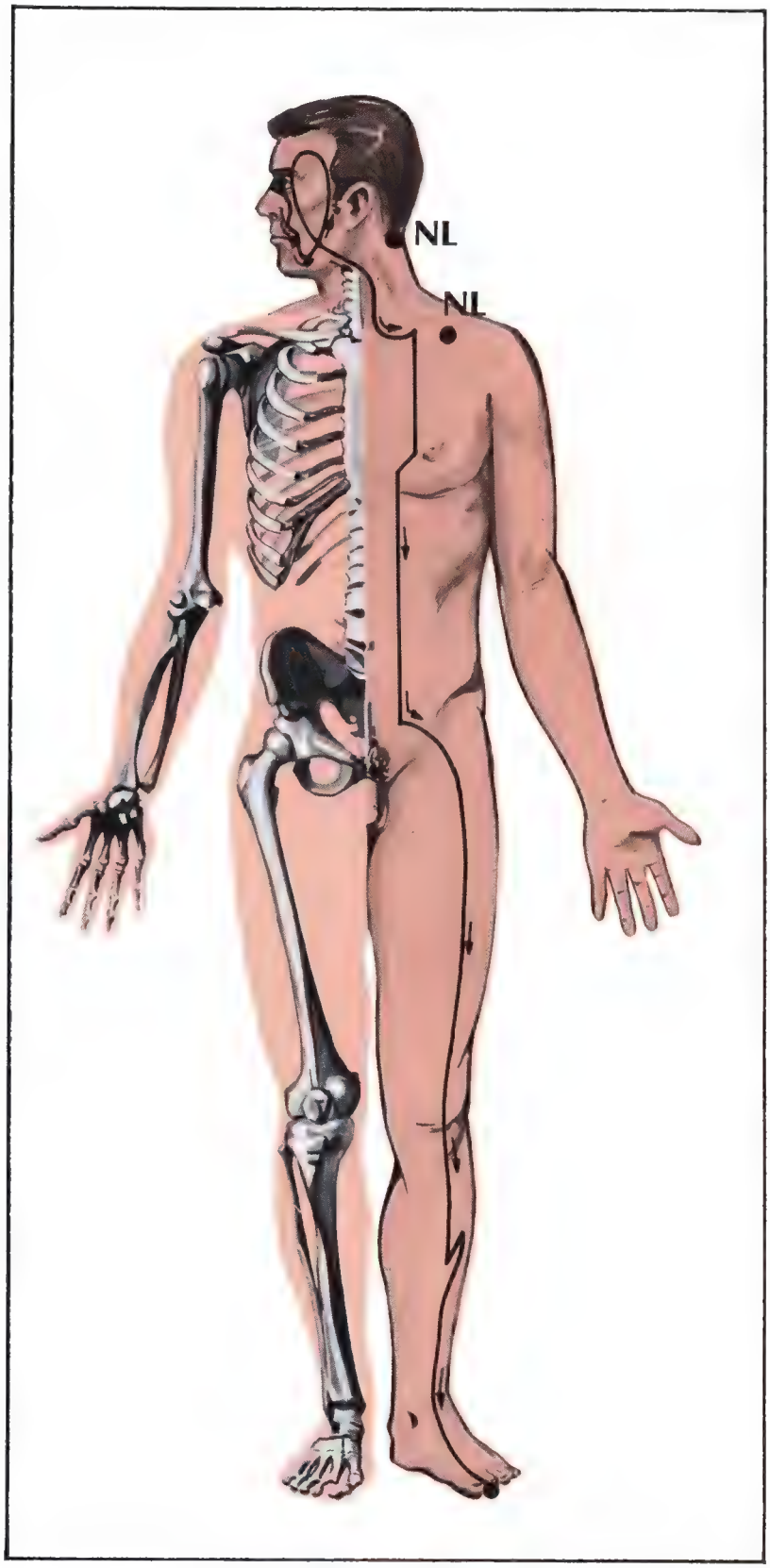

# QUADRATUS LUMBORUM - APPENDIX

| | |
|---|---|
| **STRUCTURAL WEAKNESS** | Low hip while standing, subluxated ilium, lower rib subluxation, back pain. |
| **INTERNAL MANIFESTATIONS** | Chest and abdominal pains, gastric upset, appendicitis (but not a substitute for necessary surgery). |
| **NEUROLYMPHATICS** | **ANTERIOR:** IN RESEARCH.<br>**POSTERIOR:** Interspinous-transverse space of T-11 (right side only) and the upper edge of the 12th rib (right side only). |
| **MERIDIAN** | Large intestine. Also check kidney meridian. |
| **NUTRITION** | Vitamin E, Vitamin C, Vitamin A and natural gastric concentrates. |
| **ASSOCIATED MUSCLES** | Sacrospinalis, iliopsoas, abdominals, popliteus. |
| **LAB TESTS** | CBC, cardiac enzymes, diagnex blue, serum amylase. |
| **EXERCISE** | Lateral bending. |
| **ACTION** | Lateral flexion of lumbar column, pelvic stabilizer, depresses the last rib. |
| **ORIGIN** | Iliolumbar ligament and the iliac crest. |
| **INSERTION** | Inferior border of last rib, transverse process of upper 4 lumbars. |
| **NERVE SUPPLY** | T-12, L-1, 2 & 3. |
| **PALPATE** | Very difficult to palpate, except on extremely thin individuals and then one would palpate on the lateral aspect of erector spinae in lumbar region. |

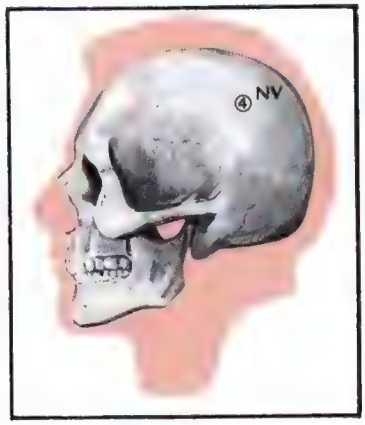


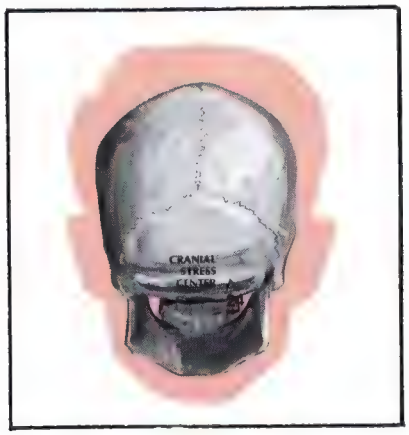

# QUADRATUS LUMBORUM - APPENDIX

**TO STRENGTHEN:**

**TO WEAKEN:**

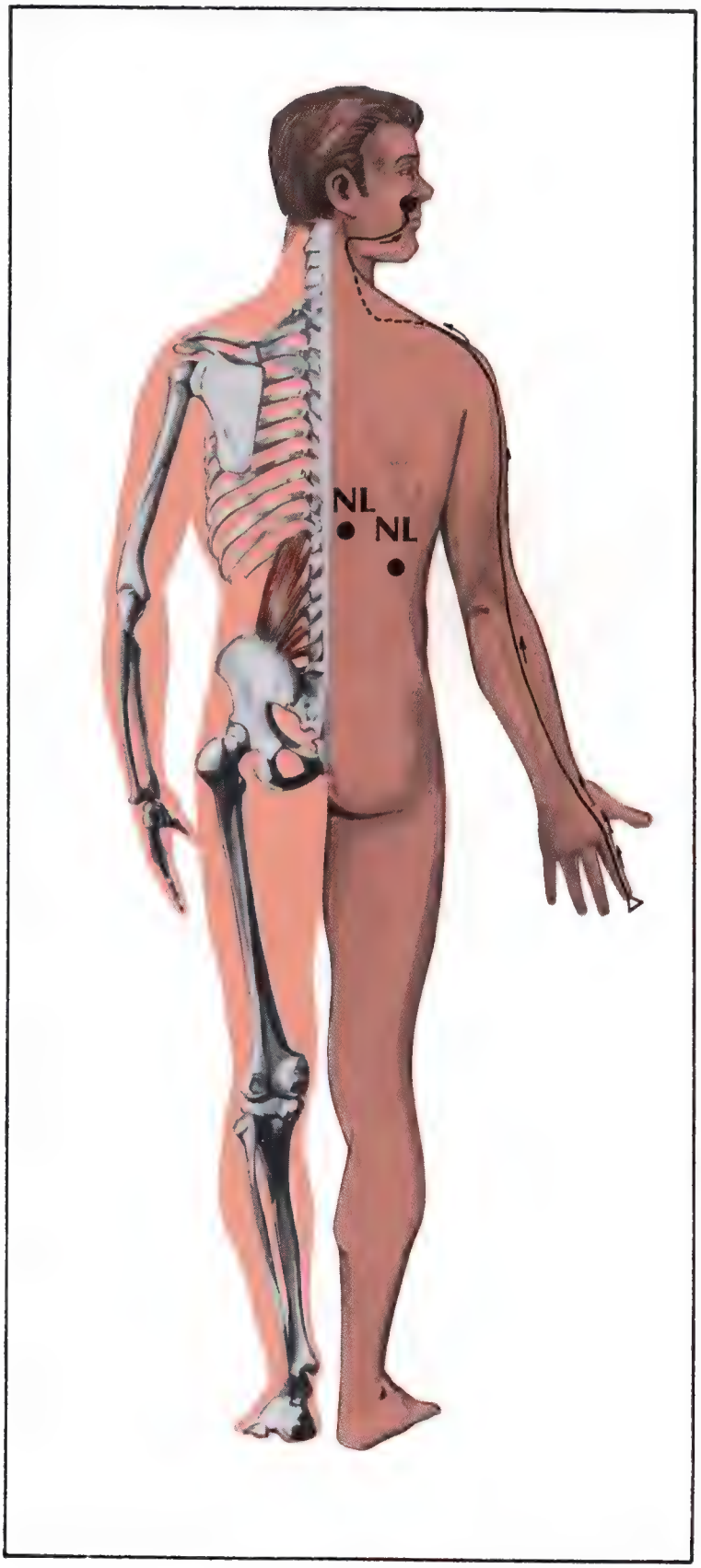

# QUADRICEPS - SMALL INTESTINE

## VASTUS INTERMEDIUS

| | |
|---|---|
| STRUCTURAL WEAKNESS | Low back conditions, difficulty in climbing stairs or in getting up from a seated position, difficulty in raising the knee, pain in the knee cap and other related knee problems. |
| INTERNAL MANIFESTATIONS | Associated with problems of the jejunum and the ileum (which is the last two-thirds of the small intestine) in the form of indigestion and other digestive difficulties. |
| NEUROLYMPHATICS | **ANTERIOR:** Between the 8th, 9th, 10th & 11th ribs, near the cartilages.<br>**POSTERIOR:** Between T-8, 9, 10 & 11, 1" lateral to the spine. |
| MERIDIAN | Small Intestine. |
| NUTRITION | B complex, natural concentrates from the small intestine. |
| ASSOCIATED MUSCLES | Sacrospinalis, abdominals, hamstrings, popliteus. |
| LAB TESTS | CBC, urinalysis, diagnex blue, serum amylase, BUN. |
| EXERCISE | Running, jumping, hopping, skipping, walking. |
| ACTION | Extends the leg. |
| ORIGIN | Upper two-thirds of the anterior lateral surface of the femur, lower part of the lateral intermuscular septum. |
| INSERTION | Proximal border of patella, through patella ligament to tuberosity of tibia. |
| NERVE SUPPLY | Femoral nerve, L-2, 3 & 4. |
| PALPATE | Cannot be palpated. |

CSC IN RESEARCH

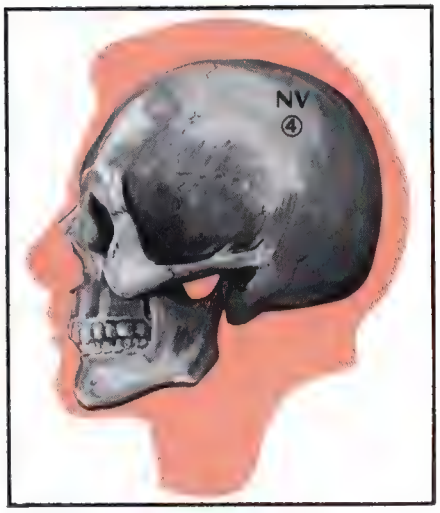

# QUADRICEPS - SMALL INTESTINE
## VASTUS INTERMEDIUS

**TO STRENGTHEN:**

**TO WEAKEN:**

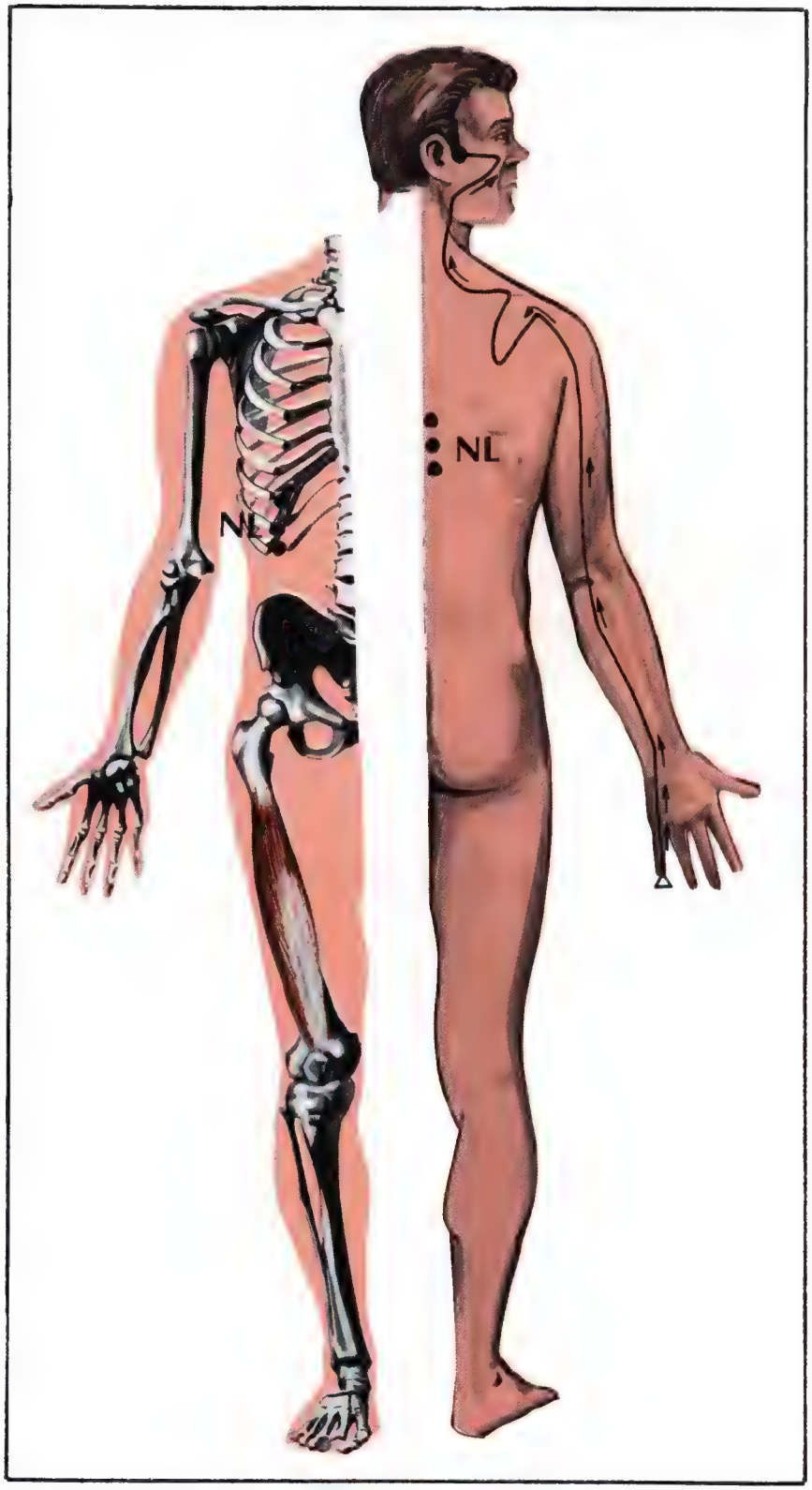

# QUADRICEPS - SMALL INTESTINE

## VASTUS LATERALIS

| | |
|---|---|
| STRUCTURAL WEAKNESS | Low back conditions, difficulty in climbing stairs or in getting up from a seated position, difficulty in raising the knee, pain in the knee cap and other related knee problems. |
| INTERNAL MANIFESTATIONS | Associated with problems of the jejunum and the ileum (which is the last two-thirds of the small intestine) in the form of indigestion and other digestive difficulties. |
| NEUROLYMPHATICS | **ANTERIOR:** Between the 8th, 9th, 10th & 11th ribs, near the cartilages.<br>**POSTERIOR:** Between T-8, 9, 10 & 11, 1" lateral to the spine. |
| MERIDIAN | Small Intestine. |
| NUTRITION | B complex, natural concentrates from the small intestine. |
| ASSOCIATED MUSCLES | Sacrospinalis, abdominals, hamstrings, popliteus. |
| LAB TESTS | CBC, urinalysis, diagnex blue, serum amylase, BUN. |
| EXERCISE | Running, jumping, hopping, skipping, walking. |
| ACTION | Extends the leg. |
| ORIGIN | Capsule of hip joint, anterior and inferior border of greater trochanter, lateral linea aspera. |
| INSERTION | Proximal border of patella, through patella ligament to tuberosity of tibia. |
| NERVE SUPPLY | Femoral nerve, L-2, 3 & 4. |
| PALPATE | Palpate the lateral and medial side of the thigh. |

CSC IN RESEARCH

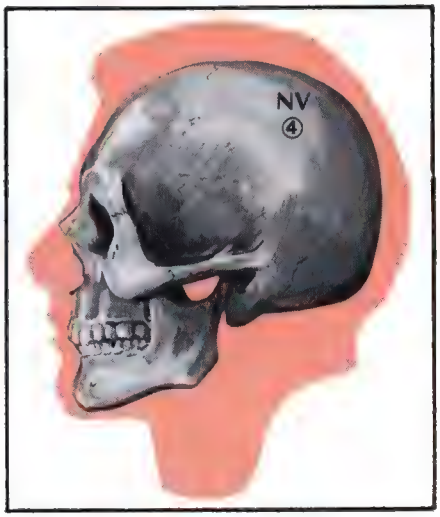

# QUADRICEPS - SMALL INTESTINE
## VASTUS LATERALIS

**TO STRENGTHEN:**

**TO WEAKEN:**

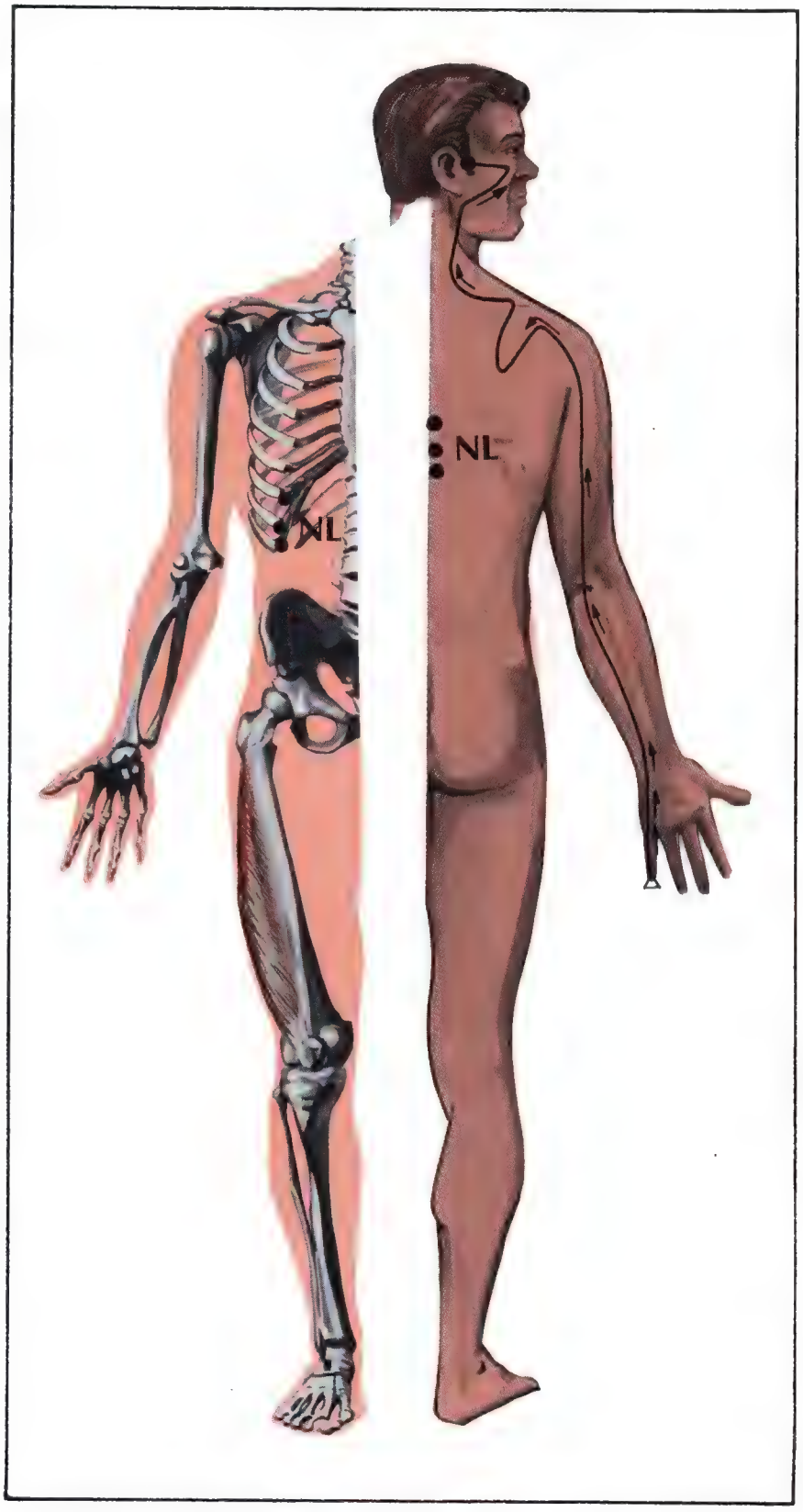

# QUADRICEPS - SMALL INTESTINE

## VASTUS MEDIALIS

| | |
|---|---|
| STRUCTURAL WEAKNESS | Low back conditions, difficulty in climbing stairs or in getting up from a seated position, difficulty in raising the knee, pain in the knee cap and other related knee problems. |
| INTERNAL MANIFESTATIONS | Associated with problems of the jejunum and the ileum (which is the last two-thirds of the small intestine) in the form of indigestion and other digestive difficulties. |
| NEUROLYMPHATICS | **ANTERIOR:** Between the 8th, 9th, 10th and 11th ribs, near the cartilages.<br>**POSTERIOR:** Between T-8, 9, 10 and 11, 1" lateral to the spine. |
| MERIDIAN | Small Intestine. |
| NUTRITION | B complex, natural concentrates from the small intestine. |
| ASSOCIATED MUSCLES | Sacrospinalis, abdominals, hamstrings, popliteus. |
| LAB TESTS | CBC, urinalysis, diagnex blue, serum amylase, BUN. |
| EXERCISE | Running, jumping, hopping, skipping, walking. |
| ACTION | Extends the leg. |
| ORIGIN | Lower half of the intertrochanteric line, linea aspera and medial intermuscular septum, tendon of adductor magnus. |
| INSERTION | Proximal border of patella, through patella ligament to tuberosity of tibia. |
| NERVE SUPPLY | Femoral nerve, L-2, 3 & 4. |
| PALPATE | Medial anterior side of the thigh near the knee joint. |

CSC IN RESEARCH

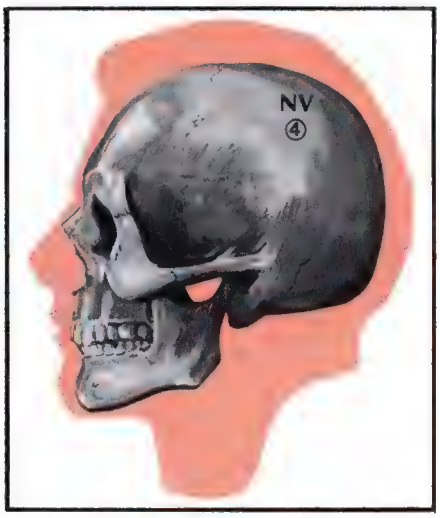

# QUADRICEPS - SMALL INTESTINE
## VASTUS MEDIALIS

**TO STRENGTHEN:**

**TO WEAKEN:**

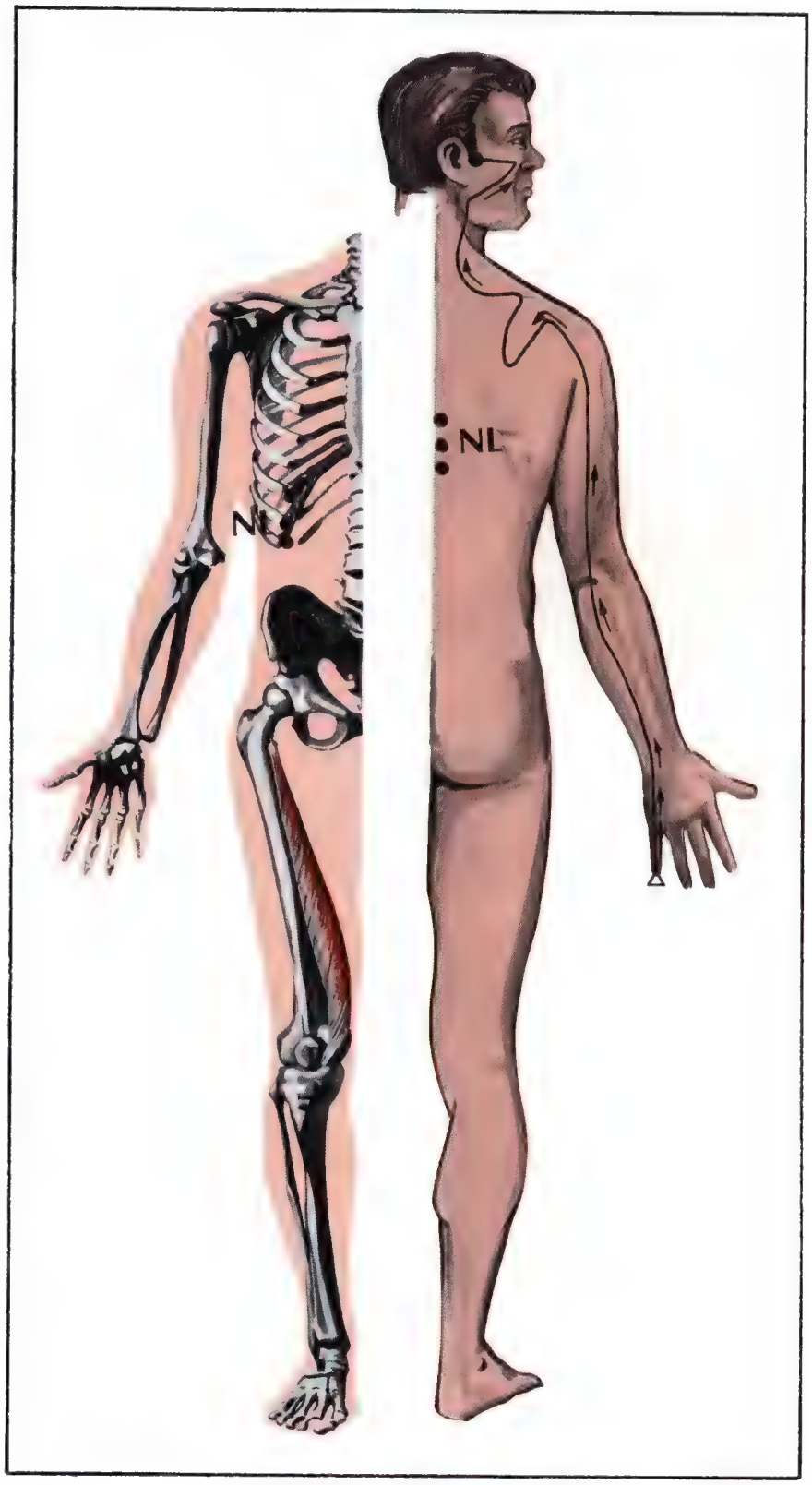

# QUADRICEPS - SMALL INTESTINE

## RECTUS FEMORIS

| | |
|---|---|
| STRUCTURAL WEAKNESS | Low back conditions, difficulty in climbing stairs or in getting up from a seated position, difficulty in raising the knee, pain in the knee cap and other related knee problems. |
| INTERNAL MANIFESTATIONS | Associated with problems of the jejunum and the ileum (which is the last two-thirds of the small intestine) in the form of indigestion and other digestive difficulties. |
| NEUROLYMPHATICS | **ANTERIOR:** Between the 8th, 9th, 10th & 11th ribs, near the cartilages.<br>**POSTERIOR:** Between T-8, 9, 10 & 11, 1" lateral to the spine. |
| MERIDIAN | Small Intestine. |
| NUTRITION | B Complex, natural concentrates from the small intestine. |
| ASSOCIATED MUSCLES | Sacrospinalis, abdominals, hamstrings and popliteus. |
| LAB TESTS | CBC, urinalysis, diagnex blue, serum amylase, BUN. |
| EXERCISE | Running, jumping, hopping, skipping and walking. |
| ACTION | Extends the knee joints and flexes the hip. |
| ORIGIN | Anterior inferior iliac spine, and the reflected head from the groove above the brim of the acetabulum. |
| INSERTION | Proximal border of patella, through patella ligament to tuberosity of tibia. |
| NERVE SUPPLY | Femoral nerve, L-2, 3 & 4. |
| PALPATE | The anterior surface of the femur. |

CSC IN RESEARCH

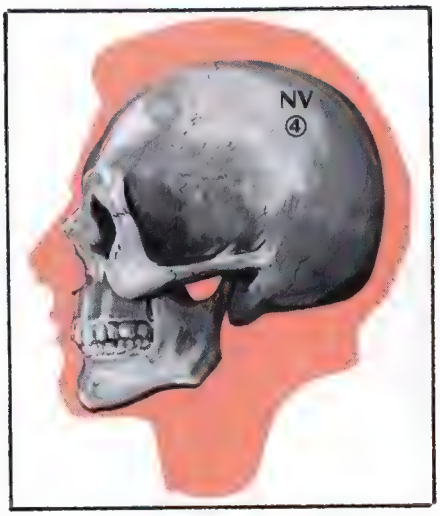

# QUADRICEPS - SMALL INTESTINE
## RECTUS FEMORIS

**TO STRENGTHEN:**

**TO WEAKEN:**

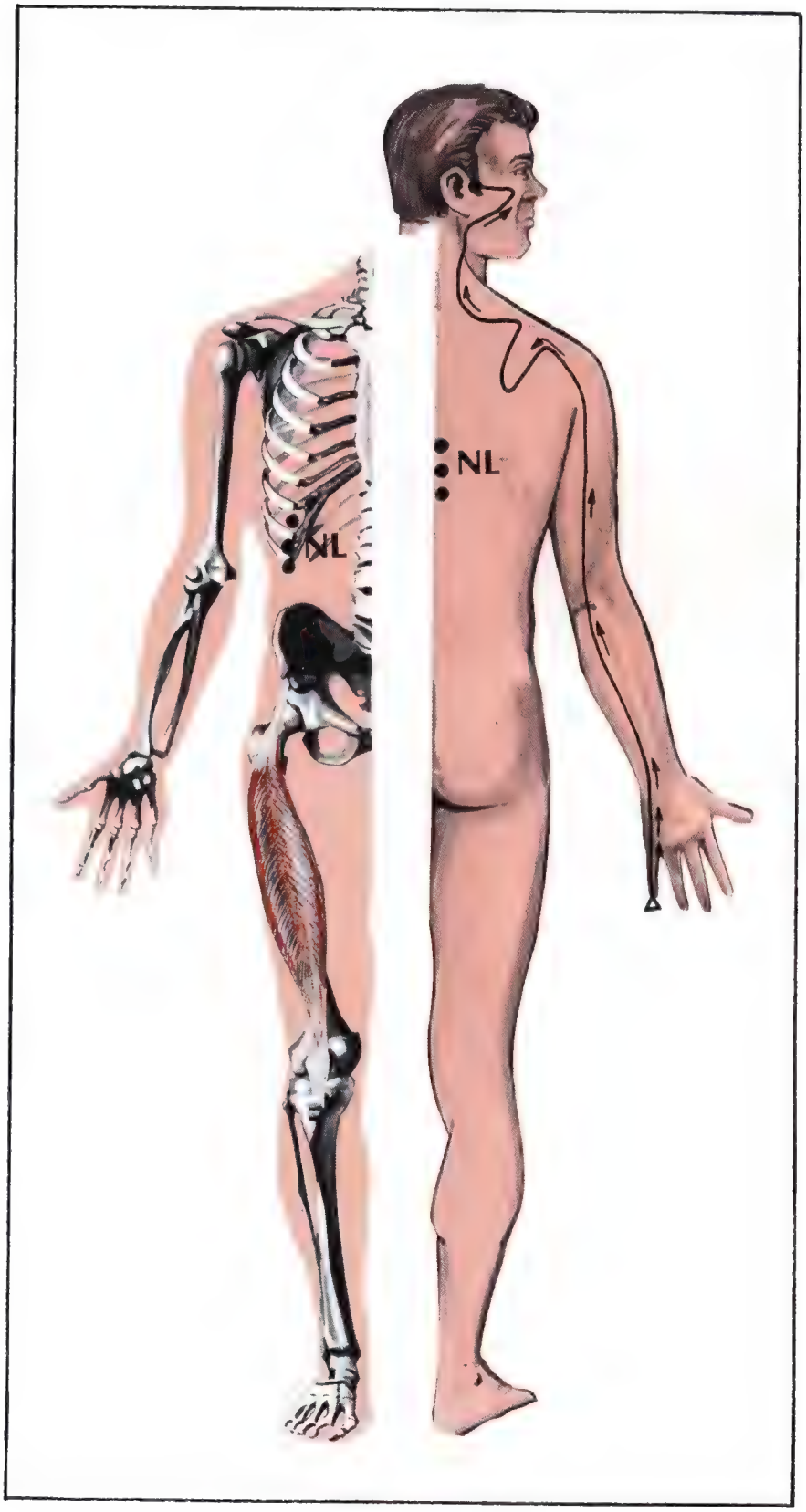

# RHOMBOIDS - LIVER

## MAJOR

| | |
|---|---|
| STRUCTURAL WEAKNESS | May be involved with shoulder problems. |
| INTERNAL MANIFESTATIONS | Liver and gastric disturbances. |
| NEUROLYMPHATICS | **ANTERIOR:** On the left between the 5th & 6th ribs, from the nipple to the breast bone.<br>**POSTERIOR:** Between T-6 & T-7 on the left, interspinous-transverse space. |
| MERIDIAN | Stomach (not Liver as one might assume). |
| NUTRITION | Vitamin A. |
| ASSOCIATED MUSCLES | Levator scapulae, anterior serratus, trapezius, anterior deltoid, latissiums dorsi, pectoralis major sternal. |
| LAB TESTS | Thymol turbidity, NPN, BUN. |
| EXERCISE | Swimming, any exercise in which the arms are drawn down to the side from the horizontal position. |
| ACTION | Adducts and rotates scapula medially, assists in elevation. |
| ORIGIN | Spinous processes of T-2 through T-5. |
| INSERTION | By fibrous attachment to medial border of scapula between the spine and inferior angle (vertebral margin of scapula). |
| NERVE SUPPLY | Dorsal scapular, C-4 & 5. |
| PALPATE | Located under the trapezius and cannot be palpated. |

NV IN RESEARCH

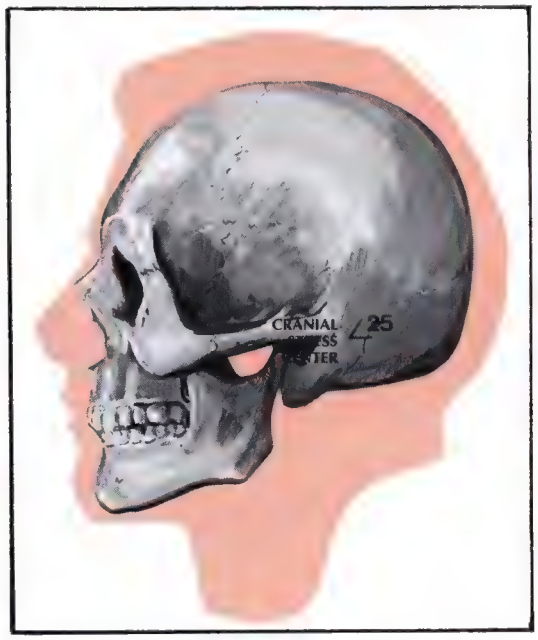

# RHOMBOIDS - LIVER
## MAJOR

TO STRENGTHEN:

TO WEAKEN:

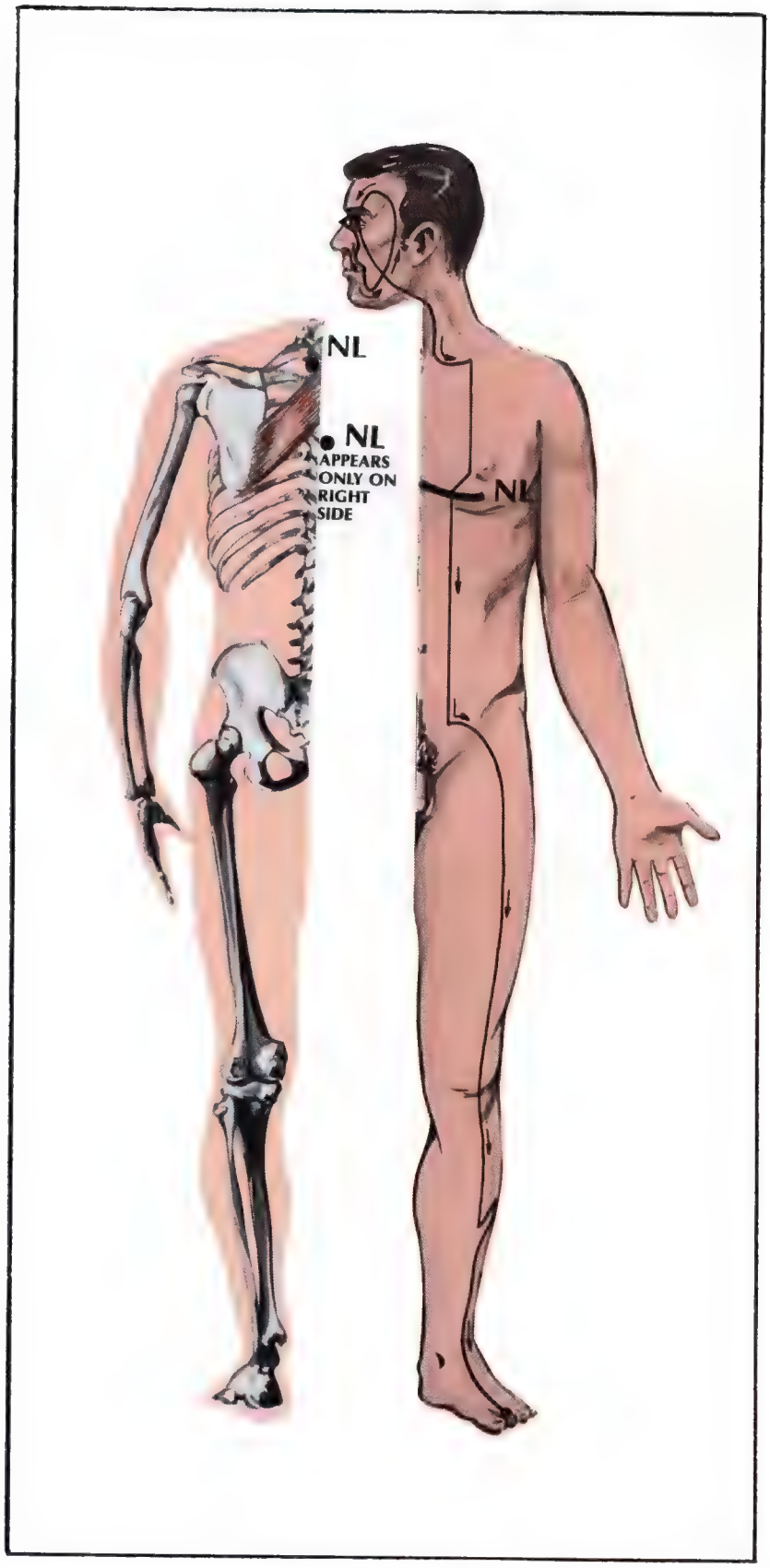

# RHOMBOIDS - LIVER

## MINOR

| | |
|---|---|
| **STRUCTURAL WEAKNESS** | May be involved with shoulder problems. |
| **INTERNAL MANIFESTATIONS** | Liver and gastric disturbances. |
| **NEUROLYMPHATICS** | **ANTERIOR:** On the left between the 5th & 6th ribs, from the nipple to the breast bone.<br>**POSTERIOR:** Between T-6 & T-7 on the left, interspinous-transverse space. |
| **MERIDIAN** | Stomach. |
| **NUTRITION** | Vitamin A. |
| **ASSOCIATED MUSCLES** | Levator scapulae, anterior serratus, trapezius, anterior deltoid, latissimus dorsi, pectoralis major sternal. |
| **LAB TESTS** | Thymol turbidity, NPN, BUN. |
| **EXERCISE** | Swimming, any exercise in which the arms are drawn down to the side from the horizontal position. |
| **ACTION** | Adducts and rotates scapula medially, assists in elevation. |
| **ORIGIN** | Ligamentum nuchae, spinous of the 7th cervical and the first dorsal vertebrae. |
| **INSERTION** | To the root of the spine of scapula. |
| **NERVE SUPPLY** | Dorsal scapular, C-4 & 5. |
| **PALPATE** | Located under the trapezius and cannot be palpated. |

NV IN RESEARCH

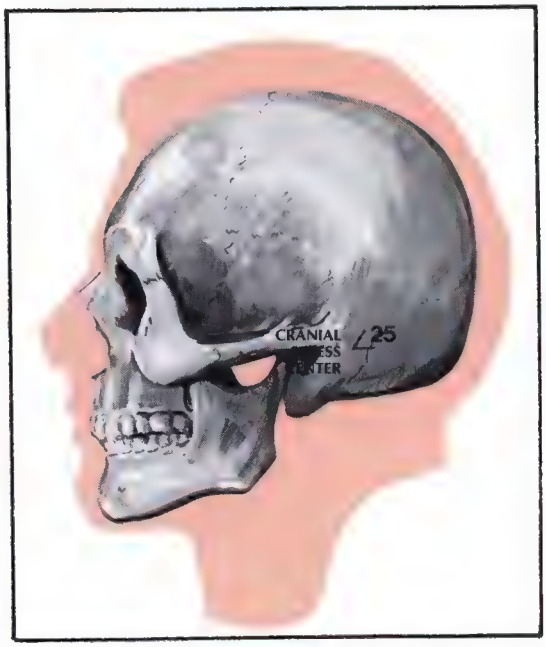

# RHOMBOIDS - LIVER
## MINOR

TO STRENGTHEN:

TO WEAKEN:

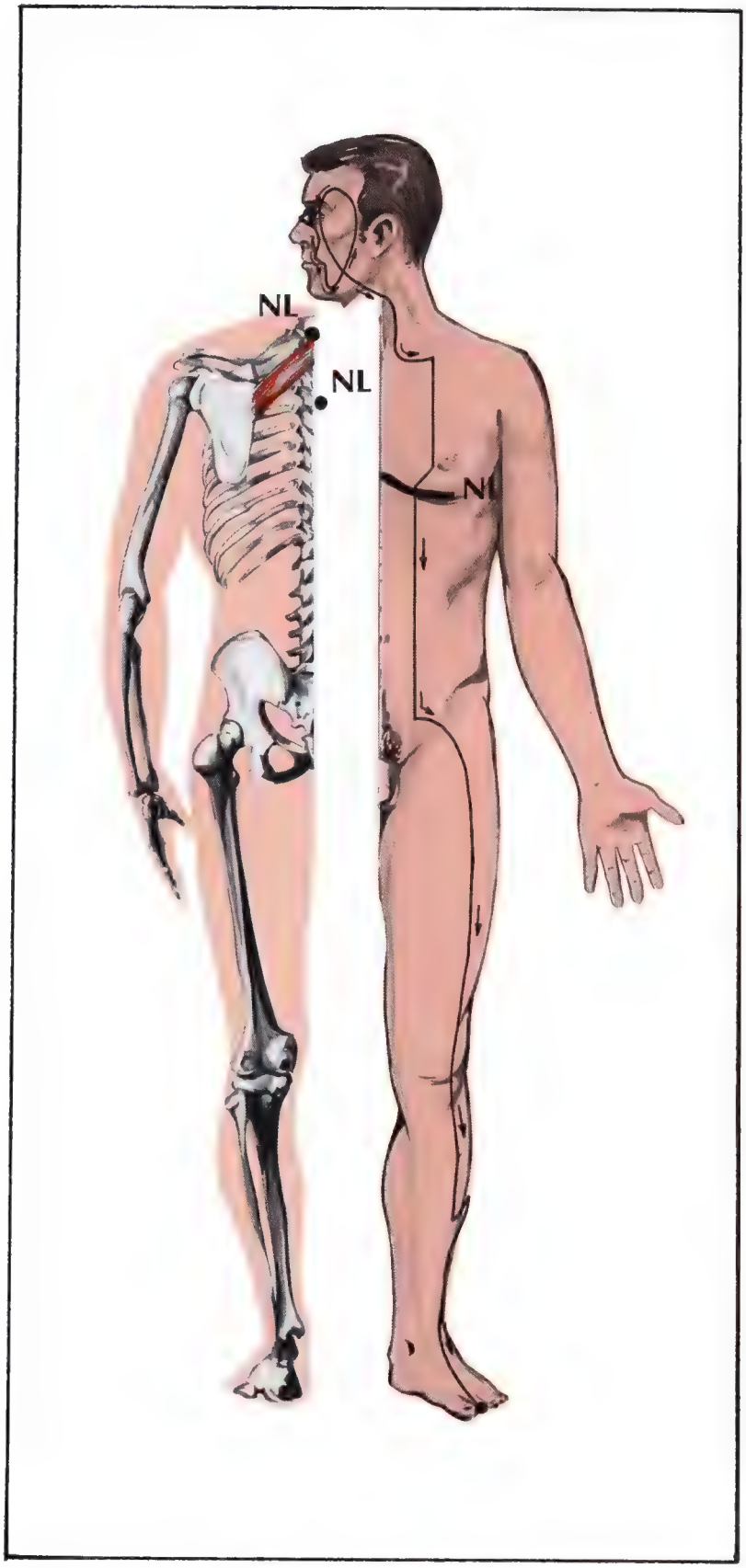

# SACROSPINALIS

## SACROSPINALIS — ERECTOR SPINAE
### ILIOCOSTALIS LUMBORUM - ILIOCOSTALIS THORACIS - ILIOCOSTALIS CERVICIS

| | |
|---|---|
| **STRUCTURAL WEAKNESS** | Arthritis, rheumatism, bursitis, shoulder and elbow pain or restricted motion, bilateral weakness of extensors in low back lordosis, unilateral contracture resulting in scoliosis. |
| **INTERNAL MANIFESTATIONS** | Bladder disturbances, emotional strain. |
| **NEUROLYMPHATICS** | **ANTERIOR:** Lateral to umbilicus, center of pubic bone.<br>**POSTERIOR:** End of transverse processes of L-2. |
| **MERIDIAN** | Bladder. |
| **NUTRITION** | Vitamin A, C, E and calcium. |
| **ASSOCIATED MUSCLES** | Abdominals, quadriceps, hamstrings, anterior tibials, peroneus, gluteus maximus. |
| **LAB TESTS** | C-Reactive protein, uric acid, latex fixation, ESR, complete urine analysis. |
| **EXERCISE** | Lateral bending, prone hyperextensions. |
| **ACTION** | **ILIOCOSTALIS LUMBORUM:** Extends the vertebral column to the side and draws the rib downward.<br>**ILIOCOSTALIS THORACIS:** (Same as above.)<br>**ILIOCOSTALIS CERVICIS:** Extends the vertebral column to the side. |
| **ORIGIN** | **ILIOCOSTALIS LUMBORUM:** Common origin from anterior surface of broad tendon attached to medial crest of sacrum, spinous processes of lumbar and 11th and 12th thoracic vertebrae, posterior part of medial lip of iliac crest, supraspinous ligament, and lateral crests of sacrum.<br>**ILIOCOSTALIS THORACIS:** By tendons from upper borders of angles of lower 6 ribs.<br>**ILIOCOSTALIS CERVICIS:** Angles of 3rd, 4th, 5th, and 6th ribs. |
| **INSERTION** | **ILIOCOSTALIS LUMBORUM:** By tendons into inferior borders of angles of lower 6 or 7 ribs.<br>**ILIOCOSTALIS THORACIS:** Cranial borders of angles of upper 6 ribs, and dorsum of transverse process of 7th cervical vertebra.<br>**ILIOCOSTALIS CERVICIS:** Posterior tubercles of transverse processes of 4th, 5th, and 6th cervical vertebrae. |
| **NERVE SUPPLY** | Branches of the dorsal primary divisions of the spinal nerves. |
| **PALPATE** | On the lower lumbar region on either side of the spine. |

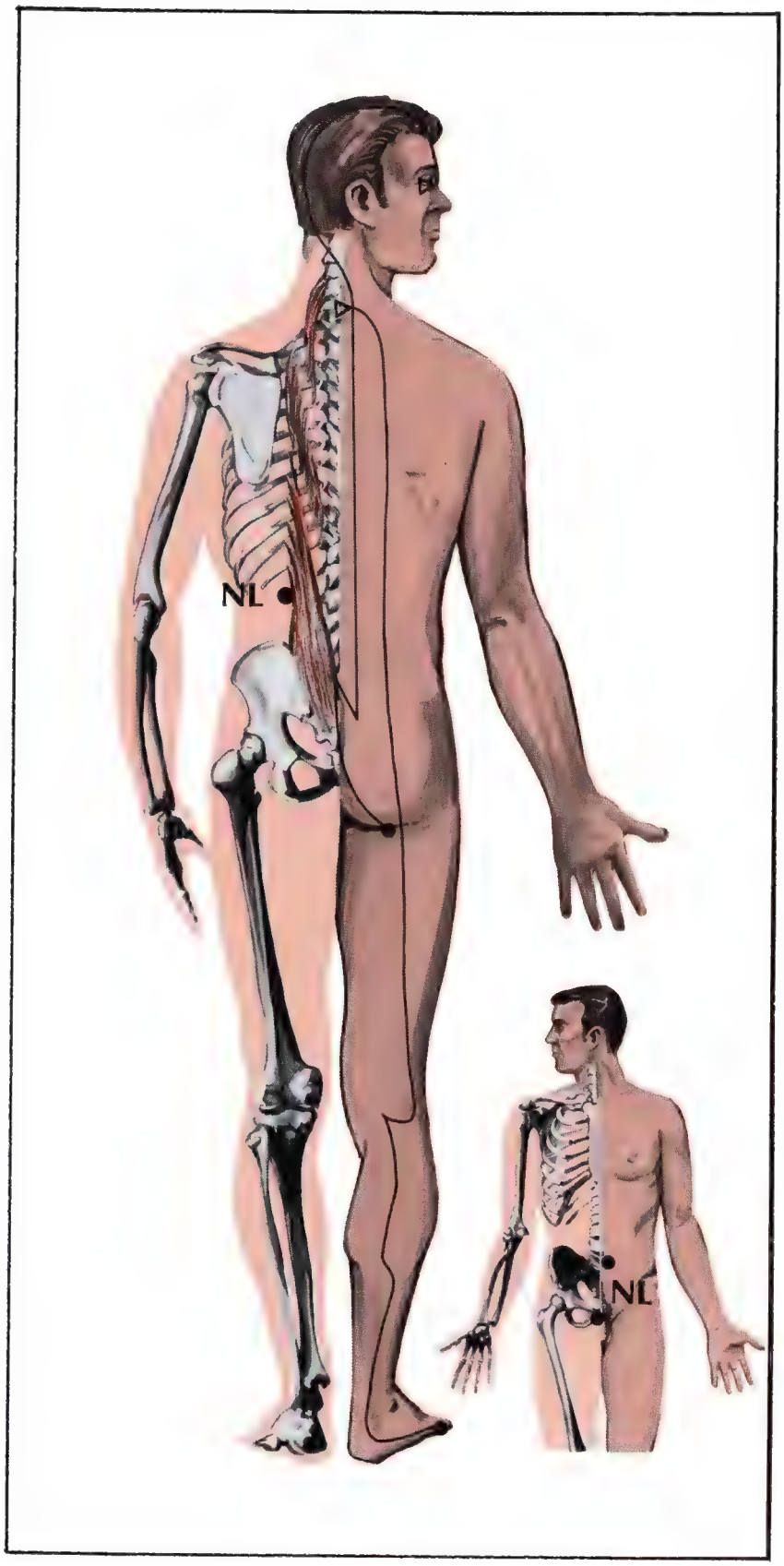
NL
NL

# SACROSPINALIS

## SACROSPINALIS — ERECTOR SPINAE
### LONGISSIMUS THORACIS - LONGISSIMUS CERVICIS - LONGISSIMUS CAPITIS

| | |
|---|---|
| **STRUCTURAL WEAKNESS** | Arthritis, rheumatism, bursitis, shoulder and elbow pain or restricted motion, bilateral weakness of extensors in low back lordosis, unilateral contracture resulting in scoliosis. |
| **INTERNAL MANIFESTATIONS** | Bladder disturbances, emotional strain. |
| **NEUROLYMPHATICS** | **ANTERIOR:** Lateral to umbilicus, center of pubic bone.<br>**POSTERIOR:** End of transverse processes of L-2. |
| **MERIDIAN** | Bladder. |
| **NUTRITION** | Vitamin A, C, E and calcium. |
| **ASSOCIATED MUSCLES** | Abdominals, quadriceps, hamstrings, anterior tibials, peroneus, gluteus maximus. |
| **LAB TESTS** | C-reactive protein, uric acid, latex fixation, ESR, complete urine analysis. |
| **EXERCISE** | Lateral bending, prone hyperextensions. |
| **ACTION** | **LONGISSIMUS THORACIS:** Extends the vertebral column and bends it to one side.<br>**LONGISSIMUS CERVICIS:** Draws the ribs downward.<br>**LONGISSIMUS CAPITIS:** Extends the head, the muscle of one side acting alone bends the head to the same side and rotates the face toward that side. |
| **ORIGIN** | **LONGISSIMUS THORACIS:** In lumbar region it is blended with Iliocostalis lumborum, posterior surfaces of transverse and accessory processes of lumbar vertebrae, and anterior layer of thoracolumbar fascia.<br>**LONGISSIMUS CERVICIS:** By tendons from transverse processes of upper 4 or 5 thoracic vertebrae.<br>**LONGISSIMUS CAPITIS:** By tendons from transverse processes of upper 4 or 5 thoracic vertebrae, and articular processes of lower 3 or 4 cervical vertebrae. |
| **INSERTION** | **LONGISSIMUS THORACIS:** By tendons into tips of transverse processes of all thoracic vertebrae, and by fleshy digitations into lower 9 or 10 ribs between tubercles and angles.<br>**LONGISSIMUS CERVICIS:** By tendons into posterior tubercles of transverse processes of 2nd through 6th cervical vertebrae.<br>**LONGISSIMUS CAPITIS:** Posterior margin of mastoid process. |
| **NERVE SUPPLY** | **LONGISSIMUS THORACIS:** Branches of the dorsal primary divisions of the spinal nerves.<br>**LONGISSIMUS CERVICIS:** Branches of the dorsal primary divisions of the spinal nerves.<br>**LONGISSIMUS CAPITIS:** Branches of the dorsal primary divisions of the middle and lower cervical nerves. |
| **PALPATE** | Not palpable. |

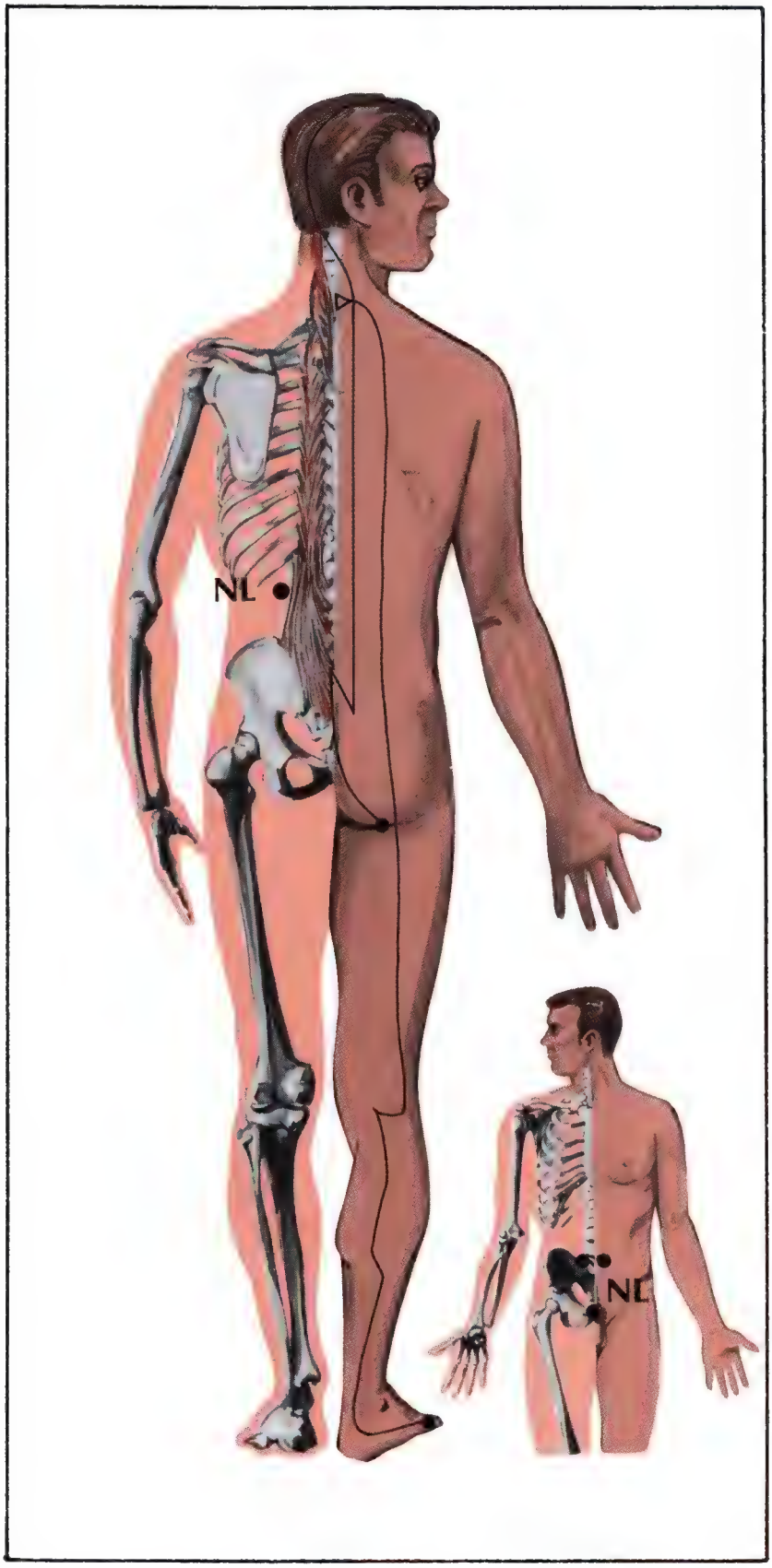
NL
NL

# SACROSPINALIS

## SACROSPINALIS — ERECTOR SPINAE
### SPINALIS THORACIS - SPINALIS CERVICIS - SPINALIS CAPITIS

| | |
|---|---|
| **STRUCTURAL WEAKNESS** | Arthritis, rheumatism, bursitis, shoulder and elbow pain or restricted motion, bilateral weakness of extensors in low back lordosis, unilateral contracture resulting in scoliosis. |
| **INTERNAL MANIFESTATIONS** | Bladder disturbances, emotional strain. |
| **NEUROLYMPHATICS** | **ANTERIOR:** Lateral to umbilicus, center of pubic bone.<br>**POSTERIOR:** End of transverse processes of L-2. |
| **MERIDIAN** | Bladder. |
| **NUTRITION** | Vitamin A, C, E and calcium. |
| **ASSOCIATED MUSCLES** | Abdominals, quadriceps, hamstrings, anterior tibials, peroneus, gluteus maximus. |
| **LAB TESTS** | C-Reactive protein, uric acid, latex fixation, ESR, complete urine analysis. |
| **EXERCISE** | Lateral bending, prone hyperextensions. |
| **ACTION** | **SPINALIS THORACIS:** Extends the vertebral column.<br>**SPINALIS CERVICIS:** Extends the vertebral column.<br>**SPINALIS CAPITIS:** Extends the vertebral column. |
| **ORIGIN** | **SPINALIS THORACIS:** By tendons from spinous processes of first 2 lumbar and last 2 thoracic vertebrae.<br>**SPINALIS CERVICIS:** Ligamentum nuchae, lower part; spinous process of 7th cervical.<br>**SPINALIS CAPITIS:** Inseparably connected with Semispinalis Capitis. |
| **INSERTION** | **SPINALIS THORACIS:** Spinous processes of upper 4-8 (variable) thoracic vertebrae.<br>**SPINALIS CERVICIS:** Spinous process of axis and, occasionally, into spinous processes of C-3 and C-4.<br>**SPINALIS CAPITIS:** Spinous processes of upper thoracic 4-8 (variable), and lower 2 cervical vertebrae. |
| **NERVE SUPPLY** | **SPINALIS THORACIS:** Branches of the dorsal primary divisions of the cervical nerves.<br>**SPINALIS CERVICIS:** Branches of the dorsal primary divisions of the cervical nerves.<br>**SPINALIS CAPITIS:** Branches of the dorsal primary divisions of the cervical nerves. |
| **PALPATE** | Not palpable. |

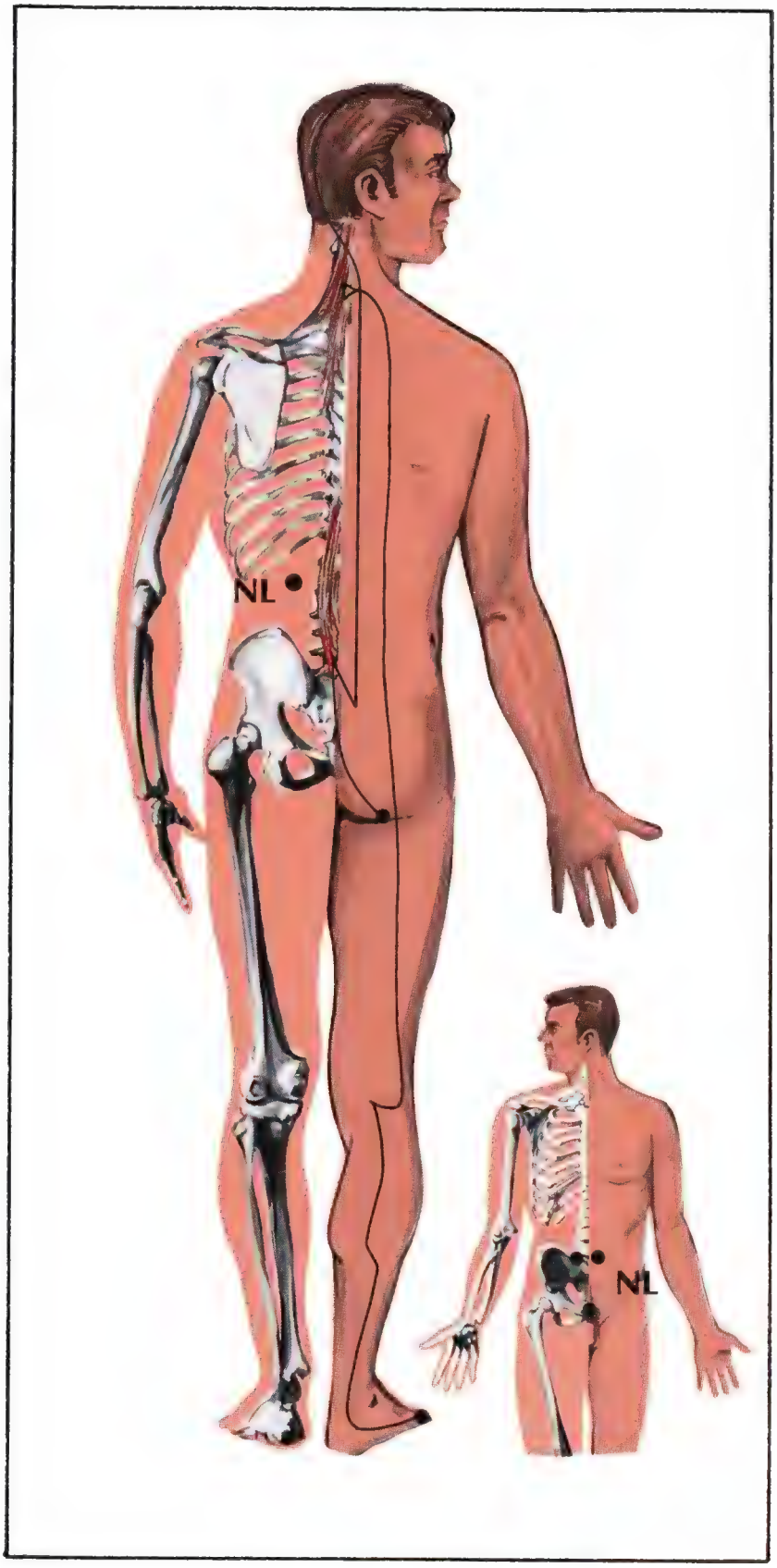
NL
NL

# SACROSPINALIS

## SACROSPINALIS — TRANSVERSOSPINALIS

### SEMISPINALIS THORACIS - SEMISPINALIS CERVICIS - SEMISPINALIS CAPITIS - MULTIFIDUS - ROTATORES

| | |
|---|---|
| **STRUCTURAL WEAKNESS** | Arthritis, rheumatism, bursitis, shoulder and elbow pain or restricted motion, bilateral weakness of extensors in low back lordosis, unilateral contracture resulting in scoliosis. |
| **INTERNAL MANIFESTATIONS** | Bladder disturbances, emotional strain. |
| **NEUROLYMPHATICS** | **ANTERIOR:** Lateral to umbilicus, center of pubic bone.<br>**POSTERIOR:** End of transverse processes of L-2. |
| **MERIDIAN** | Bladder. |
| **NUTRITION** | Vitamin A, C, E and calcium. |
| **ASSOCIATED MUSCLES** | Abdominals, quadriceps, hamstrings, anterior tibials, peroneus, gluteus maximus. |
| **LAB TESTS** | C-Reactive protein, uric acid, latex fixation ESR, complete urine analysis. |
| **EXERCISE** | Lateral bending, prone hyperextensions. |
| **ACTION** | **SEMISPINALIS THORACIS:** Extends the vertebral column and rotates it toward the opposite side.<br>**SEMISPINALIS CERVICIS:** Extends the vertebral column and rotates it toward the opposite side.<br>**SEMISPINALIS CAPITIS:** Extends the vertebral column and rotates it toward the opposite side.<br>**MULTIFIDUS:** Extends the vertebral column and rotates it toward the opposite side.<br>**ROTATORES:** Extends the vertebral column and rotates it toward the opposite side.<br>**INTERSPINALIS:** Extends the vertebral column.<br>**INTERTRANSVERSARII:** Bends the vertebral column laterally. |
| **ORIGIN** | **SEMISPINALIS THORACIS:** Transverse processes of lower thoracic vertebrae.<br>**SEMISPINALIS CERVICIS:** Transverse processes of upper 5 or 6 thoracic vertebrae.<br>**SEMISPINALIS CAPITIS:** Tips of transverse processes of upper 6 or 7 thoracic and 7th cervical vertebrae, and articular processes of cervical 4th, 5th, and 6th.<br>**MULTIFIDUS:** *Sacral region:* Posterior surface of sacrum, medial surface of posterior superior iliac spine, and posterior sacroiliac ligaments.<br>*Lumbar region:* / *Thoracic region:* / *Cervical region:* Transverse processes of L-5 through C-4.<br>**ROTATORES:** Transverse processes of vertebrae.<br>**INTERSPINALIS:** Placed in pairs between spinous processes of contiguous vertebrae.<br>*Cervical:* 6 pair.<br>*Thoracic:* 2 or 3 pair; between 1st and 2nd, (2nd and 3rd), and 11th and 12th.<br>*Lumbar:* 4 pair.<br>**INTERTRANSVERSARII:** Small muscles placed between transverse processes of contiguous vertebrae in cervical, thoracic, and lumbar regions. |

| | | |
|---|---|---|
| **INSERTION** | **SEMISPINALIS THORACIS:** | Spinous processes of upper thoracic 4-8 (variable), and lower 2 cervical vertebrae. |
| | **SEMISPINALIS CERVICIS:** | Cervical spinous processes, 2nd through 5th. |
| | **SEMISPINALIS CAPITIS:** | Between superior and inferior nuchal lines of occipital bone. |
| | **MULTIFIDUS:** | Spanning 2 to 4 vertebrae, inserted into spinous process of a vertebra above. |
| | **ROTATORES:** | Lamina of the vertebra above. |
| | **INTERSPINALIS:** | Placed in pairs between spinous processes of contiguous vertebrae.<br>*Cervical:* 6 pair.<br>*Thoracic:* 2 or 3 pair; between 1st and 2nd, (2nd and 3rd), and 11th and 12th.<br>*Lumbar:* 4 pair. |
| | **INTERTRANSVERSARII:** | Small muscles placed between transverse processes of contiguous vertebrae in cervical, thoracic, and lumbar regions. |
| **NERVE SUPPLY** | **SEMISPINALIS THORACIS:** | Branches of the dorsal primary divisions of the spinal nerves. |
| | **SEMISPINALIS CERVICIS:** | Branches of the dorsal primary divisions of the spinal nerves. |
| | **SEMISPINALIS CAPITIS:** | Branches of the dorsal primary divisions of the spinal nerves. |
| | **MULTIFIDUS:** | Branches of the dorsal primary divisions of the spinal nerves. |
| | **ROTATORES:** | Branches of the dorsal primary divisions of the spinal nerves. |
| | **INTERSPINALIS:** | Branches of the dorsal primary divisions of the spinal nerves. |
| | **INTERTRANSVERSARII:** | Anteriores, posteriores, and laterales by branches of the ventral primary divisions of the nerves; the mediales by branches of the dorsal primary divisions. |
| **PALPATE** | Cannot be palpated. | |

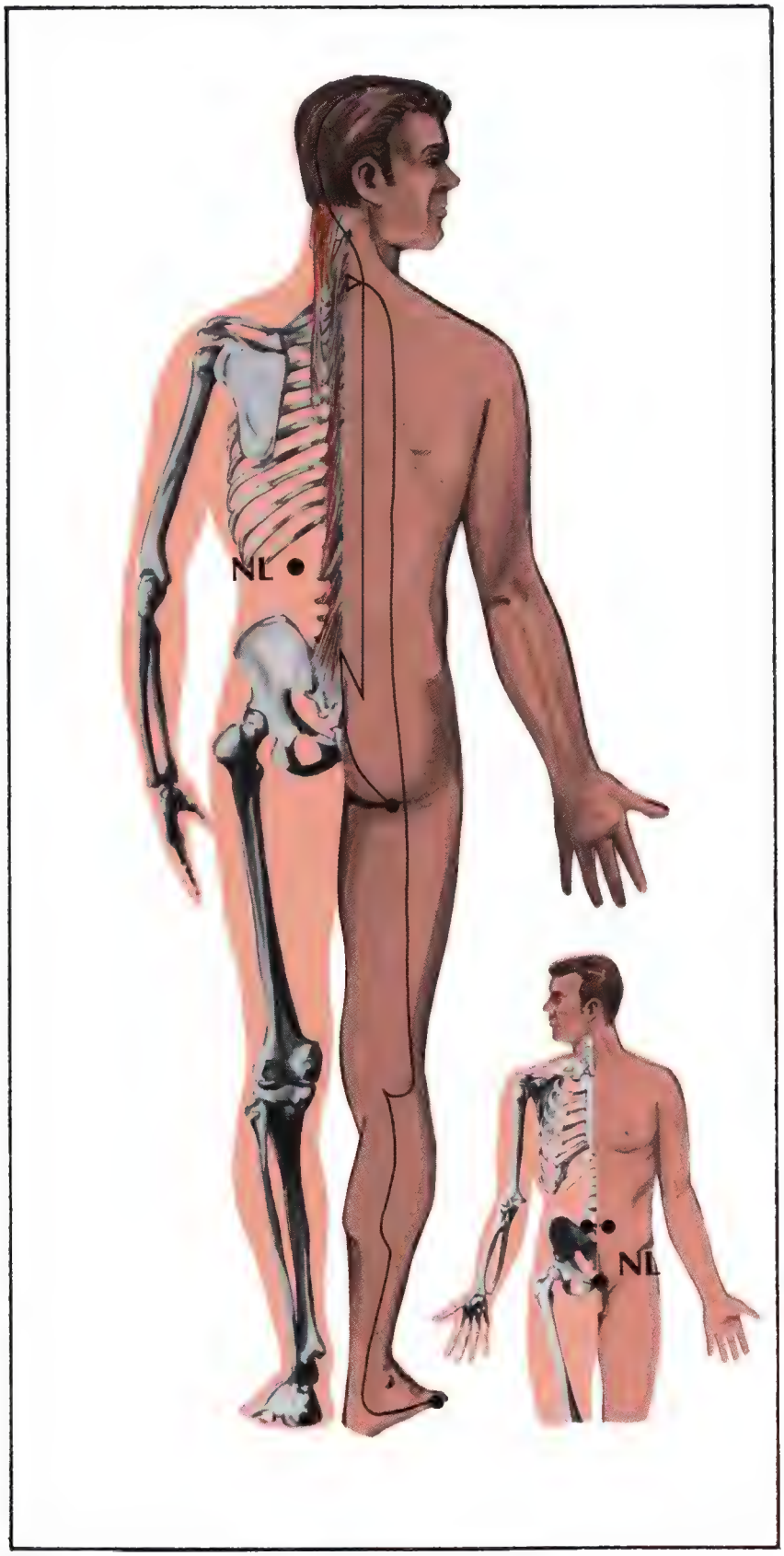
NL
NL

# SACROSPINALIS

**TO STRENGTHEN:**

**TO WEAKEN:**

CSC IN RESEARCH
NV IN RESEARCH

Muscle is tested by having the patient bend laterally to each side and noting restriction of motion.

# SARTORIUS - ADRENALS

| | |
|---|---|
| STRUCTURAL WEAKNESS | Knee pain, knocked knees, pelvic rotation, posterior ilium and jammed occiput. In absence of posterior ilium or anatomical deficiency, short leg in supine position becomes long in prone position. |
| INTERNAL MANIFESTATIONS | Morning fatigue, hypoglycemia, hyperinsulinism, allergies, hives, asthma, infections, check for swelling of hands and/or feet, as there may be possible water imbalance. |
| NEUROLYMPHATICS | **ANTERIOR:** 2" above and 1" on either side of the umbilicus.<br>**POSTERIOR:** Between T-10 & T-12, interspinous-transverse space. |
| MERIDIAN | Circulation Sex. |
| NUTRITION | Natural adrenal concentrates, Vitamin C, betaine hydrochloride. |
| ASSOCIATED MUSCLES | Adductors, neck flexors, soleus, gracilis, latissimus dorsi, pectoralis major clavicular, gastrocnemius, psoas, peroneus, sacrospinalis, anterior tibials. |
| LAB TESTS | CBC, HGB, hematocrit, 5-hour glucose tolerance test, T-3, T-4, sputum eosinophil culture, serum potassium. |
| EXERCISE | Sit-ups with legs extended, walking, jogging. |
| ACTION | Flexes leg on thigh, flexes thigh on pelvis and rotates thigh laterally. |
| ORIGIN | Anterior superior iliac spine, upper half of iliac notch. |
| INSERTION | Medial surface of tibia, distal to the condyle. |
| NERVE SUPPLY | Femoral, L-2, 3 & 4. |
| PALPATE | At the anterior superior iliac spine it is easiest to palpate. |

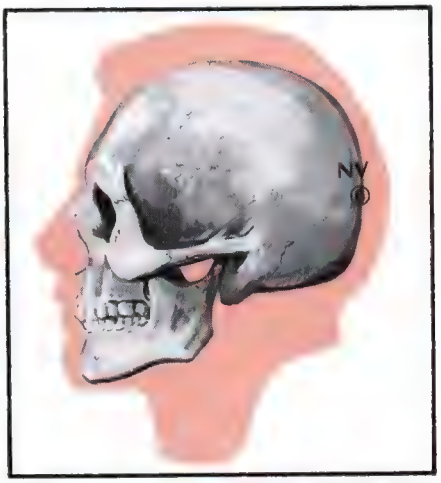


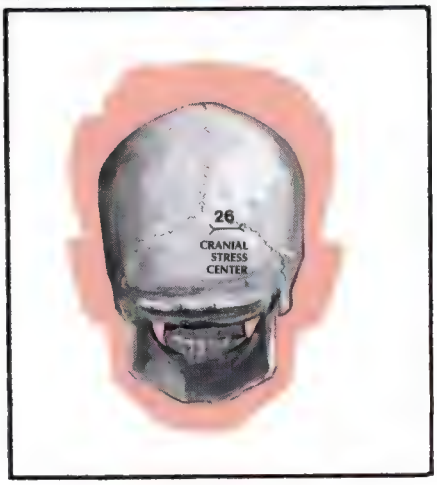

# SARTORIUS - ADRENALS

**TO STRENGTHEN:**

**TO WEAKEN:**

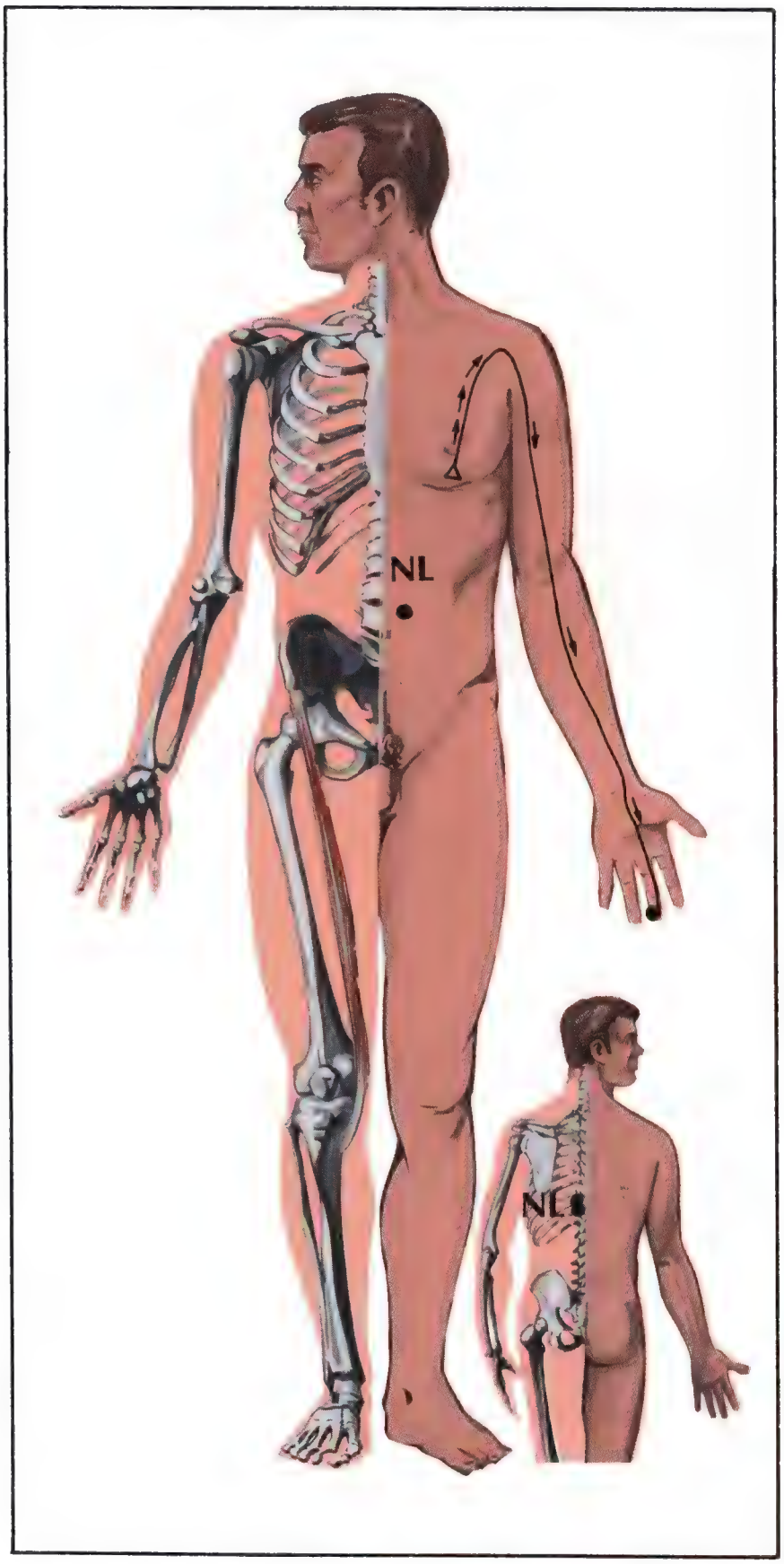

# ANTERIOR SERRATUS - LUNGS

| | |
|---|---|
| STRUCTURAL WEAKNESS | Shoulder problems, diaphragmatic problems. |
| INTERNAL MANIFESTATIONS | Chest congestion, allergies, asthma, hiatal hernia. |
| NEUROLYMPHATICS | **ANTERIOR:** Intercostal space between the 3rd through the 5th ribs, adjacent to the sternum.<br>**POSTERIOR:** Interspinous-transverse space between T-3 through T-5, 1" lateral to the spine. |
| MERIDIAN | Lung. |
| NUTRITION | Lung cytotropic extract, Vitamin C, green peppers, citrus fruits, occasionally spleen extracts are indicated. |
| ASSOCIATED MUSCLES | Deltoid, coracobrachialis, diaphragm. |
| LAB TESTS | WBC, urinalysis, eosinophil count, eosinophil sputum culture. |
| EXERCISE | Push-ups, facing away from wall weights and drawing the arms from a side horizontal to a front horizontal position. |
| ACTION | Abducts scapula, raises ribs when scapula is fixed. |
| ORIGIN | Outer surfaces and superior borders of upper 8 or 9 ribs. |
| INSERTION | Full length of vertebral border of the scapula. |
| NERVE SUPPLY | Long thoracic, C-5, 6 & 7. |
| PALPATE | Front and lateral side of the chest below the 5th & 6th rib. |

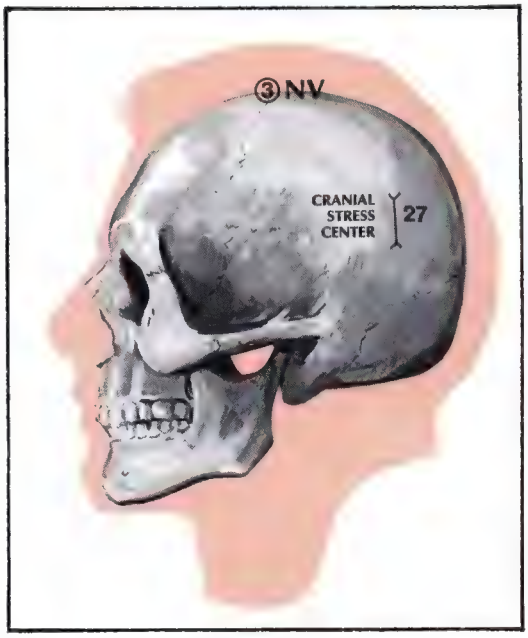

# ANTERIOR SERRATUS - LUNGS

**TO STRENGTHEN:**

**TO WEAKEN:**

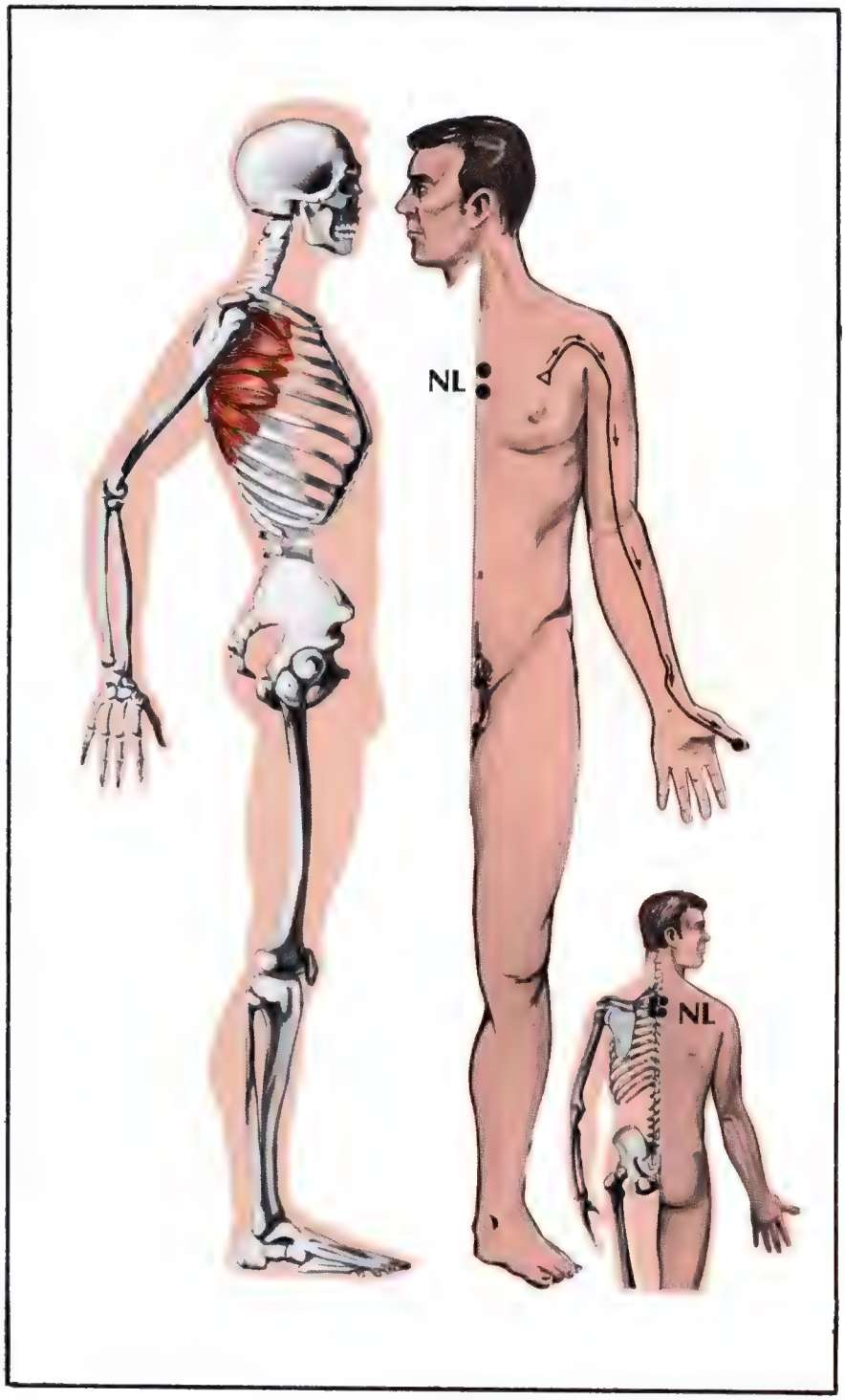

# SOLEUS - ADRENALS

| | |
|---|---|
| STRUCTURAL WEAKNESS | Anterior or forward leaning of the body. |
| INTERNAL MANIFESTATIONS | Allergies, asthma, hypoglycemia, emotional fatigue, morning tiredness, mild shock conditions. |
| NEUROLYMPHATICS | **ANTERIOR:** 1″ on either side and 2″ above umbilicus.<br>**POSTERIOR:** Interspinous-transverse space between T-11 & T-12, and occasionally L-1. |
| MERIDIAN | Circulation sex. |
| NUTRITION | Vitamin C, B complex, natural adrenal extracts. |
| ASSOCIATED MUSCLES | Gracilis, sartorius, pectoralis major clavicular, latissimus dorsi, triceps, adductors, cervical flexors and extensors. |
| LAB TESTS | Eosinophil count, sputum eosinophil culture 5-hour glucose tolerance test, T-3, T-4, RBC count, HGB, hematocrit, serum chloride, serum potassium. |
| EXERCISE | Running, jumping, hopping, skipping. |
| ACTION | Plantar flexes the foot, steadies leg upon foot. |
| ORIGIN | Posterior surface of head of the fibula and upper third of shaft of the fibula, middle third of the medial border of tibia, tendinous arch between tibia and fibula. |
| INSERTION | Into the calcaneus by the calcaneal tendon (Achilles tendon). |
| NERVE SUPPLY | Tibial, L-5, S-1 & 2. |
| PALPATE | Under the gastrocnemius on the lateral side of the lower leg. |

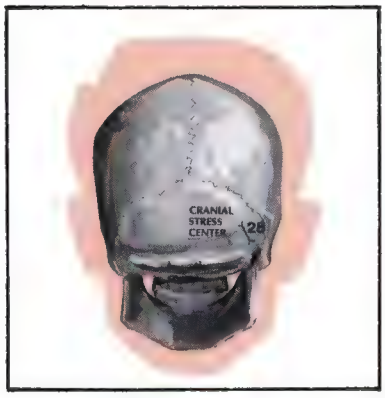


NV IN RESEARCH

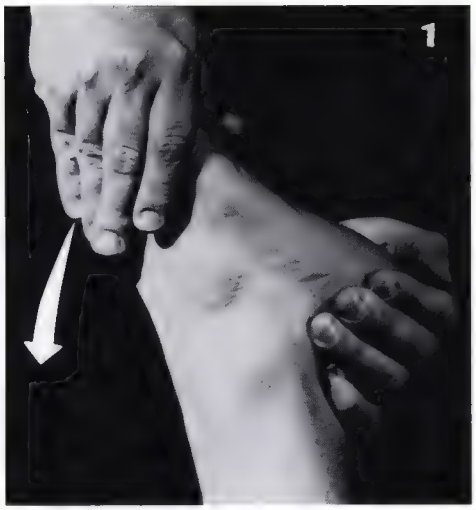

# SOLEUS - ADRENALS

**TO STRENGTHEN:**

**TO WEAKEN:**

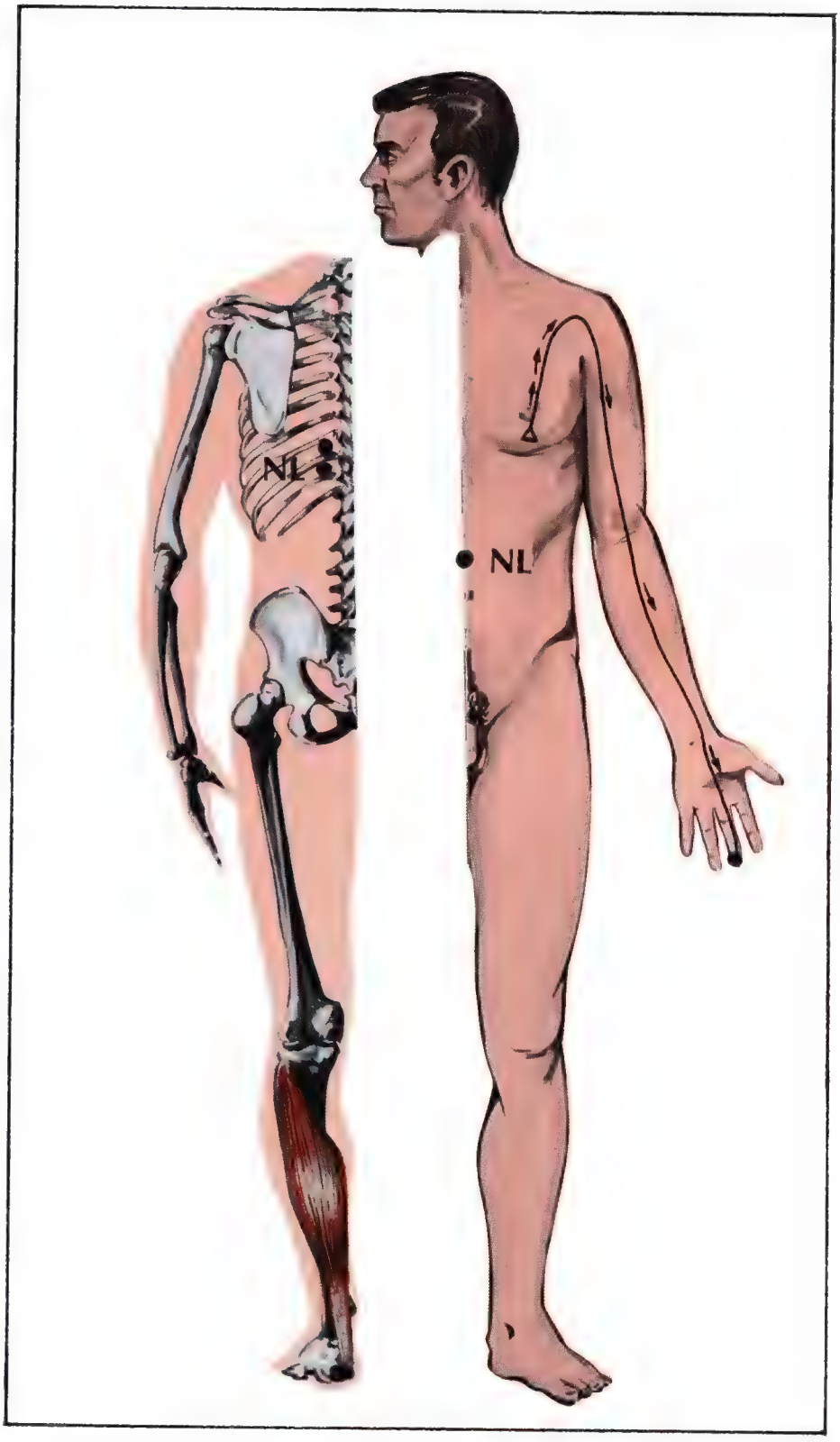

# SUBCLAVIUS — ASSOCIATED ORGAN IN RESEARCH

| | |
|---|---|
| STRUCTURAL WEAKNESS | Shoulder problems, frozen shoulder syndrome, carpal tunnel syndrome, bursitis. |
| INTERNAL MANIFESTATIONS | IN RESEARCH. |
| NEUROLYMPHATICS | **ANTERIOR:** Junction of the clavicle, sternum and 1st rib, and medial two-thirds of the muscle.<br>**POSTERIOR:** Interspinous-transverse space of T-1. |
| MERIDIAN | IN RESEARCH. |
| NUTRITION | Vitamin A, Vitamin C, Vitamin E, acid calcium. |
| ASSOCIATED MUSCLES | Supraspinatus, teres minor, deltoid, coracobrachialis, upper trapezius, anterior scalene, latissimus dorsi, rectus abdominis. Check for weak rectus abdominis on opposite side. |
| LAB TESTS | Serum calcium, CBC, urinalysis, C reactive protein, latex fixation test. |
| EXERCISE | Push-ups, pull-ups, throwing. |
| ACTION | Draws the clavicle downward and draws shoulder forward and downward. |
| ORIGIN | Upper border of the first rib and its cartilages at the junction. |
| INSERTION | Groove on the under surface of the clavicle between the costoclavicular and conoid ligaments. |
| NERVE SUPPLY | 5th & 6th cervical nerve. |
| PALPATE | Not palpable. |

NOTE: Subclavius muscle can not be isolated to be tested.

NV IN RESEARCH

CSC IN RESEARCH

# SUBCLAVIUS

ACU-THERAPY HOLDING POINTS IN RESEARCH.

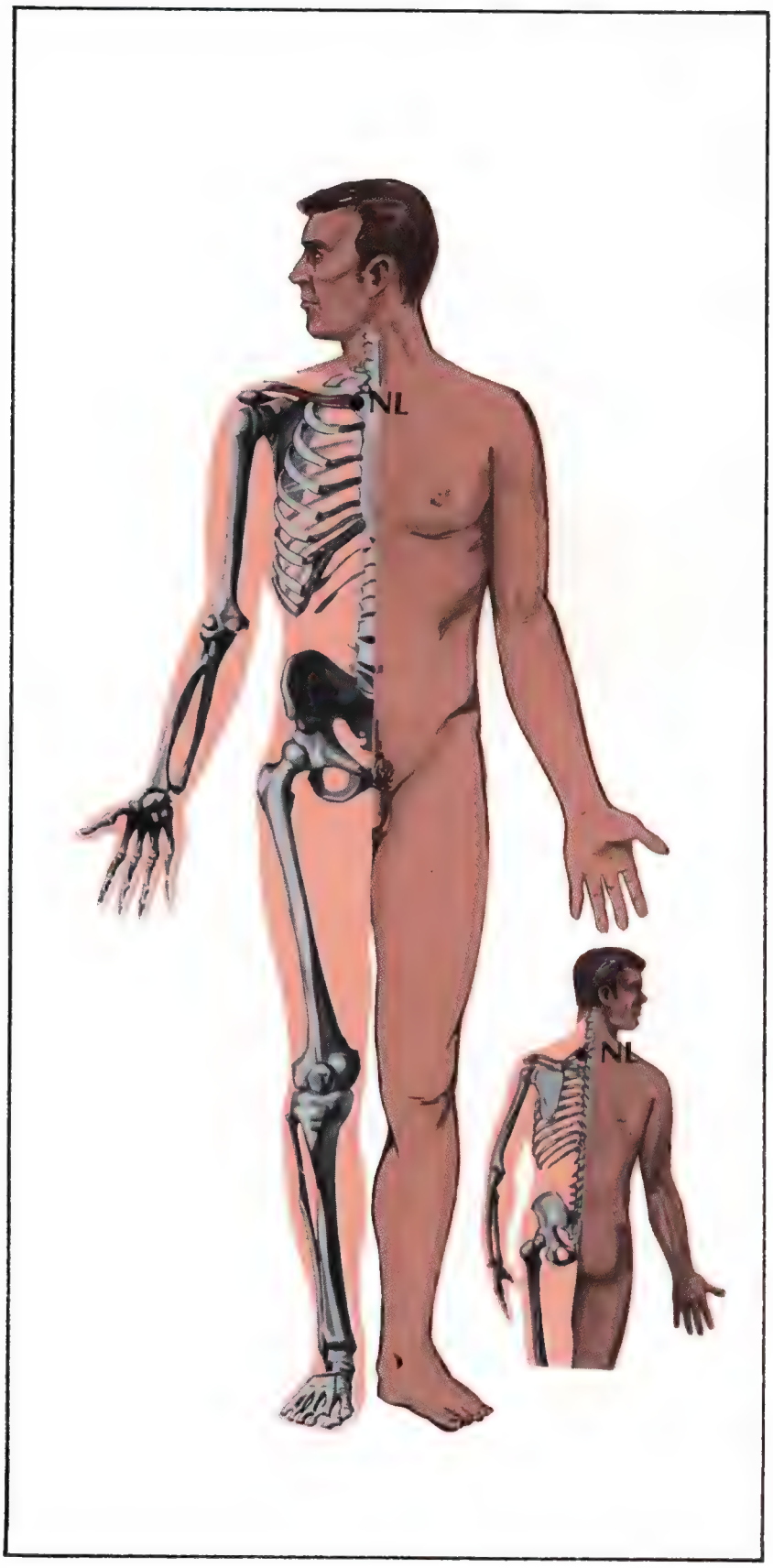

# SUBSCAPULARIS - HEART

| | |
|---|---|
| STRUCTURAL WEAKNESS | Chest pains or tight feeling in the chest, shoulder problems, brachial neuritis. |
| INTERNAL MANIFESTATIONS | Palpations, dizziness, bleeding gums, difficulty swallowing. |
| NEUROLYMPHATICS | **ANTERIOR:** Intercostal space between 2nd & 3rd ribs, near the border of the sternum.<br>**POSTERIOR:** Intertransverse space, between T-2 & T-3. |
| MERIDIAN | Heart. |
| NUTRITION | Vitamin G, Vitamin E, B complex, Vitamin C, cardiac extract. |
| ASSOCIATED MUSCLES | Abdominals, quadriceps, supraspinatus, psoas. |
| LAB TESTS | CBC, ESR, cardiac enzymes, BUN, T-3, urinalysis cardiac enzymes, serum bilirubin. |
| EXERCISE | Rope climbing, chinning, dips on parallel bars. |
| ACTION | Rotates humerus medially and draws it forward and downward when the arm is raised. |
| ORIGIN | Subscapular fossa of scapula. |
| INSERTION | Lesser tubercle of humerus and the front of the capsule of shoulder joint. |
| NERVE SUPPLY | Upper and lower subscapular, C-5 & 6. |
| PALPATE | Cannot be palpated. |

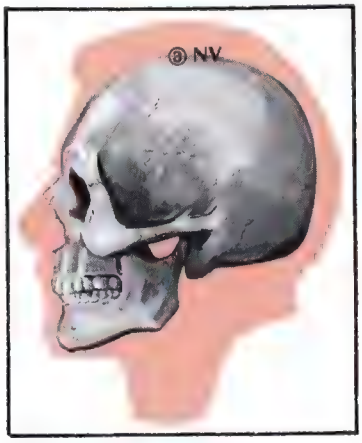


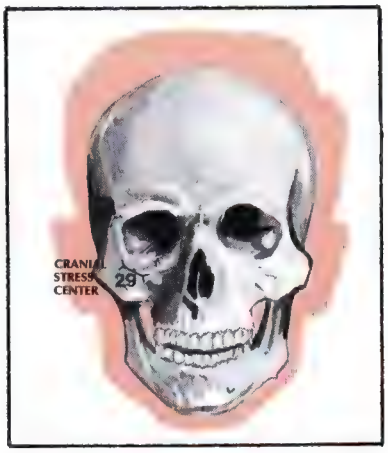

# SUBSCAPULARIS - HEART

**TO STRENGTHEN:**

**TO WEAKEN:**

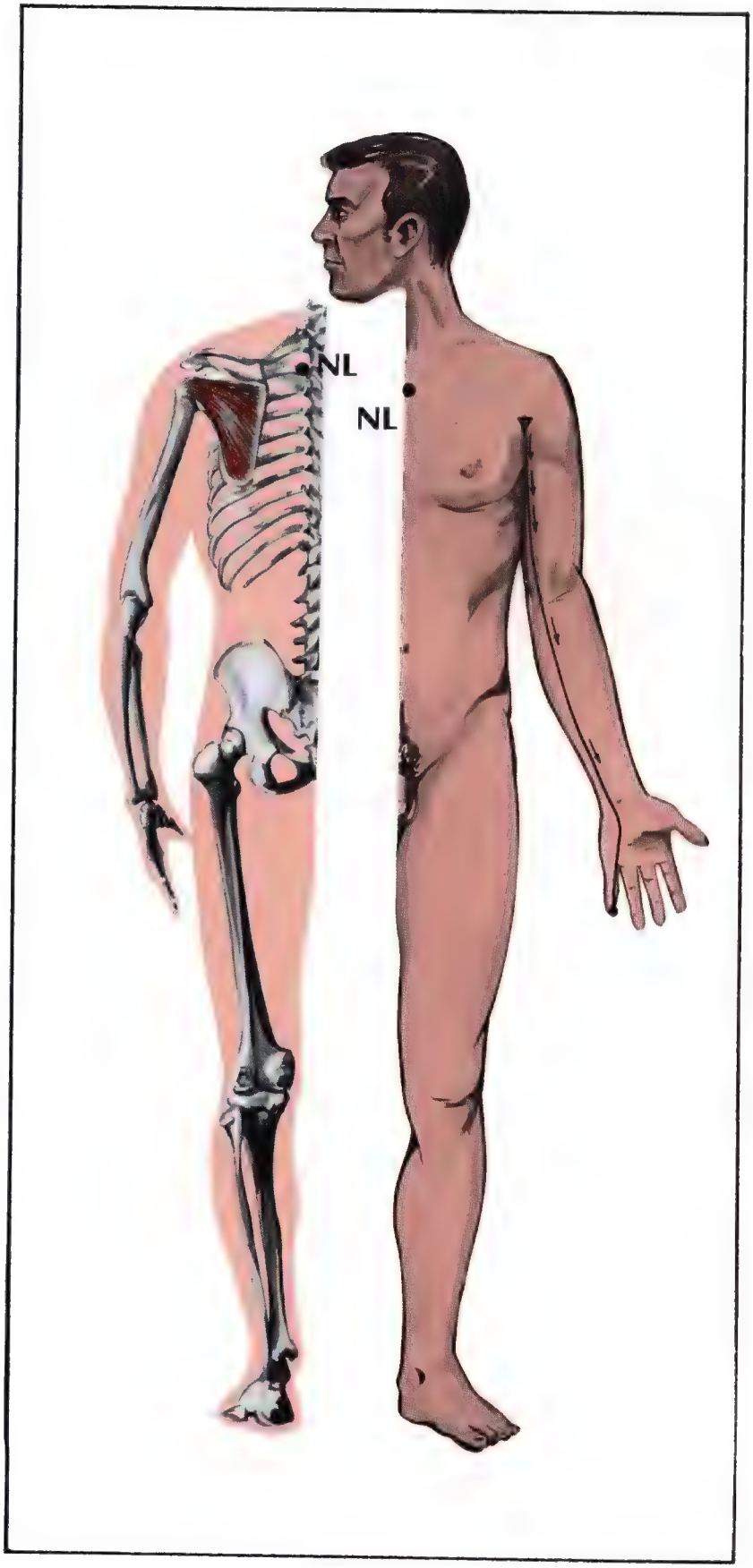

# SUPRASPINATUS - BRAIN

| | |
|---|---|
| STRUCTURAL WEAKNESS | Shoulder problems. |
| INTERNAL MANIFESTATIONS | Anxiety, emotional stress, mental fatigue, learning problems in children. |
| NEUROLYMPHATICS | **ANTERIOR:** Tip of the coracoid process of the scapula.<br>**POSTERIOR:** At the base of the skull, 1-2" lateral of the center line. |
| MERIDIAN | Central meridian or conception vessel. |
| NUTRITION | Cytotropic extracts of brain material, RNA. |
| ASSOCIATED MUSCLES | Deltoid, upper trapezius, popliteus, pectoralis major clavicular, pectoralis major sternal. |
| LAB TESTS | CBC, urinalysis, HGB, serum magnesium. |
| EXERCISE | Dips, dumbell or barbell extensions above the head. |
| ACTION | Abducts the shoulder joint, stabilizes the head of the humerus into the glenoid cavity during movements of this joint. |
| ORIGIN | Medial two-thirds of supraspinous fossa of the scapula. |
| INSERTION | Superior facet of the greater tubercle of the humerus, the shoulder joint capsule. |
| NERVE SUPPLY | Suprascapular, C-4, 5 & 6. |
| PALPATE | Located under the deltoid muscle & cannot be palpated. |

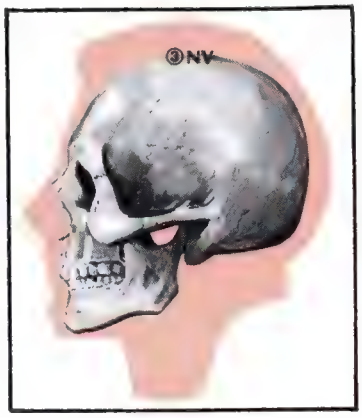


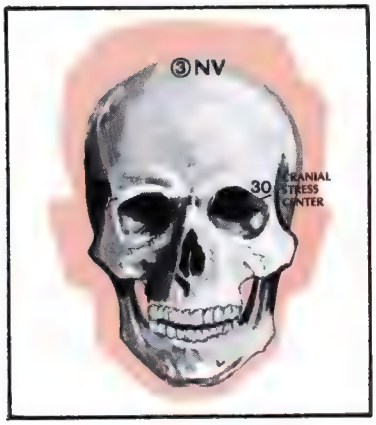

# SUPRASPINATUS - BRAIN

ACU-THERAPY HOLDING POINTS
IN RESEARCH.

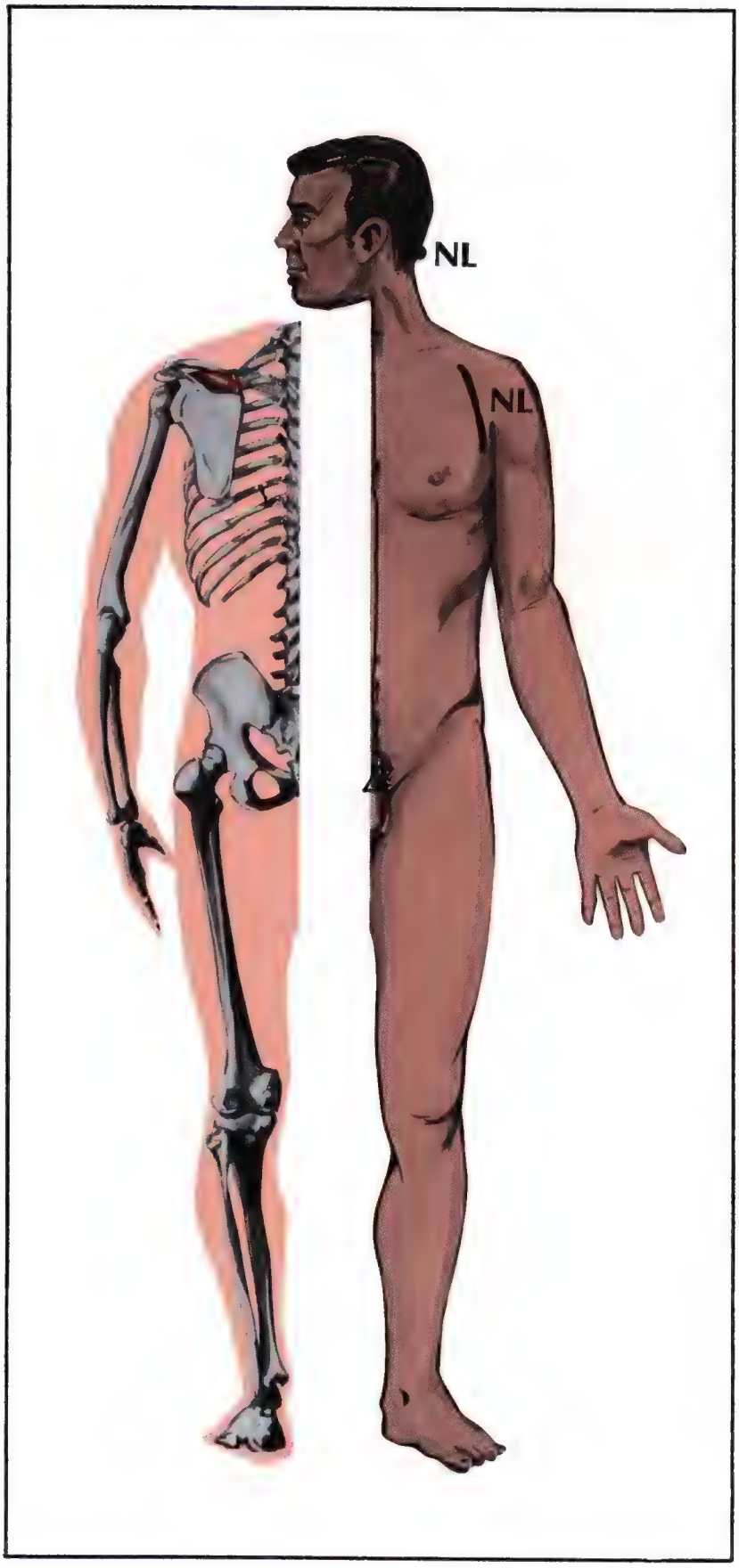

# TEMPORALIS

| | |
|---|---|
| STRUCTURAL WEAKNESS | Jaw problems. |
| INTERNAL MANIFESTATIONS | Headaches. |
| NEUROLYMPHATICS | IN RESEARCH. Possibly 2nd & 3rd intercostal space adjacent to the sternum. |
| MERIDIAN | Stomach. |
| NUTRITION | IN RESEARCH. |
| ASSOCIATED MUSCLES | Neck flexors and extensors. |
| LAB TESTS | IN RESEARCH. |
| EXERCISE | IN RESEARCH. |
| ACTION | Closes the jaw. |
| ORIGIN | From the whole of the temporal fossa and from the deep surface of the temporal fascia. |
| INSERTION | Coronoid process and anterior border of the ramus of the mandible. |
| NERVE SUPPLY | Anterior and posterior deep temporal nerves from the mandibular division of the trigeminal nerve. |
| PALPATE | Superior to the ear. |

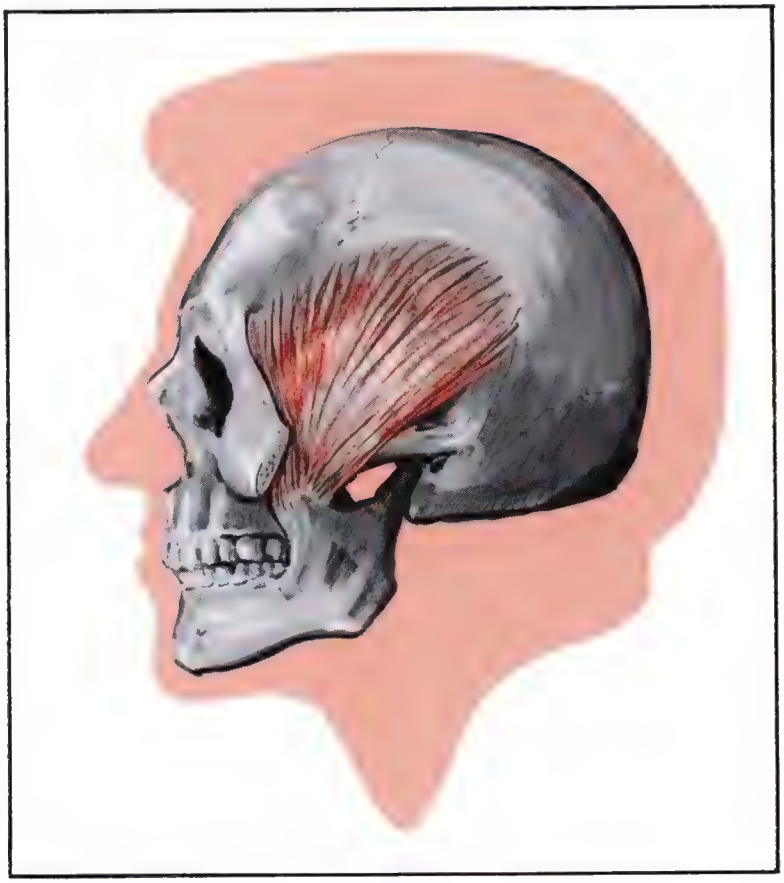

NV IN RESEARCH
CSC IN RESEARCH

# TEMPORALIS

**TO STRENGTHEN:**

**TO WEAKEN:**

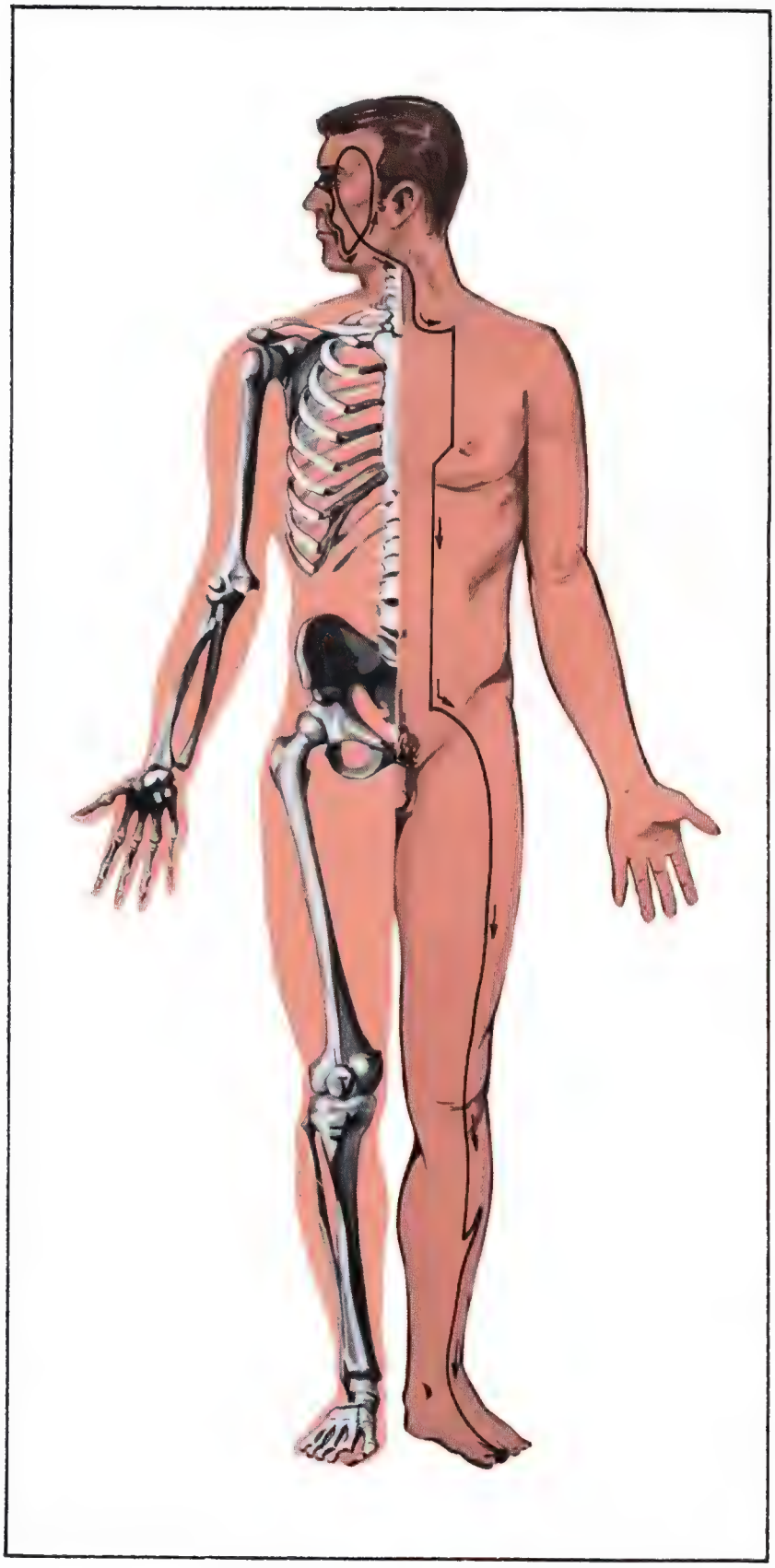

# TENSOR FASCIA LATA - LARGE INTESTINE

| | |
|---|---|
| STRUCTURAL WEAKNESS | Low back conditions, sciatica, pelvic tilts, knee problems, a tendency toward bowed legs. |
| INTERNAL MANIFESTATIONS | Constipation, colitis, spastic colon, diarrhea, menstrual problems and breast soreness. If bilateral weakness, check for possible hypochromic anemia. |
| NEUROLYMPHATICS | **ANTERIOR:** From the trochanter of the femur, lateral aspect of the thigh to the knee. **POSTERIOR:** The triangular area from L-2 to the middle of the posterior crest of the ilium, across to the 4th lumbar vertebrae. |
| MERIDIAN | Large Intestine. |
| NUTRITION | Intestinal enzymes, lactic acid yeast, Vitamin D, Vitamin B. If bilateral, use iron. |
| ASSOCIATED MUSCLES | Adductors, quadriceps, psoas. |
| LAB TESTS | ESR, neutrophil count, stool examination for blood, pus and mucous, total and fractionated estrogens, RBC, HGB, hematocrit. |
| EXERCISE | Supine leg raises with inward rotation of the femur, jogging. |
| ACTION | Flexes, medially rotates the thigh, helps assist in knee extension. |
| ORIGIN | Anterior part of the outer lip of the iliac crest, outer surface of anterior superior iliac spine. |
| INSERTION | Middle one-third of thigh between the two layers of the iliotibial band. |
| NERVE SUPPLY | Superior gluteal nerve, L-4, 5 & S-1. |
| PALPATE | Slightly in front of the greater trochanter of the femur. |

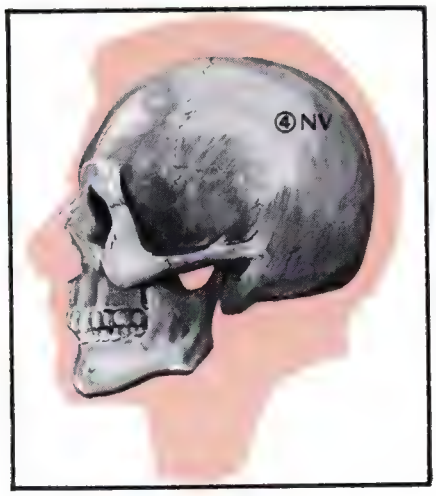


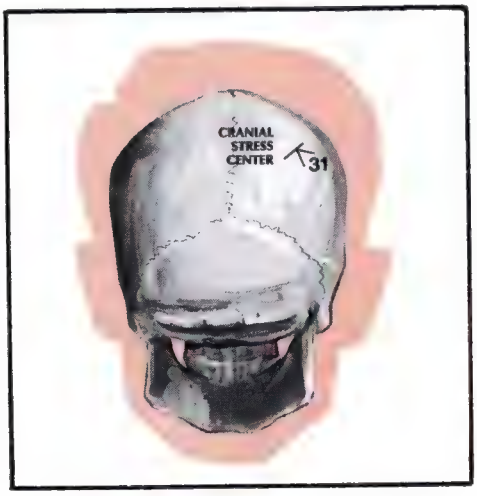

# TENSOR FASCIA LATA - LARGE INTESTINE

**TO STRENGTHEN:**

**TO WEAKEN:**

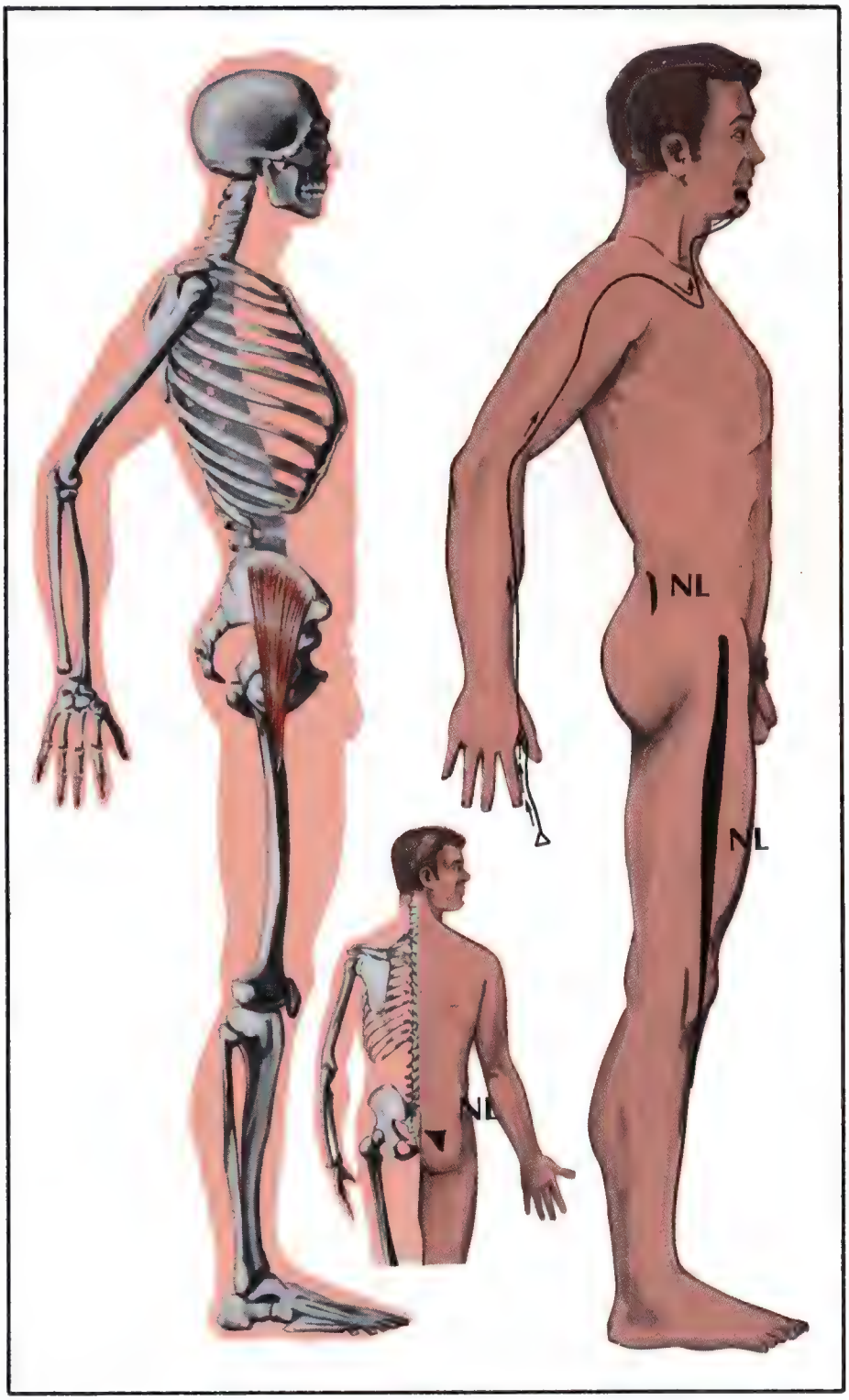

# TERES MAJOR - SPINE

| | |
|---|---|
| STRUCTURAL WEAKNESS | Rib fixations, shoulder problems, when bilaterally weak, check for dorsal fixations. |
| INTERNAL MANIFESTATIONS | Acid alkaline imbalance, muscular cramps, plantar warts, and glucose metabolism disorders. |
| NEUROLYMPHATICS | **ANTERIOR:** Between the 2nd & 3rd ribs, approximately 2½" lateral to the sternum.<br>**POSTERIOR:** Between T-2 & T-3, 1" lateral to the spine. |
| MERIDIAN | IN RESEARCH. Possibly stomach meridian or governing vessel. |
| NUTRITION | Kelp is indicated in cases of excess perspiration. Chromium in trace minerals for glucose problems. |
| ASSOCIATED MUSCLES | Trapezius. |
| LAB TESTS | Check pH of saliva and urine, 5 hour glucose tolerance test. |
| EXERCISE | Chinning, rope climbing, dips on parallel bars or other upper movements on horizontal bars (see latissimus dorsi exercises). |
| ACTION | Adducts, medially rotates humerus, extends the shoulder joint. |
| ORIGIN | Dorsal surface of the inferior angle of the scapula. |
| INSERTION | Crest of the lesser tubercle of humerus. |
| NERVE SUPPLY | Lower subscapular, C-5, 6 & 7. |
| PALPATE | Posterior surface diagonally upward from the inferior angle of the scapula. |

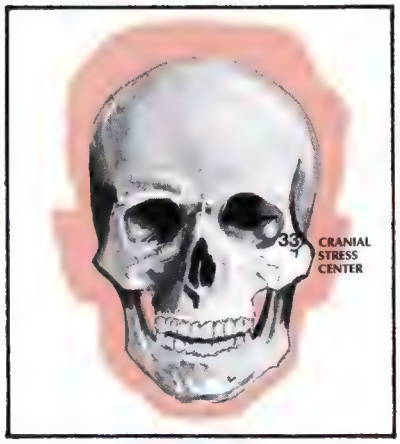


NV IN RESEARCH

# TERES MAJOR - SPINE

ACU-THERAPY HOLDING POINTS IN RESEARCH.

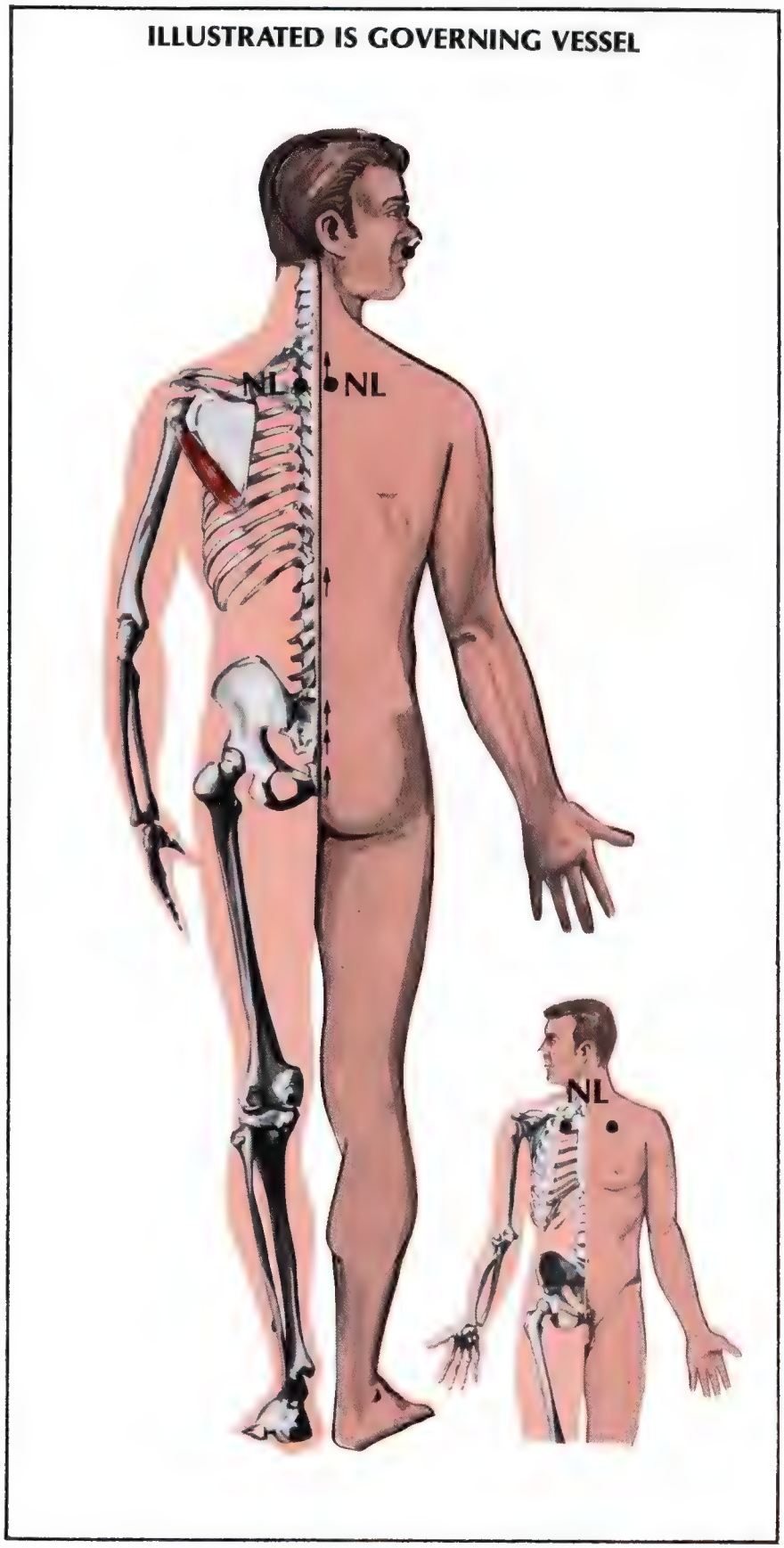

# TERES MINOR - THYROID

| | |
|---|---|
| STRUCTURAL WEAKNESS | Elbow and wrist problems, shoulder difficulties, teres minor appears weak if trapezius or rhomboids are weak. |
| INTERNAL MANIFESTATIONS | Thyroid conditions, digestive disturbances, infections, weight changes, unwarranted and uncontrolled crying. |
| NEUROLYMPHATICS | **ANTERIOR:** Between 2nd & 3rd ribs, adjacent to sternum.<br>**POSTERIOR:** Transverse space between T-2 & T-3. |
| MERIDIAN | Triple-warmer. |
| NUTRITION | Organic iodine, kelp, thyroid extract. |
| ASSOCIATED MUSCLES | Trapezius, rhomboids. |
| LAB TESTS | T-3, T-4, cholesterol, diagnex blue, WBC. |
| EXERCISE | Jumping jacks, push-ups, jumping rope, swimming. |
| ACTION | Rotates arm laterally and weakly adducts it, draws the humerus toward glenoid fossa. |
| ORIGIN | Dorsal surface of the axillary border of scapula. |
| INSERTION | Lowest impression of the greater tuberosity of the humerus, capsule of the shoulder joint. |
| NERVE SUPPLY | Axillary, C-5 & 6. |
| PALPATE | Between scapula and humerus on the posterior side, just below the fibers of the deltoid. |

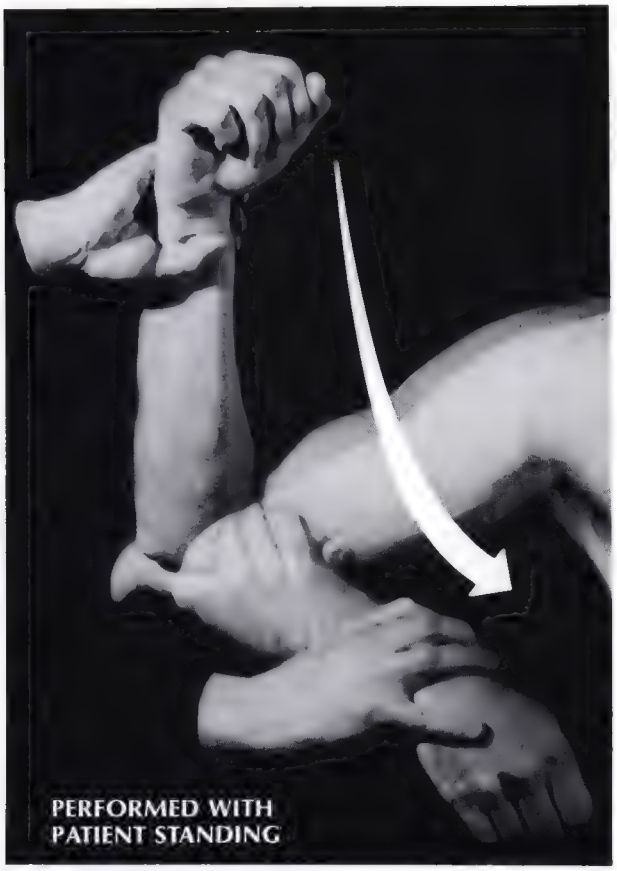

# TERES MINOR - THYROID

**TO STRENGTHEN:**

**TO WEAKEN:**

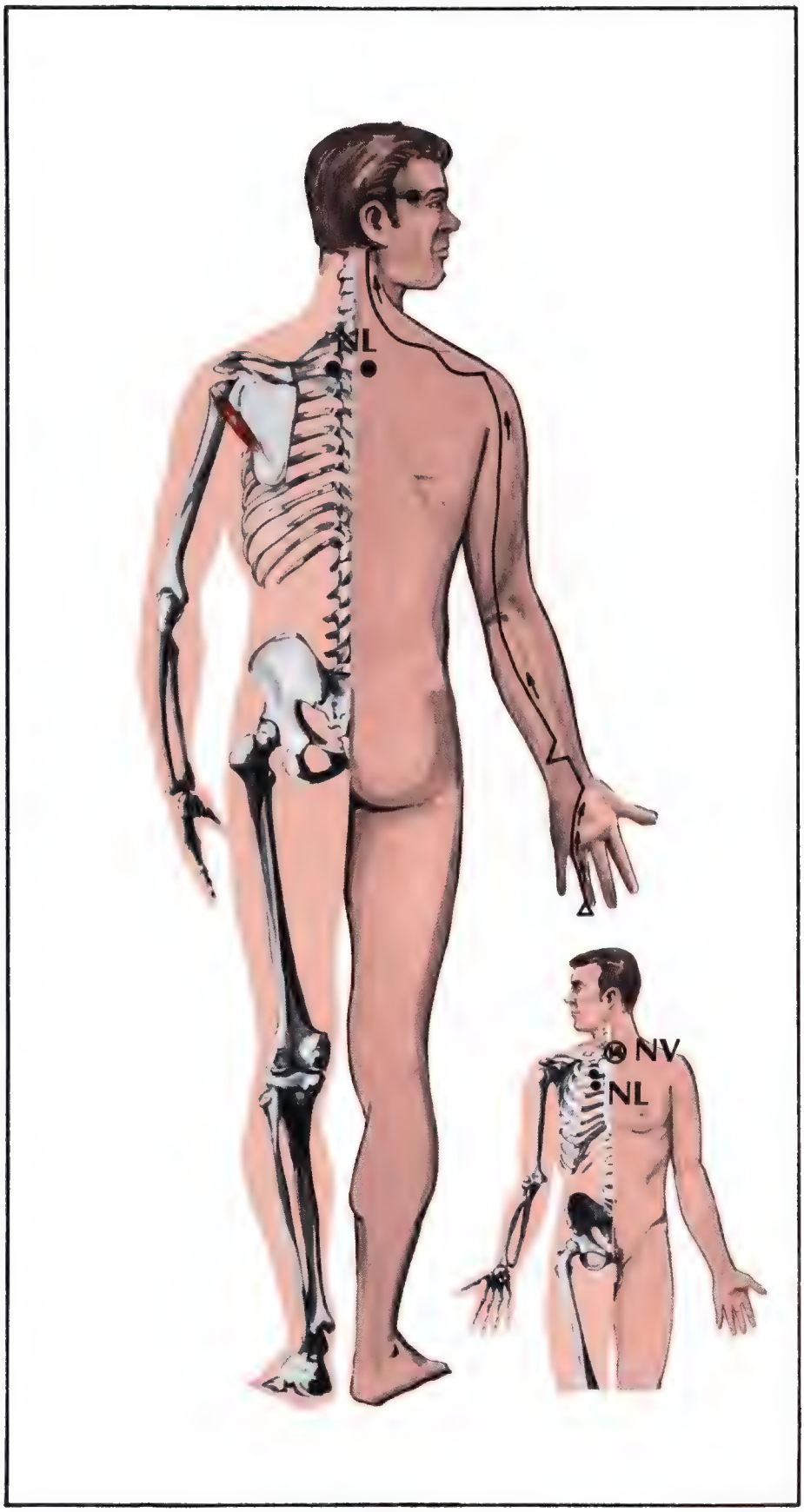

# TIBIALIS ANTERIOR - BLADDER

| | |
|---|---|
| STRUCTURAL WEAKNESS | Flatfoot or fallen arches, bunions. |
| INTERNAL MANIFESTATIONS | Rectal fissures and other related rectal problems, urethra and bladder problems. |
| NEUROLYMPHATICS | **ANTERIOR:** Approximately ¾″ superior to the symphysis pubis.<br>**POSTERIOR:** Upper edge of L-2 transverse process. |
| MERIDIAN | Bladder. |
| NUTRITION | Vitamin E, wheat germ. |
| ASSOCIATED MUSCLES | Sacrospinalis, peroneus, psoas. |
| LAB TESTS | CBC, ESR, urinalysis, urine culture. |
| EXERCISE | Walking on the outside of the foot (inversion). |
| ACTION | Dorsiflexes the foot and inverts it. |
| ORIGIN | Front of leg from lateral condyle and upper one-half of the lateral surface of the tibial body, interosseous membrane and lateral intermuscular septum. |
| INSERTION | Medial and plantar surface of the medial cuneiform bone and base of the first metatarsal bone. |
| NERVE SUPPLY | Peroneal, L-4, 5 & S-1. |
| PALPATE | First muscle on the lateral side of the tibia. |

NV IN RESEARCH

# TIBIALIS ANTERIOR - BLADDER

**TO STRENGTHEN:**

**TO WEAKEN:**

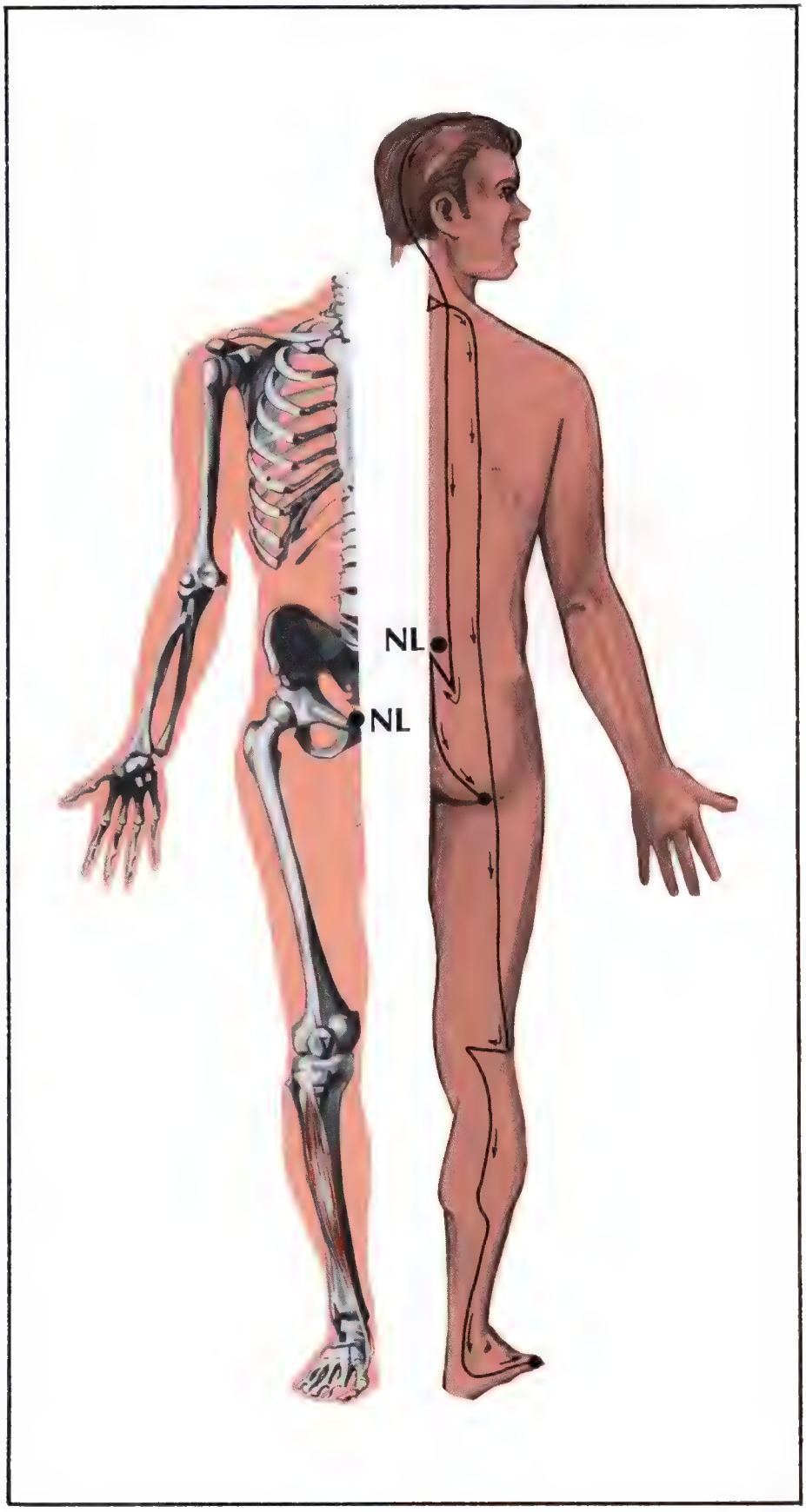

# TIBIALIS POSTERIOR — ASSOCIATED ORGAN IN RESEARCH

| | |
|---|---|
| STRUCTURAL WEAKNESS | Pronation of the foot, possible fallen arches, inability to stand on the toes, gastrocnemius limp. |
| INTERNAL MANIFESTATIONS | IN RESEARCH. |
| NEUROLYMPHATICS | IN RESEARCH — At this time, origin/insertion technique will provide similar results to neurolymphatic stimulation. |
| MERIDIAN | Liver. |
| NUTRITION | Vitamin E. |
| ASSOCIATED MUSCLES | Flexor digitorum longus, extensor hallucis longus, soleus, gastrocnemius, peroneus, anterior tibials. |
| LAB TESTS | IN RESEARCH. |
| EXERCISE | Running, jumping, hopping, skipping, toe walking. |
| ACTION | Plantar flexes the foot and inverts it. |
| ORIGIN | Lateral part of the posterior surface of the body of tibia, upper two-thirds of the medial surface of the fibula and interosseous membrane. |
| INSERTION | Tuberosity of the navicular bone, plantar surface of all cuneiform bones, cuboid and bases of the 2nd, 3rd & 4th metatarsals. |
| NERVE SUPPLY | Tibial, L-4, 5 & S-1. |
| PALPATE | Cannot be palpated. |

NV IN RESEARCH

CSC IN RESEARCH

# TIBIALIS POSTERIOR

**TO STRENGTHEN:**

**TO WEAKEN:**

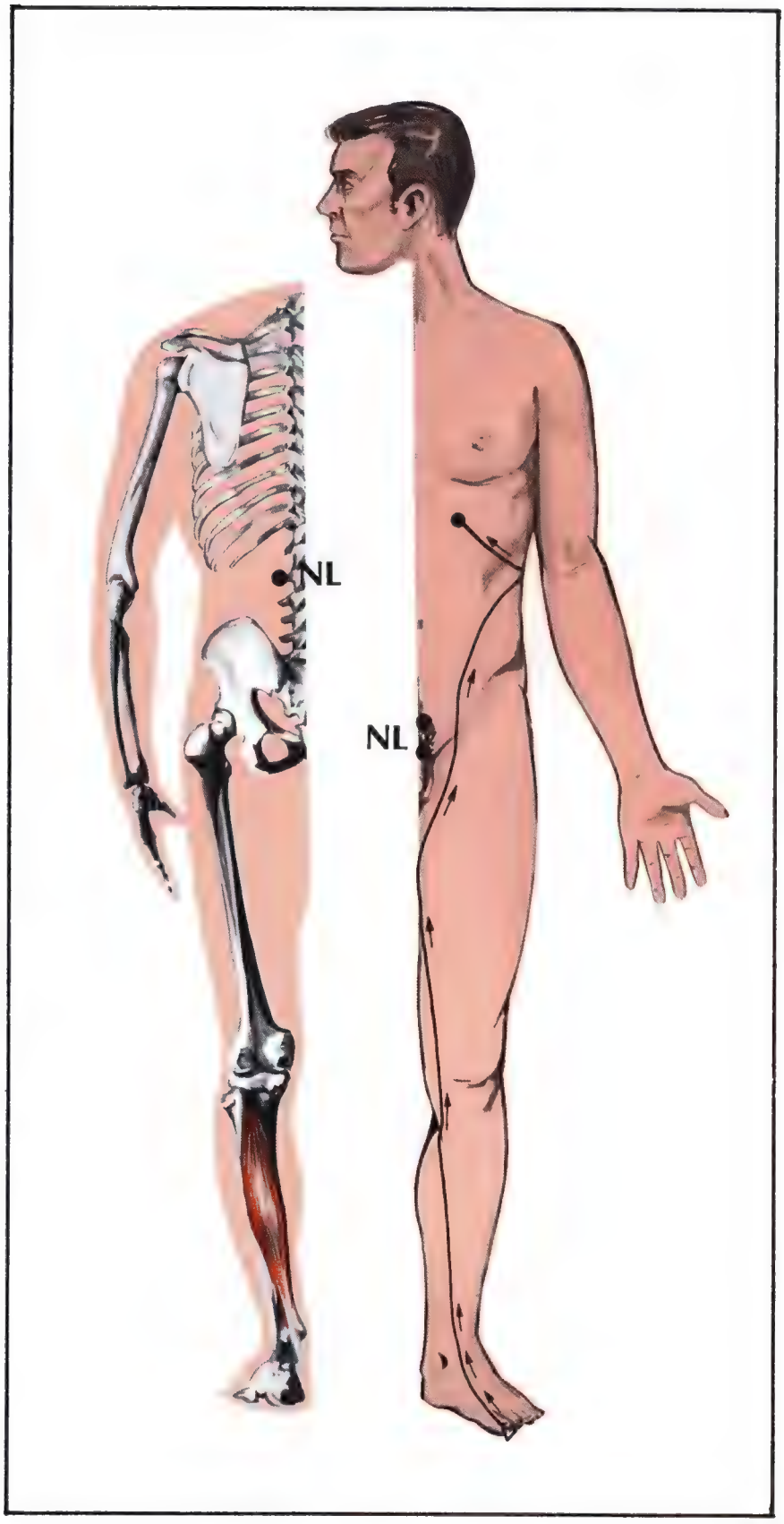

# TRAPEZIUS - SPLEEN
## MIDDLE & LOWER

| | |
|---|---|
| STRUCTURAL WEAKNESS | Sciatic neuritis, upper back pain, difficulty in abduction or flexion of the humerus. When the lower trapezius is bilaterally weak, this indicates dorsal lumbar fixation. Frequently involved with the 7th thoracic subluxation and a cause of pain in the pectoralis major clavicular. |
| INTERNAL MANIFESTATIONS | Infections, sore throats, hearing loss, anemia, polycythemia, high temperatures. |
| NEUROLYMPHATICS | **ANTERIOR:** Between the 7th & 8th ribs, near the junction of the cartilages on the *left* only.<br>**POSTERIOR:** Between T-7 & T-8 transverse processes. |
| MERIDIAN | Spleen. |
| NUTRITION | Vitamin C, Vitamin F, Vitamin G, ACP, thymus extracts and calcium lactate. |
| ASSOCIATED MUSCLES | Serratus anterior, rhomboids, pectoralis major clavicular. |
| LAB TESTS | CBC, HGB, ESR, hematocrit. |
| EXERCISE | Behind-the-head chins, weights in each hand with the arms extended horizontally moving them overhead, shoulder shrugs with weights in the hands. |
| ACTION | Adducts scapula, tilts the chin, draws back the acromion, rotates the scapula and draws scapula downward. |
| ORIGIN | **MIDDLE:** Spinous processes of T-1 through T-5.<br>**LOWER:** Spinous process of T-6 through T-12. |
| INSERTION | **MIDDLE:** Superior lip of the spine of the scapula.<br>**LOWER:** Apex of the spine of the scapula. |
| NERVE SUPPLY | Spinal accessory (11th cranial), ventral ramus, C-2, 3 & 4. |
| PALPATE | The large area between the spine and the scapula in the vertebral column. |

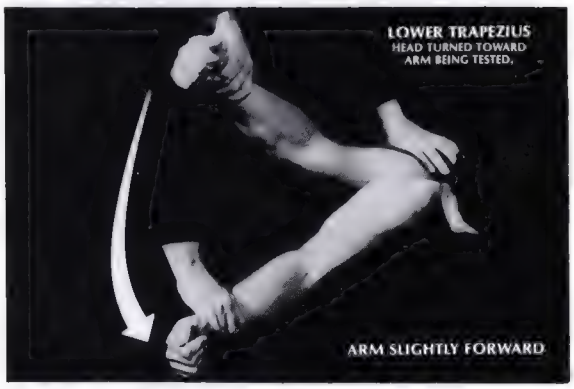


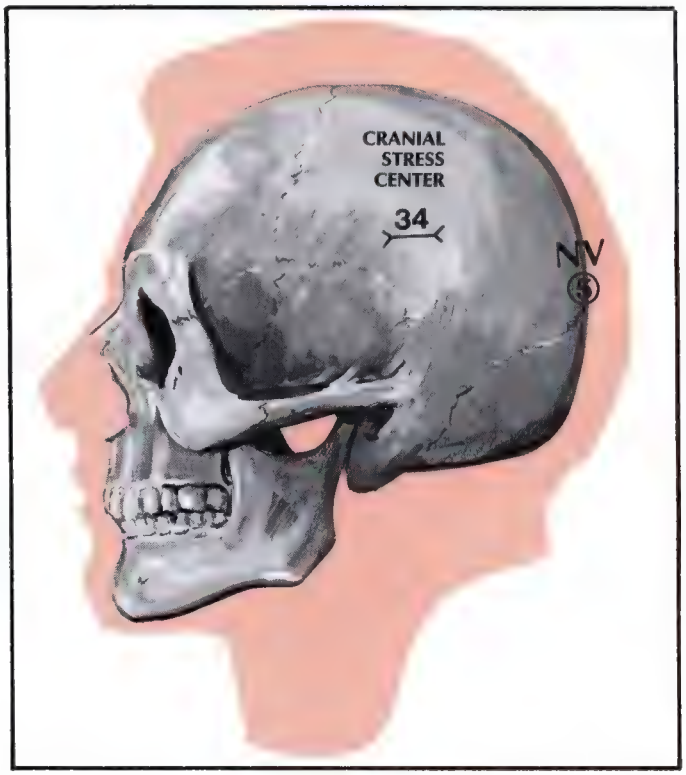

# TRAPEZIUS - SPLEEN
## MIDDLE & LOWER

**TO STRENGTHEN:**

**TO WEAKEN:**

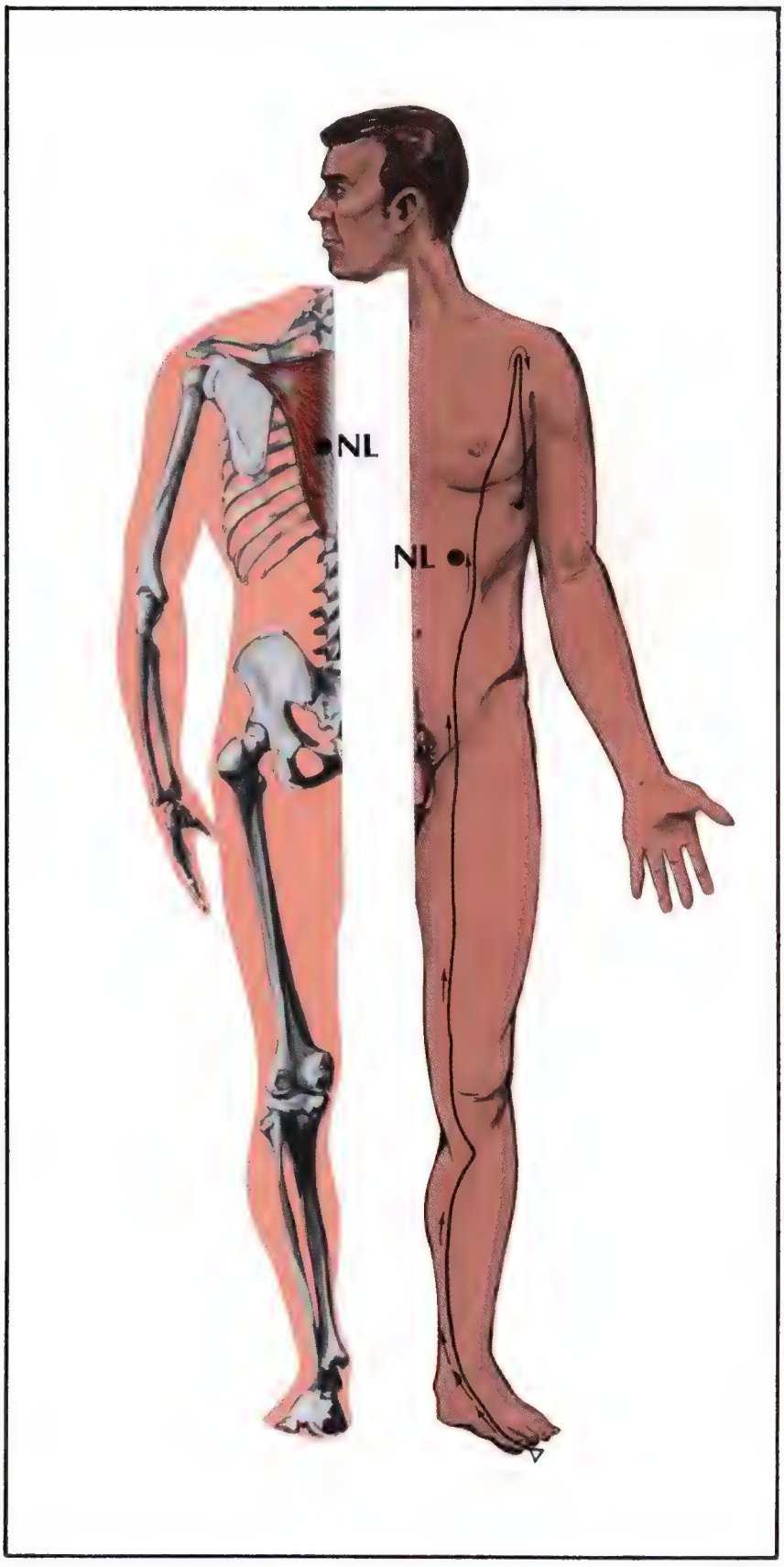

# TRAPEZIUS - EYE & EAR

## UPPER

| | |
|---|---|
| STRUCTURAL WEAKNESS | Torticollis, high occiput and low shoulder frequently seen on the side of weakness, sciatic neuritis with blurring of vision. |
| INTERNAL MANIFESTATIONS | Eye problems, hearing loss, otitis media, conjunctivitis and night blindness. |
| NEUROLYMPHATICS | **ANTERIOR:** Anterior surface of humerus from surgical neck downward in the midline for about 2½".<br>**POSTERIOR:** Base of the skull, approximately 1½" lateral to the center of the base of the skull. |
| MERIDIAN | Kidney. |
| NUTRITION | Vitamins A, B, F, G and calcium, avoidance of foods containing oxalic acid may be necessary, e.g., coffee, chocolate, cranberries, purple fruit. |
| ASSOCIATED MUSCLES | Neck flexors and extensors, rhomboids, pectoralis major clavicular. |
| LAB TESTS | CBC, culture and sensitivity, blood test for Vitamin A, audiometer. |
| EXERCISE | Behind-the-head chins, weights in each hand with the arms extended horizontally moving them overhead, shoulder shrugs with weights in the hands. |
| ACTION | Adducts scapula, tilts the chin, draws back the acromion, rotates the scapula, and draws scapula upward, bracing the shoulder. |
| ORIGIN | External occipital protuberance, superior nuchal line, nuchal ligament from the spine of the 7th cervical vertebrae. |
| INSERTION | Into the lateral third of the clavicle, spine of the scapula and acromion. |
| NERVE SUPPLY | Spinal accessory (11th cranial) and ventral ramus, C-2, 3 & 4. |
| PALPATE | Upper area above the scapula to the base of the skull. |

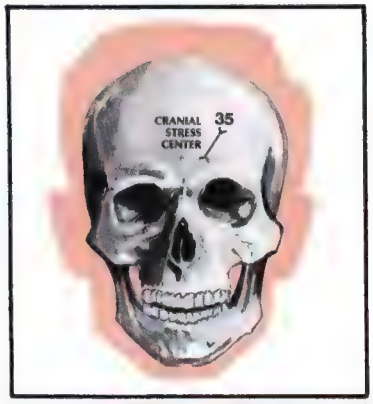


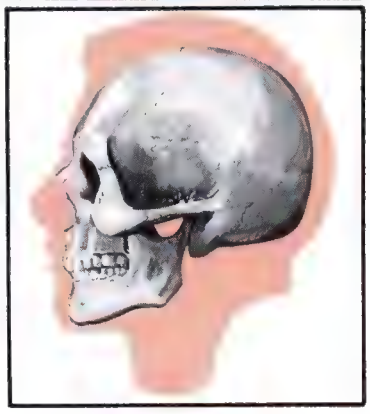

# TRAPEZIUS - EYE & EAR
## UPPER

**TO STRENGTHEN:**

**TO WEAKEN:**

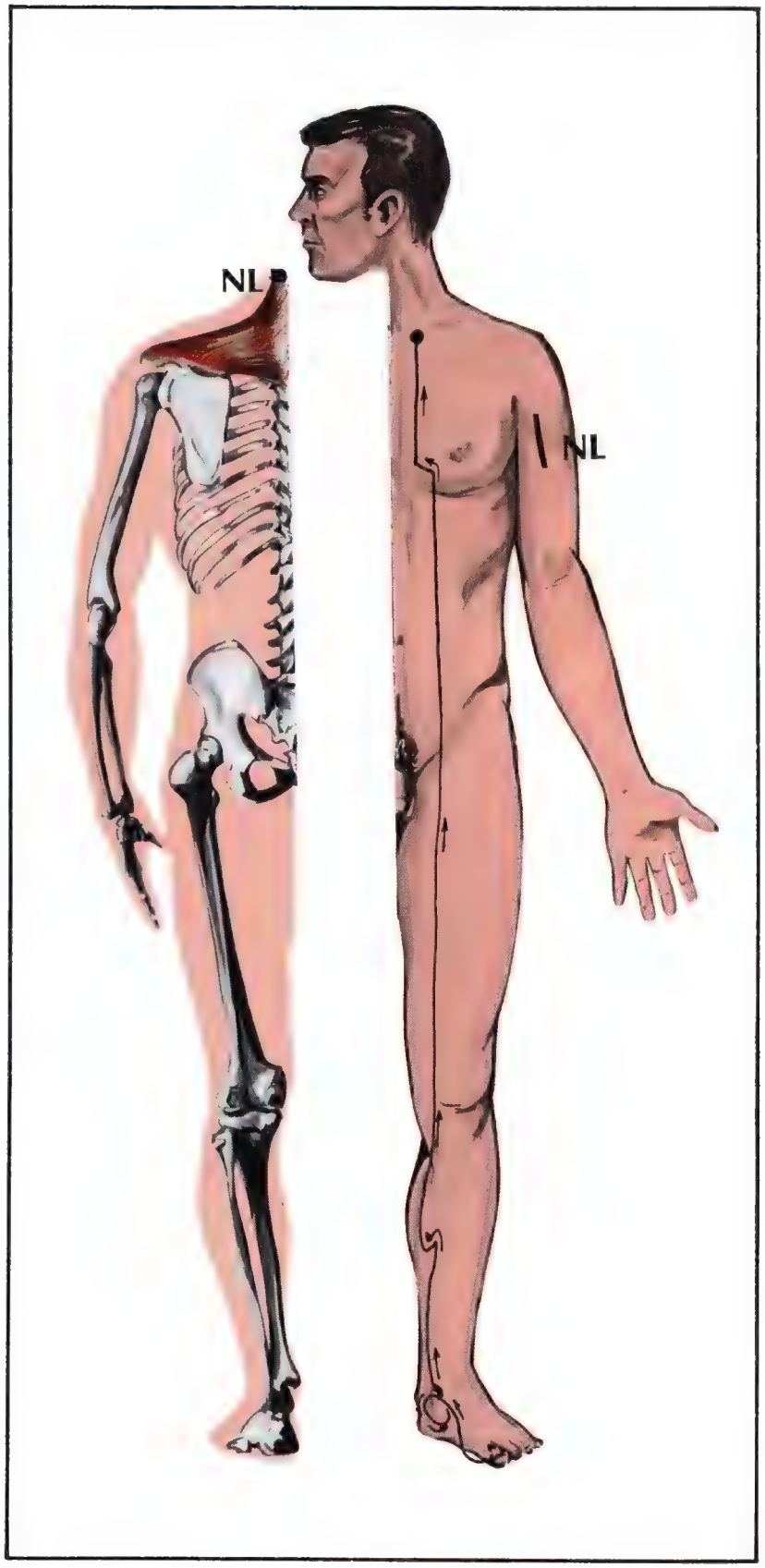

# TRICEPS BRACHII - PANCREAS

| | |
|---|---|
| STRUCTURAL WEAKNESS | Elbow and shoulder problems. |
| INTERNAL MANIFESTATIONS | Carbohydrate sensitivity. |
| NEUROLYMPHATICS | **ANTERIOR:** Between the 7th & 8th ribs, below the nipple.<br>**POSTERIOR:** Between T-7 & T-8, 1" to each side of the spine, and belly of the supraspinatus muscle. |
| MERIDIAN | Spleen. |
| NUTRITION | Vitamin A, Vitamin F, betaine hydrochloride concentrates. |
| ASSOCIATED MUSCLES | Latissimus dorsi, rhomboids, levator scapulae. |
| LAB TESTS | 5-hour glucose tolerance, adrenal cortical function test. |
| EXERCISE | Dips on parallel bar, push-ups, pressing a barbell or dumbell upward. |
| ACTION | Extends the forearm, the long head adducts and may assist in the extension of the shoulder joint. |
| ORIGIN | **The Long Head:** Infraglenoid tubercle of scapula.<br>**The Lateral Head:** Posterior and lateral surface of the humerus and lateral intermuscular septum.<br>**The Medial Head:** Posterior surface of the humerus below radial groove, medial border of humerus, medial intermuscular septum. |
| INSERTION | Posterior surface of the olecranon process of ulna. |
| NERVE SUPPLY | Radial, C-6, 7, 8 & T-1. |
| PALPATE | Posterior lateral aspect of the humerus. |

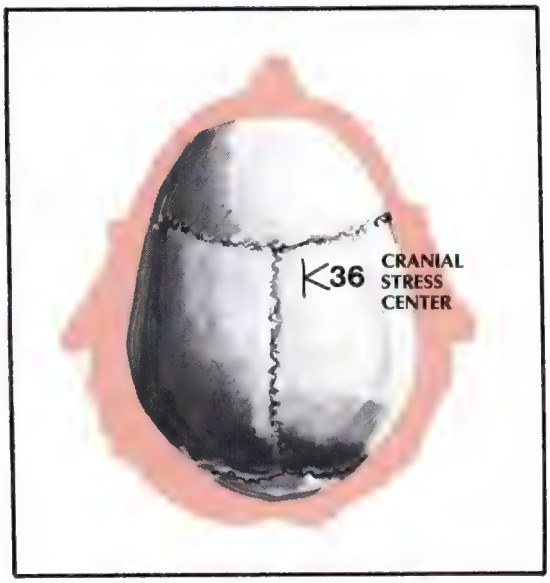


NV IN RESEARCH

# TRICEPS BRACHII - PANCREAS

**TO STRENGTHEN:**

**TO WEAKEN:**

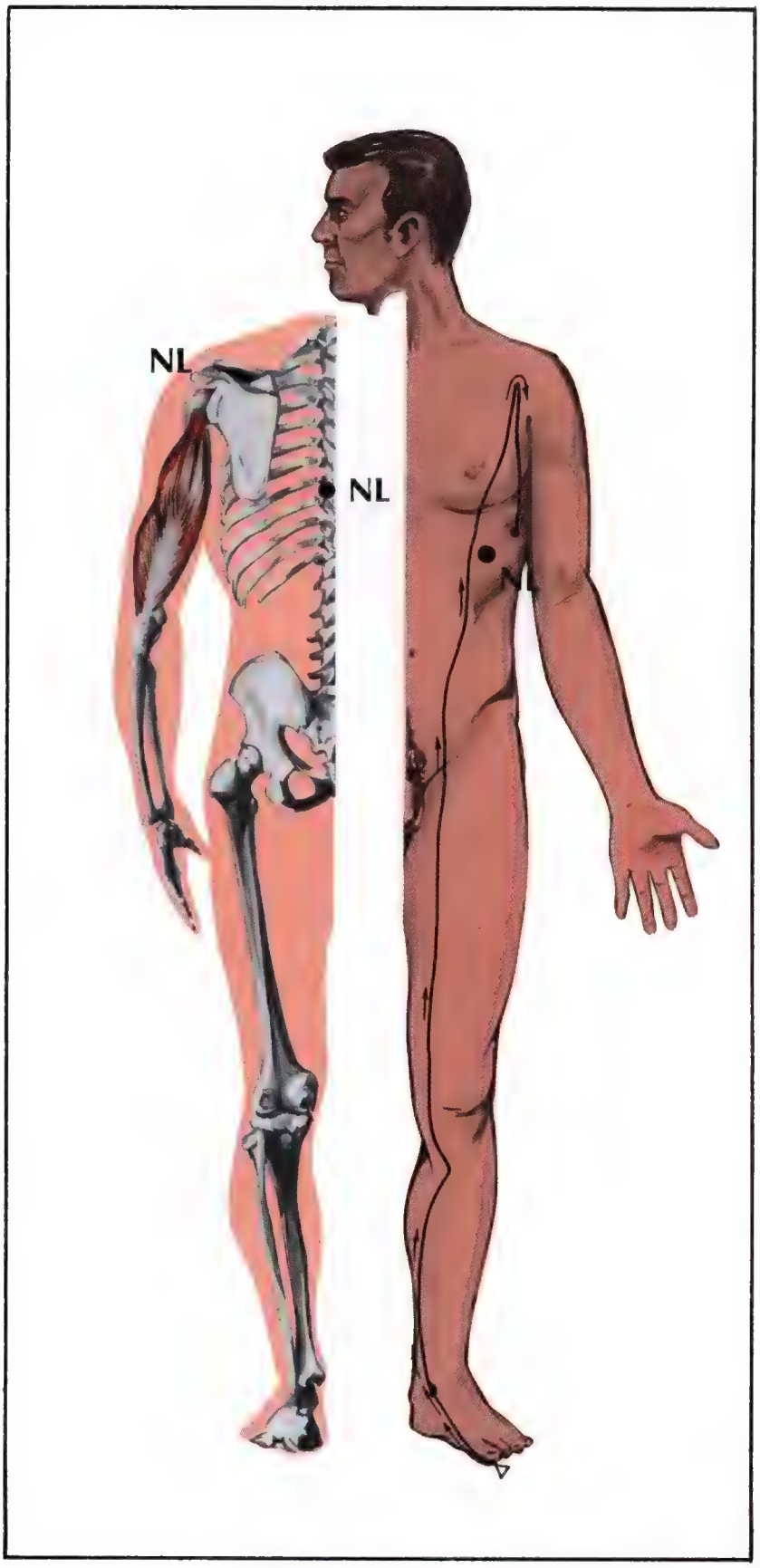

# CHAPTER V

# ORTHOPEDIC TESTS

## ORTHOPEDIC EXAMINATION INTRODUCTION

For many years, Chiropractors have been employing orthopedic tests routinely in everyday practice. With the advent of Applied Chiropractic Kinesiological Diagnosis and Technique, many of the positive orthopedic tests frequently encountered are reversed following the first Chiropractic kinesiological treatment. This reversal is so frequent that many Chiropractors now only employ standard orthopedic tests for the benefit of industrial commissions or attorneys requesting narrative reports.

This is not to say that all orthopedic procedures are invalid, nor is this suggesting every orthopedic test is reversed following kinesiological treatment. It does indicate that routine orthopedic examination is now warranted on the initial examination due to the frequency of reversibility. However, these tests may be desirable on subsequent examination if the patient fails to respond.

For the above-mentioned reasons, orthopedic tests are included in this textbook in detail. They are presented with a written and pictorial description explaining how to perform each test. If the test is positive, a continuum is given listing other related tests which one may perform. The rationale is provided where possible, in addition to a list of the most frequent conditions responsbile for the positive findings.

# ORTHOPEDIC TESTS

| TEST | PROCEDURE | POSITIVE INDICATES | RELATED TESTS |
|---|---|---|---|
| **ADAM'S POSITION** STANDING POSITION | If the examiner notes an "S" or a "C" scoliosis, the patient is asked to flex forward and touch his toes slowly. If the scoliosis straightens, the test is normal and the patient is considered to have a functional scoliosis. If the scoliosis stays the same, the test is positive and indicates a pathological scoliosis. | Altered morphology, pathology, trauma, subluxation. | Soto-Hall, Kemp's. |
| **LEWIN'S SIGN** STANDING POSITION | The examiner palpates all areas of the patient's spine for fixations as the patient attempts to touch his fingers to his toes. The examiner then measures the distance from the patient's fingers to the floor. | Areas of fixation, restricted motion. | Further examination would be based upon fixation. |
| **LEWIN'S TEST** STANDING POSITION | Have the patient straighten his knees one at a time. This test is positive if pain occurs or the knee snaps back into a relaxed position. | Disc lesion, lumbo-sacral or sacroiliac lesion, gluteal disturbance. | Trendelenburg's, Lasègue's, Kemp's, Braggard's, Fabere-Patrick's. |
| **TOE-TO-MOUTH TEST** STANDING POSITION | The patient is standing and raises one leg (with the use of his hands) and touches his toe to his mouth. This is then repeated on the opposite side. This test is positive if pain is produced in the sacroiliac or iliolumbar spine on the same side as the leg being raised. | Sacroiliac lesion, iliolumbar lesion, restricted range of motion. | Trendelenburg's, Nachlas'. |

| TEST | PROCEDURE | POSITIVE INDICATES | RELATED TESTS |
|---|---|---|---|
| **TRENDELENBURG'S TEST** STANDING POSITION | Have the patient flex the leg at the knee and raise the knee to the level of the hip. If the right hip is suspected, the patient would flex the left knee, and if the left iliac crest raises, the test is normal. However, if the iliac crest lowers, the test would be positive. | Subluxation, coxa vara, epiphyseal separation, Legg-Calve-Perthes disease, congenital dislocation, muscular dystrophy, fracture, polio. | Lasègue's, Braggard's, Bilateral Leg Lowering, Gaenslen's, Hibb's, Fabere-Patrick's. |
| **KEMP'S SIGN OR TEST** 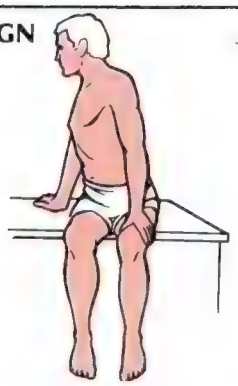 STANDING OR SEATED POSITION | Have the patient bend obliquely backward. If pain radiates down the side which the patient is bending, the test is positive. | Subluxation, sciatica, disc involvement, exostoses, tumors, degenerative joint disease. | Lasègue's, Braggards, Fajersztajn's, Naffziger's. |
| **HEEL-AND-TOE STANDING TEST** STANDING POSITION | The patient is instructed to stand on his heels and take several steps forward, turn around and return on his toes. This test is positive if the patient is unable to perform this test unilaterally or bilaterally. | Subluxation, sciatica, femoral nerve involvement, popliteal nerve injury, anterior horn spinal cord disorders and/or tumors, leg muscle weakness. | Lasègue's, Kemp's, Braggard's, Fajersztajn's. |
| **STANDING SIGN-OF-FOUR** STANDING POSITION | The patient is asked to place the heel of one foot to the shin of the opposite leg. This test is positive if the patient is unable to perform this function. | Cerebellar lesion, vertebral subluxation, sacroiliac lesion. | Finger-to-Nose, Finger-to-Finger, Bechterew's. |

| TEST | PROCEDURE | POSITIVE INDICATES | RELATED TESTS |
|---|---|---|---|
| **CHEST EXPANSION** SEATED POSITION | Chest measurements are taken after the patient inhales and again after exhalation. A positive test would be less than 1" differential. | Spinal ankylosis. | Orthopedic Range of Motion, Spirometer. |
| **MINOR'S SIGN** SEATED POSITION | Minor's sign is often observed in patients with low back conditions. The patient supports his weight on the uninvolved side by placing one hand on the healthy leg and one hand on his back as he rises from a seated position. | Sciatica, sacroiliac lesions, lumbo-sacral lesions, disc syndromes. | Naffziger's, Lasègue's, Goldthwait's, Braggard's, Spinous Percussion. |
| **GOWERS' SIGN** 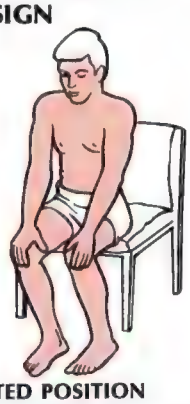 SEATED POSITION | The patient uses hands on the thighs to push his trunk to an erect position when arising from a seated position. | Lumbo-sacral lesion, sacroiliac lesion, fracture, disc syndrome. | Naffziger's, Lasègue's, Goldthwait's, Braggard's, Spinous Percussion. |
| **STRAIGHT LEG SITTING OR BECHTEREW'S TEST** SEATED POSITION | The patient is asked to extend one leg at a time and then both legs. This test is positive if pain occurs or increases in the lumbo-sacral area. | Sciatica, disc lesion, exostosis, adhesions, spasm, subluxation. | Lasègue's, Goldthwait's Gaenslen's, Fabere-Patrick's. |

| TEST | PROCEDURE | POSITIVE INDICATES | RELATED TESTS |
|---|---|---|---|
| **MILL'S TEST** SEATED OR STANDING POSITION | The patient is instructed to flex the forearm, making a complete fist and flexing the wrist. Then, the patient is asked to pronate the forearm and extend the forearm. The test is positive if elbow pain is increased. | Radiohumeral epicondylitis (tennis elbow). | Carpal Tunnel Test, Kinesiological Exam. |
| **SOTO-HALL TEST** 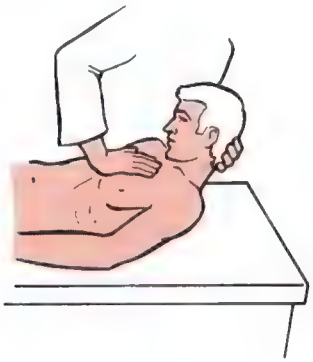 SUPINE POSITION | The examiner places his superior hand under the patient's occiput and the opposite hand on the patient's sternum. Then, the examiner lifts the patient's head to the patient's sternum while pressing down on the sternum. This puts a progressive pull on the posterior spinous ligaments. When the spinous process of the injured vertebra is reached, the patient should experience an acute pain over the injured area. | Subluxation, exostosis, disc lesion, lumbar sprain/strain, vertebral fracture. | Because of the multiplicity of areas in which a positive finding may be noted, it is impossible to recommend any specific confirmatory tests. The examiner should perform confirmatory tests based upon the area of positive finding. |
| **LASÈGUE'S TEST** 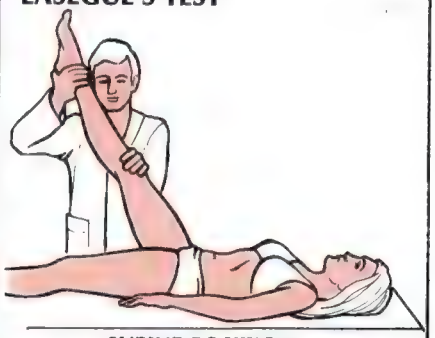 SUPINE POSITION | The examiner places his hand under the patient's heel and the other hand is placed on the patient's knee with the limb extended. The examiner then slowly brings the leg toward the abdomen. This test may be considered positive if the maneuver is markedly limited due to pain. | Sciatica from lumbo-sacral or sacroiliac lesions, subluxation syndrome, disc lesions, intervertebral foramen occlusions, adhesions. | Braggard's, Fajersztajn's. |
| **GOLDTHWAIT'S TEST** 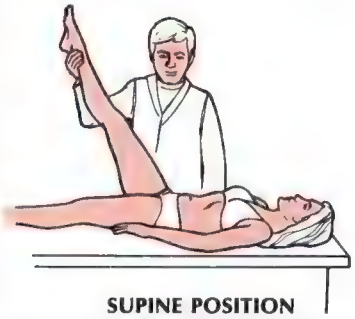 SUPINE POSITION | The examiner places one hand under the patient's lower lumbar spine. The patient then raises the leg on the involved side toward the abdomen without allowing the knee to flex. This test is positive if pain occurs before the spine begins to move. | Lumbo-sacral lesion, sacroiliac lesion, disc involvement, arthritis, subluxation. | Lasègue's, Braggard's, Bilateral Leg Lowering. |

| TEST | PROCEDURE | POSITIVE INDICATES | RELATED TESTS |
|---|---|---|---|
| **BRAGGARD'S TEST OR FAJERSZTAJN'S TEST** 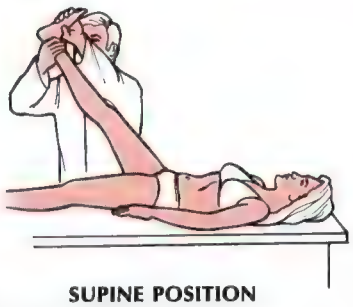 SUPINE POSITION | This test is a continuation of Lasègue's Test. After pain is produced, the examiner lowers the affected leg to a point that will ease the pain and then dorsiflexes the affected foot. The test is positive if pain returns. | Sciatica, spinal nerve root irritation, cord tumors, disc herniations or disc lesions. | Lasègue's, Fajersztajn's, Goldthwait's, Bilateral Leg Lowering. |
| **BILATERAL LEG LOWERING** 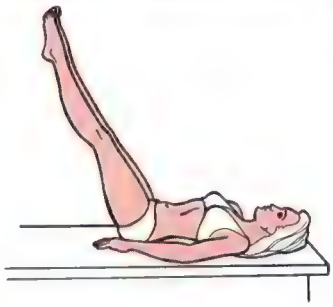 SUPINE POSITION | The patient lowers straight legs from a 90 degree angle to a 45 degree angle. This test is positive if the legs drop or pain is produced. | Lumbo-sacral involvement, disc lesion, exostosis. | Goldthwait's, Lasègue's, Braggard's. |
| **FABERE-PATRICK'S TEST** 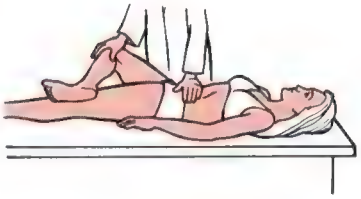 SUPINE POSITION | The examiner grasps the ankle and bends the knee. He then flexes the thigh, abducts and externally rotates the thigh (placing the external malleolus over the opposite knee) and presses downward on the superior knee. The examiner then removes the external malleolus and extends the leg. This test is positive if the patient is unable to perform these motions or pain occurs. | Hip joint lesion, sacroiliac lesion, coxa pathology. | Trendelenburg's, Standing Sign-of-Four, Nachlas', Range of Motion examination performed on the area of orthopedic limitation. |
| **THOMAS' SIGN** SUPINE POSITION | The thigh is flexed and bent upon the abdomen. The patient's lumbar spine should normally flatten. However, if it maintains its normal lordotic curve, the test is positive. | Hip contracture, shortened iliopsoas. | Trendelenburg's, Fabere-Patrick's. |

| TEST | PROCEDURE | POSITIVE INDICATES | RELATED TESTS |
|---|---|---|---|
| **GAENSLEN'S TEST** SUPINE POSITION | The patient is placed well to the side of the table with one leg flexed upon the abdomen. The opposite leg is laying partially off the table. The examiner then places pressure upon the flexed leg and slowly hyperextends the opposite thigh. Repeat on opposite side. This test is positive if pain occurs in the sacroiliac area. | Sacroiliac lesion. | Lasègue's, Goldthwait's, Toe-to-Mouth, Nachlas'. |
| **KERNIG'S SIGN** SUPINE POSITION | The patient elevates the leg to a 90 degree angle. If the patient cannot completely extend his leg, the test is positive. | Meningitis, dural adhesions, disc lesion, restricted range of motion. | Lasègue's, Braggard's, Fajersztajn's. |
| **RUST'S SYNDROME** 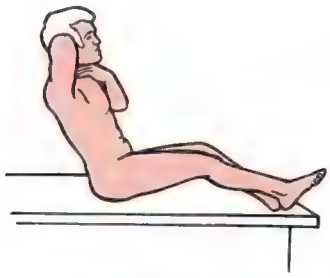 SUPINE POSITION | The patient grasps the head with both hands when lying down or arising from a recumbent position as a result of a stiff neck. | Severe whiplash, rheumatism, arthritis, fracture, cervical subluxation. | Foramina Compression, Adson's. |
| **NACHLAS' TEST** 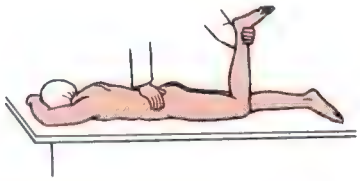 PRONE POSITION | The examiner flexes the knee on the side of the involvement. This test is positive if pain radiates to either the lumbo-sacral or sacroiliac area. | Lumbo-sacral or sacroiliac lesion. | Fabere-Patrick's, Goldthwait's, Braggard's, Lasègue's. |

| TEST | PROCEDURE | POSITIVE INDICATES | RELATED TESTS |
|---|---|---|---|
| **ELY'S TEST (Heel to Buttocks)** PRONE POSITION | The examiner flexes each leg separately, touching the heel to the buttocks. This test is positive if the patient is unable to complete flexion or if the hip raises off the table on the side being tested. | Lumbo-sacral spine lesion, hip lesion. | Fabere-Patrick's, Goldthwait's, Bilateral Leg Lowering, Lasègue's. |
| **YEOMAN'S TEST** 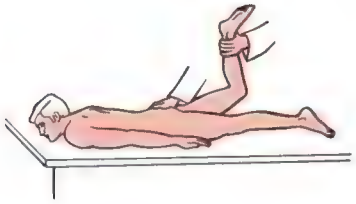 PRONE POSITION | With one hand, the examiner stabilizes the suspected sacroiliac joint. With the other hand, the examiner lifts the patient's leg on the affected side to the limit and then hyperextends the thigh. This test is positive if pain occurs in the sacroiliac area. | Sacroiliac lesion. | Lasègue's, Goldthwait's, Toe-to-Mouth, Nachlas'. |
| **HIBB'S TEST** 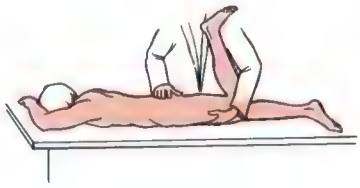 PRONE POSITION | The examiner extends the patient's thigh on the affected side and rotates the hip joint internally by rotating the leg outward. Increased pain is considered a positive sign. | Sacroiliac lesion. | Lasègue's, Goldthwait's, Nachlas'. |
| **SPINOUS PERCUSSION TEST** 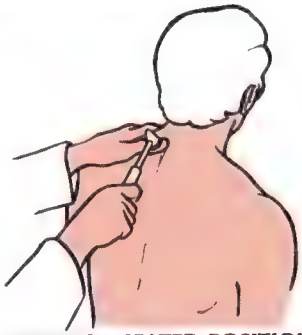 PRONE OR SEATED POSITION | The examiner uses a reflex hammer with his thumb over the spinous process in question and percusses it. A tuning fork (128-C) may also be used. A positive finding would result in pain or aggravation of the symptoms. | Fracture, osseous pathology, intervertebral disc syndrome, acute subluxation. | Segmental neurological diagnosis, kinesiological examination, Naffziger's, Foramina Compression, Bilateral Leg Lowering. |

| TEST | PROCEDURE | POSITIVE INDICATES | RELATED TESTS |
|---|---|---|---|
| **MENNELL'S SIGN** 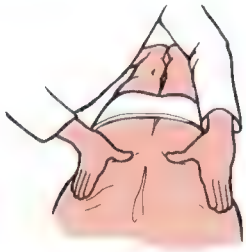 PRONE POSITION | The examiner places his thumbs over the posterior superior spine of the sacrum and exerts pressure. He then slides his thumbs outward and then inward. If tenderness is increased, this test is positive. Tenderness when sliding outward is significant because it probably indicates calcium deposits. If tenderness is noted on inward movement, it is probably due to strain of the sacroiliac ligaments. | Deposits in the structure or adjacent structure, sacroiliac joint involvement, ligamentous strain/sprain. | Bilateral Leg Lowering, Goldthwait's, Lasègue's. |
| **OBER'S TEST** 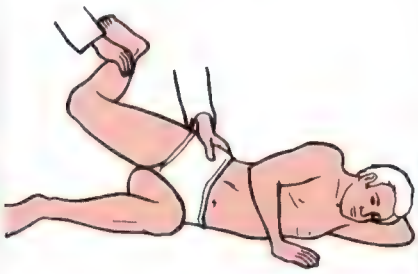 SIDE POSITION | The patient is placed with the unaffected side next to the table. The examiner places one hand on the pelvis and grasps the patient's ankle lightly with the other hand, holding the knee flexed at a right angle. The thigh is abducted and extended laterally. This test is positive if the leg remains abducted. | Contracted tensor fascia lata. | Trendelenburg's, Fabere-Patrick's, Tensor Fascia Lata Muscle Test. |
| **COMPRESSION PELVIC TEST** 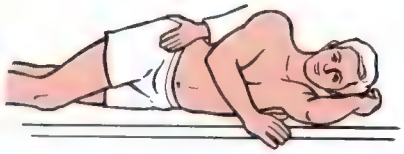 SIDE POSITION | The patient lies on his side with the affected side up. The examiner places his forearm over the iliac crest and presses downward for approximately 30 seconds. This test is positive if pain occurs. | Sacroiliac strain/sprain or inflammation. | Lasègue's, Goldthwait's Toe-to-Mouth, Nachlas'. |
| **WELL-LEG-RAISING TEST** 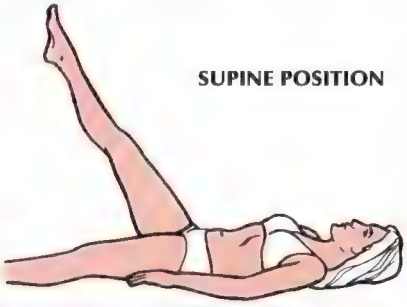 SUPINE POSITION | The patient is in a supine position. The test is performed by elevating and extending the unaffected leg. The test is positive if there is a reproduction of pain in the affected leg. | Sciatica, nerve root lesions, disc herniations or disc lesions. | Lasègue's, Braggard's, Kernig's, Kemp's. |

# ORTHOPEDIC TESTS — NEUROVASCULAR SECTION

| TEST | PROCEDURE | POSITIVE INDICATES | RELATED TESTS |
|---|---|---|---|
| **FORAMINA COMPRESSION TEST** SEATED POSITION | The examiner forcibly presses downward and laterally on the patient's head. The test is positive if it initiates or increases radiating pain in the arm. | Cervical subluxation, disc involvement, exostosis, cervical rib. | Adson's, hyperabduction, costoclavicular, neurological evaluation, lab tests. |
| **JACKSON'S MANEUVER** SEATED POSITION | Have the patient sit erect and bend the head obliquely backward, slightly toward the involved side. The examiner then applies a downward pressure on the vertex of the skull. A positive sign occurs if pain radiates down the arm. | Subluxation, neurovascular compression syndrome, disc involvement, exostosis, possible cervical rib. | Adson's, hyperabduction, costoclavicular, Allen's, Wright's, shoulder depression. |
| **ADSON'S MANEUVER** (Scalenus Anticus Syndrome) SEATED POSITION | The examiner palpates the radial pulse and directs the patient to rotate the head toward the affected side and bend the head backward and obliquely. The patient is then asked to take a deep breath and hold it for 20 seconds. The test is positive if marked weakening, loss of pulse, or an increased paresthesia takes place. | Cervical subluxation, scalenus anticus syndrome, spasm of the scalenus muscles, cervical rib, compression of the brachial plexus, subclavian artery compression. | Deep and superficial reflexes, shoulder depression, measurement of upper extremities, hyperabduction, costoclavicular. |
| **HYPERABDUCTION TEST** SEATED POSITION | This test may be performed in conjunction with the Adson's Maneuver. Have the patient raise his arms to a 45 degree angle and then take the pulse. The test is positive if the pulse becomes weak or diminishes. | Subluxation, neurovascular compression syndrome, hyperabduction syndrome. | Costoclavicular, Allen's, Wright's, shoulder depression, Adson's. |

| TEST | PROCEDURE | POSITIVE INDICATES | RELATED TESTS |
|---|---|---|---|
| **COSTOCLAVICULAR TEST** 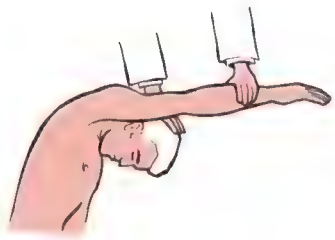 SEATED OR STANDING POSITION | This test may be performed in conjunction with the hyperabduction test. Have the patient bend his head forward and hold his chin as close as he can to his chest, placing tension on the neck muscles. The arms should be extended above the head. Then, check both extremities to see if the pulse has been altered. The test is positive if there is a weakening, alteration or stopping of the pulse. | Cervical subluxation, scalenus anticus syndrome, compression of the brachial plexus, clavicular subluxation. | Hyperabduction, shoulder depression, Allen's, Wright's. |
| **ALLEN'S TEST** 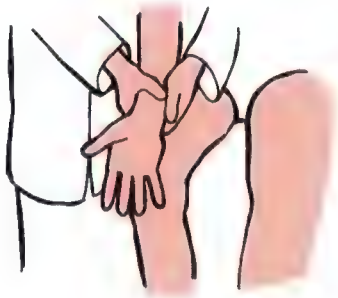 SEATED OR STANDING POSITION | The patient elevates the arm and clenches his fist to shunt blood from the palm, after which the doctor occludes the radial and ulnar arteries. Then, the doctor lowers the arm and instructs the patient to open his hand. The doctor then releases the pressure off the arteries. Normally, the skin of the palm should flush within three seconds. This test is positive if the skin does not flush entirely or partially within the given period of time. | Subluxation, vascular occlusion of the ulnar or radial arteries. | Wright's, shoulder depression, Adson's. |
| **WRIGHT'S TEST** 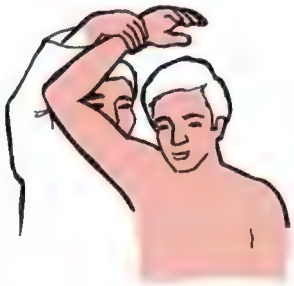 SEATED OR STANDING POSITION | The doctor palpates the radial pulse beginning from a downward position and moving the arm through the normal range of motion of the shoulder (180 degree arc). This test is positive if the pulse diminishes or disappears, if there is a marked accentuation of pain, or if paresthesia occurs anytime during the range of motion. | Hyperabduction syndrome, subluxation, neurovascular compression syndrome. | Allen's, shoulder depression, Adson's. |

| TEST | PROCEDURE | POSITIVE INDICATES | RELATED TESTS |
|---|---|---|---|
| **SHOULDER DEPRESSION TEST** SEATED POSITION | The examiner first depresses the patient's shoulder on the affected side, then laterally extends the cervical spine away from that shoulder. This test is positive if pain is produced or aggravated. | Dural adhesions, nerve root irritation, inflammatory process of the shoulder joint. | Eden's, costoclavicular, Adson's, Allen's, Wright's. |
| **EDEN'S TEST** SEATED POSITION | This test is a modified shoulder depression test. The examiner palpates the radial pulse. The patient is requested to take a deep breath and hold it, while pulling his shoulders backward and throwing his chest outward. The test is positive if a weakening or loss of pulse occurs, or pain increases. | Compression of the neurovascular bundle as it presses between the clavicle and first rib. | Shoulder depression, Wright's, Allen's, Adson's. |

# ORTHOPEDIC TESTS — MALINGERING TESTS

| TEST | PROCEDURE |
|---|---|
| **LIBMAN'S TEST** SEATED POSITION | The examiner presses superior to the inferior tip of the mastoid. This determines the patient's pain threshold. If the patient is unable to tolerate this pressure (which should be gradually increased), the examiner is then able to determine the pain threshold of the patient. |
| **HOOVER'S SIGN** 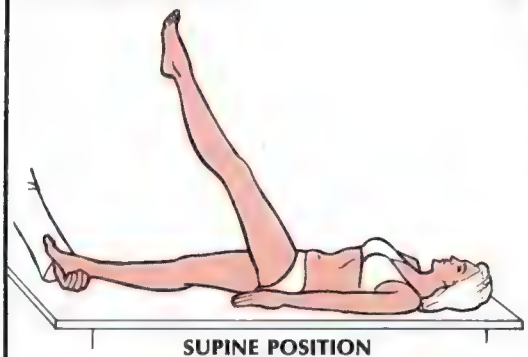 SUPINE POSITION | Before performing the Hoover's Sign, ask the patient to lift the unaffected leg or hip while the examiner places his hand under the heel on the affected side. This will establish in the examiner's mind the amount of pressure the patient normally unconsciously exerts against the examining table. The patient is then asked to lift the affected leg or hip while the examiner places his hand under the heel on the unaffected side. In malingering, the pressure the heel exerts upon the examining table will be the same or less than that felt by the examiner on the unaffected side. |
| **BURN'S TEST** 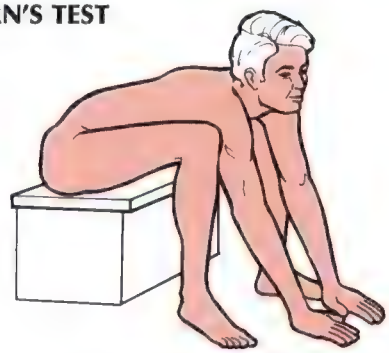 SEATED POSITION | The patient is asked to sit on a low chair or a low stool and to bend forward and touch the floor with the palms of his hands. If the patient says he cannot do this because of low back pain, you may suspect malingering, as flexion in this particular case would not affect the low back specifically. The motion comes primarily from the acetabular cavities. |
| **FLIP TEST** 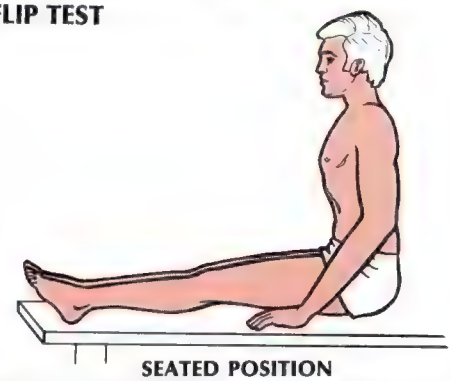 SEATED POSITION | Have the patient sit on the examination table with his back straight and his legs extended on the table. If the patient is suffering from a sciatic nerve involvement, he cannot do this. The patient will have to lift the leg and bend the back to take the pressure off the sciatic nerve. If the patient can perform this task but complains of sciatic pain, then suspect malingering. |

| TEST | PROCEDURE |
|---|---|
| **PLANTAR FLEXION TEST** 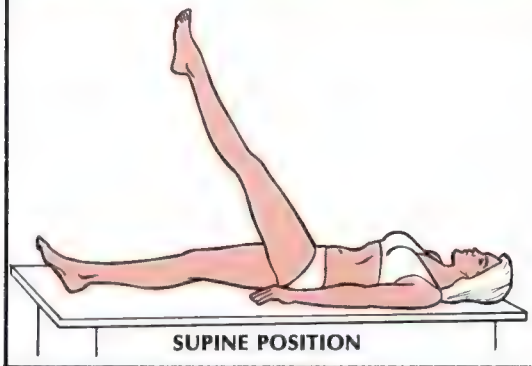 SUPINE POSITION | The patient is asked to raise his legs one at a time to the point where pain is initiated. The doctor notes the degree where pain is supposedly incurred. The patient is then asked to lower the leg. The doctor places one hand under the patient's knee, one hand at the bottom of the patient's foot and raises the leg approximately one-half of the distance to where the original pain was felt. Then, the doctor dorsiflexes the foot. If the patient says it causes pain, suspect malingering. |
| **SEATED FORWARD BEND TEST** 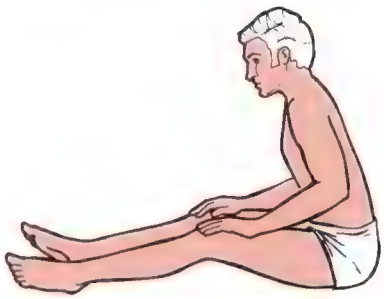 SEATED POSITION | This test is primarily for patients who complain of a stiff lower back. The patient is asked to sit on the examination table with his legs spread apart, and his hands just above his knees. He is then asked to lower himself forward. If the patient says he cannot perform this test because of pain, suspect malingering. |
| **FLEXED HIP TEST** 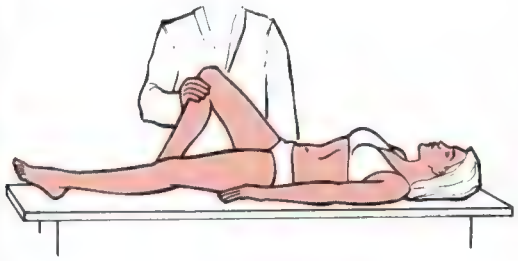 SUPINE POSITION | The doctor places one hand under the patient's lumbar spine and raises the patient's knee toward the abdomen but not enough to cause lumbar movement. If the patient complains of pain before lumbar movement is felt by the examiner, suspect malingering. |

# USE OF THE GONIOMETER

Restricted ranges of motions can be calculated by the inability of the member to be moved throughout its normal arc. Naturally, in order to estimate the amount of restriction which exists, the normal range of motion must first be known.

Factors such as age, pre-existing disease, athletic prowess or natural physical makeup may decrease or increase these ranges of normal motion. On the whole, however, normal ranges of motion may be expressed in accordance with the illustrations in this chapter.

The goniometer is an instrument used for measuring these ranges of motion. As the joint is moved through its arc, from its neutral position to maximum flexion or extension, the degree of motion is measured by the distance covered by the goniometer arm. For example, if a member is in its neutral position which registers 180° on the goniometer and is moved to maximum flexion where it registers 110°, the arc of motion would be determined by subtracting 110° from 180°. In other words, the arc of motion would be 70°. (See FIG. O-1.)

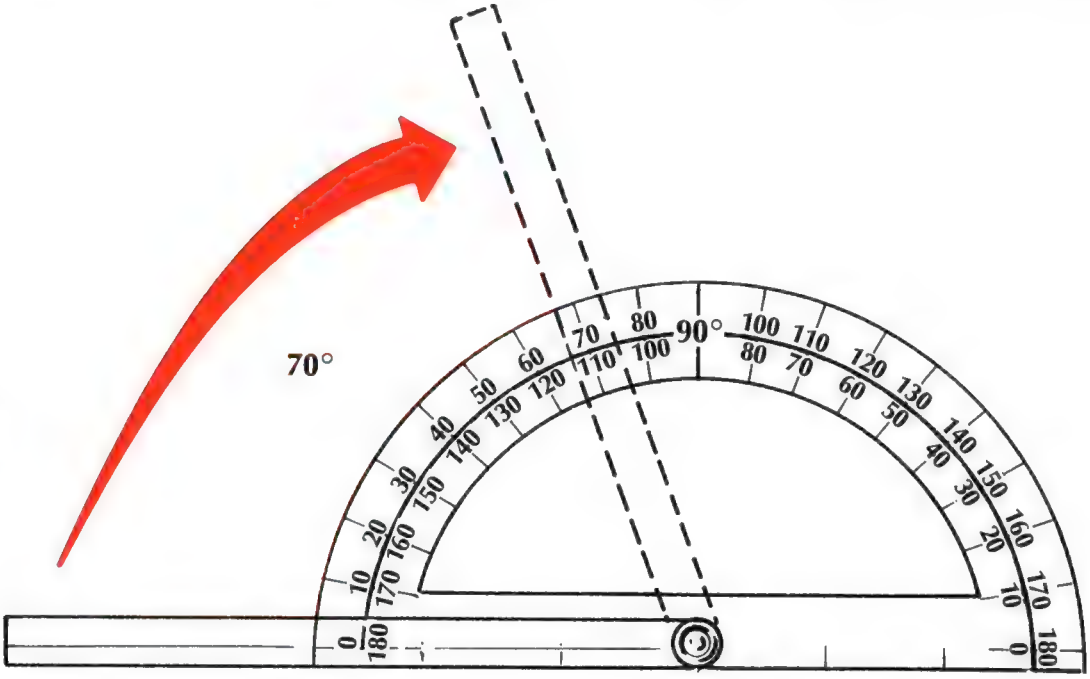


**(FIG. O-1)**

Because the goniometer has a 90° center, instead of 0°, the reading obtained on the goniometer must be converted into degrees of arc of motion. The following table provides those conversions utilized when the goniometer arm begins at 90°:

| GONIOMETER READING | ARC OF MOTION | GONIOMETER READING | ARC OF MOTION |
|---|---|---|---|
| 90 | 0° | 90 | 0° |
| 100/80 | 10° | 80/100 | 10° |
| 110/70 | 20° | 70/110 | 20° |
| 120/60 | 30° | 60/120 | 30° |
| 130/50 | 40° | 50/130 | 40° |
| 140/40 | 50° | 40/140 | 50° |
| 150/30 | 60° | 30/150 | 60° |
| 160/20 | 70° | 20/160 | 70° |
| 170/10 | 80° | 10/170 | 80° |
| 180/0 | 90° | 0/180 | 90° |

# ORTHOPEDIC RANGES OF MOTION

| TEST | DESCRIPTION |
|---|---|
| **CERVICAL FLEXION & EXTENSION**<br> 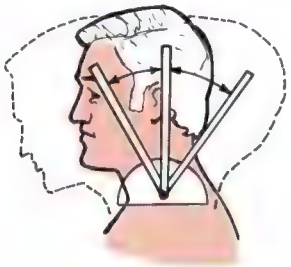 <br>**30° - 0° - 30°**<br>NORMAL RANGE OF MOTION | The patient should be seated in a neutral position with the arms at the sides. Place the goniometer at the side of the neck in line with the superior border of the larynx (C-5). Place the goniometer arm in line with the mastoid process. Ask the patient to bend the neck forward and backward as far as possible while following the arc of motion with the goniometer arm. Record flexion and extension. |
| **CERVICAL RIGHT & LEFT LATERAL FLEXION**<br> 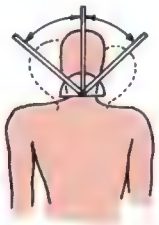 <br>**40° - 0° - 40°**<br>NORMAL RANGE OF MOTION | The patient should be seated in a neutral position. Center the goniometer at the back of the neck in line with the occipital protuberance. Place the goniometer arm along the center of the back of the head. Ask the patient to bend the neck to the right and left as far as possible while following the arc of motion with the goniometer arm. Record right and left lateral flexion. |
| **CERVICAL RIGHT & LEFT ROTATION**<br> 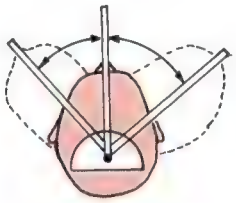 <br>**30° - 0° - 30°**<br>NORMAL RANGE OF MOTION | The patient should be seated in a neutral position. Center the goniometer on the top of the head, with the goniometer arm extended above the center of the bridge of the nose. Ask the patient to turn the head to the right and left as far as possible while following the arc of motion with the goniometer arm. Record cervical right and left rotation. |
| **DORSOLUMBAR FLEXION & EXTENSION**<br> 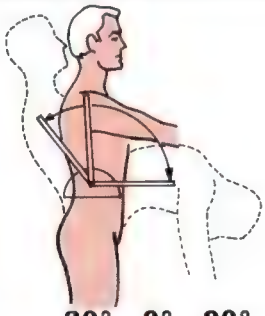 <br>**30° - 0° - 90°**<br>NORMAL RANGE OF MOTION | The patient should be standing in a neutral position with the arms flexed (forward extended). Place the goniometer at the patient's side at the level of the lowest rib with the goniometer arm along the mid-axillary line. Ask the patient to bend forward and backward as far as possible while following the arc of motion with the goniometer arm. Record dorsolumbar flexion and extension. |

| TEST | DESCRIPTION |
|---|---|
| **DORSOLUMBAR RIGHT & LEFT LATERAL FLEXION**<br> 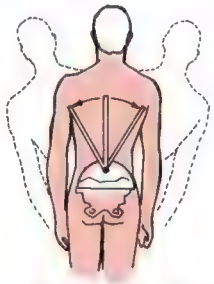 <br>**20° - 0° - 20°**<br>NORMAL RANGE OF MOTION | The patient should be standing in a neutral position. Place the goniometer on the back of the patient over the posterior superior iliac spines with the goniometer arm along the midline of the back. Ask the patient to bend the trunk to the right and left as far as possible while following the arc of motion with the goniometer arm. Record right and left lateral flexion. |
| **DORSOLUMBAR RIGHT & LEFT ROTATION**<br> 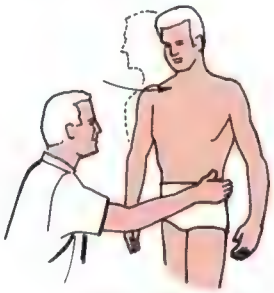 <br>**30° - 0° - 30°**<br>NORMAL RANGE OF MOTION | The patient should be standing in a neutral position. The examiner should be seated facing the patient with his hands on both sides of the patient's pelvis for stabilization. Ask the patient to twist the trunk to the right and left as far as possible while the examiner "estimates" the arc of motion. Record dorsolumbar right and left rotation. |
| **ELBOW FLEXION**<br> 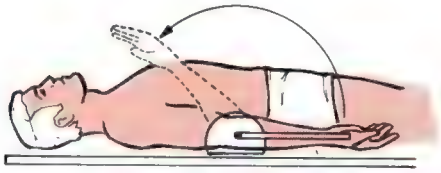 <br>**150°**<br>NORMAL RANGE OF MOTION | Patient may be in a seated, standing or supine position. Ask the patient to extend the arm as far as possible. Center the goniometer next to the elbow joint. Place the goniometer arm along the axis of the forearm. Ask the patient to flex the arm as far as possible while following the arc of motion with the goniometer arm. Record flexion. |
| **ELBOW EXTENSION**<br> 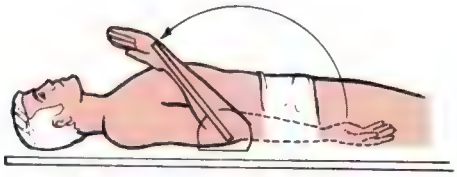 <br>**150°**<br>NORMAL RANGE OF MOTION | Patient may be in a seated, standing or supine position. Ask the patient to flex the arm as far as possible. Center the goniometer next to the elbow joint and place the goniometer arm along the axis of the forearm. Ask the patient to extend the arm as far as possible while following the arc of motion with the goniometer arm. Record extension. |

| TEST | DESCRIPTION |
|---|---|
| **FOREARM SUPINATION**<br> <br>**90°**<br>NORMAL RANGE OF MOTION | Patient may be in a seated or standing position. Ask the patient to place the arm at his side and flex the elbow to 90° with the forearm in a neutral position. The examiner should stabilize the upper arm. The patient is requested to supinate the forearm as far as possible. Estimate degree of arc of motion. |
| **FOREARM PRONATION**<br> 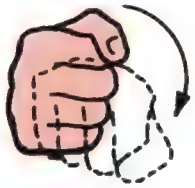 <br>**90°**<br>NORMAL RANGE OF MOTION | Patient may be in a seated or standing position. Ask the patient to place the arm at his side and flex the elbow to 90° with the forearm in a neutral position. The examiner should stabilize the upper arm. The patient is requested to pronate the forearm as far as possible. Estimate degree of arc of motion. |
| **WRIST FLEXION**<br> 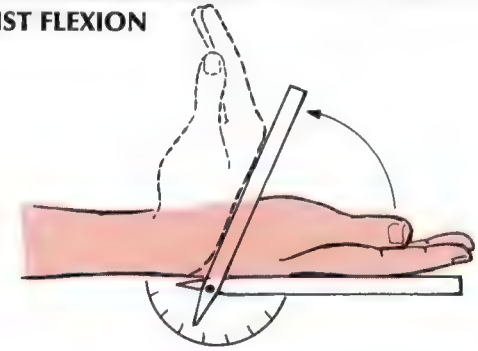 <br>**90°**<br>NORMAL RANGE OF MOTION | Patient may be seated or standing. Ask the patient to extend the arm in front of him. Center the goniometer over the wrist joint with the goniometer arm along the axis of the dorsum of the third metacarpal bone. Ask the patient to flex the wrist as far as possible while following the arc of motion with the goniometer arm. Record wrist flexion. |
| **WRIST EXTENSION**<br> 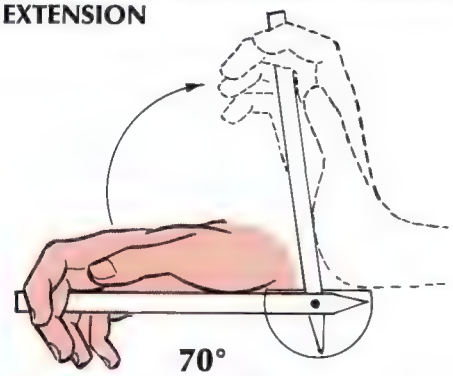 <br>**70°**<br>NORMAL RANGE OF MOTION | Patient may be seated or standing. Ask the patient to extend the arm in front of him. Center the goniometer over the palmar surface of the wrist joint with the goniometer arm along the center of the palm, extending between the middle and ring fingers. Ask the patient to extend the wrist as far as possible while following the arc of motion with the goniometer arm. Record wrist extension. |

| TEST | DESCRIPTION |
|---|---|
| **WRIST RADIAL DEVIATION**<br> 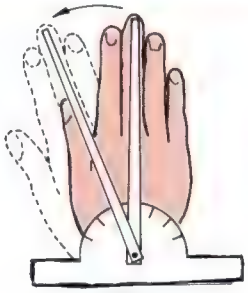 <br>**20°**<br>NORMAL RANGE OF MOTION | Patient may be seated, standing or supine. Center goniometer over the wrist joint with the goniometer arm lying directly over the third metacarpal bone. Starting from a neutral position, ask the patient to radial deviate the wrist as far as possible while following the arc of motion with the goniometer arm. Record radial deviation. |
| **WRIST ULNAR DEVIATION**<br> 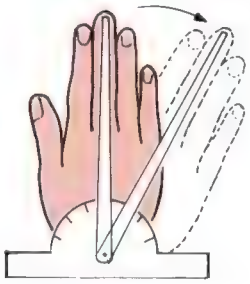 <br>**30°**<br>NORMAL RANGE OF MOTION | Patient may be seated, standing or supine. Center goniometer over the wrist joint with the goniometer arm lying directly over the third metacarpal bone. Starting from a neutral position, ask the patient to ulnar deviate the wrist as far as possible while following the arc of motion with the goniometer arm. Record ulnar deviation. |
| **HIP FLEXION**<br> 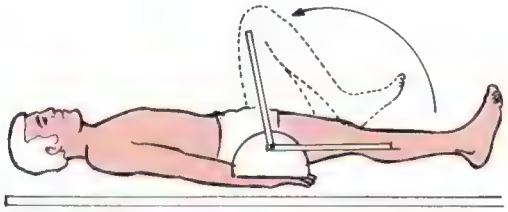 <br>**110°**<br>NORMAL RANGE OF MOTION | Patient is in a supine position with both legs extended. Place the goniometer next to the hip joint with the goniometer arm parallel to the axis of the femur. Ask the patient to flex the thigh as far as possible with the knee bent while following the arc of motion with the goniometer arm. Record flexion. |
| **HIP BACKWARD EXTENSION**<br> 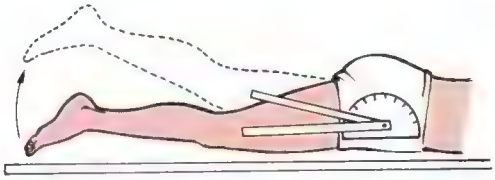 <br>**30°**<br>NORMAL RANGE OF MOTION | Patient is in the prone position with both legs extended. Center the goniometer next to the hip joint with the goniometer arm parallel to the axis of the femur. Ask the patient to raise the leg as far as possible while following the range of motion with the goniometer arm. Record backward extension. |

| TEST | DESCRIPTION |
|---|---|
| **HIP ABDUCTION** 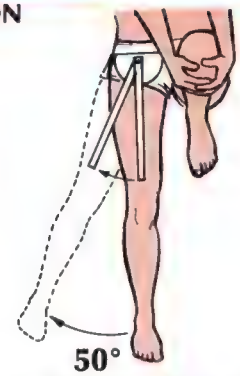 **50°** NORMAL RANGE OF MOTION | Patient is in a supine position with the hip flexed and held to lock pelvis. The leg to be tested is extended. Center the goniometer over the hip joint with the goniometer arm parallel with the axis of the femur. Ask the patient to start from a neutral position and abduct the thigh as far as possible while following the arc of motion with the goniometer arm. Record abduction. |
| **HIP ADDUCTION** **30°** NORMAL RANGE OF MOTION | Patient is in a supine position with the hip flexed and held to lock pelvis. The leg to be tested is extended. Center the goniometer over the hip joint with the goniometer arm parallel with the axis of the femur. Ask the patient to start from a neutral position and adduct the thigh as far as possible while following the arc of motion with the goniometer arm. Record adduction. |
| **KNEE FLEXION** 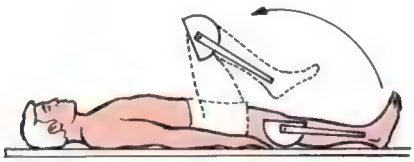 **130°** NORMAL RANGE OF MOTION | Patient is in a prone position. Center the goniometer next to the knee joint with the goniometer arm parallel to the axis of the tibia. The examiner stabilizes the pelvis and asks the patient to flex the knee as far as possible while following the arc of motion with the goniometer arm. Record flexion. |
| **KNEE EXTENSION** 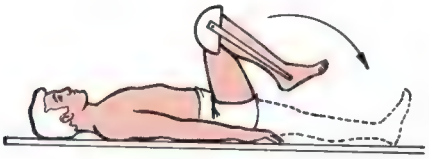 **150°** NORMAL RANGE OF MOTION | Patient is in a prone position with one knee flexed as far as possible. Center the goniometer next to the knee joint with the goniometer arm parallel to the axis of the tibia. The examiner stabilizes the pelvis and asks the patient to extend the knee as far as possible while following the arc of motion with the goniometer arm. Record extension. |

| TEST | DESCRIPTION |
|---|---|
| **ANKLE DORSIFLEXION**<br> <br>**15°**<br>NORMAL RANGE OF MOTION | The patient is in a supine position. Center goniometer over the lateral malleolus with the goniometer arm parallel to the sole of the foot. Ask the patient to dorsiflex the ankle as far as possible while following the arc of motion with the goniometer arm. Record dorsiflexion. |
| **ANKLE PLANTAR FLEXION**<br> 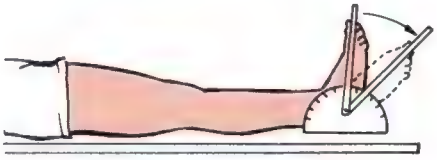 <br>**50°**<br>NORMAL RANGE OF MOTION | The patient is in a supine position. Center goniometer over the lateral malleolus with the goniometer arm parallel to the sole of the foot. Ask the patient to plantar flex the ankle as far as possible while following the arc of motion with the goniometer arm. Record plantar flexion. |
| **SHOULDER FLEXION**<br> 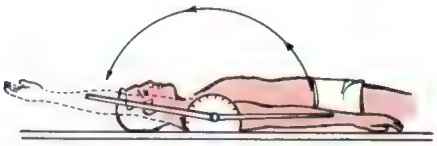 <br>**170°**<br>NORMAL RANGE OF MOTION | The patient is in a supine position with arms at rest beside the body. Center goniometer at outer side of shoulder joint with the goniometer arm along the axis of the arm. Ask the patient to elevate both arms as far as possible toward the ears while following the arc of motion with the goniometer arm. Record flexion. |
| **SHOULDER EXTENSION**<br> 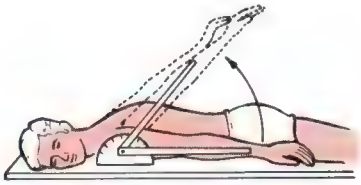 <br>**30°**<br>NORMAL RANGE OF MOTION | The patient is in a prone position. Center the goniometer next to the shoulder joint with the goniometer arm along the axis of the upper arm. Ask the patient to elevate both arms as far as possible while following the arc of motion with the goniometer arm. Record extension. |

| TEST | DESCRIPTION |
|---|---|
| **SHOULDER INTERNAL ROTATION**<br> 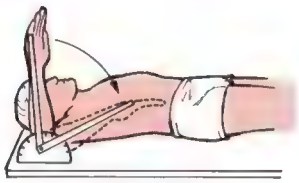 <br>**60°**<br>NORMAL RANGE OF MOTION | The patient is in a supine position with the arm laterally extended and bent at the elbow at a 90° angle. Center the goniometer next to the elbow joint with the goniometer arm parallel to the axis of the forearm. Ask the patient to touch the palmar surface of the arm to the table top while following the arc of motion with the goniometer arm. Record internal rotation. |
| **SHOULDER EXTERNAL ROTATION**<br> 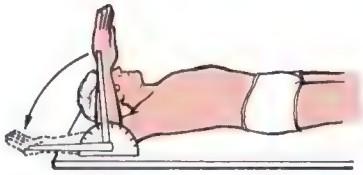 <br>**80°**<br>NORMAL RANGE OF MOTION | The patient is in a supine position with the arm laterally extended and bent at the elbow at a 90° angle. Center the goniometer next to the elbow joint with the goniometer arm parallel to the axis of the forearm. Ask the patient to touch the dorsal surface of the forearm to the table top while following the arc of motion with the goniometer arm. Record external rotation. |
| **SHOULDER ABDUCTION**<br> 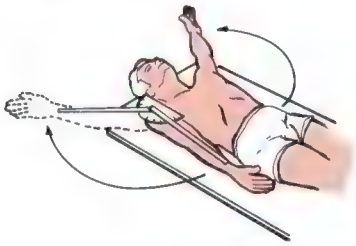 <br>**170°**<br>NORMAL RANGE OF MOTION | Patient is in a supine position. Center goniometer over the shoulder joint with the goniometer arm along the axis of the arm. Ask the patient to abduct both arms as far as possible while following the arc of motion with the goniometer arm. Record abduction. |

# CHAPTER VI

## INTRODUCTION TO NEUROLOGY

The material contained in this chapter provides the essentials of a detailed office neurological examination and other material pertinent to the patient's general neurological behavior.

Instructions for the performance of each test are presented in detail, along with pictorial explanations where appropriate. The interpretation of the neurological procedure is of equal importance, and it is presented where possible.

The order in which the examiner performs the neurological examination may be adopted directly from the text, or it may be altered according to the individual situation.

# NEUROLOGY

The neurological portion of the examination actually begins the moment the doctor meets the patient. From that moment forward, the doctor should continually note the patient's speech, posture, body movements, etc., as each may have a neurological significance.

## NEUROLOGY—GENERAL CEREBRAL FUNCTIONS

**I. GENERAL BEHAVIOR**

The examiner should note if there are any defects in the patient's behavior from either a learned or cultural aspect. Specific attention should be paid to any disarrangement of the patient's clothing, food stains on the clothing, eccentric dress, mannerisms, gestures, etc.

**II. LEVEL OF CONSCIOUSNESS**

Is the patient alert, drowsy or stuporous? Does the patient have periods of lost contact, or is the patient attentive and responsive to suggestion and ideas.

**III. MEMORY**

How is the patient's memory for past events? This is easy to judge when taking the patient's history. Immediate memory retention can be tested by noting the patient's ability to remember a series of digits, working from a shorter to longer series. For example, ask the patient to repeat a series of numbers. Then, ask the patient to repeat them backwards. Also, a patient's orientation could be tested by asking the patient to explain abstract reasoning such as, "A bird in the hand is worth two in the bush."

**IV. EMOTIONAL STATUS**

Watch for inappropriate or bizarre reactions during the examination. Note if the patient's frame of mind changes or if the patient maintains excessive tension, hostility, depression or euphoria.

**V. THOUGHT CONTENT**

While the examiner is taking the history, he should pay particular attention to undue preoccupations, inappropriate recurrent thoughts or ideas, excessive repetition of complaints, fixed ideas, illusions, delusions, hallucinations, etc. From time to time, it may be necessary for the examiner to call on the patient's relatives to provide useful information on points left out by the patient.

# SPECIFIC CEREBRAL FUNCTION

## I. CORTICAL SENSORY INTERPRETATION

Certain areas of the cerebral cortex are essential to recognition of objects by sight, sound and feeling. Agnosia is the inability to recognize objects through any of the special senses. There are four common types of agnosia: visual (occipital lobe), auditory (lateral and superior portion of the temporal lobe), tactile (parietal lobe), and body parts and relationships (posterior and inferior regions of the parietal lobe). The following tests will aid the examiner in determining the presence of any of the above agnosias:

| TEST | PROCEDURE |
|---|---|
| Visual Object Recognition | Ask the patient to identify familiar objects, such as a pen or wristwatch. |
| Sound Recognition | With the patient's eyes closed, ask him to identify familiar sounds, such as the ticking of a wristwatch. |
| Touch Recognition | With the patient's eyes closed, ask him to identify familiar objects placed in his hands, such as a comb, coin, pocketknife, or key. |
| Recognition of Body Parts | With the patient's eyes closed, determine his ability to recognize and locate his various body parts, such as his foot, hand or arm. |

## II. CORTICAL MOTOR INTEGRATIONS

Apraxia is the inability to carry out a purposeful, useful or skilled act in the absence of paralysis. Before the patient can carry out a skilled act, he must understand what is desired, he must remember the instructions until the act is performed, and he must have the normal motor strength. The following are tests which will aid the examiner in determining the presence of apraxia:

| TEST | PROCEDURE |
|---|---|
| Performance of Skilled Motor Acts | Check to see if the patient can complete motor acts such as drinking from a cup, closing a safety pin, or using common items such as a comb. |
| Visual Verbal Comprehension | Ask the patient to read a sentence from a newspaper and explain its meaning. If the patient is unable to talk, the examiner should print instructions and determine whether the patient can carry them out. |

## III. LANGUAGE

Aphasia is the deficiency or loss of the power of expression by speech, writing or signs. The most common types of aphasia are auditory receptive (temporal lobe), expressive speaking (inferior posterior frontal areas), visual receptive (parieto-occipital area), expressive writing (posterior frontal area). The following tests will aid the examiner in determining the presence of the above listed aphasias:

| TEST | PROCEDURE |
|---|---|
| Auditory-Verbal Comprehension | Determine if the patient can answer questions, carry out instructions or answer simple math questions. |
| Motor Speech | Ask the patient to imitate several different sounds and phrases: "La-La," "Me-Me," "This is a good book," etc., increasing the difficulty. Note abnormal word usage in conversation. |
| Automatic Speech | Ask the patient to repeat one or two series he has learned in the past, such as the days of the week or months of the year. |
| Volitional Speech | Determine if the patient can answer questions meaningfully. |
| Writing | Have the patient write his name and address, simple sentences, a word with his eyes closed and repeat with his eyes open, or write the name of a familiar object. |

# NEUROLOGY - CRANIAL NERVE EXAMINATION

| NERVE | DESCRIPTION OF TEST AND GENERAL INFORMATION | POSITIVE MAY INDICATE |
|---|---|---|
| I—OLFACTORY | Before the olfactory nerve is tested, the examiner should examine the nasal passages to be sure they are free from obstruction. The patient is then asked to close both eyes and occlude one nostril. The patient is asked to identify familiar odors that are enclosed in test tubes, such as cloves, camphor, wintergreen, coffee or tobacco. Any substance can be used in this examination, but the odor should be easily identifiable. | Anosmia (loss of smell) commonly occurs in cases of colds and rhinitis. Unilaterally, anosmia may indicate significant brain lesions such as tumors or lesions in the frontal lobe, congenital lesions, trauma to the head, local nasal disease, local sinus disorders (disease), intracranial tumors, basilar meningitis. |
| II—OPTIC | Before examining the optic nerve, the patient's VISUAL ACUITY should be tested with a Snellen Eye Chart. If the patient wears glasses, he should be tested with his glasses on and without them. In order to examine the OPTIC NERVE, flash a light into the patient's eye while the other eye is closed or covered. Ask the patient if the light bothers him and if he can see the light clearly with each eye. If the patient does not see the light with the same intensity in each eye, he should once again be asked to close one eye as the examiner moves a pen or cotton-tipped applicator from the periphery toward the center of vision in each visual quadrant. The patient is asked to indicate when he sees each object. This procedure will allow the examiner to check each quadrant of the eye for possible gross visual defects. More specific information relative to VISUAL FIELD determination would require the use of a perimeter or a tangent screen. | Occipital lobe lesion may result in contralateral blindness in the corresponding half of each visual field (but central vision is intact). Parietal lobe lesion may result in lower quadrant blindness of both eyes. Temporal lobe lesion may result in blindness in the upper quadrants of both visual fields on the opposite side of the lesion.<br><br>Optic nerve dysfunction may be due to disturbance along the optic pathway, including sense organs, neurons in retina fibers of the optic nerve and tract, the lateral geniculate body, and the geniculo-calcarine tract. |
| III—OCULO-MOTOR<br>IV—TROCHLEAR<br>VI—ABDUCENS | These nerves are tested as a unit because they all have similar function and similar cranial anatomical origin.<br><br>**OCULOMOTOR:** The oculomotor nerve supplies the superior rectus, medial rectus, inferior rectus, levator palpebral and inferior oblique muscles, as well as those muscles which constrict the pupil. The OCULAR MOVEMENTS are examined by asking the patient to follow the movement of the examiner's pen or finger as the examiner moves it in all directions. Involvement or lesion of the oculomotor nerve will result in the patient's inability to look in combinations of directions (up, down or | **OCULOMOTOR:**<br>Oculomotor paralysis, external and internal ophthalmoplegia, aneurysms, trauma to the head, invasive neoplastic disease of the midbrain, myasthenia gravis, syphilis. |

| NERVE | DESCRIPTION OF TEST AND GENERAL INFORMATION | POSITIVE MAY INDICATE |
|---|---|---|
| | medially). One would expect to find ptosis of the lid, dialation of the pupil or an inability to turn the affected eye upward and medially. | |
| | **TROCHLEAR:** The trochlear nerve supplies the superior oblique muscle which is responsible for downward and lateral movement of the eye. | **TROCHLEAR:** Trochlear paralysis (rare) accompanied by strabismus and diplopia, ocular torticollis, congenital lesion. |
| | **ABDUCENS:** The abducens nerve supplies the lateral rectus muscles which control lateral movement of the eye. | **ABDUCENS:** Late syphilis, basilar disease or trauma. |
| | If the TROCHLEAR NERVE or ABDUCENS NERVE is affected, one would suspect that the patient may also complain of double vision. | |
| | During the examination of the OCULOMOTOR, TROCHLEAR AND ABDUCENS NERVE, the examiner should be acutely aware of any extraocular movements or nystagmus, in addition to the size, shape and equality of the pupils. ACCOMMODATION or CILIARY REFLEX is tested by checking the pupillary constriction as the examiner moves his finger or a similar object approximately 12″ from the patient's nose directly toward the nose. PUPILLARY RESPONSE or CONSTRICTION is evaluated by hitting the pupil of the eye with a beam of light. | **OCULOMOTOR, TROCHLEAR & ABDUCENS:**<br>1) congenital lesion<br>2) infectious diseases of the midbrain<br>3) skull fractures<br>4) aneurysm of internal carotid artery<br>5) mastoiditis<br>6) increased intracranial pressure |
| **V—TRIGEMINAL** | The function of the trigeminal nerve is primarily sensory and secondarily motor. The SENSORY PORTION of the nerve supplies the entire face, cornea and tongue. Examination of the sensory portion of the trigeminal nerve should begin by the examiner checking the presence of several different types of sensations and by determining whether both sides are equally sensitive. ANESTHESIA TO LIGHT TOUCH is determined by touching the forehead, cheeks and jaws lightly with wisps of cotton. A difference in response on the opposite side of the face would indicate an increased or decreased sensitivity to light touch. The same procedure is followed when determining degrees of sensitivity to pinpricks or pinwheels and to warm and cold objects. All of these tests should be performed with the patient's eyes closed. The CORNEAL REFLEX is tested by observing if the patient feels the examiner lightly touching the cornea of the eye with a wisp of | Tic douloureux or trifacial neuralgia, neuritis, trismus (lockjaw), alcoholism, tumors in the middle fossa and in the cerebello-pontine angle. Nerve injury or lesion resulting in paralysis will cause the jaw to deviate to the same side.<br><br>**IRRITATING LESIONS:**<br>1) Tetany<br>2) Tabes<br>3) Encephalitis<br>4) Tetanus or lockjaw<br>5) Clonic spasm, occasionally seen in petit mal attacks |

| NERVE | DESCRIPTION OF TEST AND GENERAL INFORMATION | POSITIVE MAY INDICATE |
|---|---|---|
| | cotton. Avoid stroking the sclera. The MOTOR PORTION of the trigeminal nerve supplies the muscles of mastication. The motor portion of the nerve is examined in the following manner: The MASSETERS and the TEMPORAL MUSCLES are examined by palpating them when the jaws are clamped tightly together. The examiner should note whether there is a deviation of the jaw when the mouth is open. The JAW JERK or MAXILLARY REFLEX is performed by tapping the middle of the chin with a reflex hammer while the patient's mouth is slightly open. A normal reflex is a sudden, slight closing movement of the jaw. The three divisions of the trigeminal nerve are opthalmic, maxillary and mandibular. | |
| **VII—FACIAL** | The facial nerve is both motor and sensory in function. The SENSORY PORTION of the nerve supplies a portion of the ear, a portion of the pharynx, taste to the anterior two-thirds of the tongue and the salivary glands. The sensory portion of the facial nerve is tested by having the patient identify the taste of sugar and salt which is placed only on the anterior part of the tongue (test each side of the tongue with each substance). The patient should take a sip of water after each test substance is placed on the tongue. The tongue must remain protruded during the test. The MOTOR PORTION of the facial nerve enervates muscles of the face, and is tested by asking the patient to imitate the examiner as the examiner looks at the ceiling, wrinkles his forehead, frowns, smiles and raises his eyebrows. The examiner should note any asymmetry of the patient's face as the patient imitates the examiner. The strength of the eyelid muscles are determined by asking the patient to try to keep the eyes closed as the examiner attempts to open them. | 1) Central Facial Palsy (contralateral cerebral cortex or subcortical white matter of the brain)<br><br>2) Incomplete Peripheral Facial Palsy (nucleus in pons or distal to it, e.g., Bell's Palsy)<br><br>3) Complete Peripheral Facial Palsy |
| **VIII—ACOUSTIC** | Before examination of the cochlear nerve is performed, one should examine the external ear canal with an otoscope to make sure there is no abnormality and it is free from obstruction. RINNE'S TEST will detect nerve deafness, such as a lesion in the organ of corti or in the cochlear division of the acoustic nerve. Rinne's Test is performed by placing the shank of a vibrating tuning fork against the mastoid until the patient no longer hears it. Then, the examiner places the prongs about 1″ from the external auditory meatus. Normally, the fork is heard about twice as long by air conduction as compared to bone conduction. This test is positive when bone conduction (over mastoid) is longer than air conduction. The examiner should | Otitis media, skull fractures, otosclerosis, basal tumors, Meniere's Syndrome. |

| NERVE | DESCRIPTION OF TEST AND GENERAL INFORMATION | POSITIVE MAY INDICATE |
|---|---|---|
| | note if there is any difference between the ears in hearing acuity. WEBER'S TEST OR LATERALIZATION is tested by placing a tuning fork on the top of the patient's skull and inquiring whether the patient feels a centralized sensation or if it is referred to one side. BARANY'S TEST (caloric test) may be used to test the vestibular portion of the acoustic nerve. Barany's Test is performed by irrigating the ear with cold water. Nystagmus will develop on the opposite side. There will be no nystagmus if the labyrinth is diseased. Response should occur within 30 seconds. | Vestibular lesions are characterized by vertigo and nystagmus. |
| **IX—GLOSSO-PHARYNGEAL** | The glossopharyngeal nerve is both motor and sensory in function. The SENSORY PORTION of the nerve supplies the taste sensation to the posterior one-third of the tongue, the soft palate, the hard palate and the tonsils. The sensory portion of the nerve is tested by phonation (talking), i.e., "AH," etc. The MOTOR PORTION of the nerve supplies the levator muscles of the pharynx and the opening of the eustachian tube. The motor portion is tested by touching the uvula with a tongue depressor. The uvula should rise, and this test should initiate the GAG REFLEX. An alternate test which is not recommended for geriatric cases or for people with known cardiovascular disease is the CAROTID SINUS REFLEX. This test is performed as follows: If the nerve is functioning properly, pressure over the carotid sinus normally causes the heart to slow down and decreases the blood pressure. | Skull fractures, 9th cranial nerve disease, dysphagia, tachycardia. |
| **X—VAGUS** | The integrity of the vagus nerve can be determined by the patient's ability to swallow, speak clearly without hoarseness and by good symmetrical movements of the vocal chords. Also, the OCULOCARDIAC REFLEX may be used to check the integrity of the vagus nerve as follows: Place pressure upon the orbits. If the vagus nerve is of normal integrity, this should decrease the cardiac rate and output and thus decrease the blood pressure. | Paralysis of the superior laryngeal nerve; unilateral vagal paralysis; bilateral paralysis may be associated with poliomyelitis, Guillain-Barré Syndrome, amyotrophic lateral sclerosis, posterior diphtheritic paralysis. |
| **XI—SPINAL ACCESSORY** | To determine the functional integrity of the accessory nerve, the examiner should palpate and note the strength of the sternocleidomastoid muscles and the trapezius muscles while the patient's shoulders are shrugged against resistance. (For muscle testing, see the appropriate section in the chapter on Muscles, Structural Faults and Correction.) | Multiple sclerosis, certain types of epilepsies, 11th cranial nerve palsy due to trauma, cervical disc lesions, spasmotic torticollis, poliomyelitis, amyotrophic lateral sclerosis, spinal cord tumors. |

# NEUROLOGY-CRANIAL NERVE EXAMINATION

| NERVE | DESCRIPTION OF TEST AND GENERAL INFORMATION | POSITIVE MAY INDICATE |
|---|---|---|
| **XII—HYPO-GLOSSAL** | The examiner should ask the patient to protrude the tongue. Note any lateral deviations, tremors, or atrophy. The patient should then be instructed to move the tongue from side to side. Note any restrictions of motion. Have the patient stick his tongue into the left and right cheek, and note any difference in strength as the cheek is palpated. | Skull fracture, cervical subluxation, aneurysm of the circle of Willis.<br><br>**USUAL LESIONS OF 12TH CRANIAL NERVE:**<br>1) Coarse tremors of the tongue, i.e., Parkinson's Disease, paresis<br>2) Fine tremors of the tongue, i.e., alcoholism, senility, bromide intoxication, functional (idiopathic) disorders<br>3) Fibrillations of the tongue and hemiatrophy, i.e., bulbar palsy, syringomyelia, occasional poliomyelitis |

# NEUROLOGY—THE CEREBELLUM

## I. GENERAL CEREBELLAR FUNCTIONS

**A.** Coordination of voluntary movement.

**B.** Fine muscular movement.

**C.** Postural reflexes.

**D.** Equilibrium.

**E.** Synergic voluntary movement.

## II. GENERAL CEREBELLAR TEST

Coordination, Gait and Equilibrium Test: A simple walking test will reveal the patient's posture, gait and coordinated automatic movements. The examiner should observe the swinging of the arms, the patient's ability to walk in a straight line and the patient's ability to make rapid turning movements at the examiner's order.

## III. SPECIFIC CEREBELLAR TESTS

The correct performance of these tests depends principally on the integrity of the cerebellum and its afferent and efferent tracts.

### A. FINGER-TO-NOSE TEST

The patient is in a standing or seated position, preferably standing. The patient is instructed to bring his index finger to the tip of his nose, first with his eyes open and then with his eyes closed, utilizing both his right and left hands. This test is positive if the patient is unable to bring his finger to the tip of his nose with his eyes open or closed.

### B. SUPINATION-PRONATION TEST

Supination and pronation of the forearms are tested in continuous, rapid alternation. This test is positive if the patient is unable to perform these movements speedily and smoothly.

### C. TANDEM GAIT

The patient is instructed to walk forward and backward with the toes of one foot touching the heel of the other. This should be performed with only minimal instability. This test is positive if the patient is unable to perform this test due to great instability.

### D. STANDING SIGN-OF-FOUR

The patient is asked to stand in an erect position and put the heel of one foot to the shin of the opposite leg. This test is positive if the patient is unable to perform this function.

### E. ROMBERG'S SIGN

The patient stands with both feet together, first with the eyes open and then with the eyes closed. This test is positive if the patient is capable of standing erect with the eyes open but sways or falls with the eyes closed.

### F. TOE-TO-FINGER TEST

The patient is supine and touches the examiner's finger with his great toe, holding it there until the examiner moves his finger to a new position 6″-8″ away. The patient then follows the examiner's finger with his toe.

### G. HOLMES' REBOUND PHENOMENON

The patient flexes his arm against the resistance of the examiner. This test is positive if the arm strikes the patient's chest uncontrollably when it is suddenly released by the examiner.

## IV. COMMON SIGNS OF CEREBELLAR DISORDERS

**A.** Disturbances of Alternating Movement.

**B.** Ataxia.

**C.** Tremor.

**D.** Abnormalities of Muscle Tone.

**E.** Abnormalities of Speech.

**F.** Nystagmus

## V. COMMON CAUSES OF CEREBELLAR DISORDERS

**A.** Tumors.

**B.** Trauma.

**C.** Inflammatory Disease.

**D.** Toxins

**E.** Degenerative Lesions.

**F.** Cranial Faults.

# NEUROLOGY—PYRAMIDAL SYSTEM

## I. LOCATION

The Pyramidal tracts consist of those fibers which originate in the cortex and pass to the spinal cord through the pyramids of the medulla. Example: corticospinal tract.

## II. GENERAL FUNCTION

Involved in finite voluntary muscular control required for complicated acts, i.e., idiokinesis, mature, well localized moves which begin and end quickly.

## III. PYRAMIDAL TESTS

### A. PYRAMIDAL SIGN

Have the patient flex his fingers, and the examiner flex his. Ask the patient to pull against the examiner's fingers. This action will cause the thumb on the involved side to adduct to the palm of the hand if this test is positive.

### B. QUADRICEPS TONUS TEST

Ask the patient to lie in a supine position on the examining table with maximum relaxation of the legs. The examiner places one hand under the thigh and the other hand under the leg. The extremity is raised to approximately 45°, after which the examiner pulls his hand from under the leg allowing it to fall. Normally, the leg falls and the motion is even throughout its course. In pyramidal lesions, it has a jerky dropping appearance, not smooth. In Parkinson's disease, it is not jerky, but is slower than normal.

### C. TIBIALIS ASSOCIATED MOVEMENT

The patient is in a supine position with the legs outstretched and is asked to raise the affected leg against resistance which the examiner places on the knee. In spastic paralysis, the foot will dorsiflex and supinate and the tendon of the tibialis anterior muscle will become prominent.

# NEUROLOGY—EXTRAPYRAMIDAL SYSTEM (BASAL GANGLIA)

## I. GENERAL FUNCTIONS

**A.** Control of postural adjustments.

**B.** Aids in voluntary motion.

**C.** Autonomic integration.

## II. GENERAL TESTS

The muscles should be inspected and palpated while at rest for size, consistency and possible atrophy. They should also be examined for resistance and passive movement in the affected area. Compare corresponding parts of the extremities. Different muscle groups should be tapped lightly to test for irritability and myotonia. Examine and compare the fine muscles of each hand, looking for wasting, fasciculations and fine tremors of individual muscle fibers. Fasciculations are often present when there is muscle wasting of lower motor neuron origin. The examiner should keep in mind that certain tics and gross involuntary movements may be of an emotional origin.

## III. SPECIFIC TESTS

### A. SHOULDER SHAKING TEST

The patient is in a standing position with his arms at his sides. The examiner faces the patient and grasps both of the patient's wrists. The examiner then alternately pulls each arm downward, thus causing the patient's shoulders to move or shake. In an extrapyramidal system lesion, the range of motion is diminished on the affected side. In a cerebellar lesion, the affected side will increase in range of motion.

### B. PENDULUM ARM SWINGING TEST

This is a simple walking test in which the examiner is interested specifically in the swinging of the arms. Parkinson's disease, which is the most common of the extrapyramidal system lesions, automatically reduces the pendulousness of the arms.

## IV. COMMON MAJOR CONDITIONS

**A.** Parkinsonism (paralysis agitans).

**B.** Involuntary movements (athetosis chorea).

**C.** Internal capsule involvement due to cerebral vascular accident.

# NEUROLOGY—TRACTS OF THE SPINAL CORD

## (Examination and Lesions)

It is not within the scope of this manual to discuss the entire anatomy of the spinal cord, as this information can be easily found in any anatomy textbook. We will, however, discuss the various spinal tracts which can be easily related to your examination and practice.

## I. WHITE MATTER

White matter, or the portion which contains the tracts which are sensory or ascending and motor or descending, is divided into the following three distinct segments:

### A. POSTERIOR WHITE COLUMNS

These consist mainly of the tracts of Goll (fasciculus gracilis) which is located to the medial aspect of the posterior columns and the tract of Burdach (fasciculus cuneatus) which is located just lateral to the tract of Goll in the posterior or dorsal column. They are ascending tracts. The functions of the posterior white columns are to convey conscious proprioception (muscle and joint or position sense), deep touch and pressure, vibration sense and two point discrimination. The tract of Goll conducts the above mentioned sensations from the lower half of the body and lower limbs to the thalamus, from where the impulses are then sent to the parietal area of the brain (somesthetic area of the cortex) where we have the ability to localize sensations or pinpoint on a conscious level from where the impulse is coming.

### B. LATERAL WHITE COLUMNS

The following tracts are the primary ascending tracts of importance in this segment. The SPINO-THALAMIC TRACT is one of the major ascending tracts which carries pain and temperature sensations to the thalamus and from there they are distributed to the somesthetic area of the cerebral cortex. These fibers cross at the spinal cord level just behind the central canal of the spinal cord. Therefore, in upper motor neuron lesions (UMN) the absence of pain is on the opposite side, whereas in lower motor neuron lesions (LMN), the pain is altered on the same side. The SPINOCEREBELLAR TRACTS are also ascending tracts found in the lateral columns just behind the spinothalamic tract. They are two in number — the ventral and dorsal spinocerebellar tracts. These are for unconscious proprioception and convey information concerning muscle and tendon tension to the cerebellum.

The CORTICOSPINAL TRACT (cerebrospinal tract) or LATERAL PYRAMIDAL TRACT is the primary descending tract of importance in this segment. It is the major motor tract of the body. It conveys motor impulses from the opposite cerebral hemisphere, where it takes origin in the motor cells of Betz. It's fibers cross to the opposite side of the body at the pyramidal decussation in the medulla. These fibers then pass down the lateral aspect of the spinal cord, just medial to the spinocerebellar tracts.

### C. ANTERIOR OR VENTRAL WHITE COLUMNS

The ANTERIOR PYRAMIDAL TRACT (ventral corticospinal tract) is the primary descending tract of importance in this segment. It conveys a portion of the motor impulses from the cerebral cortex. These tracts don't cross or decussate in the medulla. However, at each spinal level they cross to supply the anterior horn cells of the opposite side.

The ANTERIOR OR VENTRAL SPINOTHALAMIC TRACT is the primary ascending tract of importance in this segment. It is found just lateral and anterior to the anterior pyramidal tract. It conveys light touch sensations to the brain, and may be checked by using a small brush or a wisp of cotton.

## II. GRAY MATTER

Gray matter consists of nerve cell bodies which form the letter "H" located in the center of the cord, and this substance is divided into the following four major segments:

**A.** The ANTERIOR HORNS are where the anterior horn cells are located and also where the pyramidal tracts synapse. These anterior horn cells are the origin of the motor unit and lower motor neuron (LMN, sometimes called the final common pathway).

**B.** The POSTERIOR HORNS are the areas where the sensory synapses take place.

**C.** The LATERAL HORNS are the areas for the cells of origin of the sympathetic nervous system which are found in the 12 dorsal levels and the first and second lumbar levels. These fibers pass via the anterior root and pass to the lateral sympathetic chain ganglia. They are called WRC (white ramus communicans) and in the ganglia they synapse with the GRC (gray ramus communicans).

**D.** The GRAY COMMISSURE is that portion of the "H" that runs between the two lateral halves. It has in its center the central canal, which runs the entire length of the spinal cord. It contains fibers called commissural fibers which pass from one side of the spinal cord to the other.

## III. DISORDERS RESULTING FROM LESIONS OF THE WHITE OR GRAY MATTER

### A. POSTERIOR WHITE COLUMNS

Lesions of this area, such as in tabes dorsalis and various forms of sclerosis, result in:

1) Loss of vibratory sensation. This is tested by placing the tuning fork (C-128) over the medial and lateral malleolus of the lower extremity or any other bony prominence in the area, thus checking the integrity of the tract of Goll. The examiner then places the tuning fork over the styloid process of the upper extremity to check the integrity of the tract of Burdach.
2) Ataxis. By definition, this means a wobbling, unsteady or drunken gait. This occurs due to the lack of muscle, joint and tendon sensations, thus resulting in a loss of conscious proprioception.
3) Position sense is absent. This can be checked by aiding the patient in moving a toe or finger (with the patient's eyes closed) and having the patient tell you the position of it. Be sure to grasp the toe or finger firmly between your thumb and first finger and move it about — don't push it.

### B. PYRAMIDAL TRACTS

Lesions of this area result in all findings and signs characteristic of an UMN lesion (see upper motor neuron lesions in this chapter).

### C. ANTERIOR HORNS

Lesions of this area result in:

1) Progressive muscular atrophy (considered a form of amylotrophic lateral sclerosis without the involvement of the lateral tracts or UMN lesions).
2) Polio.

### D. GRAY COMMISSURE

Lesions of this area result in syringomyelia. This is a condition characterized by gliosis around the central canal of the spinal cord, thus it causes destruction of the fibers of pain and temperature that cross just behind the central canal. Anesthesia will result on both sides of the body at the levels of the lesions.

## IV. LOCALIZATION OF SPINAL CORD LESIONS

This may be accomplished in numerous ways and is usually done by correlating the various known methods. The following are those methods which are most frequently used:

**A.** REFLEX TESTING to determine the integrity of the reflexes at the various levels of involvement.

**B.** MUSCLE TESTING to determine the motor power of the various groups of muscles supplied by the levels of involvement. Muscles are checked for a number of changes:

1) Motor power which is graded according to standards.
2) Degree of tonus, that is, is the muscle flaccid or spastic.
3) Degree of muscular atrophy of involved area.

**C.** CUTANEOUS SENSITIVITY of the various dermatome areas supplied by the involved levels of the cord. These are also checked for a number of changes.

1) Superficial sensation which consists of temperature, pain and tactile (light touch). Always compare dermatome on one side to that of the other.

**D.** DEEP SENSITIVITY of the various dermatome areas.

1) Position sense and vibration sense.
2) Muscle and tendon pain.

Keep in mind that the intervertebral foramen from which the nerve emits does not correspond to the level of the cord from which the nerve arises.

# NEUROLOGY—SENSORY SYSTEM

## I. TESTS FOR THE SENSORY SYSTEM

Throughout the examination, the doctor should:

**A.** Note the patient's ability to perceive the sensations being tested.

**B.** Compare both sides of the body and corresponding extremities.

**C.** Compare the sensitivity of the distal and proximal parts of each extremity for each form of sensation.

**D.** Try to determine whether the sensory change is involved in dermatomal distribution, involves the entire side of the body, or if it is confined to the peripheral nerves.

In all sensory tests, the patient's eyes should be *kept closed.* The results of sensory testing depend upon the patient's perception and interpretation of the stimuli. The cooperation of the patient is imperative. Sensory tests are often difficult to evaluate since one frequently finds a diminution of sensation rather than total anesthesia.

## II. PRIMARY FORMS OF SENSATION

### A. SUPERFICIAL TACTILE SENSATION

1) Does the patient feel the touch of a wisp of cotton?
2) How does the sensitivity to cotton on one side of the body compare with that on the opposite side?
3) Check hands, forearms, upper arms, trunk, thighs, lower legs and feet (in that order) and then the perineal and perianal areas.
4) Compare the sensitivity of the proximal part of each extremity to the distal part.

### B. SUPERFICIAL PAIN

Using a pin, pinwheel or other sharp object, follow the procedure outlined in Subsection A above, points 2 through 4.

### C. SENSITIVITY TO TEMPERATURE

Using the same procedure, touch various parts of the body with test tubes containing hot and cold water.

**D. SENSITIVITY TO VIBRATION**

Hold a tuning fork to the bony prominences of:

1) Wrists.
2) Elbows.
3) Shoulders.
4) Hips.
5) Knees.
6) Shins.
7) Ankles.

Note the patient's ability to feel when the vibration stops. Compare sensitivity from side to side and in the proximal and distal portions of the extremities.

**E. DEEP PRESSURE PAIN**

Squeeze the Achilles tendons, the calf and forearm muscles, noting sensitivity.

**F. MOTION AND POSITION**

The fingers and toes are moved passively. The patient is asked to indicate the direction of movement and the final position of the digit. Care should be exercised so that pressure on the skin cannot be used as a clue to the direction of movement. Therefore, the sides of the toes, thumbs and fingers are grasped between the examiner's index finger and thumb.

**III. SENSORY LOSS**

Sensory loss may be due to many factors and may be accompanied by pain. However, upper motor neuron lesions, i.e., brain or cord injuries or disease may also exist. In such cases, abnormal reflexes and other signs are present, such as the absence of superficial reflexes, exaggerated deep tendon reflexes, spastic and rigid paralysis.

## NEUROLOGY—MOTOR SYSTEM

**I. TESTS FOR THE MOTOR SYSTEM**

The power of the muscle groups of the extremities, neck and trunk should be tested. Where weakness is apparent, one should test the individual muscles in the group. (If additional information is required regarding muscle testing, see the chapter on Muscles, Structural Faults and Correction.

**II. CHARACTERISTICS OF MOTOR DISTURBANCES**

Motor disturbances may be caused by the same disease processes as sensory disturbances. However, the primary cause of motor disturbances are nerve root involvement, upper motor neuron lesions and lower motor neuron lesions.

**A. NERVE ROOT INVOLVEMENT**

Motor nerve involvements may be characterized by deep muscular pain in the involved muscles. In the early stages, hypertonicity or muscle spasm is evident. In the latter stages or in chronic conditions, loss of tendon reflexes, muscular weakness, atrophy or even trophic changes in the overlying skin may be present.

**B. UPPER MOTOR NEURON LESIONS**

Upper motor neuron lesions may be characterized by hyperreflexia (see upper motor neuron lesions).

**C. LOWER MOTOR NEURON LESIONS**

(See lower motor neuron lesions.) NOTE: Hyporeflexia, particularly if bilateral or present in other similar reflexes, may be normal for a particular patient.

# REFLEXES

## NEUROLOGY—VISCERAL REFLEXES

| REFLEX | DESCRIPTION | AFFERENT | CENTER | EFFERENT |
|---|---|---|---|---|
| **LIGHT** | Constriction of the pupil of the eye when light is thrown on the retina. | CRANIAL II | MIDBRAIN | CRANIAL III |
| **ACCOMMODATION** | Constriction of the pupils when the patient looks at close objects and the eyes are converged. | CRANIAL II | OCCIPITAL CORTEX | CRANIAL III |
| **CILIOSPINAL** | Dialation of the pupil upon painful stimulation of any sensory area, usually by pinching the neck. | SENSORY | T-1 & T-2 | CERVICAL SYMPATHETICS |
| **OCULOCARDIAC** | Slowing of the heart rate produced by heavy pressure on the eyeballs. | CRANIAL V | MEDULLA | CRANIAL X |
| **CAROTID SINUS** | Slowing of the heart rate with decrease in blood pressure produced by applying pressure over the carotid sinus in the neck. | CRANIAL IX | MEDULLA | CRANIAL X |
| **BULBOCAVERNOSUS** | Contraction of the bulbocavernosus muscle (compressor urethrae) upon stroking the dorsum of the glans penis. | PUDENDAL | S-2, 3 & 4 | PELVIC AUTONOMIC |
| **BLADDER OR RECTAL** | Control of the urine and feces is under the influence of the pelvic autonomics. Interruption of these motor fibers will result in incontinence. Interruption of the afferent tract abolishes the urge to urinate or defecate (seen in tabes dorsalis), which results in distention and dribbling. | PUDENDAL | S-2, 3 & 4 | PUDENDAL AND AUTONOMICS |

## SUPERFICIAL REFLEXES

| REFLEX | DESCRIPTION | AFFERENT | CENTER | EFFERENT |
|---|---|---|---|---|
| **CORNEAL** | Observe whether the patient responds to a light touch with a wisp of cotton on the cornea. | CRANIAL V | PONS | CRANIAL VII |
| **UVULA** | Touch the uvula with a tongue depressor. The uvula should rise, and this will initiate the gag reflex. | CRANIAL IX | MEDULLA | CRANIAL X |
| **UPPER ABDOMINAL** | With the patient supine and the abdominals relaxed, the upper quadrant of the abdomen is briskly stroked with a pin or pinwheel from the periphery toward the umbilicus. Normally, the local abdominal muscles contract, causing the umbilicus to move toward the quadrant stimulated. | T-7 through T-10 | T-7 through T-10 | T-7 through T-10 |
| **LOWER ABDOMINAL** | With the patient supine and the abdominals relaxed, the lower quadrant of the abdomen is briskly stroked with a pin or pinwheel from the periphery toward the umbilicus. Normally, the local abdominal muscles contract, causing the umbilicus to move toward the quadrant stimulated. | T-10 through T-12 | T-10 through T-12 | T-10 through T-12 |
| **CREMASTERIC** | Stroke the skin of the inner side of the proximal third of the thigh. This should cause retraction of the testicle on that side. | FEMORAL | L-1 | GENITOFEMORAL |
| **PLANTAR** | Slightly rotate the thigh externally. Lightly stroke the sole of the foot with a large pin from the heel to the base of the little toe and then inward across the ball of the foot. Normal response usually consists of plantar flexion of all the toes with slight inversion and flexion of the distal portion of the foot. | TIBIAL | S-1 & S-2 | TIBIAL |
| **ANAL** | Contraction of the sphincter ani upon stroking the perianal area or upon inserting a gloved finger into the rectum. | PUDENDAL | S-4 & S-5 | PUDENDAL |

# NEUROLOGY—DEEP REFLEXES

| REFLEX | DESCRIPTION | AFFERENT | CENTER | EFFERENT |
|---|---|---|---|---|
| **BICEPS** | The examiner strikes his thumb which has been placed on the patient's biceps tendon (elbow slightly flexed). This should produce a slight contraction of the biceps muscle. | MUSCULO-CUTANEOUS | C-5 & C-6 | MUSCULO-CUTANEOUS |
| **TRICEPS** | With the patient's elbow supported in the examiner's hand, the triceps is sharply percussed just above the olecranon. Contraction of the triceps with extension of the forearm usually results. | RADIAL | C-6 & C-7 | RADIAL |
| **RADIAL** | With the patient's forearm supported by the examiner's hand, the brachioradial tendon is sharply percussed. Contraction of the forearm and sometimes flexion of the fingers should occur. | RADIAL | C-6 through C-8 | RADIAL |
| **PATELLAR** | Tap the patellar tendon lightly with a percussion hammer and contraction of the quadriceps muscle can be elicited. The patient may be seated on the edge of a table or bed with his legs hanging loosely. For those patients on the adjusting table, the knees may be flexed over the supporting arm of the examiner with the heels resting lightly on the table. | FEMORAL | L-2, 3 & 4 | FEMORAL |
| **ACHILLES** | This is best elicited by having the patient kneel on a chair with his ankles and feet projecting over the edge of the chair. The Achilles tendon is then struck with a percussion hammer. This should elicit plantar flexion of the foot. | TIBIAL | S-1 & S-2 | TIBIAL |
| **MAXILLARY (Jaw Jerk)** | Tap the middle of the chin with a reflex hammer while the patient's mouth is slightly open. The normal reflex is a sudden, slight closing movement of the jaw. | TRIGEMINAL | PONS | TRIGEMINAL |

## PATHOLOGICAL REFLEXES—HEAD

| REFLEX | PICTORIAL EXPLANATION | DESCRIPTION |
|---|---|---|
| BABINSKI'S PLATYSMA SIGN | 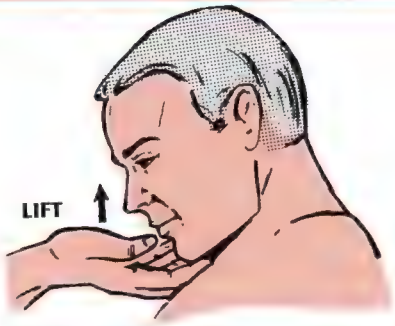  | If resistance is offered to flexion of the chin against the chest or to the opening of the mouth, the platysma on the sound side will contract. That on the affected side will not contract. |
| MC CARTHY'S SIGN | 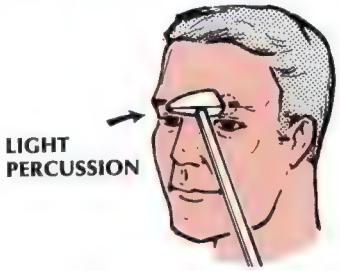  | Light percussion of the supraorbital ridge results in a reflex contraction of the orbicularis oculi muscle. |

## PATHOLOGICAL REFLEXES—UPPER EXTREMITIES

| REFLEX | PICTORIAL EXPLANATION | DESCRIPTION |
|---|---|---|
| HOFFMAN'S SIGN | | Clawing movements of the fingers produced by flicking the distal phalanx of the index finger. |
| GORDON'S FINGER SIGN | | Flexion of the fingers or thumb and index finger when pressure is exerted over the pisiform bone. |
| CHADDOCK'S WRIST SIGN | | Flexion of the wrist with extension and fanning of the fingers upon stroking the ulnar surface of the forearm near the wrist. |

# PATHOLOGICAL REFLEXES—LOWER EXTREMITIES

| REFLEX | PICTORIAL EXPLANATION | DESCRIPTION |
|---|---|---|
| BABINSKI'S SIGN | | Extension of the large toe with fanning of the small toes upon stimulation of the plantar surface of the foot. |
| CHADDOCK'S TOE SIGN | | Babinski-like response obtained by stroking the lateral malleolus. |
| GORDON'S LEG SIGN | 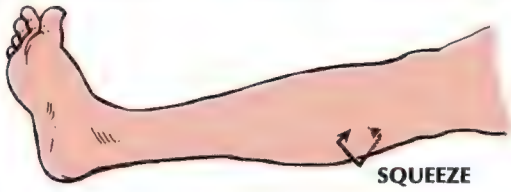  | Babinski-like response upon squeezing the calf muscle. |
| OPPENHEIM'S SIGN | 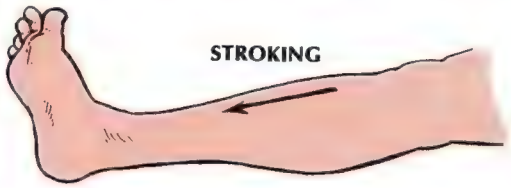  | Babinski-like response elicited by firm, downward stroking of the tibia and the tibialis anterior muscle. |
| GONDA REFLEX | 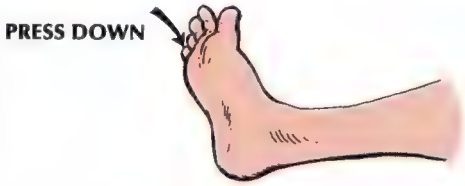  | Upward movement of the big toe upon pressing one of the other toes downward and releasing it with a snap. |
| SCHAEFER'S SIGN | 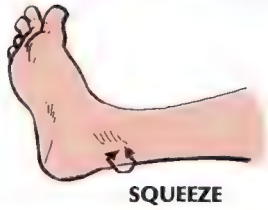  | Babinski-like response upon squeezing the Achilles tendon. |
| ROSSOLIMO'S SIGN | 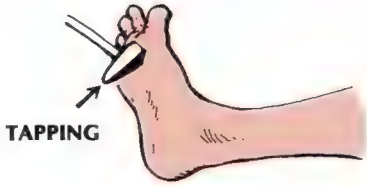  | Flexion of the toes upon tapping the ball of the foot. |

# NEUROLOGY—REFLEXES

## I. GRADING OF DEEP REFLEXES

The following are grades of the various reflexes and the significance of each grade:

1) Grade 0 — A reflex which cannot be elicited at all.
2) Grade -3 — A reflex which is absent, except on reinforcement (the Jendrassik method of reinforcement should be tried).
3) Grade -2 — A reflex which is markedly decreased.
4) Grade -1 — A reflex which is weak (compare both sides of the body).
5) Grade N — A reflex which is normal.
6) Grade +1 — A reflex which is slightly hyperactive.
7) Grade +2 — A reflex which is markedly increased (associated with unsustained clonus).
8) Grade +3 — A reflex which is markedly increased (associated with sustained clonus).

## II. SIGNIFICANCES OF ABNORMAL REFLEXES

Significance of abnormal reflex responses in diminished or in the absence of deep reflexes may result from any lesion which interrupts the reflex arc, i.e., peripheral nerve disease, involvement of the posterior columns of gray matter of the spinal cord and cerebellar disease. Since the deep reflexes are normally under partial inhibition by the higher centers, lesions of the upper motor cortex or pyramidal tracts (upper motor neuron) results in exaggerated deep reflexes and muscular rigidity. Hyperactive reflexes also occur in strychnine poisoning and in some functional disorders.

In patients with exaggerated reflexes, clonus may be elicited in the wrist, patellar or ankle.

The patellar reflex is simply an extension of the knee when the patellar tendon is struck. Westphal's sign is when this reflex is absent. If a response cannot be obtained, use the Jedrassik method of producing it, which is to have the patient interlace and pull his forefingers against each other. At this time percuss the patellar tendon.

# NEUROLOGY—UPPER AND LOWER MOTOR NEURON LESIONS

## I. LOWER MOTOR NEURON LESIONS (LMN)

Lower motor neuron lesions may be located in the cells of the ventral gray column of the spinal cord, brain or in the axons which constitute the ventral roots and spinal or cranial nerves. Signs of lower motor neuron lesions include flaccid paralysis of involved muscles, and muscle atrophy. Reflexes are diminished or absent in these cases and usually no pathological reflexes are obtainable.

## II. UPPER MOTOR NEURON LESIONS (UMN)

Upper motor neuron lesions may be located in the cerebral cortex, the internal capsule, the cerebral peduncles, the brain stem or the spinal cord. Signs of upper motor neuron lesions include spastic paralysis of the involved muscles, little or no muscle atrophy and hyperactive deep reflexes, diminished or absent superficial reflexes and the presence of pathological reflexes and signs.

## III. DIFFERENTIATION BETWEEN LMN AND UMN

| LOWER MOTOR NEURON LESIONS (LMN) | UPPER MOTOR NEURON LESIONS (UMN) |
|---|---|
| 1. Absence or diminished reflexes. | 1. Hyperactive reflexes. |
| 2. Loss of tone. | 2. Increased tone. |
| 3. Flaccid paralysis. | 3. Spastic paralysis. |
| 4. Marked muscle atrophy. | 4. Limited atrophy. |
| 5. Small area of involvement. | 5. Large area of involvement. |
| 6. No clonus. | 6. Clonus. |
| 7. Fasciculations. | 7. No fasciculations. |
| 8. Negative pathological reflexes. | 8. Positive pathological reflexes. |

## IV. CAUSES OF LOWER AND UPPER MOTOR NEURON LESIONS

| LOWER MOTOR NEURON LESIONS (LMN) | UPPER MOTOR NEURON LESIONS (UMN) |
|---|---|
| 1. Subluxation. | 1. Subluxation. |
| 2. Disc lesions. | 2. Disc lesions. |
| 3. Trauma. | 3. Cord injury. |
| 4. Fracture. | 4. Fracture. |
| 5. Nerve inflammatory conditions, e.g., neuritis, neuralgia. | 5. Inflammatory conditions, e.g., encephalitis. |
| 6. Tumors of peripheral nerves. | 6. Tumors of C.N.S. (brain & cord) |
| 7. Polio. | 7. Hemorrhage (cerebral vascular accident). |
| 8. Progressive atrophy. | 8. Sclerosis, e.g., multiple. |

## V. SYMPTOMS OF SPACE OCCUPYING LESIONS

### A. SPACE OCCUPYING LESIONS ABOVE THE FIRST CERVICAL VERTEBRA

1) Severe headaches that do not respond to the use of narcotic sedation. May be associated with vomiting.
2) Cranial nerve involvement which is usually unilateral.
3) Hearing loss may occur.
4) Visual field may be affected.
5) Symptoms are frequently progressive in nature and severity.
6) May be associated with tumors of the past, recent infection or trauma.
7) Epileptic-type seizures.
8) Progressive paralysis.
9) Personality changes.
10) Increased cranial pressure.

### B. SPACE OCCUPYING LESIONS BELOW THE FIRST CERVICAL VERTEBRA

1) Radicular pain.
2) Muscle atrophy.
3) Increased frequency of symptoms and increased severity.
4) Progressive paraplegia, hemiplegia, monoplegia.
5) Decreased sensation.
6) History of infection, trauma, neoplasms, especially if they have had a history of a previous malignancy.
7) Loss of bladder and rectal function.

# NEUROLOGY—GAITS*

## I. DEFINITION

Gait is the patient's manner or style of walking. The examiner can gain significant information from the patient's gait.

## II. COMMON GAITS

Listed below are the gaits most frequently seen in general practice:

### A. NORMAL GAIT

Normal rhythmic pattern of walking.

### B. ANTALGIC GAIT

The position the patient assumes to relieve himself from pain.

### C. ATAXIC GAIT

A walk in which the foot is raised high and the sole strikes the ground at once and very suddenly.

### D. CEREBELLAR GAIT

A staggering gait indicative of cerebellar disease.

### E. CHARCOT'S GAIT

Intermittent limping in arteriosclerosis of the legs and feet.

### F. GAIT LIMP

The cause of limp can be seen when the patient walks undressed. If the limp is caused by pain, the weight is lowered carefully onto the affected side, the knee bends slightly to absorb the shock, and the length of the step is shortened so that the weight can be taken off the leg quickly. If the limp is due to a stiff hip, the whole trunk and the affected leg are swung forward as one piece from the sound hip. If there is apparent shortening, the heel of the short side does not touch the ground.

### G. MULTIPLE SCLEROTIC GAIT

Spastic gait with rigidity of the lower limbs.

### H. STEPPAGE GAIT

A gait in which the advancing foot hangs with the toes pointing toward the ground, the leg being lifted high so that the toes may clear the ground. It is due to paralysis of the peroneal nerve and is seen in lesions of the lower motor neuron, such as multiple neuritis, lesions of the anterior motor horn cells and lesions of the cauda equina.

### I. SPASTIC GAIT

A walk in which the legs are held together and move in a stiff manner, the toes seeming to drag and catch.

### J. PARALYTIC GAIT

A gait in which the foot is dragged loosely along the ground.

*See Nerve Root and Disc Syndromes, page 391.

# CHAPTER VII

# CLINICAL LABORATORY

## INTRODUCTION

Great strides have been made in clinical laboratory diagnosis in the last 50 years. The Chiropractor of today is armed with many tests that our colleagues of the past never dreamed could be possible.

To some Chiropractors, the multiplicity of laboratory aids appear unnecessary or make the practice of Chiropractic more confusing. To those Chiropractors who understand clinical laboratory diagnosis, it makes the practice of Chiropractic and the documentation of the patient's case much easier. Coordinated with the knowledge of the patient's history, examination and x-rays, laboratory tests aid in the Chiropractor's management of the most difficult cases.

At no time should a clinical laboratory procedure be regarded as the sole practice of Chiropractic in itself, nor should the specific information provided by a laboratory test be construed as the total rationale in clinical judgment.

The following information is given for the busy practitioner or student to broaden his knowledge in the field of clinical laboratory diagnosis. In most cases, the minimum number of tests are given. This information may be used as a quick reference guide and should not be construed as a complete treatise on the subject of clinical laboratory procedure.

## COMMON CLINICAL LABORATORY ABBREVIATIONS

| | |
|---|---|
| BUN | Blood Urea Nitrogen |
| CBC | Complete Blood Count |
| CRP | C-Reactive Protein |
| CREATININE (SER) | Serum Creatinine |
| CREATININE (UR) | Urine Creatinine |
| ESR | Erythrocyte Sedimentation Rate |
| FBS | Fasting Blood Sugar |
| LDH | Lactic Acid Dehydrogenase |
| MONO | Mononucleosis Agglutination |
| PAP | Papanicolaou Test for Malignancy |
| R.A. LATEX | Latex Fixation Test for Rheumatoid Arthritis |
| RBC | Red Blood Count |
| SGOT | Serum Glutamic Oxalic Transaminase |
| SGPT | Serum Glutamic Pyruvic Transaminase |
| UA | Urinalysis |
| VDRL | Veneral Disease Research Laboratories Test for Syphilis |
| WBC | White Blood Cell Count |

# HEMATOLOGY

## DIFFERENTIAL COUNT

The differential count is one of the most informative and basic tests performed or requested by the busy practitioner.

This test consists of an estimation of the number or percentage of each variety of leukocytes in the blood, and yields more helpful general information than any other blood test.

Study the values closely in the differential count because an increase or a decrease in the relative value of a blood cell or cells is diagnostically significant.

The following information is presented in graphic form for quick reference and to facilitate learning.

| | | |
|---|---|---|
| **NEUTROPHILS** | NORMAL: | Bands or Stab — 0-500/cu. mm.<br>Segmented — 6,000/cu. mm. |
| | INCREASED: (Neutrophilia) | Acute infections, acute inflammation, myocardial infarction, crush injuries, hemorrhage, toxemias, myeloid leukemia, leukemic reactions. |
| | DECREASED: (Neutropenia) | Long-standing infections, overwhelming infections, Vitamin B-12 deficiencies, agranulocytosis, drug reactions, severe irradiations, lupus erythematosus. |
| **EOSINOPHILS** | NORMAL: | 50-300/cu. mm. |
| | INCREASED: (Eosinophilia) | Allergenic states, metazoan parasitic infections, skin conditions — including psoriasis, myeloid leukemia, radiation therapy or exposure, Hodgkin's disease, scarlet fever. |
| | DECREASED: (Eosinopenia) | Acute hemorrhage, acute infections, adrenal cortex hyperfunction, severe stress, shock. |
| **BASOPHILS** | NORMAL: | 0-100/cu. mm. |
| | INCREASED: (Basophilia) | Polycythemia vera, colitis, myxedema, myeloid leukemia, leukemic diseases. |
| | DECREASED: (Basopenia) | Allergies, hyperthyroidism. |
| **LYMPHOCYTES** | NORMAL: | 1,000-4,000/cu. mm. |
| | INCREASED: (Lymphocytosis) | Infectious mononucleosis, pertussis, recovery phase of an acute infection, hepatitis, herpes simplex, herpes zoster, syphilis, lymphatic leukemia. |
| | DECREASED: (Lymphopenia) | Acute pyogenic infections, lupus erythematosus, active TB. |
| **MONOCYTES** | NORMAL: | 200-800/cu. mm. |
| | INCREASED: (Monocytosis) | Protozoan parasitic infections, Hodgkin's disease, irradiation therapy, monocytic leukemia, TB. |
| | DECREASED: (Monocytopenia) | None known. |

**ADDITIONAL INFORMATION**

The absolute count is obtained by multiplying the particular series percentage by the total leukocyte count. The term a "shift to the left" refers to the increase in immature cells in the blood and this usually exists if there is an excessive demand for phagocytic cells which results in premature release of neutrophils from the marrow. Neutrophils reflect the severity of an infection by their percentage. A "shift to the right" indicates an increased maturity in the cells of a particular series.

# HEMATOLOGY

| | | |
|---|---|---|
| **HEMOGLOBIN** | NORMAL: | Males: 13 to 16 gm.%.<br>Females: 11 to 14.5 gm.%.<br>Children: 10.2 to 16.5 gm.% (varies with age). |
| | INCREASED: | Polycythemia vera, secondary polycythemia, dehydration. |
| | DECREASED: | All the anemias, late pregnancy. |
| | DISCUSSION: | Hemoglobin is responsible for oxygen transport in the blood. However, there can be considerable physiological variation in hemoglobin. Therefore, in interpreting hemoglobin values, a few grams above or below the average normal warrants discretion before interpreting the test as pathological. |
| **HEMOGLOBINEMIA** | DISCUSSION: | This term refers to the presence of free hemoglobin in the plasma and can result from any condition which causes rapid hemolysis. |
| **HEMOGLOBINURIA** | DISCUSSION: | This condition occurs when the plasma level exceeds the renal threshold. |
| **HEMATOCRIT (Packed Cell Volume)** | NORMAL: | Males: 40 to 50%.<br>Females: 38 to 45%. |
| | INCREASED: | Polycythemia, dehydration. |
| | DECREASED: | Anemias, hemorrhage. |
| | DISCUSSION: | Packed cell volume (PCV) or hematocrit is defined as the volume of packed erythrocytes per 100 milliliters of blood. This is done by centrifuging. One of the most precise methods of determining the degree of anemia or polycythemia is the hematocrit. |
| **ERYTHROCYTE SEDIMENTATION RATE (ESR)** | NORMAL: | Males: 0 to 9 mm./hr.<br>Females: 0 to 20 mm./hr. |
| | INCREASED: | Acute hemorrhage, inflammatory conditions, chronic infections, rheumatoid arthritis, gouty arthritis, hyperthryoidism, acute hepatitis, myocardial infarction, kidney disease, advanced malignancies, tuberculosis, rheumatic fever. |
| | DECREASED: | None known. |
| | DISCUSSION: | The ESR is not a specific test for any one disease. It is, however, increased in any disorder where there is an inflammatory reaction, tissue degeneration, suppuration or necrosis. The practitioner should note the ESR is usually increased in rheumatoid and gouty arthritis, while it is usually normal in osteoarthritis. |

| | | |
|---|---|---|
| **ERYTHROCYTE COUNT (RBC)** | NORMAL: | Males: 4,500,000 to 8,000,000/cu. mm.<br>Females: 4,000,000 to 6,000,000/cu. mm. |
| | INCREASED: (Erythrocytosis) | Polycythemia vera, secondary polycythemia. |
| | DECREASED: | Anemia, hyperchromic macrocytic anemia, pernicious anemia, gastrointestinal lesions, severe liver disease, hypochromic microcytic anemia, chronic hemorrhage, iron deficiency anemia, acute hemorrhage, normochromic normocytic anemia, decreased blood production, increased blood destruction. |
| | CLASSIFICATION: | Based upon morphological classification of anemia, three common types exist: MACROCYTIC HYPERCHROMIC, MICROCYTIC HYPOCHROMIC, and NORMOCYTIC NORMOCHROMIC. |
| | GENERAL CAUSES: | Inadequate intake or utilization, increased blood destruction, decreased blood production, hemorrhage. |
| | DISCUSSION: | The RBC count is performed routinely when the hematocrit is below 35 percent or above 45 percent. RBC count is useful in assessing the degree of anemia or erythrocytosis. |
| | RELATED TERMS: | The following terms are commonly used in reference to erythrocytes:<br>NORMOCHROMIC: Cells that have the normal amount of hemoglobin with no residual of basophilic material.<br>HYPOCHROMIC: Decrease in color density.<br>POLYCHROMIC: A mixture of hemoglobin color and basophilic material of the immature form.<br>MACROCYTIC: Cells which are larger than normal.<br>MICROCYTIC: Cells which are smaller than normal.<br>ANISOCYTOSIS: Inequality in the size of cells.<br>POIKILOCYTOSIS: Erythrocytes of abnormal size or shape.<br>LEPTOCYTE: An abnormally thin erythrocyte.<br>SPHEROCYTE: A cell of normal volume, increased thickness and decreased diameter.<br>BASOPHILIC STIPPLING, HOWELL-JOLLY BODIES, CABOT RINGS: These are synonyms which refer to immature cells due to rapid increased cell production.<br>TARGET CELLS: Cells which are characterized by increased density — seen in chronic anemias. |

| | | |
|---|---|---|
| **CELL INDICES (Average Red Cell Volume or Cell Constants)** | NORMAL: | M.C.V.: 80-94 cubic microns.<br>M.C.H.: 27-32 micromicrograms.<br>M.C.H.C.: 33-38%<br>Color Index: 0.9-1.1<br>Saturation Index: 0.85-1.15<br>Volume Index: 0.9-1.1 |
| | DISCUSSION: | When the hemoglobin concentration, the red cell count and the hematocrit have been determined, simple calculation yielding cell constants may help diagnose a specific type of anemia. Blood indices give the same information as the constants but are expressed as fractions of the normal. Calculations are determined from the following formulas:<br><br>**MEAN CORPUSCULAR VOLUME (M.C.V.)**<br>$\text{M.C.V.} = \frac{\text{P.C.V. X 10}}{\text{RBC in millions/cu. mm.}} = \text{80-94 cu. microns}$<br><br>**MEAN CORPUSCULAR HEMOGLOBIN (M.C.H.)**<br>$\text{M.C.H.} = \frac{\text{Hb. in gm. \% X 10}}{\text{RBC in millions/cu. mm.}} = \text{27-32 micromicrograms}$<br><br>**MEAN CORPUSCULAR HEMOGLOBIN CONCENTRATION (M.C.H.C.)**<br>$\text{M.C.H.C.} = \frac{\text{M.C.H. X 100}}{\text{M.C.V.}} = \text{32-36\%}$<br><br>**COLOR INDEX (C.I.)**<br>$\text{C.I.} = \frac{\text{Hemoglobin (in \% of normal)}}{\text{Erythrocyte count (in \% of normal)}} = \text{0.9-1.1}$<br><br>**SATURATION INDEX (S.I.)**<br>$\text{S.I.} = \frac{\text{Hemoglobin (in \% of normal)}}{\text{Hematocrit (in \% of normal)}} = \text{0.85-1.15}$<br><br>**VOLUME INDEX (V.I.)**<br>$\text{V.I.} = \frac{\text{Volume of packed red cells (in \% of normal)}}{\text{Erythrocyte count (in \% of normal)}} = \text{0.9-1.1}$ |
| **LUPUS ERYTHEMATOSUS (L.E. CELLS)** | NORMAL: | None. |
| | INCREASED: | Disseminated lupus erythematosus, rheumatoid arthritis, active chronic hepatitis, periarthritis nodosa. |
| | DISCUSSION: | Finding L.E. cells can strongly support a diagnosis of disseminated erythematosus. However, L.E. cells do not have to be found in order to have a reported case of lupus erythematosus. |

| | | |
|---|---|---|
| **SICKLE CELL PREPARATION** | DISCUSSION: | This test is of particular value and peculiar only to Negroes, whereby the clinical picture indicates a hereditary or familiar form of chronic hemolytic anemia. When sickling occurs rapidly with many different bizarre forms, it may indicate sickle cell anemia, provided the other hematologic findings indicate a hemolytic type of anemia with active regeneration of blood. When sickling occurs slowly and only a few bizarre cells are found without the signs of hemolytic anemia or active blood regeneration, this is indicative of sickle cell trait. |
| **PLATELET COUNT** | NORMAL: | 150,000 to 400,000/cu. mm. |
| | INCREASED: | Bone fractures, acute blood loss, chronic myeloid leukemia, polycythemia vera. |
| | DECREASED: | Irradiation, severe burns, acute leukemia, aplastic anemia, megaloblastic anemia, viral infections. |
| | DISCUSSION: | A decrease in blood platelets is termed THROMBOCYTOPENIA. THROMBOCYTOSIS is an abnormal increase in blood platelets. Due to human error and technical inaccuracies plus individuals having wide physiological variations, the number would have to be significantly increased or decreased before being considered pathological. |
| **RETICULOCYTE COUNT** | NORMAL: | 0.1 to 1.5% of RBC. |
| | INCREASED: | Hemolytic anemias, hemorrhage. |
| | DECREASED: | Aplastic anemias. |
| | DISCUSSION: | The number of reticulocytes in the peripheral blood is a good indication of erythroblastic activity of the bone. Any condition in which there is a rapid red cell destruction will cause an increased reticulocyte count. |

# URINALYSIS

## URINALYSIS — PHYSICAL EXAMINATION

| | | | | |
|---|---|---|---|---|
| **COLOR** | NORMAL: | Straw to amber | | |
| **COLOR** | ABNORMAL: | | **Substance** | **Could be Due To** |
| | | Yellowish Foam | Bilirubin | Obstructive jaundice or severe hepatocellular damage. |
| | | Blue | Methylene Blue | Substance used in renal function test. |
| | | Greenish Foam | Biliverdin | Oxidation of bilirubin. |
| | | Reddish | Porphyrins | Pernicious anemia, barbiturate poisoning, lead poisoning, congenital defect. |
| | | Clear Red to Reddish Brown | Hemoglobin | Paroxysmal hemoglobinuria, rapid hemolysis. |
| | | Orange Red | Pyridium | Urinary analgesic. |
| | | Smoky Red to Brown | Blood | Acute nephritis, kidney infarction, urogenital bleeding. |
| | | Brown to Black | Melanin | Melanoma, leukemia, ochronosis, hepatic carcinoma. |
| | | Black | Homogentisic Acid | Congenital abnormality, such as alkaptonuria. |

| | | |
|---|---|---|
| **TRANSPARENCY** | NORMAL: | Clear. |
| | TURBIDITY DUE TO: | Pus, blood, phosphates, urates, amorphous, mucus. |
| **QUANTITY** | NORMAL: | 1,200 to 1,500 ml./day. |
| **SPECIFIC GRAVITY** | NORMAL: | 1.010 to 1.030. |
| | INCREASED: | Dehydration, diabetes mellitus with glycosuria. |
| | DECREASED: | Diabetes insipidus. |

# URINALYSIS — CHEMICAL EXAMINATION

| | | |
|---|---|---|
| **ALBUMIN** | NORMAL: | None. |
| | INCREASED: (albuminuria or proteinuria) | All stages of glomerulonephritis, diabetes mellitus, lupus erythematosus, severe muscular exercise, amyloidosis. |
| | DISCUSSION: | Albuminuria or proteinuria is the term used when albumin is found in the urine for an undisclosed reason. Albumin is the smallest of the normal plasma proteins and it will readily pass through the glomerular membrane when it has been damaged. Therefore, albuminuria is a common finding in abnormal urine. |
| **SUGAR** | NORMAL: | None. |
| | INCREASED: | Diabetes mellitus, chronic liver disease, hyperpituitarism, hyperthyroidism, adrenal hyperfunctions, hemochromatosis. |
| | DISCUSSION: | Glycosuria is the term used when sugar is found in the urine. Glucose is the most frequent sugar found in urine. In patients with long-standing diabetes, the renal threshold may be increased. |
| **ACETONE** | NORMAL: | None. |
| | INCREASED: | Diabetes mellitus, abnormal fat metabolism, glycogen storage disease, eclampsia. |
| | DISCUSSION: | Acetonuria frequently occurs as a result of deficient carbohydrate metabolism which results in increased fat catabolism and ketosis. |
| **BILE** | NORMAL: | None. |
| | DISCUSSION: | Bile in the urine usually signifies extra hepatic obstruction. Bile seen in the urine is cholebilirubin which is soluble since it has been through the liver. Prior to processing in the liver, bilirubin is insoluble and is also bound to albumin. Therefore, it cannot pass through the intact glomular membranes. |
| **OCCULT BLOOD** | NORMAL: | None. |
| | INCREASED: | Hemoglobinuria, hematuria. |
| | DISCUSSION: | One must determine if the occult blood is from a hemolytic disorder or from a hematuric cause such as glomerulonephritis. |

# URINALYSIS — MICROSCOPIC URINE ANALYSIS

| | | |
|---|---|---|
| **LEUKOCYTES (WBC)** | NORMAL: | None, but occasional few per h.p.f. |
| | INCREASED: | Acute glomerulonephritis, prostatis, urethritis. |
| | DISCUSSION: | Pus in the urine indicates suppurative inflammation somewhere in the genitourinary tract. |
| **ERYTHROCYTES (RBC)** | NORMAL: | None or occasional per h.p.f. |
| | INCREASED: | Acute glomerulonephritis, calculi, bacterial infections. |
| | DISCUSSION: | Large numbers of RBC's in the urine without pus are suggestive of malignancy or trauma. RBC's and WBC's found together in the urine are often suggestive of bacterial infection or TB. |
| **EPITHELIAL CELLS** | NORMAL: | Occasional, mostly of the squamous variety. |
| | INCREASED: | Hemorrhagic nephritis, nephrosis or chronic kidney congestion. |
| | DISCUSSION: | An increase in a certain type of cell may give the doctor a clue as to the location of the lesion. Squamous epithelial cells arise from the lower urinary tract, round epithelial cells arise from the kidney tubules and caudate cells from the kidney pelvis. |
| **UNORGANIZED SEDIMENT (Amorphosus Sediment)** | DISCUSSION: | Usually, amorphosus substances have no clinical significance. Amorphosus substances are usually urates of sodium or potassium (if the urine is acid) or calcium phosphates or calcium magnesium (if the urine is alkaline). |
| **MUCUS** | NORMAL: | Small amounts. |
| | INCREASED: | Inflammatory conditions of the urinary tract. |
| | DISCUSSION: | Mucus indicates an inflammatory or irritative condition of the genitourinary system. |
| **CASTS OR CYLINDRURIA** | NORMAL: | None to rare. |
| | INCREASED: | Acute glomerulonephritis (red cell cast), chronic glomerulonephritis (waxy cast), nephrosis (fatty cast), amyloidosis (waxy cast). Hyaline casts indicate mild renal damage, epithelial casts indicate active acute nephritis. |
| | DISCUSSION: | All casts indicate some degree of kidney damage except hyaline casts, and they generally have less pathological significance than granular or cellular casts. |
| **CHRYSTALS** | NORMAL: | Alkaline Urine — triple phosphate, ammonium urate.<br>Acid Urine — calcium oxalate, sodium urate, uric acid. |
| | DISCUSSION: | Liver damage contains tyrosine and leucine, renal calculi has cystine chrystals, nephritic conditions and lipoidal nephrosis have cholesterol chrystals. |

# BIOCHEMISTRY — URINE

| | | |
|---|---|---|
| **BENCE-JONES PROTEIN (BJP)** | NORMAL: | None. |
| | INCREASED: | Multiple myeloma, metastatic bone tumors, primary bone tumors, chronic leukemias. |
| | DISCUSSION: | BJP's are not present necessarily in all of the beforementioned conditions; however, they are frequently associated with them. This protein is most frequently associated with multiple myeloma. |
| **CREATINE** | NORMAL: | Men: 0-50 mg./24 hrs.<br>Women: 0-100 mg./24 hrs.<br>(higher in pregnant women and children.) |
| | INCREASED: | Muscular disorders such as myasthenia gravis, muscular atrophy, anterior poliomyelitis, amyothrophic lateral sclerosis, diffuse myostitis, hepatic carcinoma, hyperthyroidism, low carbohydrate diet. |
| | DISCUSSION: | In the normal physiology of muscle metabolism, creatine must be present. It is seen in small amounts in the urine of normal adults who are on a normal diet. Creatinuria may be seen occasionally following heavy exercise or in any of the pathological processes listed above. |
| **CREATININE** | NORMAL: | 15-25 mg./kg. of body weight/24 hrs. |
| | INCREASED: | Diabetes, pneumonia, tetanus, high fevers. |
| | DECREASED: | Muscular dystrophy, anemia, leukemia and advanced nephritis. |
| | DISCUSSION: | Serum creatinine and urinary creatinine levels parallel one another. |
| **CREATININE TOLERANCE TEST** | NORMAL: | 110-150 ml./min. per 1.73 $m^2$ of the body surface area. |
| | DISCUSSION: | This test is important in determining and evaluating kidney function. Creatinine daily excretion is extremely constant in normal individuals. This fact enables one to evaluate any abnormal level of its excretion. |
| **DIAGNEX BLUE** | NORMAL: | Greater than 0.6 mg. Azure A. |
| | DECREASED: | Hypochlorhydria and achlorhydria. |
| | DISCUSSION: | This test is to determine the presence or absence of free HCL in the stomach. |

| | | |
|---|---|---|
| **QUANTITATIVE CALCIUM** | NORMAL: | LOW CALCIUM DIET — Less than 115 mg./24 hrs.<br>NORMAL DIET — Less than 250 mg./24 hrs. |
| | INCREASED: | Hyperparathyroidism, hyperthyroidism, metastatic carcinoma, multiple myeloma, hypervitaminosis D, Paget's disease. |
| | DECREASED: | Hypoparathyroidism, hypothyroidism, osteomalacia, renal rickets, nephritis. |
| | DISCUSSION: | A significant amount of calcium is normally found in the urine. The normal serum level is well above the renal threshold. Therefore, precise urinary calcium measurement could indicate the severity of a disease process involving calcium. This finding should be correlated with the serum calcium levels. |
| **MAGNESIUM** | NORMAL: | 0.1-0.2 gms./24 hrs. |
| | DISCUSSION: | Magnesium is essential in the functional integrity of the neuromuscular system. High concentrations act upon the central nervous system as a neuromuscular depressant. |
| **POTASSIUM** | NORMAL: | 25-100 milliequivalents/24 hrs. |
| | INCREASED: | Adrenal cortical hyperactivity, adrenal corticotropic hormone therapy, increased oral or parenteral intake. |
| | DECREASED: | Decreased intake, decreased glomerular filtration, adrenal insufficiency. |
| | DISCUSSION: | In carbohydrate metabolism, potassium is essential. Also, potassium is the chief intracellular cation. There appears to be a reciprocal relationship in all body fluids between sodium and potassium. Sodium seems to exert the controlling influence. Therefore, when sodium levels rise, potassium is excreted. |
| **SODIUM** | NORMAL: | 110-milliequivalents/24 hrs. |
| | INCREASED: | Increased intake, decreased tubular absorption, adrenal insufficiency, diuretics. |
| | DECREASED: | Insufficient intake, excessive perspiration, hypercorticoadrenalism. |
| | DISCUSSION: | Aldosterone causes increased absorption of sodium from the distal tubules. Increased sodium retention may result in increased potassium excretion. |
| **URIC ACID** | NORMAL: | 0.30-0.75 mg./24 hrs. |
| | INCREASED: | Gout (during attack), leukemia, cortisone therapy. |
| | DISCUSSION: | In gout, the urine uric acid is low before an attack and increases during the attack. Uric acid is the end product of purine metabolism and reflects the purine dietary level. |

# BIOCHEMISTRY — BLOOD FILTRATE

| | | |
|---|---|---|
| **NONPROTEIN NITROGEN (NPN)** | NORMAL: | 25-40 mg./100 ml. |
| | INCREASED: | Renal disorders, myocardial infarction, intestinal obstruction. |
| | DECREASED: | Protein malnutrition and severe liver damage. |
| | DISCUSSION: | The NPN's most often measured are creatinine, urea-nitrogen and uric acid. The urea-nitrogen and creatinine usually parallel the NPN. The BUN is more useful as an index of kidney function since all urea-nitrogen is excreted through the kidneys. |
| **BLOOD UREA NITROGEN (BUN)** | NORMAL: | 10-20 mg./100 ml. |
| | INCREASED: | Kidney diseases, dehydration, intestinal obstruction, severe febrile states, uncontrolled diabetes, myocardial infarction, bleeding gastric ulcer, prostatic hypertrophy. |
| | DECREASED: | Acute hepatic insufficiency, protein deficiency, late pregnancy. |
| | DISCUSSION: | Urea is the chief end product of protein metabolism and is produced only in the liver. It is excreted almost entirely by the kidney. The most common cause of an elevated BUN is kidney disease. In general, the BUN level parallels that of the NPN. |
| **BLOOD GLUCOSE** | NORMAL: | 80-110 mg.%. |
| | INCREASED: | Diabetes mellitus, hyperfunction of pituitary, adrenals and/or thyroid glands, severe stress, nephritis. |
| | DECREASED: | Hyperfunction of islet cells, hypofunction of pituitary adrenals or thyroid glands, glycogen storage disease, starvation. |
| | DISCUSSION: | All carbohydrates are broken down to simple sugars before utilization. The majority are converted to glucose which is maintained within narrow limits. This test is most commonly used for diabetes mellitus but can be used for other conditions, also. Many factors affect glucose levels but it is generally true that insulin lowers the blood glucose level by increasing tissue utilization. Hormones of the thyroid, adrenal cortex and pituitary tend to elevate the blood glucose level through their effects on the liver. Post prandial sample is of more value in screening for diabetes mellitus than a fasting specimen. Fasting levels are more useful in determining hypoglycemic states. |

# GLUCOSE TOLERANCE CURVES

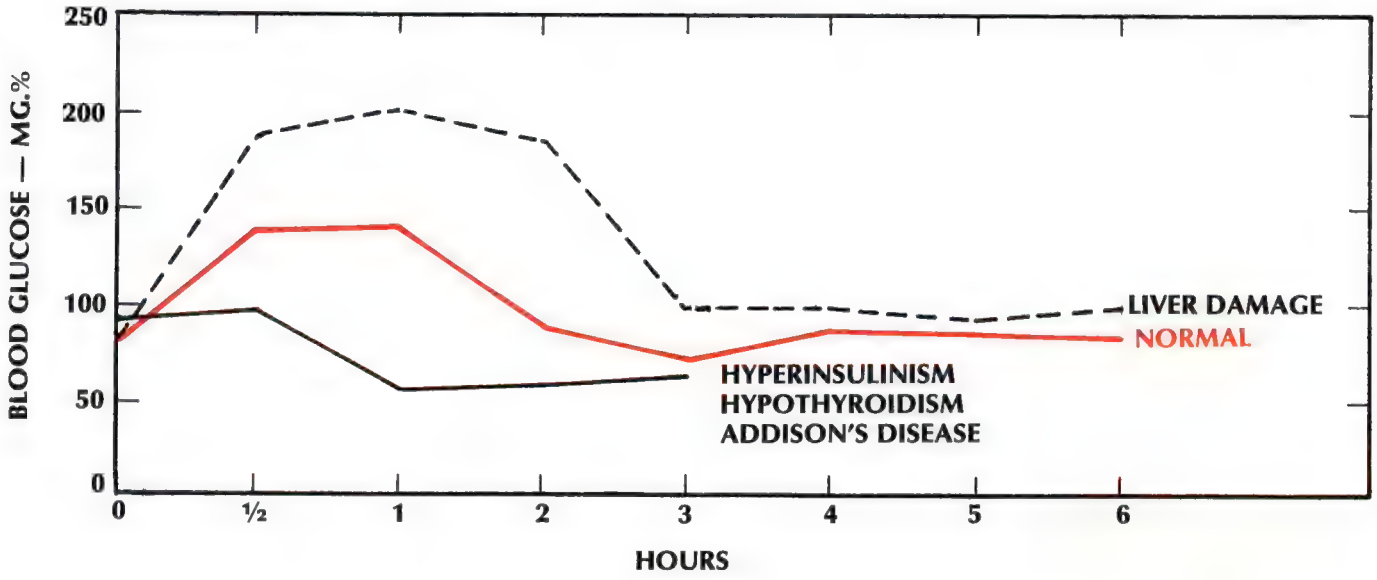


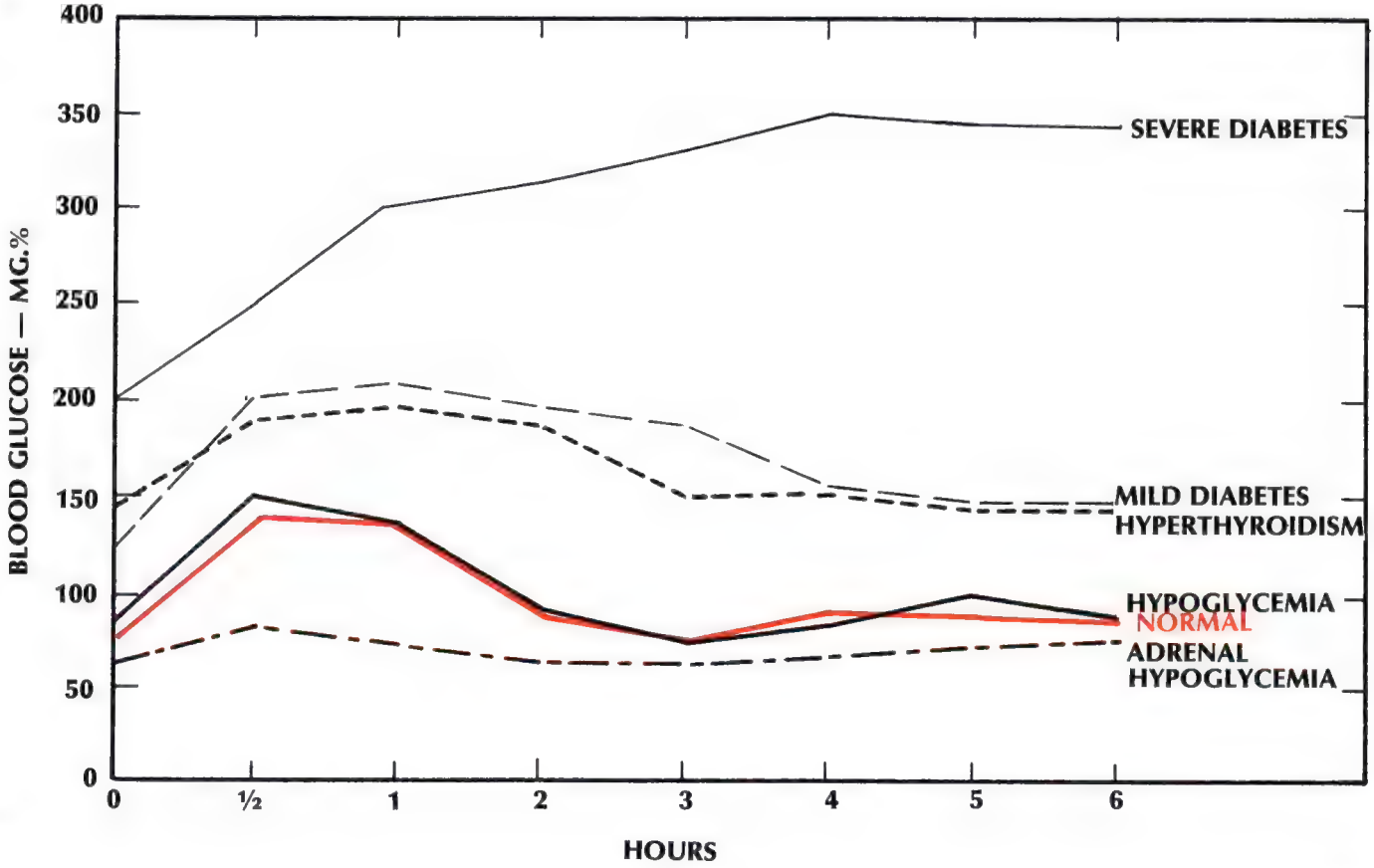

# BLOOD BIOCHEMISTRY

| | | |
|---|---|---|
| **THYMOL TURBIDITY** | NORMAL: | 0-5 units. |
| | INCREASED: | Hepatic cirrhosis, multiple myeloma, lymphogranuloma venereum, lupus erethematosus. |
| | DISCUSSION: | This test is used primarily to detect liver disease and parallels the cephalin flocculation test. |
| **SERUM URIC ACID** | NORMAL: | 3.0 to 7.0 mg.%. |
| | INCREASED: | Gout, renal disorders, leukemia, polycythemia, purine-rich diets. |
| | DISCUSSION: | Aside from gout, this test may be helpful in determining the prognosis of toxemias of pregnancy. |
| **CEPHALIN FLOCCULATION** | NORMAL: | 0-2+/48 hrs. |
| | INCREASED: | Liver disease, myelofibrosis, rheumatoid arthritis, malaria. |
| | DISCUSSION: | This test often becomes positive in hepatitis before jaundice is evident. Many authorities feel that nothing less than 3+ should be considered positive with a 24-hour reliable reading. This test is based upon the ratio of albumin to gamma globulins in the plasma. |
| **SERUM BILIRUBIN** | NORMAL: | Direct — 0.1-0.4 mg./100 ml.<br>Indirect — 0.2-0.7 mg./100 ml.<br>Total — 0.3-1.1 mg./100 ml. |
| | INCREASED: | DIRECT (POST HEPATIC)<br>Complete biliary obstruction due to inflammation, stone, neoplasm or congestive heart failure.<br>INDIRECT (PREHEPATIC)<br>Hemolysis, e.g., hemolytic anemias. Internal hemorrhage, congestive heart failure.<br>DIRECT AND INDIRECT<br>Hepatitis, cirrhosis, viral, toxic. |
| | DECREASED: | Hypochromic microcytic anemia. |
| | DISCUSSION: | The above is important in deciding whether jaundice is hemolytic or obstructive. Bilirubin is the end product of hemoglobin breakdown. Thus, when increased substantially, it is responsible for the various types of jaundice. It is classified as indirect or prehepatic and direct or posthepatic. This classification is based upon being either water soluble or insoluble in the laboratory. |
| **MUCOPROTEIN** | NORMAL: | Male — 45-117 mg.%.<br>Female — 49-103 mg.%. |
| | INCREASED: | Rheumatoid arthritis, ankylosing spondylitis, infections, carcinomatosis. |
| | DISCUSSION: | This is the colormetric test of serum mucoprotein. |

# BLOOD BIOCHEMISTRY — ELECTROLYTES

| | | |
|---|---|---|
| **SERUM CHLORIDES** | NORMAL: | 340-380 mg.%. |
| | INCREASED: | Hyperventilation, nephrosis, urinary obstruction. |
| | DECREASED: | Hypoventilation, adrenal cortical hypofunction, nephritis. |
| | DISCUSSION: | Chloride is the principal anion found in serum. Serum chloride concentration usually varies inversely with that of bicarbonate. Therefore, increased chlorides are commonly associated with acidosis and decreased chlorides are commonly associated with alkalosis. |
| **SERUM SODIUM** | NORMAL: | 310-340 mg.%. |
| | INCREASED: | Dehydration, diabetic coma. |
| | DECREASED: | Addison's disease, metabolic acidosis, diarrhea, diabetes mellitus, severe burns. |
| | DISCUSSION: | Sodium is the most abundant cation in the extracellular fluid. Its greatest importance is in osmotic regulation of extra-intracellular water balance and in acid base equilibrium. |
| **SERUM POTASSIUM** | NORMAL: | 14-20 mg.%. |
| | INCREASED: | Shock, hypoventilation, hypofunction of adrenal cortex, renal insufficiency. |
| | DECREASED: | Alkalosis, vomiting, diarrhea, hyperfunction of adrenal cortex. |
| | DISCUSSION: | Potassium is the chief ion found in the intracellular fluid. Only small proportions of the total body potassium are contained in the serum, but its proper level is critical. |

# BLOOD BIOCHEMISTRY — ENZYMES

| | | |
|---|---|---|
| **SERUM AMYLASE** | NORMAL: | 80-150 S.U./100 ml. |
| | INCREASED: | Acute pancreatitis, common duct obstruction, mumps, renal insufficiency. |
| | DECREASED: | Liver damage, extensive pancreatic destruction. |
| | DISCUSSION: | Amylase is an enzyme which initiates the digestion of starch. This enzyme is normally present in serum and an increase may be characteristic of acute pancreatitis. |
| **SERUM LACTIC DEHYDROGENASE (LDH)** | NORMAL: | 0-250 I.U. |
| | INCREASED: | Myocardial infarction, pulmonary embolism, leukemia, hepatitis. |
| | DISCUSSION: | Clinically, pulmonary embolism is often characterized by an increased LDH, increased serum bilirubin, with a normal transaminase in patients with cardiac symptoms. LDH is also present in the cerebral spinal fluid and in the gastric juice of patients with stomach cancer. |
| **ACID PHOSPHATASE** | NORMAL: | 1.0-5.0 King-Armstrong Units. |
| | INCREASED: | Prostatic carcinoma, Paget's disease, hyperthyroidism. |
| | DISCUSSION: | The prostate contains the highest concentration of acid phospatase. However, it is usually confined to the gland and this does not contribute to the serum levels. In prostatic carcinoma with osseous metastasis, the substance is released into the blood and lymph, thus being diagnostically important. |
| **ALKALINE PHOSPHATASE** | NORMAL: | 3.0-10 Gutman Units. |
| | INCREASED: | Osteogenic sarcoma, Paget's disease, prostatic carcinoma with osseous metastasis, osteomalacia, hyperparathyroidism, obstructive hepatic jaundice. |
| | DISCUSSION: | Nearly all serum containing increased amounts of alkaline phosphatase is of diagnostic importance and suggests osteoblastic lesions. Lesser elevations may be suggestive of jaundice or common bile duct obstruction. |

| | | |
|---|---|---|
| **SERUM GLUTAMIC PYRUVIC TRANSAMINASE (S-GPT)** | NORMAL: | S-GPT: 5-35 units/ml. |
| | INCREASED: | HEPATITIS<br>S-GPT: 500-2,500 units/ml. |
| | | HEPATIC CIRRHOSIS<br>S-GPT: 20-250 units/ml. |
| | | EXTRAHEPATIC OBSTRUCTIVE JAUNDICE<br>S-GPT: 50-300 units/ml. |
| | DISCUSSION: | This is an enzyme which is capable of transferring the alpha amino group of an amino acid to an alpha keto-acid. Maximum concentrations are found in the liver, kidney and heart. It is also found in the skeletal muscles but to a much lesser degree. The S-GPT is less elevated in myocardial infarction than S-GOT. In liver disease, S-GPT is much more elevated than S-GOT. |
| **SERUM GLUTAMIC OXALACETIC TRANSAMINASE (S-GOT)** | NORMAL: | S-GOT: 5-40 units/ml. |
| | INCREASED: | MYOCARDIAL INFARCTION EFFECT ON S-GOT<br>Onset — Normal.<br>7-9 Hours — Begins to increase.<br>30 Hours — Increases to highest point.<br>4 Days — Normal. |
| | DISCUSSION: | S-GOT is able to transfer the alpha amino group of amino acid to an alpha keto-acid. The main use of this test is in myocardial infarction. It also increases in liver disease. |
| **CREATINE PHOSPHORIC ACID (C.P.K.)** | DISCUSSION: | This is a relatively new test for myocardial infarction. The enzyme was originally found in 1927, but the test has only been available at local laboratories within recent months. This test appears to be the most sensitive and accurate on those patients suspected of myocardial infarction. C.P.K. appears four to six hours after onset of a myocardial infarction and remains for three days at a very high level. |

# BLOOD BIOCHEMISTRY — LIPID FRACTIONATION

| | | |
|---|---|---|
| **TOTAL CHOLESTEROL** | NORMAL: | 150-250 mg.%. |
| | INCREASED: | Hypothyroidism, atherosclerosis, diabetes mellitus, diets which are high in saturated fat. |
| | DECREASED: | Hyperthyroidism, anemias, starvation. |
| | DISCUSSION: | Cholesterol is normally found in all body cells and in the blood plasma. There are wide variations in the plasma levels of normal individuals. Cholesterol is considered diagnostically significant in only a few conditions. |
| **TRIGLYCERIDES** | NORMAL: | 0-250 mg.%. |
| | INCREASED: | Diabetes, hypothyroidism, atherosclerosis, pancreatitis, nephrosis, primary hyperlipidemia. |
| | DISCUSSION: | Triglyceride concentrations may change quite readily. Therefore, triglyceride studies should include lipids. In patients with coronary artery disease, triglycerides were more frequently elevated than cholesterol. A definite link has been established between faulty lipid metabolism and cardiovascular disease. |
| **PRIMARY HYPERLIPIDEMIA** | CLASSIFICATIONS: | 1. ELEVATED CHYLOMICRA (Rare)<br>Findings: Elevated triglycerides, normal cholesterol, no carbohydrate sensitivity, fat sensitivity.<br>2. ELEVATED BETA LIPOPROTEINS<br>Findings: Normal triglycerides, elevated cholesterol, no carbohydrate sensitivity, fat sensitivity.<br>3. ABNORMAL BETA LIPOPROTEINS<br>Findings: Elevated triglycerides, elevated cholesterol, carbohydrate sensitivity, fat sensitivity.<br>4. ELEVATED PRE-BETA LIPOPROTEINS<br>Findings: Elevated triglycerides, normal or elevated cholesterol, carbohydrate sensitivity, no fat sensitivity.<br>5. ELEVATED CHYLOMICRA AND PRE-BETA LIPOPROTEINS<br>Findings: Elevated triglycerides, elevated cholesterol, carbohydrate sensitivity, fat sensitivity. |

# SEROLOGY

| | | |
|---|---|---|
| **ANTISTREPTOLYSIN-O-TITER (ASO, ASTO)** | NORMAL: | 50 Todd Units or less. |
| | INCREASED: | Acute rheumatic fever, acute glomerulonephritis, streptococcus infections. |
| **C-REACTIVE PROTEIN (CRP)** | NORMAL: | None. |
| | INCREASED: | Rheumatic fever, myocardial infarction, rheumatoid arthritis, lupus erythematosus. |
| | DISCUSSION: | The above test is not specific for any one disease. However, inflammatory reaction of a bacterial or nonbacterial nature may cause the formation of C-reactive protein. |
| **RHEUMATOID ARTHRITIS (RA)** | NORMAL: | Nonreactive. |
| | INCREASED: | Rheumatoid arthritis. |
| | DISCUSSION: | The existence of the rheumatoid factor has been well demonstrated but its exact nature is still not well understood. However, simply stated, the rheumatoid factor is an abnormal substance found in the serum of a large percentage of patients with rheumatoid arthritis. |
| **HETEROPHIL ANTIBODY** | NORMAL: | None. |
| | INCREASED: | Infectious mononucleosis. |
| | DISCUSSION: | Heterophil agglutinins are antibodies which are increased in the serum of individuals with infectious mononucleosis. |
| **FLORESCENT TREPONEMAL ANTIBODIES (FTA)** | NORMAL: | Nonreactive. |
| | INCREASED: | Syphilis. |
| | DISCUSSION: | This test is fast becoming the most popular clinical lab test performed on suspected syphilitic patients. It is also used to verify positive VDRL. |
| **VDRL** | NORMAL: | Nonreactive. |
| | REACTIVE: | Syphilis. |
| | FALSE POSITIVE: | Rheumatoid arthritis, lupus erythematosus, periarteritis nodosa, malaria, leprosy, infectious mononucleosis. |
| | DISCUSSION: | The VDRL test is based upon a precipitation reaction between a nonspecific beef heart antigen and a reagin present in the syphilitic serum. |

# ENDOCRINOLOGY

| | | |
|---|---|---|
| **CHORIONIC GONADOTROPHIN** | NORMAL: | None. |
| | INCREASED: | Pregnancy. |
| | DISCUSSION: | Chorionic gonadotrophic hormones are found in the urine approximately one week after the first missed period. Therefore, if this hormone elevates, it is indicative of pregnancy. Abnormally high values may be present in certain pathological conditions such as hydatidiform mole and placental malignancies. |
| **PROTEIN-BOUND IODINE (PBI)** | NORMAL: | 4.0-8.0 mcg.%. |
| | INCREASED: | Hyperthyroidism, early hepatitis, acromeglia. |
| | DECREASED: | Hypothyroidism, cretinism, myxedema, nephrosis. |
| | DISCUSSION: | Today, this test is usually performed in conjunction with T-4 or T-3. The amount of protein-bound iodine correlates directly with the level of the circulating thyroxin in the plasma, and this is the rationale for the test. |
| **TRI-IODOTHYRONINE (T-3)** | NORMAL: | 25-35%. |
| | INCREASED: | Hyperthyroidism, congestive heart failure, nephrosis. |
| | DECREASED: | Hypothyroidism. |
| | DISCUSSION: | This test utilizes $I^{131}$, labeled as T-3, and is added to the patient's blood sample. Therefore, by using the patient's blood sample, it does not necessitate injecting $I^{131}$ into the patient's body. The radioactive $I^{131}$ readily combines with the thyroid-binding globulin (TBG) that is not already saturated with thyroxine. In cases of hypothyroidism, much of the TBG will be unattached with the hormone due to the deficiency of its production. Thereby, a large amount of the T-3 will combine with the unattached TBG molecule. Interpretation of the test is based upon the measurement of the remaining T-3 which is taken up by the plasma. The plasma is occasionally referred to as the secondary binding substance and sometimes resin is used for this purpose. |
| **THYROXINE BY RADIOASSAY (T-4)** | NORMAL: | 3.4-11.2 mg./ml. |
| | INCREASED: | Hyperthyroidism, hepatitis. |
| | DECREASED: | Hypothyroidism, cretinism, myxedema, nephrosis. |
| | DISCUSSION: | This test measures the actual physiological thyroxine level in the serum. Therefore, it offers an advantage over the PBI. However, the T-4 test does not replace the T-3. The T-4 and T-3 combined provide a more adequate measurement of the functioning of the thyroid than either one individually. |

| | | |
|---|---|---|
| **17-KETOSTEROIDS, TOTAL NEUTRAL** | NORMAL: | Male — 7.0-20.0 mg./24 hrs.<br>Female — 5.0-15.0 mg./24 hrs. |
| | INCREASED: | Testicular tumors, interstitial cell tumors, adrenal hyperplasia, Cushing's syndrome, adrenal tumors and malignancies. |
| | DECREASED: | Addison's disease, hypopituitarism, hypo-adrenalism, hypogonadism, myxedema. |
| | DISCUSSION: | 17-ketosteroids are the end products of androgenic hormone production of the testes and the adrenal cortex, and, therefore, are excreted in the urine. The amounts are easily measured if one suspects abnormal function of the adrenal cortex or testes. This test is one of the most useful endocrine assays available. |
| **TOTAL AND FRACTIONATED ESTROGENS** | NORMAL: | Male — 4.0-25 mcg./24 hrs.<br>Female — 4.0-60.0 mcg./24 hrs. |
| | INCREASED: | Adrenocortical tumors, ovarian tumors, tumors of the testes. |
| | DECREASED: | Primary and secondary amenorrhea, pituitary dwarfism. |
| | DISCUSSION: | Estrogen excretion in men, children and post menopausal women is primarily from the adrenals. Figures on these excretion ratios are accurate. |

# TOXICOLOGY

| | | |
|---|---|---|
| **BARBITURATES TEST** | NORMAL: | None. |
| | INCREASED: | Barbiturate intake. |
| | DISCUSSION: | Quite frequently, patients who have ingested large quantities of prescribed barbiturates will come to a D.C.'s office for treatment. The ingestion of these barbiturates will often change the patient's physical response, as well as the symptomatic picture. Occasionally, it is advisable to run this test on a patient who has been on barbiturates for a long period of time in order to clarify why he may be reacting as he is (withdrawal symptoms can confuse the original symptomatic picture). |
| **SULFONAMIDES** | NORMAL: | None. |
| | INCREASED: | Sulfonamide therapy. |
| | DISCUSSION: | Quite frequently, patients who have ingested large quantities of prescribed sulfonamides will come to a D.C.'s office for treatment. The ingestion of these sulfonamides will often change the patient's physical response, as well as the symptomatic picture. Occasionally, it is advisable to run this test on a patient who has been on sulfonamides for a long period of time in order to clarify why he may be reacting as he is (withdrawal symptoms can confuse the original symptomatic picture). |
| **BROMIDES** | NORMAL: | 1-2 mg.%. |
| | DISCUSSION: | Bromides are very difficult for a body to eliminate, and the cumulative effect upon the body can cause toxicity and produce symptoms. A patient who has been taking large amounts of bromides can increase his chloride intake and hasten the bromide excretion. In some cases of schizophrenia, the cause has been attributable to many of the over-the-counter nerve tonics containing bromides which are available in drug stores without prescriptions. Bromide toxicity appears to be directly related to many cases of schizophrenia. |
| **SALICYLATES** | NORMAL: | None. |
| | INCREASED: | Salicylate therapy. |
| | DISCUSSION: | Salicylate intoxication is becoming a more frequently encountered term and condition seen in general practice. Spontaneous hemorrhage is often a cardinal sign of salicylate toxicity. |
| **FLUORIDE** | NORMAL URINARY OUTPUT: | 0.4-1.0 mg. |
| | DISCUSSION: | Research has revealed that the fluoride ions can severely inhibit glycolysis. A lethal dose is 5 grams. Chronic intoxication results in structural alterations of the bones and teeth. |

# CULTURES AND SENSITIVITIES

Cultures and sensitivities can be ordered for any dermatological condition or substance secreted through any of the body cavities, e.g., vaginal, oral, etc. It is often advisable for a doctor to run a culture and a sensitivity upon a discharge of an oral surface or have a culture performed on a dermatological condition in order to determine the etiological agent. Sensitivities are frequently requested to determine what antibiotic would be recommended, especially if the doctor is considering referring the patient.

It is not within the scope of this manual to outline all the possible cultures that are available. However, it is important to review the findings of a stool culture, which is being examined more frequently today than ever before.

| | | |
|---|---|---|
| **STOOL CULTURE** | ORDINARILY NON-PATHOGENIC: | Escherichia coli, aerobacter aerogenes, paracolon, alcaligenes, clostridium welchii and clostridium tetani on occasion. |
| | PATHOGENIC: | Pseudomonas aeruginosa, staphylococci coagulase, proteus vulgaris, salmonella group, shigella group, vibrio comma. |
| | DISCUSSION: | Because of the increased indiscriminate use of broad spectrum antibiotics, this has caused an increased number of staphylococcal infections by disturbing the normal bacterial balance. It is difficult to classify intestinal bacteria today as being either pathogenic or non-pathogenic because of the lowered natural resistance present in many of the patients we see. |

# DISEASES AND LABORATORY FINDINGS

This section has been added to the manual in the interest of the busy practitioner.

Frequently encountered disorders are listed alphabetically by disease, along with the respective laboratory tests. However, all cancer, heart and kidney disorders or disorders related to these organs may be found at the end of the section listed alphabetically under these respective organs.

Only the minimum number of tests are listed for each disease, and in some cases only those findings which are peculiar to that particular disease are listed.

| | | |
|---|---|---|
| **ALLERGIES** | INCREASED: | Blood eosinophils. |
| **ACUTE APPENDICITIS** | INCREASED: | Blood: Neutrophils (left shift).<br>Urine: Leukocytes, erythrocytes. |
| **ASTHMA** | INCREASED: | Blood: Eosinophils.<br>Sputum: Eosinophils, Curschmann's spirals, charcot-leyden crystals. |
| **ATHEROSCLEROSIS** | INCREASED: | Blood: Glucose, Uric Acid, Cholesterol, Triglycerides, Lipoprotein. |
| | DECREASED: | Blood: Glucose. |
| | DISCUSSION: | Blood glucose may be increased or decreased depending upon the patient's age, height, weight and dietary background. |
| **BRONCHIECTASIS** | INCREASED: | Blood: Erythrocytes.<br>Sputum: Bacteria (should be cultured). |
| **COLITIS** | INCREASED: | Stool: Blood, pus cells, mucus.<br>Blood: Erythrocyte sedimentation rate, neutrophils. |
| | DECREASED: | Blood: Erythrocytes, possible hypochromic microcytic anemia.<br>Serum: Protein. |
| | DISCUSSION: | One must keep in mind that the acuity and chronicity will affect the laboratory findings. For example, the ESR and the neutrophil count is usually increased in the acute phase, while the anemia and decreased serum protein will tend to occur in the chronic phase. |
| **HEPATIC CIRRHOSIS** | INCREASED: | Serum: Bilirubin, cephalin flocculation, alkaline phosphatase, prothrombin time, gamma globulin fraction, SGOT, SGPT.<br>Urine: Aldosterone. |
| | DECREASED: | Serum: Albumin, plasma fibrinogen, glucose tolerance, cholesterol esters.<br>Blood: Erythrocytes, zinc.<br>Urine: Zinc. |
| **CYSTITIS** | INCREASED: | Urine: Pus cells, erythrocytes, bacteria, mucus. |
| **DIABETES MELLITUS** | INCREASED: | Blood: Glucose, post prandial glucose fasting.<br>Urine: Specific gravity, glucose, acetone.<br>Serum: Cholesterol. |
| | DECREASED: | Serum: Insulin. |

| | | |
|---|---|---|
| **DIPHTHERIA** | INCREASED: | Nasopharyngeal<br>Exudate: Corynebacterium diphtheria.<br>Blood: Neutrophils. |
| **ERYSIPELAS** | INCREASED: | Blood: Neutrophils, ESR. |
| **GALLBLADDER** | INCREASED: | Serum: Bilirubin, cholesterol.<br>Blood: ESR. |
| **GONORRHEA** | INCREASED: | Urine: Pus cells.<br>Urethreal<br>Exudate: Gonococci positive. |
| **GOUT** | INCREASED: | Serum: Uric acid.<br>Blood: Neutrophils, ESR.<br>Urine: Uric acid. |
| **VIRAL HEPATITIS** | INCREASED: | Serum: SGPT, SGOT, bilirubin (direct and indirect), BSP, cephalin flocculation, thymo-turbidity, gamma globulin.<br>Blood: ESR.<br>Urine: Bilirubin, Protein. |
| | DECREASED: | Serum: Cholesterol esters, albumin and globulin ratio. |
| | DISCUSSION: | The BSP, cephalin flocculation, urinary bilirubin and sedimentation rate may be increased before jaundice is evident. |
| **INFECTIOUS MONONUCLEOSIS** | INCREASED: | Serum: Heterophil antibodies.<br>Blood: Lymphocytes. |
| | DECREASED: | Blood: Granulocytes. |
| **INTESTINAL OBSTRUCTION** | INCREASED: | Plasma: Total proteins, albumin, globulin, fibrinogen.<br>Blood: Uric acid, creatinine, BUN.<br>Serum: Lipase, amylase. |
| | DECREASED: | Serum: Cholesterol, chloride potassium. |
| | DISCUSSION: | Etiology will vary, thus the findings will be dependent upon the initiating cause of the obstruction and its duration. Naturally, the amount of vomiting will determine the electrolyte imbalance. |
| **MUMPS** | INCREASED: | Serum: Amylase. |
| **OSTEOMALACIA** | INCREASED: | Serum: Alkaline phosphatase. |
| | DISCUSSION: | One must consider the degree of parathyroid compensation relative to the serum calcium and phosphorus levels. |
| **OTITIS MEDIA** | INCREASED: | Blood: Neutrophils.<br>Exudate: Culture to determine etiological agent. |
| **OSTEITIS DEFORMANS (Paget's Disease)** | INCREASED: | Serum: Alkaline phosphatase, acid phosphatase occasionally.<br>Urine: Calcium. |

| | | |
|---|---|---|
| **ACUTE PROSTATITIS** | INCREASED: | Blood: Neutrophils, ESR.<br>Urine: Erythrocytes, pus cells. |
| **PYLORIC STENOSIS** | INCREASED: | Blood: Hematocrit.<br>Urine: p.H. |
| | DECREASED: | Serum: Potassium, chloride. |
| **RHEUMATIC FEVER** | INCREASED: | Blood: ESR, leukocytes.<br>Serum: Antistreptolysin-o-titer, C-reactive protein. |
| | DECREASED: | Blood: Erythrocytes. |
| **RHEUMATOID ARTHRITIS** | INCREASED: | Blood: ESR, leukocytes.<br>Serum: RA test, C-reactive protein, alpha and gamma globulin. |
| | DECREASED: | Blood: Erythrocytes, hemoglobin. |
| | DISCUSSION: | Hypochromic anemia is frequently seen in rheumatoid arthritis. |
| **RUBEOLA** | INCREASED: | Urine: Protein. |
| | DECREASED: | Blood: Leukocytes. |
| **MALE STERILITY** | INCREASED: | Seminal Fluid: Abnormalities of sperm, either qualitative or quantitative. |
| | DECREASED: | Seminal Fluid: Sperm count. |
| **SYPHILIS** | INCREASED: | Serum: FTA, VDRL. |
| **TESTICULAR TUMORS** | INCREASED: | Urine: 17-ketosteroids, chorionic gonadotrophins, estrogen. |
| **TETANUS** | INCREASED: | Urine: Creatinine.<br>Blood: Neutrophils. |
| **THYROID HYPERFUNCTION (Thyrotoxicosis)** | INCREASED: | Blood: Glucose, lymphocytes.<br>Serum: T-4, PBI, T-3, magnesium, TSH.<br>Urine: Glucose, calcium, creatinine. |
| | DECREASED: | Blood: Glucose tolerance.<br>Serum: Cholesterol. |
| **THYROID HYPOFUNCTION** | INCREASED: | Blood: Glucose tolerance test.<br>Serum: C-reactive protein, cholesterol, carotene, TSH. |
| | DECREASED: | Blood: Erythrocytes.<br>Serum: T-3, T-4, TSH, magnesium, PBI. |
| **RINGWORM (Tinea)** | DISCUSSION: | Must be cultured from scrapings of the hair, skin or nails. |
| **DUODENAL ULCER** | INCREASED: | Stool: Occult blood.<br>Gastric Contents: Occult blood, hydrochloric acid. |
| | DECREASED: | Blood: Erythrocytes. |

| | | |
|---|---|---|
| **GASTRIC ULCER** | DISCUSSION: | As in the duodenal ulcer, hypochlorhydria may be the most characteristic finding. Many authorities consider achlorhydria in a gastric ulcer to be directly associated with carcinoma of the same organ. |
| **URETHRITIS** | INCREASED: | Urine: Erythrocytes, pus cells, culture for etiological agent. |
| **VON GIERKE'S DISEASE (Glycogen Storage Disease)** | INCREASED: | Urine: Acetone. |
| | DECREASED: | Blood: Glucose tolerance test (similar to the diabetic curve).<br>Urine: p.H.<br>Serum: Glucose-6-phosphate dehydrogenase. |

## DISEASES AND LABORATORY FINDINGS
## — CANCER —

| | | |
|---|---|---|
| **DIFFUSE CANCER** | INCREASED: | Serum: Lactic dehydrogenase, mucoprotein. |
| **ACUTE LEUKEMIA** | INCREASED: | Blood: Leukocytes, aurer bodies.<br>Serum: Uric acid. |
| | DECREASED: | Blood: Erythrocytes, thrombocytes. |
| **CHRONIC LEUKEMIA** | INCREASED: | Blood: Leukocytes, thrombocytes.<br>Serum: Uric acid. |
| | DISCUSSION: | Any one or more of the leukocytic series may be involved in leukemia, but the neutrophils and lymphocytes are most commonly affected. Acute leukemia differs characteristically from chronic leukemia in that many immature blast forms are seen in acute leukemia, while in the chronic leukemia the maturity is varied. |
| **MULTIPLE MYELOMA** | INCREASED: | Blood: Plasma cells.<br>Urine: Bence-Jones protein, calcium.<br>Plasma: Total protein, fibrinogen, globulin.<br>Serum: Calcium, alkaline phosphatase. |
| | DECREASED: | Blood: Prothrombin, erythrocytes.<br>Serum: Albumin. |
| **PROSTATIC CARCINOMA** | INCREASED: | Serum: Acid phosphatase, alkaline phosphatase only with metastasis.<br>Urine: Pus cells, erythrocytes. |
| | DECREASED: | Blood: Erythrocytes. |
| **OSTEOGENIC SARCOMA** | INCREASED: | Urine: Bence-Jones protein.<br>Serum: Alkaline phosphatase. |
| **STOMACH CARCINOMA** | INCREASED: | Stool: Occult blood. |
| | DECREASED: | Gastric Contents: Achlorhydria.<br>Blood: Erythrocytes. |

# DISEASES AND LABORATORY FINDINGS
## — HEART —

| | | |
|---|---|---|
| **PULMONARY EMPHYSEMA** | INCREASED: | Blood: Erythrocytes, hematocrit. |
| **MALIGNANT HYPERTENSION** | INCREASED: | Urine: Protein, casts, erythrocytes.<br>Serum: BUN, creatinine. |
| | DECREASED: | Blood: Erythrocytes. |
| | DISCUSSION: | Many conditions mimick malignant hypertension such as thyrotoxicosis, pheochromocytoma, kidney disease and vascular abnormalities. |
| **MYOCARDIAL INFARCTION** | INCREASED: | Blood: Leukocytes, neutrophils, ESR.<br>Serum: SGOT, SGPT, lactic acid dehydrogenase, C-reactive protein, CPK. |
| **PULMONARY EMBOLISM** | INCREASED: | Blood: ESR, neutrophils.<br>Serum: Lactic dehydrogenase, bilirubin (indirect). |
| | DISCUSSION: | A clinical finding of an increased lactic acid dehydrogenase without a significant increase in the serum transamynases (SGOT, SGPT) is evidence favoring pulmonary embolism rather than myocardial infarction. Also check CPK. |
| **SUBACUTE BACTERIAL ENDOCARDITIS** | INCREASED: | Serum: BUN, globulin.<br>Blood: ESR, leukocytes, streptococcus viridans (positive culture).<br>Urine: Casts, protein, erythrocytes. |
| | DECREASED: | Blood: Erythrocytes. |

# DISEASES AND LABORATORY FINDINGS
## — KIDNEY —

| | | |
|---|---|---|
| **GLOMERULONEPHRITIS** | INCREASED: | Urine: Albumin, erythrocytes, leukocytes.<br>Serum: Antistreptolysin-o-titer. |
| | DECREASED: | Urine: PSP (phenolsulfonphthalein).<br>Serum: Albumin. |
| | DISCUSSION: | PSP may be decreased in either the acute or chronic phase, depending upon the functional impairment of the kidneys. The ASO-titer is usually elevated only in the acute phase. |
| **NEPHROSIS (Nephrodic Syndrome)** | INCREASED: | Urine: Protein, epithelial cells, casts (waxy and fatty), cholesterol chrystals.<br>Serum: Globulin, phospholipids, cholesterol. |
| | DECREASED: | Serum: Calcium, total protein, gamma globulin, albumin.<br>Blood: Erythrocytes. |
| **RENAL CALCULI** | INCREASED: | Urine: Chrystals (uric acid, cystine, etc.), erythrocytes. |
| | DISCUSSION: | The kinds of chrystals present in the urine might indicate the type of stone present. One might also find signs of infection present. |
| **KIDNEY UREMIA (See Glomerulonephritis)** | INCREASED: | Urine: Casts, erythrocytes, pus cells, protein.<br>Serum: BUN, uric acid, creatinine, phosphorus, potassium. |
| | DECREASED: | Urine: p.H., specific gravity.<br>Serum: Calcium, sodium.<br>Blood: Erythrocytes. |

# LABORATORY SURVEYS BY SYMPTOMS

| | |
|---|---|
| ABDOMINAL PAINS (SEVERE) | WBC and Differential, Urinalysis, CBC, ESR, C-reactive Protein Amylase, Lipase, Liver Profile. |
| CHEST PAINS | CPK, SGOT, SGPT, LDH, ESR, CBC, Amylase, Lipase. |
| CONSTIPATION | Urine Indican, ESR, Diagnex Blue. |
| DERMATITIS (NON-SPECIFIC) | CBC, VDRL, Urinalysis. |
| DIZZINESS | Fasting Blood Sugar, CBC, C-reactive Protein, BUN, Urinalysis, Atherosclerotic Profile. |
| FATIGUE AND WEAKNESS | CBC, ESR, Mononucleosis, C-reactive Protein. |
| HEADACHES (ACUTE) | CBC, BUN, C-reactive Protein, ESR. |
| HEARING DISORDERS | CBC, Atherosclerotic Profile. |
| INDIGESTION | Urinalysis, ESR, Liver Profile, Diagnex Blue, Serum Amylase, Serum Lipase, Alkaline Phosphatase. |
| LOW BACK INSTABILITY IN MALES (CHRONIC) | Urinalysis, Prostatic Profile, ESR, C-reactive Protein. |
| OCULAR DISTURBANCES | Fasting Blood Sugar, CBC, ESR. |

# CHAPTER VIII

# COMMON DISORDERS & TREATMENT TECHNIQUES

## ILEOCECAL VALVE SYNDROME

The ileocecal valve separates the small and large intestine. There are two types of muscles which form the valve. The circular or sphincter muscles close the valve, and the longitudinal or labial muscles open it. Material in the small intestine only moves in one direction. However, the contents of the large intestine can move forward or backward within the large intestine. If the ileocecal valve becomes incompetent, material may pass from the large intestine to the small intestine and will then become highly toxic to the body. Many researchers also feel that gas pressure builds in the colon and forces the valve open which can result in toxicity. The colon, which is relatively nonabsorbent, passes its contents by peristaltic action through an incompetent ileocecal valve into the highly absorbent ileum. This material is then reabsorbed in the blood and circulated to the various points in the body which can result in a diversity of symptoms. This condition is referred to as an ileocecal valve syndrome or an open ileocecal valve syndrome or an incompetent ileocecal valve syndrome. The valve normally operates like a subway turnstile, but in many individuals it operates like a pair of swinging doors, which is obviously to the detriment of the patient.

### SYMPTOMS

An ileocecal valve syndrome may be characterized by shoulder pain, sudden low back pain, chest pain, heart fluttering (palpitations), dizziness, bursitis-like pain in the shoulders or hip joints, spontaneous sacroiliac syndrome in the absence of trauma, ringing in the ears, nausea, light-headedness, recurrent sinus infections, hypochlorhydria and headaches. People with ileocecal valve involvement commonly make statements such as, "I just bent over and it hit me right here" (indicating the lower back), "I reached up and I felt like I had broken off my arm" (indicating the shoulder), or "I was fine until I bent over and just couldn't get up" (indicating the lower back). Holiday overeating and emotional trauma are common causes of the ileocecal valve syndrome.

The stool of a patient suffering from ileocecal valve involvement may be in a ribbon form or in small balls. Constipation may be present in some cases. Most enemas and colonic irrigations are contraindicated; however, after a bowel movement, a slow, saline enema with cold water will often result in tonification of the bowels and elimination of the morning backache, which is also a symptom of this condition.

The pH of the bowel and saliva are also indications to ileocecal valve functioning. Normally, the pH of the saliva should be 7.8 and the pH of the stool should be 6.8 to 7.0. When the stool is acidulous, it will cause the colon to lose tone and results in the ileocecal valve becoming spastic. When the stool is too alkaline, the colon becomes spastic, and, as a result, also causes valve malfunction in the form of incompetence. Therefore, the pH is an important indicator of the acid-alkaline balance of the colon and ileocecal valve function.

Potatoes, vegetables, fruit, butter, cream, fats and oils increase the alkalinity of the saliva. Cereals, breads, cake, all grains, meat, fish, eggs and cottage cheese decrease the alkalinity of the saliva.

The ileocecal valve syndrome is responsible for approximately 40 percent of all acute cases treated in Chiropractic offices.

The valve can be therapy localized by placing the patient in a supine position and using a strong indicator muscle, such as the psoas or piriformis. Ask the patient to place fingertips from both hands (positive and negative surfaces) halfway between the umbilicus and the anterior superior iliac spine on the right. Then, retest the indicator muscle. If the strong indicator muscle becomes weak, an ileocecal valve syndrome is present. Differential diagnosis between the spastic form or the open form of the ileocecal valve syndrome would then have to be performed.

# ILEOCECAL VALVE CHALLENGE AND CORRECTION

The ileocecal valve syndrome may be acute or chronic and may result from open or closed valve involvement. One must challenge the valve to determine its position following positive therapy localization to make the proper differential diagnosis.

The spastic (closed) ileocecal valve is different from the open ileocecal valve in that there is no garbage material regurgitation. In the spastic ileocecal valve condition, all the waste material stays in the small intestine, thus putrification ensues, and can result in many symptoms. A classic symptom of the spastic ileocecal valve syndrome is that the patient feels better the longer he is up. He doesn't feel rested upon arising, but as the day wears on, the better he feels.

To challenge for ileocecal valve syndrome, contact the abdomen with both hands halfway between the umbilicus and the anterior superior iliac spine on the right. Gently push the valve posteriorly and slightly toward the left shoulder. Hold that position for approximately 30 to 45 seconds. If this challenge results in increasing the strength of an indicator muscle which previously tested weak, it would indicate the presence of an open ileocecal valve.

The flexed knee test, which actually tests the iliacus muscle, will also indicate the presence of an open ileocecal valve syndrome. It is performed by placing the patient in a prone position with the right knee bent. Contact the lateral malleolus, and push the right leg medially against the patient's resistance (performed just opposite to the piriformis test). Weakness of the iliacus muscle on the right indicates an ileocecal valve involvement. (This test must be performed on the right side only.)

The spastic ileocecal valve syndrome is sometimes referred to as the closed ileocecal valve syndrome. To challenge, gently press posteriorly over the valve. A weak indicator muscle will become strong. Frequently accompanying the spastic ileocecal valve is a weak right rectus abdominus and a weak quadriceps on the same side. Overactivity of the kidney meridians is also seen in this condition, which results in hypertonicity of the iliacus and psoas muscles.

After the ileocecal valve has been successfully challenged and one has determined the line of correction, then adjust the valve in the same direction that produced a successful challenge. One may treat the valve using a simple stretch reflex by contacting the area with the fingers, pulling or pushing it gently in the direction of the successful challenge and holding for a pulsation (approximately 30 seconds).

Following correction, be sure to retherapy localize to verify correction. Then therapy localize the neurolymphatics for the ileocecal valve syndrome and treat accordingly based upon therapy localization. The neurolymphatics are medial to the iliacus muscle on the right, anterior one-third of the right humerus, on the lamina of the third cervical right side only. A frequent cranial fault which accompanies the ileocecal valve is the temporozygomatic cranial fault. (See Cranial Faults.) Therapy localize to see if this cranial fault is present. The cranial stress center of the ileocecal valve should also be therapy localized and treated if necessary. (See Cranial Stress Centers.) It is located one-half inch laterally to the posterior occipital protruberance.

Following correction and treatment of these structures, therapy localize the spine for subluxations and fixations. In the open ileocecal valve syndrome, L-1 is frequently subluxated, as is its Lovett Reactive Vertebra, C-5. In the spastic ileocecal valve syndrome, a frequent subluxation is L-3 and also C-3, its Lovett Brother. In both cases, be sure to therapy localize L-5 and C-1 in addition to the sacrum and occiput. Naturally, subluxations can occur at any level in the spine, but the above are the most frequent locations. Often, spinal fixations occur in the lower cervical, upper dorsals and upper lumbars. Reflex subluxations in the same locations as the fixations will also return until the valve syndrome is corrected.

From a nutritional standpoint, most open valve syndrome patients frequently require acidifying the bowel with betaine hydrochloride or sometimes lactic acid yeast. Generally, chlorophyll is also helpful. In spastic ileocecal valve patients, calicum orotate or calcium-free phosphorus, in addition to betaine and vitamins B and G is beneficial. In either the spastic or open valve conditions, the patient's nutritional needs can be determined by muscle testing. (See Nutrition and Applied Kinesiological Diagnosis and Technique.) The nutrients listed are only those most frequently encountered but, in all cases, each patient should be evaluated individually. In either the open or the spastic valve cases, all roughage and garbage foods should be eliminated from the patient's diet, and the patient should avoid improper carbohydrate intake for at least two weeks. In severe cases of ileocecal valve involvement, the previously described saline enema can be used successfully.

# POSTURAL HYPOTENSION AND FUNCTIONAL HYPOADRENIA

The clinical significance of postural changes in blood pressure often escapes the attention of many doctors. When we stand, all the blood rushes to the lower half of the body due to the effect of gravity. However, the receptors in the aorta and other blood vessels communicate this new position to the nervous system, which causes a redistribution of blood from the splanchnic area to the heart and muscles.

A simple screening test for hypoadrenia takes very little time and measures the body's ability to compensate for the effects of gravity. This test is performed by taking the patient's blood pressure in a recumbent position and in a standing position. The systolic blood pressure is normally 4-10 mm. higher when the patient changes from a supine to a standing position.

Patients who suffer from postural hypotension or functional hypoadrenia often exhibit:

1) Dizziness when changing positions.
2) Morning fatigue after a good night's rest.
3) More energy as the day progresses and sudden fatigue around 7:00 or 8:00 p.m.
4) Momentary headaches when the patient rises to an erect position from a seated or recumbent position.

These patients frequently exhibit a normal blood count, a normal blood sugar level and normal blood pressure when in a seated or recumbent position. However, when they assume an upright position, there can be as much as a 40 mm. drop in the systolic pressure. Any systolic drop is abnormal when the patient changes from a recumbent position to a standing position.

The splanchnic veins are valveless and are dependent upon the autonomic nervous system to control their function. The tone of the splanchnic nerve is controlled by the adrenal system. If the adrenals are weak, they do not provide enough sympathin to control the compensatory mechanism of the splanchnic veins. This same sympathin substance causes the contraction of the pupil to light. In hypoadrenia, the usual contraction of the pupil to light is not sustained. For example, if the examining light is shown on the eye for 30 to 40 seconds, there will be a paradoxical dilation of the pupil to light; or, as is often seen, there will be an alternating contraction and dilation of the pupil while the examining light is kept on the eye for a period of 40 seconds. This finding would be considered a positive Rogoff's Sign and indicates weak adrenals, as well as postural hypotension.

A systolic drop in blood pressure when changing from a recumbent position to a standing position and dilation of the pupil to light are both definite indicators of relative adrenal hypofunction.

Hypoadrenia is often seen with hyperinsulinism (hypoglycemia) and hypocalcemia.

Stress is the biggest cause of adrenal fatigue and this stress may be physical, psychological or nutritional. From a nutritional standpoint, the latest statistics indicate that the average American eats approximately 16.5 pounds of candy annually. Ths type of diet may deplete the adrenals and pancreas. Excessive carbohydrates are contraindicated in this condition. The effects of hypoadrenia and hyperinsulinism are multitudinous. According to Abrahamson who wrote "Body, Mind and Sugar," "The weakest, most vulnerable cells suffer first. These will differ from person to person and from time to time in the same individual; thus, producing the almost infinite variety of hyperinsulinism manifestations in different persons at different times of their lives."

## TREATMENT

Treatment consists of balancing all of the five elements of the intervertebral foramen. Also, the patient should be placed on a hyperinsulinism diet; his carbohydrates should be restricted; and he should be given calcium, betaine hydrochloride, adrenal cytotropic extracts, pancreatic cytotropic extracts, vitamin A and vitamin F. Naturally, the patient's musculature must be balanced.

# ALLERGY TECHNIQUE

Many people suffer from non-specific patterns of irritation of various systems and organs which may be grouped under the general heading of allergy. The symptoms may present themselves in many forms, such as colitis, acute states of diarrhea, paroxysmal tachycardia, asthma, sinusitis, hayfever, eczema, hives, pruritic itching disorders or mucotaneous rectal itch.

Although the category of allergies is broad, all of the above may be considered auto-immune diseases which cause excessive tissue breakdown and subsequent antibiotic formation. This reaction is actually an antibody against one's own body.

The following are common findings in allergy patients and general comments about each pattern:

| FINDING | COMMENTS |
|---|---|
| 1) PECTORALIS MAJOR CLAVICULAR WEAKNESS (BILATERAL OR UNILATERAL). | This can be identified through muscle testing. (See Chapter IV.) |
| 2) ONE-HALF BREATH IN CRANIAL FAULT OR "BANANA HEAD." | Bulged parietal on one side and flattened parietal on the other side. (See Chapter I, Cranial Faults.) |
| 3) RELATIVE LACK OF HYDROCHLORIC ACID IN THE GASTRIC MUCOSA AND SYSTEMICALLY. | Determined by the Diagnex Blue Test and pH of the saliva. Both of these tests are relative and not specific. Supplement the patient's diet with a minimal dosage of betaine hydrochloride, which will stimulate the gastric mucosa to increase its hydrochloric acid production. |
| 4) POSITIVE ROGOFF'S SIGN. | Evidenced by pupil dilation after constriction when hit by a beam of light. This test is specific for patients with low adrenal functional levels. The patient may need adrenal cytotropic extracts. |
| 5) POSITIVE RAGLAND EFFECT. | Evidenced by a positive Rogoff's Sign and a drop in the systolic blood pressure when the patient rises from a supine position to a standing position. Also, the sartorius and gracilis muscles will often test weak. There will be definite tenderness of the erector spinae muscles at the lower costal dorsal junction, and palpable tenderness of the sixth and seventh intercostal space on the left chest wall. This test is specific for patients with allergies who have superimposed low adrenal functional levels. The patient may need adrenal cytotropic extracts. |
| 6) SWELLING OF THE EXTREMITIES. | Frequently found in allergy patients who also have adrenal syndromes, and this is due to the sodium-potassium relationship. The potassium level will be increased and the sodium level will be decreased; therefore, contrary to popular belief, the patient's sodium intake should be increased unless contra-indicated by other visceral disorders. |
| 7) 17 KETOSTEROID LEVEL DECREASED. | This clinical laboratory finding will be well below the normal. (See Chapter VII.) |
| 8) MARKED INVERSION OR LOWERING OF THE T-WAVE ON EKG. | Seen in patients who have extreme adrenal deficiency. |
| 9) SIGNS OF A POSTERIOR ILIUM. | Seen in allergy patients with adrenal deficiencies. (See Chapter I, Ilium and Ischium.) |

In addition to the above, the patient's muscular weaknesses must be balanced and all structural weaknesses must be corrected. The patient should also be examined nutritionally and given the necessary supplements. Avoidance of carbohydrates may be necessary in the initial stages of treatment.

# HIATAL HERNIA

Authorities on the subject of hiatal hernia state that approximately 32 percent of the population at 50 years of age suffer from this condition. The patient may complain of angina, fear of an impending heart attack, gastric regurgitation, heartburn, ulcers or radiating pain down the arm at night when lying flat on his back.

In hiatal hernia conditions, the hiatal opening for the esophagus is elongated, which allows part of the stomach to penetrate through this opening.

There are two classifications of hiatal hernia — sliding and rolling. The sliding variety of hiatal hernia causes the patient to regurgitate the peptic acid contents of the stomach, while the rolling variety causes obstructive symptoms. These symptoms occur at night and create much pain which can radiate from the chest, down the arm, with eventual relief coming after an hour or more of actue distress. The sliding variety preserves the integrity of the cardiac sphincter of the stomach and represents only a slight elongation of the esophageal opening of the diaphragm and the esophageal gastric junction has very little or obtuse angulation. The rolling hernia generally has an acute angulation of the same esophageal gastric junction, with a portion of the gastric mucosa herniating up through the relatively large elongation of the diaphragm opening, trapping part of the upper portion of the stomach.

The diaphragmatic esophageal hiatus is a button-shaped opening, running in an anterior to posterior direction, from front left to rear right. The right diaphragmatic crus and tendons cross their medial fibers to the left, forming the left side of the hiatus. The hiatus is at the level of the tenth dorsal. Naturally, the excursion of the diaphragm changes this level.

Correction of a hiatal hernia is relatively simple when utilizing Applied Chiropractic Kinesiological Technique. However, before one begins correction, all cranial, spinal and pelvic subluxations and fixations must be corrected and all muscles must be balanced — specifically the psoas. Treatment consists of contacting the left upper gastric area with outstretched fingers of both hands with a downward pressure, and literally pulling the stomach downward, out of the hiatal hernia trap. This heavy, downward pressure, with the patient in a vertical position, may be likened to pulling a cork out of an inverted champagne bottle. This procedure may need to be repeated until successful, but will provide some immediate relief. Neurovascular contact of the anterior and posterior fontanels should be held with a slight, tugging pressure until pulsation is felt. The anterior neurolymphatic points are located over the sternum, over the gladiolus, the manubrium and the zyphoid processes. These areas are very painful, and activation with soft-tissue manipulation is necessary for a period of 30-40 seconds. The posterior neurolymphatic reflex activation points are located at the junction of the tenth rib and tenth dorsal vertebra transverse process on the right side only. Activation of these points will balance the leaves of the diaphragm and also increase the patient's breath holding time.

## DIAGNOSIS

The patient is asked to take a deep breath and hold it. The holding time is measured in seconds, and the average patient should be able to hold his breath for at least 40 seconds. There are, of course, variables, such as lack of vitamin C or thyroid conditions which can affect the holding time. Usually, however, poor breath-holding time indicates a disturbance in the muscular branches of the diaphragm. One can challenge for a hiatal hernia by the following procedure. The patient is in a supine position; test a strong indicator muscle. Then contact, with your finger tips (positive and negative surfaces), the surface of the abdomen approximately one inch below the zyphoid of the sternum and press the tissue upward as if you were pushing the stomach into the esophagus. Retest the indicator muscle. If a strong indicator muscle becomes weak, it is a positive indication of a diaphragmatic problem.

Following treatment, a patient's breath-holding time should increase by one-third to one-half of the previous amount, and it is wise to rechallenge.

*It is recommended these patients be checked with a vital capacity meter, as it is definitely a more professional approach.*

# GAIT RECEPTOR FAULTS

In the practice of Chiropractic, it is not unusual to see a patient enter the office in an antalgic position and leave the office following treatment in an erect, upright position. However, as the patient continues to move around and operate in his usual fashion, the correction occasionally deteriorates; this is usually an indication of a gait receptor fault. Therefore, in addition to applying the usual Applied Chiropractic Kinesiological Diagnoses and Techniques, one may occasionally need to examine the systems and muscles involved in gait. These gait tests should not be confused with the usual muscle tests and may be considered a separate type of muscle test, called "gait tests."

When one steps forward, the left arm flexors and the right leg flexors are facilitated. At the same time, the right arm flexors and the left leg flexors are inhibited. Upon taking another step, the reverse occurs. The normal gait process requires a rapid, crossfire motion which normally occurs at a high rate of speed and with a great deal of precision. Therefore, at the end of the day, there should be an equal number of movements of the left arm and the right leg versus the right arm and the left leg. If they are unequal, this indicates the presence of a gait fault. This is why some patients leave the office feeling fine and literally walk themselves right back into their original problem.

In order to test the gait facilitators, place the patient in a supine position. The left arm is brought forward approximately 30 to 40 degrees and is pressed downward to test the strength of the general arm flexors. Usually, it will test strong individually. Then, the right leg is brought forward 30 to 40 degrees, as if the patient were taking a step. The quadriceps and psoas muscles are tested together by pressing the patient's leg downward toward the table. This muscle combination will also usually test strong. However, when testing the general arm flexors and the general leg raisers combination SIMULTANEOUSLY in the above-described manner, weakness will be immediately noticed in either the arm flexors and/or the leg raisers combination if a gait fault exists. This procedure is then performed on the opposite extremities in the same manner, i.e., testing the general arm flexors individually, the general leg flexors combination individually and then both simultaneously. Naturally, if one notes any weakness when testing an extremity individually, it should be corrected in the usual fashion, using standard muscle testing and any one of the five elements of the intervertebral foramen before gait testing. Correction of any weakness of the extremities which becomes apparent when gait testing the extremities should be made on the Liver 3 acupuncture meridian point which is found between the first and second metatarsal base. Naturally, the correction will take place on the side of the gait involvement, which will be the leg side of the extremities being tested. One must use a soft-tissue manipulation on this point with a rather vigorous amount of pressure, exceeding the patient's normal pain threshold. Retest the extremities simultaneously to verify correction.

The contralateral gait receptors should be checked by testing the gluteus medius on one side against the rectus abdominis/transverse abdominis on the opposite side. These muscles or muscle combinations will normally test strong individually; however, if a contralateral gait receptor fault is present, they will test weak when tested simultaneously. First, test the gluteus medius, rectus abdominis and transverse abdominis muscles individually. (See Chapter IV.) Correct any individual weakness in the usual fashion by using any one of the five elements of the intervertebral foramen. Then, place the patient in a seated position on the examination table and ask him to press his right knee (gluteus medius) against your right knee while you test the left rectus abdominis and transverse abdominis by placing your hand on the front of the patient's left shoulder and attempting to press the patient backwards. Repeat this procedure on the opposite side. If both the gluteus medius or rectus abdominis weaken when the muscles are tested simultaneously, correction is made on the Gallbladder 41 acupuncture meridian point, which is located at the base of the fifth metatarsal. Once again, vigorous manipulation of this point is necessary, naturally on the side of the gluteus medius being tested. Retest contralateral receptors to verify correction.

Next, the lateral gait receptors should be checked. They are not usually observed in normal gait. However, they are readily seen when a patient limps. The patient should be placed in a supine position. The supraspinatus and deltoid are the primary upper extremity lateral gait receptor muscles while the primary lower extremity gait receptor muscles are the gluteii and the tensor fascia lata. The arm to be tested is abducted with the hand in a neutral position, the thumb facing forward and the elbow extended approximately 30 degrees. Test the muscles. Usually they will test strong, however, if weakness occurs, use specific muscle testing to locate the weakness and correct through any one of the five elements of the intervertebral foramen. Test the lower extremity gait receptors by having the patient laterally abduct the opposite leg from the arm that was just tested to about 30 degrees. If any weakness occurred, correct it in the usual fashion. Testing of the lateral gait receptors requires a simultaneous testing pressure of the opposite upper and lower extremities. If weakness occurs, correction is made by treating Stomach 43 acupuncture meridian point on the lower extremity. Acupuncture point Stomach 43 is located at the base of the second metatarsal between the second and third metatarsal. Once again, a vigorous soft-tissue manipulation past the patient's pain threshold is necessary for 10 to 15 seconds for correction. Retest the lateral gait receptors to verify correction.

Finally, the gait extensors should be tested. The patient is placed in a prone position and the arm extensors are tested individually by having the patient bring the arm back posteriorly as far as possible as the examiner presses it forward. Then the thigh extensors (gluteus maximus) are tested individually on the opposite side in the usual fashion. (See Chapter IV.) If weakness in either extremity is present when tested individually, correct the weakness in the usual fashion, using any one of the five elements of the intervertebral foramen. Repeat this same procedure on the opposite side. After both upper and lower extremities test strong individually, test them simultaneously; and if a weakness is present in one or both extremities, this would indicate the presence of a gait extensor fault. Correction would be made on the leg extensor side on the Spleen 3 acupuncture meridian point, which is just posterior and lateral to the head of the first metatarsal. Once again, a vigorous manipulation for 10 to 20 seconds is necessary. Retest the muscles to verify correction.

# HEEL AND SOLE LIFTS

Before one can consider using a heel or sole lift, the patient's musculature must first be balanced through the five elements of the intervertebral foramen. The heel or sole lift is placed in or on the shoe on the side of the deficient limb. Not all patients with an anatomically deficient limb will need a lift.

## HEEL LIFTS

After the patient's musculature has been balanced and all necessary corrections have been made, evaluate the patient's pelvis in a prone position. Then, re-evaluate the patient's pelvis in a standing position. Note pelvic balance and the patient's posture. Retest an upper extremity muscle which has been previously corrected in a prone or supine position. If the indicator muscle is weak in a standing position, place a small lift (3 mm) under the deficient limb and retest the indicator muscle. Add progressively larger lifts, i.e., 5 mm, 7 mm, 9 mm and retest the indicator muscle after each additional lift has been inserted. The patient must stand on the lift for 30 to 60 seconds to overcome the body's compensatory mechanism. When the correct lift is placed under the deficient limb, there will be a remarkable increase in the indicator muscle's strength. The patient's body will always respond by increased strength to the indicator muscle. The length of time the patient will need to wear the lift varies and should be determined on subsequent office calls by testing an indicator muscle when the patient is in a standing position with and without the lift. If there is increased strength without the lift, then remove the lift or decrease the size of the lift accordingly. Naturally, this same procedure is used for increasing the size of the lift.

## SOLE LIFTS

Sole lifts are usually added at the rate of ¼" for every ½" heel lift. The correct size of the sole lift may be verified by using muscle testing.

If one does not have the privilege of x-ray and selects the short leg by palpation and observation, one should note the following. If the lift is placed under the long leg, this will temporarily increase the strength of the indicator muscle for approximately 30 to 40 seconds. However, this strength will thereafter rapidly deteriorate.

# REFLEX POINTS FOUND ON THE SOLES OF THE FEET

There are various points found on the soles of the feet and in the lower calves which seem to have a relationship to visceral structures. Many books have been written on foot reflexes and many different charts and philosophies have been built around these "reflex points."

Dr. Walter Schmitt, Jr., when a student at the National College of Chiropractic, first observed that these reflex points on the feet as Golgi tendon/muscle spindle directional mechanisms. Dr. Goodheart correlated their use and determined the origin and insertion method of correction.

It is very easy to prove the presence of these receptors. For example, a strong psoas can be weakened (turned off) by pressing the corresponding Golgi tendon/muscle spindle receptor on the foot in the direction of the origin or insertion. If a muscle is turned off due to Golgi tendon/muscle spindle receptor involvement, treatment may be administered by challenging the Golgi tendon/muscle spindle receptor in the direction of the origin or insertion of the muscle. Retest the muscle after each challenge to determine the appropriate line of correction. After determining the direction of weakness, find the phase of respiration which neutralizes the weakness. Then push on the reflex point in the direction of weakness on the phase of respiration which strengthens, 4 to 5 times. Rechallenge the reflex point in the direction of weakness to assure correction. Then ask the patient to walk on the foot which was treated and then rechallenge once again to verify correction, following weight bearing and gait.

Occasionally, these points must be treated when patients suffer trauma to their feet, e.g. athletes strain their feet, workmen bruise the soles of their feet, etc. These points can be therapy localized in the usual manner. The muscles related to the organs listed on the chart (pages 332 and 333) are the same as those found on the T.S. line. (See Chapter IV.) However, any T.S. line muscle may be tested as an indicator for an active foot reflex.

## REFLEX POINTS FOUND ON THE SOLE OF THE RIGHT FOOT

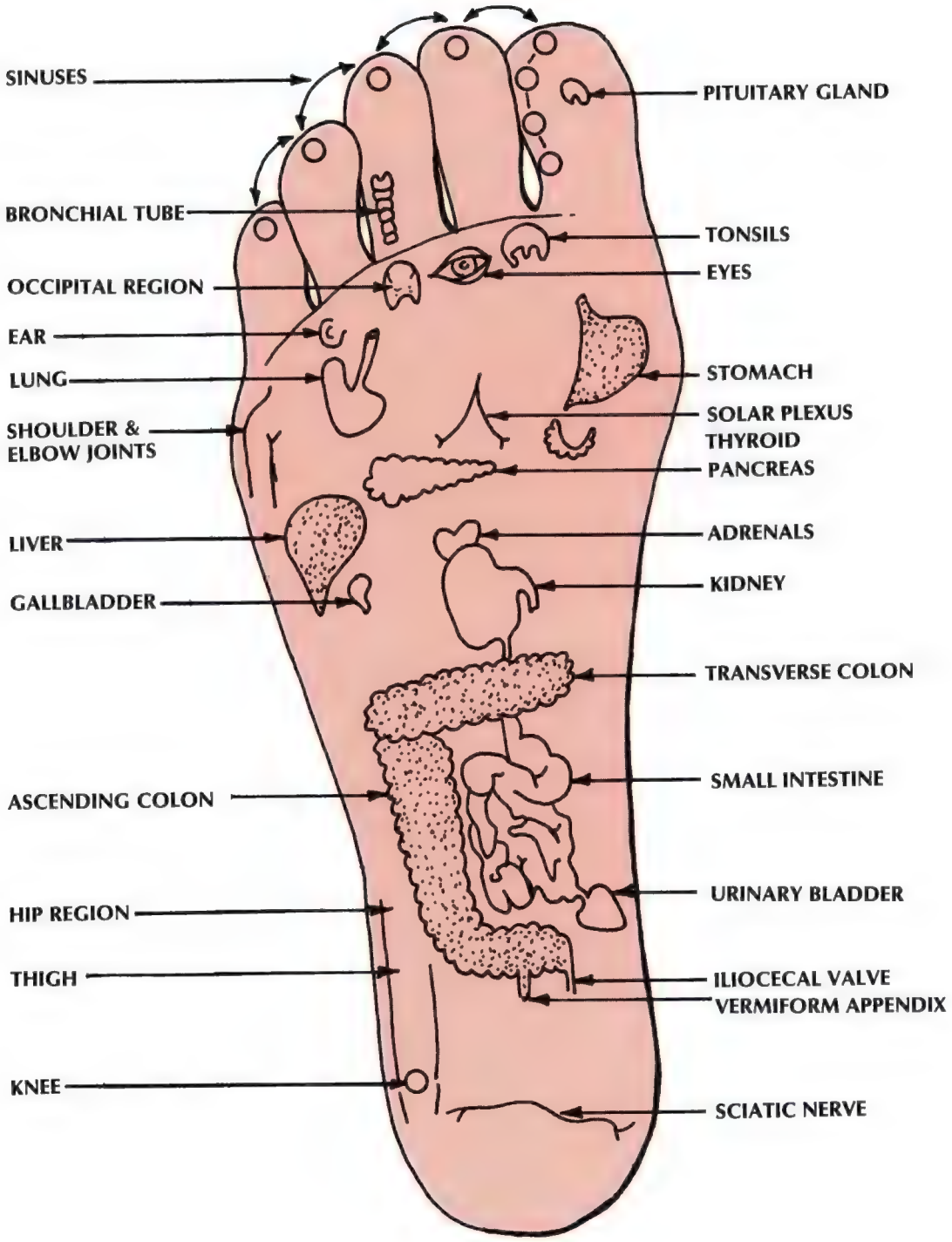

## REFLEX POINTS FOUND ON THE SOLE OF THE LEFT FOOT

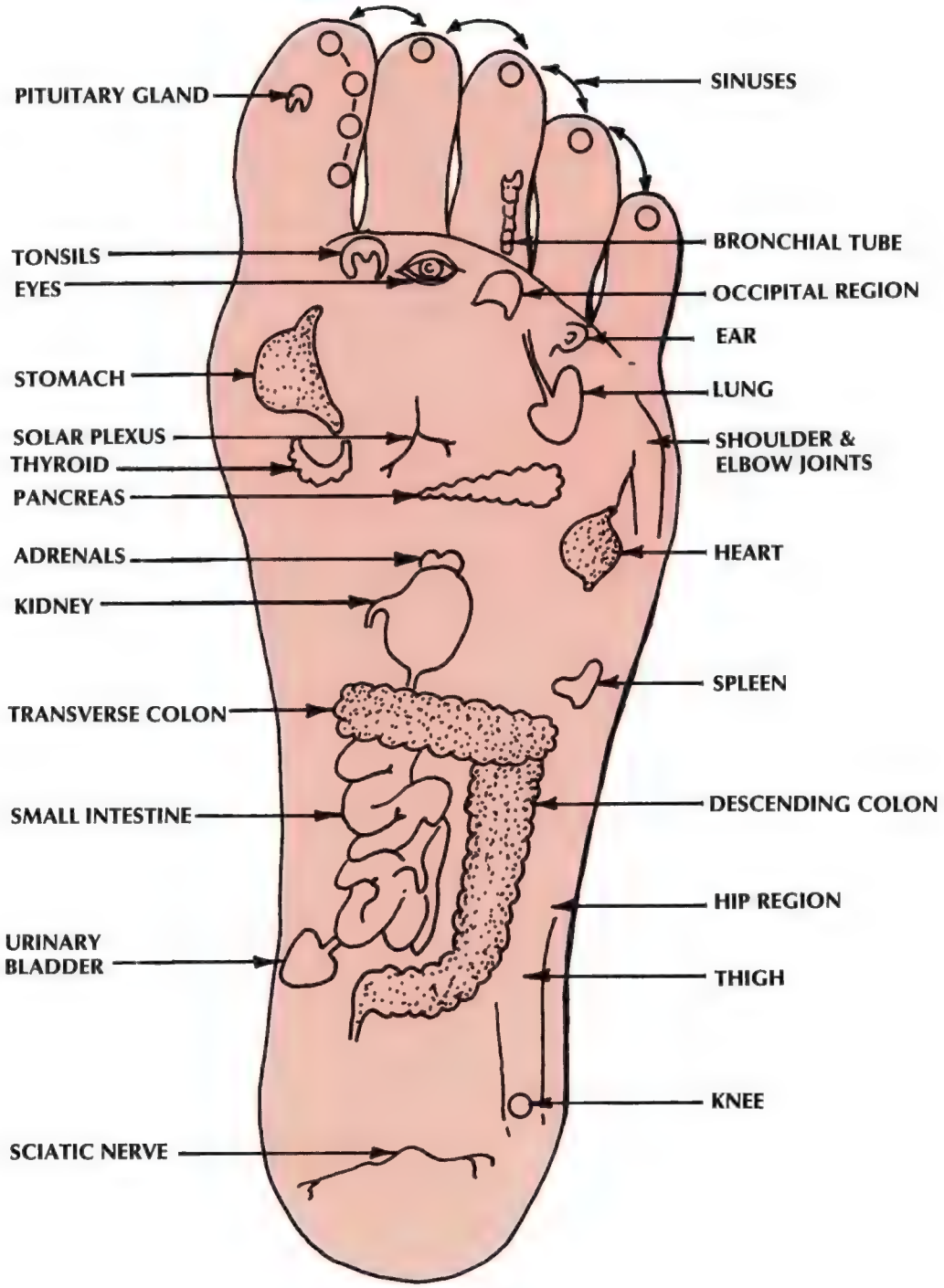

# HAND RECEPTORS

There are receptors located on the hands which relate specifically to different muscles. Occasionally, people who work with their hands inadvertently turn these receptors off, and it then becomes necessary to challenge the receptors to correct a structural problem.

The following charts are provided and developed by Dr. Vivian Bates, a Chiropractor from Chicago. When challenging these hand receptors, one must use a hard, pulling or tugging pressure of 4-5 pounds in the line of direction illustrated (either up or down, depending upon which direction produces muscle weakness). Treatment is administered in the direction which creates muscle weakness, but on the phase of respiration which abolishes it.

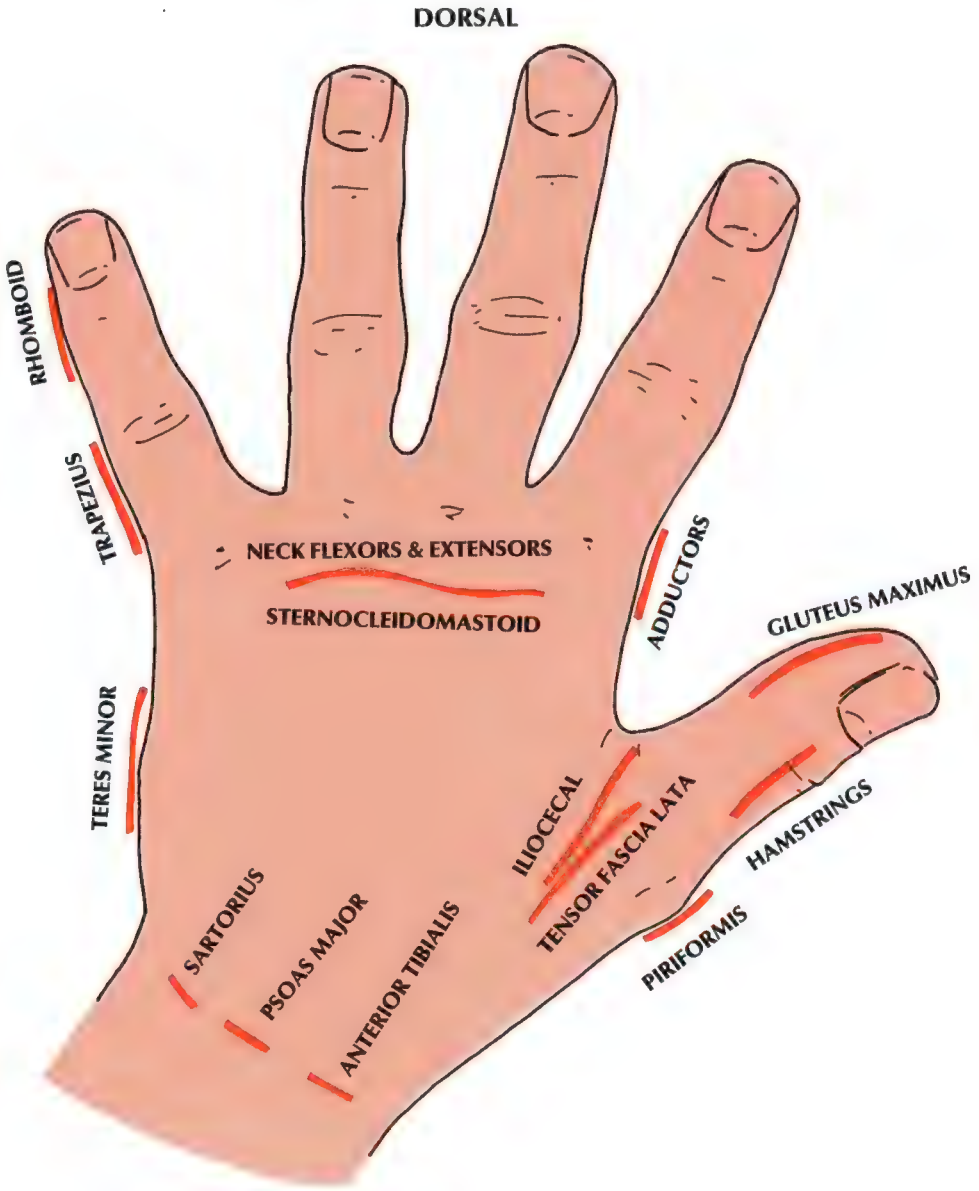

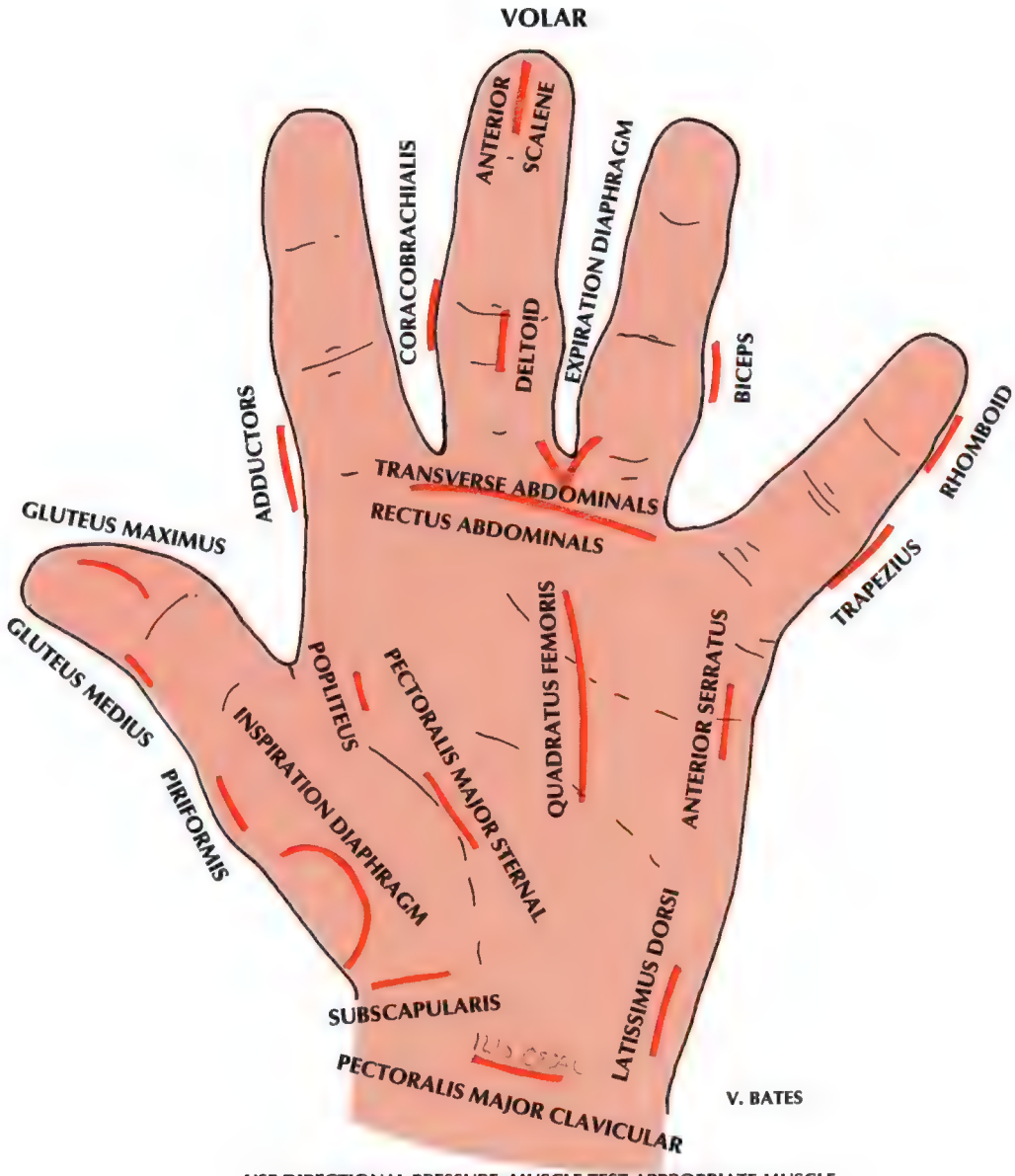


USE DIRECTIONAL PRESSURE, MUSCLE TEST APPROPRIATE MUSCLE, THEN USE APPROPRIATE RESPIRATORY TECHNIQUE.

# CARPAL-TUNNEL SYNDROME

Common symptoms of a carpal-tunnel syndrome are:

1) Numbness, tingling sensations or pain in the hands and arms (often severe enough to prevent the patient from sleeping).
2) Inability to hold light objects without dropping them.
3) Inability to hold a pencil or paper in the hand.
4) Pain on pronation or supination of the forearm.
5) Definite observable atrophy of the fleshy aspect of the thumb portion of the palm, known as the opponens muscle (in chronic carpal-tunnel syndrome).

The median nerve passes underneath the transverse carpal ligament and is the most superficial structure in the tunnel. The transverse ligament begins above the pisiform and runs into a broad band across the wrist to the base of the thenar eminence. Occasionally, a separation of the radial and ulnar joint can be seen on x-ray.

Examination for the carpal-tunnel syndrome is performed by asking the patient to press his thumb and little finger tightly together while the doctor attempts to separate them. A carpal-tunnel syndrome is characterized by marked weakness of the opponens (flexors) of the little finger and thumb. A confirmatory diagnosis may be made by asking the patient to encircle the affected wrist with his other hand and press the ulna and radius together. The doctor then retests the ability of the patient to press his thumb and little finger together while the patient places a rather firm pressure around his wrist. If the carpal-tunnel syndrome is positive, there will be a spectacular improvement in the strength of these flexors; and, if the patient originally had pain, numbness or tingling sensations in his hand, they will immediately decrease.

Correction of the carpal-tunnel syndrome is made by adjusting the radio-ulnar joint, which may or may not elicit an audible correction. Adjustment of the radio-ulnar joint is performed by asking the patient to sit on the treatment table, lay the ulnar surface of his forearm down on the table with the thumb pointed upward. The doctor then makes a pisiform contact upon the distal end of the radius, and this adjustive thrust drives the radius directly toward the ulna. A short sharp light adjustive thrust is all that is necessary; avoid a heavy-handed thrust. An alternate method of correction is to grasp the involved wrist of the patient with one hand and with the doctor's other hand hold the back side of the patient's hand and with a snapping motion, reunite the radius and ulna. Retest the opponens muscles by asking the patient to squeeze the little finger and thumb together. If correction is successful, it will test strong, but the patient should be advised to wear a leather wrist band for approximately two weeks. An elastic wristband is usually ineffective.

Occasionally, it is wise to test a patient exhibiting a carpal-tunnel syndrome with the forearm supinated and pronated and with the patient in a horizontal and vertical position.

Pain sometimes develops in the elbow as a result of this separation of the distal ulnar and radial joint, and often the proximal heads of the ulna and radial joint (see arm and elbow involvement) is also subluxated. Elbow involvement naturally requires specific adjustment of the subluxated radius. The direction of the corrective thrust applied in a carpal-tunnel syndrome may be slightly altered from its transverse radio-ulnar direction to include the adjustment of the subluxated radius. Usually, the radius subluxates slightly higher upward toward the anconeus; and, therefore, the direction of corrective thrust must be reversed. Nutritionally, a source of vacuum-processed low temperature freeze-dried veal rib is a good product to prescribe to the patient. I'm sure other calcium products will work just as effectively, but the best results have been obtained with the veal rib.

## PISIFORM-HAMMATE TUNNEL

There is another variety of carpal-tunnel syndrome which should be checked if the patient fails to respond to strapping or carpal-tunnel correction. This pattern of nerve entrapment affects the palmar branches of the ulnar nerve. The primary fingers involved in the pisiform-hammate tunnel are the ring finger and the little finger.

The usual symptoms are weakness, numbness, and burning in the little finger and ring finger. Atrophy and weakness of the opponens digiti minimi muscle can also result.

Examination of the pisiform-hammate tunnel syndrome is performed in the same manner as the carpal-tunnel syndrome, except the little finger and ring finger should be tested individually against the thumb.

The pisiform-hammate tunnel syndrome is a result of subluxation of the hammate on the pisiform, and the subluxation occurs toward the wrist in the direction of the dorsal aspect of the hand. The subluxation may be challenged in the usual fashion, but it is adjusted in the direction which produces strength.

Correction of this syndrome is performed by grasping the patient's hand, palm upward, in a double-hand contact. The doctor then places both thumbs on the pisiform or hammate, and a sharp thrust is delivered by the thumbs toward the patient's palm. Retest the little finger and ring finger flexors to verify correction. It may be necessary to tape the pisiform and hammate into position for approximately two weeks.

# TARSAL-TUNNEL SYNDROME

Symptoms of a tarsal-tunnel syndrome often resemble disc problems, herniation, radiculitis and peripheral neuritis. Burning pain down the legs, numbness, or tingling in the legs and feet may also be present. There might be referred pain along the sciatic axis up to the buttocks.

If there is a demonstrable weakness of the hallucis longus and hallucis brevis flexors, they should be examined as follows. Place the patient in a prone position with the knee flexed and the foot and ankle in a neutral position. Exert pressure against the plantar surface of the proximal and/or distal phalanx of the large toe in the direction of extension, and ask the patient to resist as the muscles are being tested. Occasionally, it is necessary to completely flex the foot in total plantar flexion, rather than leaving it in a neutral position, as this will eliminate recruitment of the toe flexors. The neutral position is preferred.

Correction of the tarsal-tunnel syndrome is administered by placing the patient in a supine position and marking the most painful medial aspect of the area inferior to the medial malleolus. Then, mark the most painful point on the lateral talus. Correct the lateral talus first by a traction thrust against the lateral aspect of the subluxated talus. If the patient has a right tarsal-tunnel, place the thenar eminences of the left hand on the distal border of the subluxated talus. The rest of the contact assumes a natural grasp around the right heel tendon and the other hand encircles the volar aspect of the top of the arch of the foot. Both hands exert traction to eliminate all slack at the ankle joint, and a sudden traction pull is exerted while the talus contact is thrusted medially. An audible sound is frequently heard, but is not necessary. Pain at the lower lateral aspect of the talus bone should be immediately eliminated, and the disappearance of this pain is essential before one can proceed. Next, correct the tarsal-tunnel syndrome by placing the patient in a prone position with the knee on the affected side flexed to approximately 45 degrees. The volar aspect of the foot is supported with the doctor's right hand. His left hand contacts the right os calcis and thrusts the posterior or heel portion of the os calcis toward the volar aspect of the arch. In other words, the os calcis is thrust (with the knee flexed at 45 degrees in a prone position) in a floorward, toeward direction. Retest the point of pain at the medial malleolus. If the pain has not entirely disappeared, repeat this thrusting motion four or five times to completely position the posterior os calcis. Use a hard, heavy pressure on the origin and insertion of the lateral and medial attachment of the plantar muscles, if necessary. Then, prescribe a suitable anti-pronation device or a temporary scaphoid pad until suitable foot leveler inserts can be obtained.

The neurovascular bundle which accompanies the posterior tibial nerve, contains the tendons of the posterior tibial, the extensor hallucis longus and the extensor digitorum longus muscles. This neurovascular tendon bundle occupies a groove just posterior to the medial malleolus. The lancinate ligament and the tensor retinaculum roof, located over this groove, behind the medial malleolus, is referred to as the tarsal-tunnel. The lansinate ligament and the tensor retinaculum extend from the tibial medial malleolus to the os calcis. It is the compromising of the space of the tarsal-tunnel that produces the entrapment of the posterior tibial nerve. The posterior movement of the os calcis entraps the nerve by tightening the lancinate ligament and the tensor retinaculum and results in impingement of the posterior tibial nerve. This posterior movement fault is responsible for the medial pronation syndrome. (See section on shock transmit vs. shock absorb.)

Subluxations of the below named bones of the feet will result in weakness of the following muscles. Correct the muscle weakness through any one of the five elements of the intervertebral foramen. Then, ask the patient to get up and walk around the room for a couple of minutes in a duck walk fashion. Place the patient back on the table and retest the muscles. If the following subluxations are not corrected, the muscle weakness will reappear. No matter how many times the muscle is corrected, the muscle weakness will reappear until the subluxations are properly corrected in the patient's feet.

| SUBLUXATION | MUSCLE WEAKNESS |
|---|---|
| Lateral Cuboid | Tensor Fascia Lata |
| Dropped Navicular | Adductors |
| Lateral Talus | Psoas |

# HAND-ARM-SHOULDER PAIN

Shoulder pain is associated with numerous conditions, and the most common associated conditions are listed below in the order in which they are most frequently seen.

## BURSITIS

Bursitis of the subdeltoid or infraspinatus tendon is the most common shoulder problem. In all true bursitis conditions, one should always find a calcareous deposit, which is frequently located behind the greater tuberosity of the humerus, or in the supraspinatus, subscapular or infraspinatus tendon. Occasionally, the calcium is in a state of precipitation and is not visible on a simple A-P x-ray projection. Therefore, it is wise to perform a fluoroscopic examination of the patient's shoulder in motion.

A sacroiliac condition on the same side is frequently associated with bursitis, and results in distortion of the musculature. One frequently also finds subluxations at C-2 and C-5 on the right, irrespective of the side of shoulder involvement.

Before treatment can be administered, all structural and muscle weaknesses must first be balanced within the patient's tolerance. Also, the patient's shoulder must be immobilized by adhesive strapping in order to remove the strain from the bursa. The application of the tape should be based upon fluoroscopy or simple observation.

Dr. Goodheart feels that most kidney stones are formed while the urine is in an alkaline state and that a similar situation occurs in calcific bursitis and where there are other calcium deposits in the body. Therefore, his treatment is designed to acidify the tissues, which results in reducing the patient's calcareous deposit and provides almost immediate relief. This is accomplished by giving the patient a microdose of Vitamin A, C and E hourly and one acid calcium tablet four times daily. Instruct the patient to take all of the calcium tablets unless yawning occurs, at which time he should not take any further calcium that day. In other words, the calcium should be taken daily until yawning occurs. Generally, yawning represents the body's effort to shift into an acid state. This shift results in dissolving the calcium deposit and diffuses the calcium into the cellular tissue, thus reducing the pain. This process generally takes between 24-48 hours. A visible reduction of the calcareous deposit can usually be seen within one week. The Sulkowitch urine test for calcium is also a good indication of the change that has taken place within the patient's body.

## SLIPPED BICIPITAL TENDON

If, following trauma, a patient complains of difficulty placing his hands in his hip pocket or raising his arm past the horizontal position, one would suspect a slipped bicipital tendon.

The biceps has two heads; one gains its origin from the top of the coracoid process and the other gains its origin from the upper lip of the glenoid fossa.

The bicipital tendon from the glenoid fossa slips out of its groove, onto the humerus and immediately causes an automatic shortening of the biceps tendon. This interferes with the incidental motion of the shoulder and causes a reduction of motion in extension, hyperextension and raising the arm. Pain, swelling and disability will result.

## TREATMENT

Allow the arm to hang loosely, with the elbow flexed, so that the forearm is at right angles to the floor. Apply a steady, lateral (rarely medial) pressure with the thumb to the slipped bicipital head and push the elbow, which is against the thorax, straight posteriorly until the limit of motion is reached. Maintain the lateral pressure on the biceps tendon while the elbow is abducted from the chest, brought forward and returned to its previous position. The tendon will slip back into the bicipital groove of the humerus. This action or maneuver may require repetition. Following correction of the slipped bicipital tendon, traction taping is recommended to hold the tendon in position.

## MUSCLE SPASMS

The teres major, the subscapularis and the infraspinatus muscles often become spastic after continued weakness of other joint muscles, resulting in a rotation of the humerus. A compensatory contraction of the pectoralis major clavicular is then created which restricts shoulder motion and causes pain. Treatment of the appropriate neurolymphatics, neurovasculars and soft-tissue manipulation of the bellies of the teres major, subscapularis and supraspinatus muscles, with secondary manipulation of the belly of the pectoralis major clavicular muscle, will relieve the condition.

The coracobrachialis muscle very seldom causes shoulder joint problems. The latissimus dorsi, however, is frequently involved; and it is always wise to examine the status of the pelvic girdle, the sacroiliac joint and the lumbosacral articulation and carefully administer any necessary treatment. In recurring, non-specific shoulder joint problems, examine the rectus abdominis.

## ACROMIO-CLAVICULAR JOINT

An acromio-clavicular joint separation may be indicated by the patient carrying his arm away from his body. Generally, if the patient has an approximation of the acromio-clavicular joint, he will carry his arm next to his body. Manipulation to correct either of these conditions should be directed to the scapula. Since the scapula floats freely on the posterior thoracic wall, a steady pressure designed to either open up or reduce the acromio-clavicular joint is often all that is required. Pressure applied on the scapula on the inferior aspect of the supraspinatus ridge, along with simultaneous headward pressure at the lower margin of the scapula, will generally allow approximation of the previously separated joint to occur if one holds it for approximately 4 to 5 minutes. The opposite procedure is required in the case of an approximation of the acromio-clavicular joint. A medial, diagonal pressure held below the supraspinatus ridge, along with a separating pressure on either the coracoid process or the clavicle border, will suffice to cause a normal separation on the acromio-clavicular joint. Taping to insure either approximation or separation of the joint is necessary only in difficult cases. If severe tearing of the acromio-clavicular joint occurs, surgery may be indicated.

## ARM AND ELBOW INVOLVEMENT

The most minute separation which causes referred pain to the shoulder and upper arm is the separation of the radio-ulnar joint. This is generally caused by a fall or trauma which results in hyperextension of the patient's wrist. (See carpal-tunnel syndrome.)

Changes in the elbow joint are also responsible for referred pain to the shoulder. Occasionally, the elbow may require a pronation-extension realignment of the humerus to the radius and ulna. This is a relatively simple maneuver in which the arm is flexed and carried into a moderate pronation. Pressure is then exerted upon the olecranon process. Then, the arm is brought into full extension and mildly pronated. Generally, an audible click is heard upon correction. The humerus, radius or ulna can be challenged individually to determine if they are in their proper relationship (see challenge technique). When challenging these bones, the most convenient muscle to use is the opponens muscles, as the indicator muscle. In extremity adjusting, always adjust in the direction which produces strength.

Nutritionally, a source of vacuum-processed, low temperature, freeze-dried veal rib is a good product to prescribe to the patient.

## VISCERAL PAIN REFERRED TO THE SHOULDER

Reflexes from various viscera produce pain in the brachial plexus and shoulder area. The gallbladder and the stomach are the most frequent sites of reflex activity. Attention to the five elements of the intervertebral foramen and specific nutrients for the gallbladder and stomach will usually alleviate the reflex referred pain.

In all shoulder disorders, all muscles associated with the shoulder should be examined, and correction should be made by the appropriate element of the intervertebral foramen.

# KNEE JOINT PROBLEMS

Knee joint disturbances may evidence themselves by the patient's inability to flex or extend the knee, which is accompanied by pain, swelling and restriction of motion. The pain may be diffuse; and, therefore, the patient may have difficulty locating the position of greatest pain. Upon palpation of the knee joint, the patient usually experiences more pain in the area of the medial meniscus than in the other areas of the knee. Medial meniscus involvement is the most common disturbance found in knee joint problems.

Much attention has been given in literature to the quadriceps muscle in knee joint disturbances. The quadriceps mechanism serves to lock the knee in extension by affecting the lateral rotation of the tibiofemoral condyles. This is a form of lock mechanism which stabilizes the extended knee, protects it and allows it to bear weight properly. When the knee is unable to be extended, as a result of injury, it results in immediate quadriceps muscle atrophy. Many authorities recommend early, graded exercises to decrease this atrophy and subsequent disability. Normal quadriceps activity in leisure walking is minimal. However, when there is no quadriceps activity as a result of knee injury, atrophy rapidly ensues.

The sartorius-gracilis muscle group is frequently associated with medial meniscus involvement. Think of the medial meniscus cartilaginous spacing of the knee joint as a rectangle which may be likened to a sandwich. The condyles are located above and below with the filling of the sandwich represented by the meniscus cartilage material. The primary muscles move the bones, but the ligaments bridge the rectangular space and merely limit the degree of motion. The sartorius and gracilis muscles must be balanced on the medial aspect and the tensor fascia lata on the lateral aspect. This will result in stabilizing the knee joint in the medial and lateral position.

The popliteus is another important primary muscle involved in knee problems. The action of the popliteus is to internally rotate the lower leg on the femur, and it also acts as a posterior joint ligament. When the popliteus is weak, it allows the knee to hyperextend, thus limiting internal rotation of the knee. It stabilizes the knee joint in conjunction with the quadriceps and the flexion activity of the hamstrings. The rectangular space is maintained by the balance action of the muscle groups on the anterior, posterior, lateral and medial sides of the knee.

In any knee injury, it is wise to check all the muscles associated with the knee. Usually, a weakness of the sartorius and gracilis muscles and pain on the medial aspect of the knee over the area of the medial meniscus will be found. Also, weakness of the popliteus is frequently found.

In athletic injuries, one frequently sees a micro-avulsion of the quadriceps muscle. Treatment requires a heavy, soft-tissue manipulation of the origin and insertion of the quadriceps muscle. When the quadriceps is weak, there is often a noticeable weakness when stair climbing or when getting up from a seated position. Quadriceps weakness may also produce popliteal muscle weakness. This will also cause the tibia to subluxate straight posteriorly, and adjustment is required to move the tibia anteriorly. Posterior subluxation of the tibia can be found through therapy localization and challenge.

Occasionally, one may find an intact sartorius with a weakened gracilis, which may occur bilaterally or unilaterally. If this occurs, it will produce a knock-knee condition and allows an external rotation of the lower leg on the femur, which can cause a medial meniscus problem.

Due to the poor supply of blood to the cartilages and the extremely rich nerve supply, the muscles should be balanced before any adjustment is made to the knee. It is recommended that Dr. A. L. Schultz's method of knee adjustment be utilized as follows. Place the patient in a supine position with the affected leg extended as far as possible. Rotate the foot medially, and in the case of a left knee problem, grasp the tibia with the left hand, crossing the foot so as to maintain the medial foot position. In other words, the volar portion of the examiner's forearm should contact the lateral portion of the patient's foot; and the hand should grasp the medial, mid-portion of the patient's tibia. The examiner's other hand should firmly grasp the patient's lateral malleolus. A sharp, forceful pull should be exerted to open the wedged space of the medial meniscus, converting it to a rectilinear space.

The relative medial torque position of the patient's foot is maintained during this sharp, traction-pull adjustment. However, no additional torque is added to the pull, which is straight toward the examiner. The medial meniscus pain, previously evident on palpation, should now be sharply diminished. One may need to repeat this torque-traction adjustment two or three times. Taping of the knee in a criss-cross fashion may be indicated.

Heat is generally contra-indicated in the treatment of knee injuries. However, diathermy may be used in the early stages, if used cautiously. Cold treatment is generally preferred to heat, as cold will initiate a vasomotor response which actually produces heat. Therefore, cold results in an increase in circulation which exceeds that obtained by heat.

Reflex disturbances from the viscera can cause knee problems. Therefore, in many knee problems which fail to

respond as expected, check the internal organ related to the involved muscle.

We have not outlined all of the muscles which surround the knee or which may be affected in knee joint problems. However, the muscles mentioned are the most frequently involved in knee joint conditions. Keep in mind that in any knee problem, all the muscles associated with the knee should be examined and corrected as outlined in Chapter IV.

# CROSS CRAWL TECHNIQUE

Man has all the evidences of bilaterality, but few men are ambidextrous. There is an overwhelming number of right-handed individuals compared to left-handed individuals. Evidence of this phenomenon can be found in all civilizations. The hemispheric dominance of right-handed individuals can be identified not only by their right handedness, but also by the dominance of their right eye, right ear, and right foot. The left side of the brain controls the right side of the body and vice versa, and one side of the brain is always dominant.

Normally, hemispheric dominance is achieved at an early age. For example, the child of one year to eighteen months operates at a very poor level of neurological organization. This stage soon advances where the child can walk bilaterally in a cross pattern, swinging the opposite arm towards the forward leg and vice versa. He develops a stereotyped existence, using both eyes, both ears and both hands to allow him to penetrate his active world. However, in a few years he must leave this bilateral world and move on to laterality, which is unique only to man. He must also learn to read, write and spell once he's achieved the rudiments of a spoken language. The individual must now develop a cortical hemispheric dominance. The two hemispheres begin to develop different functions; one becomes a dominant hemisphere and the other takes on a subdominant position. This is dictated genetically by the parent — a right-handed parent usually has a right-handed child and, interestingly enough, right-handed parents who have a history of twins in the family are more apt to have left-handed children than if they do not have a twinning pattern.

Most doctors have noticed that many patients, when asked to do one thing, perform the exact opposite function. For example, if you ask the patient to lay face down, he will frequently lay supine. If you ask him to lay supine, he will frequently assume a prone position. This apparent inability to understand simple directions has a rather deep, far-reaching significance and is related to this hemispheric dominance.

Dr. Carl H. Delacato, author of "Diagnosis and Treatment of Speech and Reading Problems," has been concerned with the neurological organization in brain-injured children who have difficulty in learning to speak, read, write and spell. He has developed the concept of allowing these children to crawl in an effort to regress them in neurological and cortical activity and then bring them forward again by having them walk. This is a rather brief and inadequate description of Dr. Delacato's work, but it does relate to what we frequently see when patient's simply cannot follow verbal instructions.

The dominant hemispheric control can be likened to the command pilot of a modern aircraft with his usual co-pilot and other flight crew. If there is difficulty with some portion of the aircraft which requires the command pilot's attention, he can give the control to the co-pilot. The co-pilot is paid less than the first pilot because of his relative lack of experience. Similarly, the dominant hemisphere of the brain, when faced by a problem of infection, injury, accident, trauma, etc., will attempt to deal with the problem as it presents itself. It gives the housekeeping tasks of the body, such as posture, digestion, respiration, elimination, oxidation, etc., to the subdominant hemisphere for temporary control. This control, due to inexperience, is many times lacking in the fine details needed for modern living in a modern environment due to the lack of experience of the subdominant hemisphere. Therefore, there is a breakdown of many body systems which fail to remedy themselves by innate intelligence because the dominant hemisphere is preoccupied with something of greater urgency. Once the command pilot has solved the problem, he can then assume his command pilot's position once again; and the co-pilot must relinquish control to the more experienced performer. The same should occur in the subdominant hemisphere. However, many times there is definite evidence of the dominant hemisphere failing to regain control. The cross crawling pattern will program the right information into the hypothalamus, which, in turn, stimulates the innate intelligence of the body to switch to dominant hemisphere control. As a result, it programs the most precise muscle balancing technique conceivable. This correction can be reversed by changing the cross crawl to a homolateral crawl.

The cross crawl pattern quickly balances residual hypertonic muscles. However, it is not a substitute for adequate treatment, such as correcting a subluxated ilium, cranial lesion, spinal subluxation, etc.

The cross crawl is performed as follows. If the right psoas muscle should remain hypertonic, and the left one is in a normal pattern, there would be a decreased inward turn of the right foot. In this instance, the patient would be asked to raise the right leg, flexing the right knee and bringing it up toward the chest, while raising the opposite (left) arm and turning his head away from the residual tonicity. In other words, the nose should be turned away from the side of the residual hypertonicity. The patient is then asked to repeat this procedure, this time using the left leg and right arm. In this instance, since there is only hypertonic muscle on one side, the patient's head remains in the center position. If there should be a residual hypertonicity on the left side, the patient would be asked to turn his head away from that muscle. He would, therefore, be turning his head in both directions. Ask the patient to repeat this procedure 25 times daily. This can be performed most easily with the patient in a recumbent position, but it can also be performed in a standing position.

In the case of a schizophrenic patient, this pattern must be reversed; and he must be treated by using a homolateral crawl. In other words, if there is a residual hypertonicity of the right psoas, we would use the right arm and the right leg, and turn the head again to the left. Here again, on the opposite arm and opposite leg, we use the same arm and the same leg.

If the homolateral crawl is used on a normal patient which has just been treated and corrected, the original problems, fixations and muscle weaknesses will completely return when the crawl is repeated 15-20 times. Likewise, a cross crawl will have the same effect on a schizophrenic patient.

# CELLULAR MEMORY

An experiment was performed using two groups of earthworms (Plantarias) under identical physical conditions. Consistently, just before Group I was fed, a light went on and a small, electrical shock was administered to the entire group. Group II also received the light and shock stimuli, but it was not related to the feeding time. In other words, when the light and shock stimuli occurred for Group II, they may or may not have received food. After sufficient time had elapsed for a conditioned response to occur, both groups of worms were sacrificed. Because of the different reinforcement schedules, Group I learned a conditioned response, but Group II did not.

Group III and Group IV were then introduced into the experiment and were placed under the same physical conditions as Group I and II. At one stage in the Plantarias' existence, they become cannibalistic. The bodies of Group I were fed to Group III and the bodies of Group II were fed to Group IV. Then, Group III and Group IV were given the identical light and shock stimulation and feeding schedule which were previously given to Group I (the conditioned worms). When the light and shock stimuli were introduced to Group III and IV, a significant number of worms in Group III moved to the feeding place shortly after the stimuli were introduced. However, Group IV which ate the unconditioned worms did not respond in this manner. Group III ate the memory contained in Group I, whereas Group II, who were untrained, provided no cellular memory for Group IV.

This research has been repeated in many different fashions by researchers all over the world, and it is now an established fact that ribonucleic acid is the chemical material of memory. Our body chemistry is continually producing vast quantities of RNA (ribonucleic acid) and DNA (deoxyribonucleic acid) from the food we eat.

We can all recall at one time forgetting a familiar telephone number, address or friend's name. Mental memory is genuinely related to the cerebral hemispheres of the brain, but there is also a cellular memory.

The ability to stand on one foot is a combination of many factors. However, after one has learned the trick of balancing and then closes the eyes, there is only one element which produces a stable one-foot-standing pattern; this is the relative chemical memory of where one's ankle is positioned. Dr. Goodheart asked many of his patients, who were unable to balance on one foot with their eyes closed, to chew a small tablet of RNA (approximately 180 microns) and hold it in their mouth. As a result, he found that these patients were often able to significantly increase their balanced standing time. If their balancing time did not increase as a result of the RNA, Dr. Goodheart would give them more than one tablet to hold in their mouth until their balancing time increased. If one RNA tablet happened to decrease their balancing time, he felt this indicated a need for a relatively homeopathic amount of RNA; and, thus, a very small amount was given. These people who require only a small amount of RNA are evidently very sensitive to it and should be given frequent, small dosages to re-establish their cellular memory (balancing time). Patients even have an increase in mental memory from this material.

Before determining one's balance time, be sure the patient is cleared of any upper cervical subluxations, fixations or structural distortions, as they would definitely affect the righting reflex.

If the clinical response is not as good as anticipated after treatment is administered through any one of the five elements of the intervertebral foramen, cellular memory involvement may be present. Therefore, it is recommended that one perform the one-foot balance test to see if RNA is indicated.

# VIVAXIS

Dr. Goodheart noted that the direction in which a patient faces may affect the strength of his muscles. After examining over 500 patients, he found that if a patient faces toward the town in which he was born, a definite increase in muscle strength can be noted (as demonstrated through muscle testing). Furthermore, the body often seems to lunge forward when faced toward this direction.

From a practical standpoint, Dr. Goodheart used the following procedure on patients with paralysis, degenerative diseases or on difficult patients who respond slowly to treatment:

> Ask the patient to face the direction of his birthplace. Have him take a deep breath, turn 90 degrees in a clockwise direction and exhale after he has reached this 90 degree turn. Then, ask the patient to take another deep breath, turn another 90 degrees and exhale after he has completed the new 90 degree turn. Repeat the same procedure once again. By now, the patient should be facing toward the town in which he was born. Ask the patient to repeat the same entire procedure at 90 degree intervals in the opposite direction or counterclockwise direction.

The results of this technique were rather remarkable. The patients no longer exhibited a change of muscle strength when turned in different directions, and it balanced them so that they were strong in all directions.

Dr. Goodheart feels that this change in muscle strength, which is exhibited when turning the patient in different directions, deals with the electromagnetic configuration of the earth. Apparently, the location where we were born establishes some type of magnetic polarity within us. If we become ill, and if the illness affects this polarity, it can be rebalanced by using this technique.

If further information on vivaxis is desired, read, "Born to be Magnetic," by Frances Nixon, published by Magnetic Publishing Company, Box 718, Chemainus, B.C., Canada.

# CHAPTER IX

# STRUCTURAL EXERCISES

Due to automation, most Americans lead extremely sedentary lives. Their typical day consists of driving to work, sitting at a desk, pushing buttons or watching dials, and ends by driving home and sitting in front of the television until 10:00 or 11:00 o'clock in the evening (they do get occasional exercise, however, when going to and from the refrigerator). The next morning, the entire sedentary process begins again.

Proper exercise is as necessary to good health as proper sleep or food. Every conscientious doctor should provide an exercise for his patient's affected body part to improve the tonation of the area and, in turn, benefit the general well-being of the patient's entire body. Usually, the patient's follow-through is good.

Proper exercise will:

1) Improve circulation.
2) Strengthen the musculature.
3) Improve the tone and function of internal organs.
4) Help maintain regular elimination.
5) Improve balance, coordination and respiration.
6) Help alleviate tension.

# LOW BACK EXERCISES

The following low back exercises are listed in order of difficulty. The patient should begin with the most simple exercise and slowly graduate to the more difficult ones.

| | |
|---|---|
| **1)** Stand erect while holding onto a table or chair. Squat down, straighten up again, relax and repeat the exercise. | 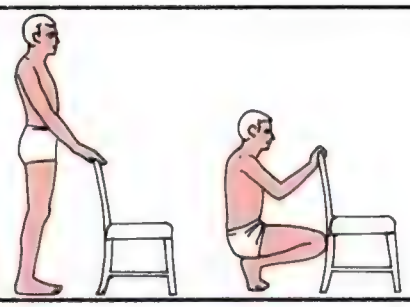 |
| **2)** Place hands at edge of chair. Bend forward, bring head to the knees, and pull in abdomen as you curl forward. Keep weight well back on the hips. Release abdominal muscles slowly as you come up. | |
| **3)** Place outstretched arms slightly to the sides. Relax the trunk muscles, press lower part of the back to the floor by tightening muscles of the abdomen and back. Relax to starting position. | |
| **4)** Place hands comfortably at sides. Lie back and relax trunk as much as possible. Take a deep breath, pushing the abdomen out as far as possible. Then exhale slowly until abdomen is pulled in and relax lower back to floor. Repeat several times. | 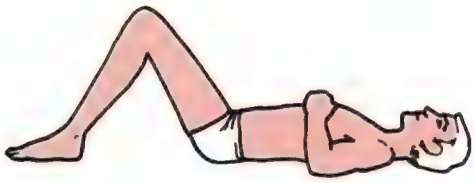 |
| **5)** A. With knees bent, feet flat on floor and hands clasped behind head, pinch buttocks together, pull in abdomen and flatten back against floor. At first, hold position for a count of five, relax for five, gradually increasing to counts of 20.<br>B. Then do this same exercise with legs extended and arms raised straight overhead. | 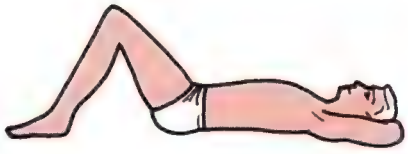 |

| | |
|---|---|
| **6)** Tighten the abdominal muscles and hold back as flat against the floor as possible. Bring one knee up to the chest holding it tightly with the hands, then slowly return it to the original position without straightening it out. Repeat with the alternate knee. | |
| **7)** Lie on your back with your arms above your head and your knees bent. Now move one knee as far as you can toward your chest and at the same time straighten out the other leg. Go back to the original position with both knees bent, and repeat the movements, switching legs. Relax and repeat the exercise. | |
| **8)** Lie on your back with your arms at your sides and your knees bent. Now bring your knees up to your chest, and with your hands clasped pull your knees toward your chest. Hold for a count of 10, keeping your knees together and your shoulders flat on the mat. Repeat the pulling and holding movement three times. Relax and repeat the exercise. | |
| **9)** Lie on back, grasp the right knee with both hands and pull the knee against the chest. Release the knee, straighten it and relax. Repeat this exercise five times and then do the same thing with the left knee. | |
| **10)** Bring one knee to the chest, then straighten it, pointing toe upward as far as possible. Bend knee back to chest and return to original position. Alternate knees with each repetition. | |
| **11)** Place arms at side, palms down and bend knees. Raise lower back and buttocks several inches off the floor and hold position for three seconds. Return to original position keeping knees bent. | 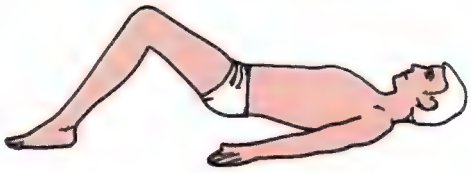 |

| | |
|---|---|
| **12)** Lie on your back and rise to a seated position, maintaining bent knees:<br>A. With arms out straight in front of you (five times).<br>B. With arms folded over your chest (five times).<br>C. With hands folded behind your head (five times). | 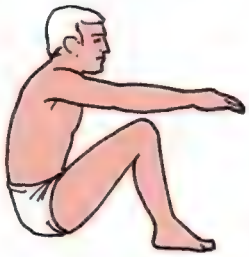 |
| **13)** A. Sit with one leg bent and the other straight.<br>B. Roll bent leg outward.<br>C. Lean toward straight leg reaching toward toes.<br>D. Return to starting position. | 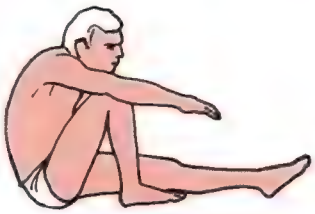 |
| **14)** A. Stand eight inches from wall.<br>B. Lean back against wall bending knees.<br>C. Tighten abdominal and buttocks muscles to flatten back against the wall.<br>D. Holding this position, slide down the wall, hold for five counts.<br>E. Return to starting position, keeping back flat. | |
| **15)** Assume a position on "all fours" (hands and knees) with arms and thighs in vertical position from shoulders and hips, respectively. Roll pelvis, arching back upward, and lowering head, trying to "round" spine as much as possible. Hold this position briefly. Then allow pelvis to rock in opposite direction, allowing spine to sway or sag, and tilting head upward. Maintain this position briefly. Relax; then return to arched position. Repeat ten times. | |
| **16)** Lie on back. Flex knees upward to chest and retain this position by holding knees firmly with hands and arms. Roll backward toward shoulders, flexing spine to its maximum. Hold position briefly, then roll back to starting position. Repeat, allowing gravity and body weight to force flexion of the lumbar and dorsal spine. Repeat ten times. (Certain cases may require a special application of this exercise. In these instances the exercise is accomplished in an identical manner, the only deviation being that only one knee is flexed and held to the chest.) | 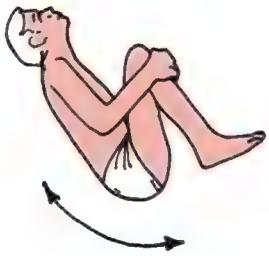 |

| | |
|---|---|
| **17)** A. Sit on floor with knees bent, keep feet flat on floor and held or hooked under a heavy piece of furniture to provide leverage.<br>B. Lie back and cross arms on chest, raise head and shoulders and curl up to a sitting position. Keep back round and pull with abdominal muscles. Lower self slowly. | |
| **18)** Lie face down, place hands on lower back. Raise head and shoulders (chest) from a prone position by contracting the back muscles (chin should be raised from floor — 20 inches). Hold this position for a count of five (five seconds) and return to starting position. Repeat exercise five times. | |
| **19)** Lie face down, place hands and arms under the head. Contract the muscles of the lower back and legs by contracting the posterior extensors. Feet should be raised to 20 inches above the floor. Hold this position for five seconds. Then, slowly return to starting position. Repeat this exercise five times. | |
| **20)** Lie face down on the floor, arms extended straight ahead. Raise arms, head and shoulders (chest) from prone position by contracting back muscles (usual height of chin from floor — 20 inches). After holding this position for a short period, slowly return to starting position. Then relax. Repeat exercise five times. | |

# NECK ROLLS

This exercise is performed in four basic movements:

| | |
|---|---|
| **1)** First, lower the head so the right ear touches the right shoulder and return the head to the vertical starting position. | |
| **2)** Then, lower the head so that the left ear touches the left shoulder and return the head to the vertical starting position. | |
| **3)** Then, lower the head, extending the neck backwards as far as possible and return the head to the vertical starting position. | |
| **4)** Finally, bring the head forward as far as possible so that the chin touches the chest and return the head to the vertical starting position. | 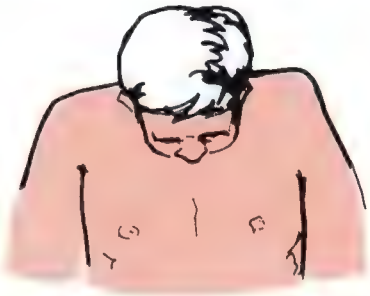 |

The above four motions should be repeated 3-4 times. The patient should then be instructed to roll the head about the shoulders in a 360° circle — first to the right three times and then to the left three times. Isometrics may be employed in each of these four motions if resistance is offered to the head.

# HIP EXERCISES

1) Lie on back; raise and lower one leg slowly:
   A. With knee bent.
   B. With knee straight.
2) Lie on back, with legs straight:
   A. Open legs wide apart.
   B. Return.
3) Lie on back, with knee bent on affected side and clasped with both arms:
   A. Force knee against chest.
   B. Push knee away from chest.
4) Lie on back, with legs flat; stretch first one leg then the other downward, then shrug each hip upward.
5) Sit on floor with legs straight out, and attempt to touch toes with hands by bending forward.
6) Lie face down, and lift leg backward, keeping knee straight.
7) Lie on side, and make a scissors motion with legs, as in the side stroke when swimming.
8) Stand between two chairs, grasping backs for support; swing affected leg back and forth.
9) Stand with feet about 12 inches apart; turn foot and leg on affected side inward and outward.
10) Stand, keeping the knee straight; raise affected leg and place heel on a stool or chair. (Gradually increase the height of object on which heel is placed.) Guard against falling!
11) Walk up and down steps.
12) Ride a stationary bicycle; or lie on back, raising legs in the air, and do bicycling exercise.

# SHOULDER EXERCISES

1) Shrug shoulders up, down, and in a circle, obtaining maximum movement.
2) Creep up the side of a wall with fingers, reaching maximum height each day.
3) Swing arm forward and up, downward and back, as far as possible.
4) Raise arms sideways and upward, clapping hands above head. Repeat the same exercise, bringing the backs of hands together.
5) Place hands alternately behind neck and lower back, keeping elbows bowed (to rotate shoulders).
6) Sit with arms folded and elbows shoulder high. Unfold arms, bringing elbows back sharply. Keep elbows shoulder high at all times.
7) Raise arms sideward, shoulder high; circle arms, starting with small circles and gradually increasing the size of the circles, until you make wide sweeping circles.
8) Stand with arms hanging, wrists crossed in front of body. Move arms upward and backward overhead, then return. (Place the wrist of the normal arm behind to help push the affected arm upward.)

Whenever possible, do these exercises with both shoulders simultaneously. The unaffected shoulder helps the affected shoulder to perform.

# KNEE EXERCISES

1) Sit or lie on back, with knee bent, and tighten muscles of the entire leg, and straighten the knee.
2) Sit on floor, keeping the leg straight, and lift knee off floor.
3) When seated on a table, gradually bend leg over edge of table, and exercise by bending and straightening the knee. (Sandbags of gradually increasing weight should be hung over the ankle as the leg straightens.)
4) Sit with body erect, legs extended with knees straight, reach forward and touch toes.
5) Lying on abdomen, bend affected knee. Wrap a towel around the ankle, then grasp both ends of the towel and attempt to flex knee by pulling on the towel.
6) Lie on back and lift legs in air. Move legs as though pedaling a bicycle, have someone grasp feet to give assistance. On succeeding days, have the assistant lightly resist the pedaling to increase bending of knee.
7) Sit on floor and hold a broomstick with both hands. Place feet on broomstick between the hands, keeping heels on floor. Resisting lightly with legs, pull stick toward body so that knees bend.
8) On hands and knees, rock backward toward heels, then forward.

# ANKLE EXERCISES

1) Bend foot up and down, slowly.
2) Turn foot in and out slowly.
3) Sitting, rotate the foot in a full circle.
4) Stand with feet parallel, about four inches apart. Rise on toes and swing heels outward. Return to standing position.
5) Sling a towel (about two yards long) across bottom of front part of foot, and hold both ends with your hand. Pull up on the towel while resisting with the foot and push down, curling toes downward.
6) With toes turned inward, walk on tiptoes, crossing feet at each step.
7) Stand facing the wall, a little more than an arm's length away. Lean forward and rest both hands on the wall. Keep knees straight, heels flat on ground, and rock forward.
8) Hold onto a support and stand with front part of one foot on the edge of a step or stool so that heel is off the edge. Lower and raise the body, supporting some weight with foot on stool or step. On subsequent days, increase amount of weight supported by foot on stool or step.

# ELBOW EXERCISES

1) Touch hand to shoulder of the same side and return.
2) Pull up on a bar or a door knob, keeping arm straight.
3) Stand facing a wall and extend arms forward at shoulder height, placing hands on wall. Allow the body to move toward the wall, causing elbows to bend. Try to touch shoulders to hands.
4) Lift and carry weights. Participate in games which involve motion of the elbow, such as
   A. Throwing a ball.
   B. Bowling.

# 9-POINT COURSE OF EXERCISES FOR VARICOSE VEINS

Do all exercises gently and at an easy pace.

At first, do each one 2-3 times. After several weeks, gradually increase, up to 6 or 8.

(First four exercises are done standing up, others lying down.)

1) Feet together, right hand on back of chair. Rise up on toes.
2) Grasp a chair back with both hands, and rise on toes. Then lift right leg, and make an easy circling motion with right foot, out at side. Repeat with left leg.
3) Position as in Illustration 1. As you count "one" lift right leg as in Illustration 3. At "two" bend knee as in Illustration 4. At "three" straighten leg, and at "four" lower leg to floor. Repeat with left leg.
4) Position same as in Illustration 2. Do easy waving movement of leg, back and forth, five times. Repeat with other leg.
5) Place feet on folded blanket, small pillow under head. Feet apart, arms straight. Make circling motion of feet, 5 times around. Repeat, circling opposite way.
6) Bend legs at knee and "walk" while lying down. "Walk" a full minute; increase later to two minutes.
7) Bend one leg up to stomach, then straighten out. Breathe in when straightening, breathe out when bending. Repeat 4 times with each leg.
8) Feet together, then swing right leg to side. Repeat with left leg. Do 4 times for each leg, breathing freely.
9) Lie on stomach. Bend leg at knee, and straighten. Then other leg. Repeat 6 times with each leg, breathing freely.

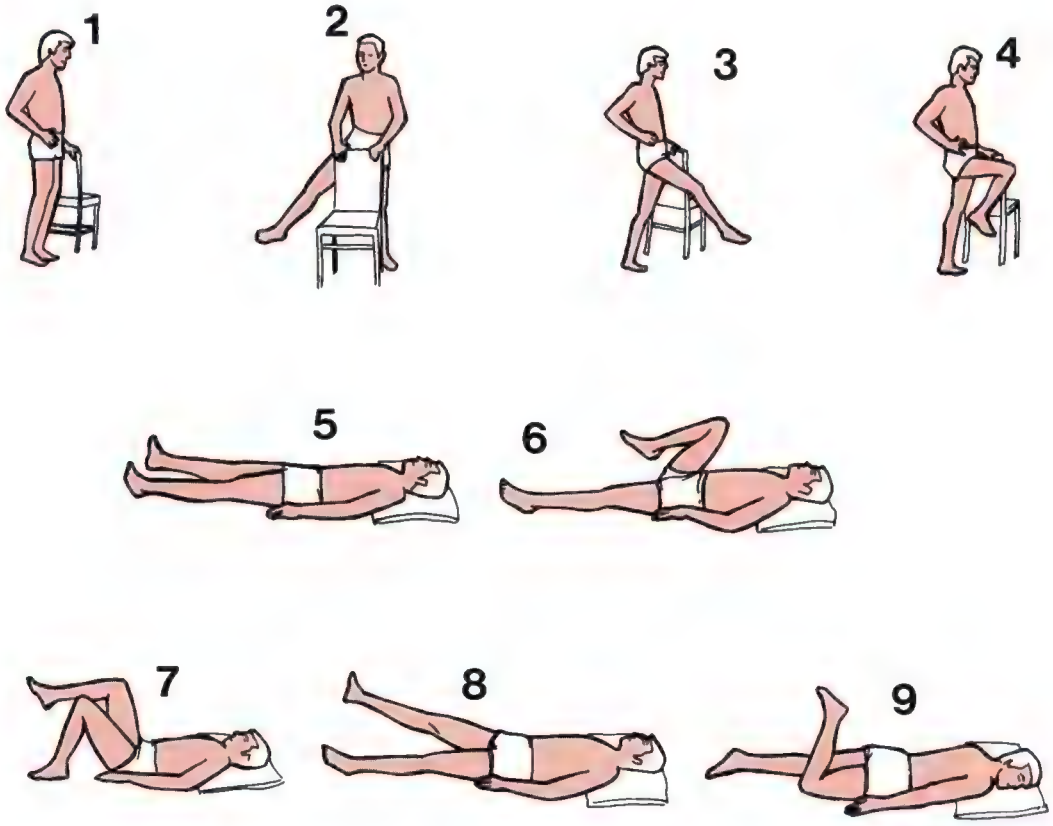

# WRIST EXERCISES

1) Close all fingers and thumb to a tight fist, then open to full extension.
2) Turn a doorknob (may be given with resistance by someone holding other side of knob).
3) Shake wrist up, down and around.
4) Place palms together so that fingers of each hand point toward the wrist of the other. Partially close each hand and hook the fingers of each hand beneath the fingers of the opposite hand. Keeping fingers closed, gently pull hands in opposite directions and gradually increase the pull.
5) Turn wrist from side to side, not moving elbow.
6) Wring out assorted sizes of cloths.
7) Place a folded newspaper or a light magazine across back of hand. Do not move the arm, and use a wrist motion to flip the newspaper or magazine from the hand. Repeat with palm of hand up.

# FINGER EXERCISES

1) Palm flat on table, raise and lower fingers one by one.
2) Make an "O" by touching thumb to each of the other fingertips, one at a time.
3) Crumple a sheet of newspaper into a small ball with one hand.
4) Squeeze a small rubber ball or sponge.
5) Pick up coins or buttons of assorted sizes.
6) Keep time to music with each finger (drum with extended finger).
7) Rest hand on table. Spread fingers wide and then bring them together.
8) Flip balls of paper with fingers, or flip a light-weight book or folded newspaper off extended fingers.
9) Place hands with palms together in front of chest. Push against fingers of affected hand with fingers of good hand.

# HERNIA EXERCISES

If the patient has a hernia and it isn't past the stage of a slight bulge, you may be able to reduce it permanently through Applied Chiropractic Kinesiological Diagnosis and Technique. Also, these exercises will be beneficial.

1) **TRUNK CURLS ON AN INCLINE BOARD:**
   Lie down on a steeply inclined board with your feet anchored at the high end of the board. Put your hands behind your head and curl only your head and shoulders up from the board. This will strengthen the abdominal muscles without activating your hip flexors and without placing too much pressure on the lower abdomen. Also, gravity will pull the intestinal tract away from the abdominal muscles.

   As you become stronger, you may hold a bag of sand against your chest for greater resistance in eight to ten repetitions. Exhale each time you contract your abdominal muscles.
2) **HELP THE HERNIA BY RELAXING ON AN INCLINE BOARD:**
   Simply lying relaxed with your head at the low end of an incline board will permit the intestinal tract and the abdominal organs to roll back and reduce the pressure in the lower abdomen. Inhale deeply and lift your chest up high for a diaphragm suction effect that will literally pull your abdominal organs out of the pelvic bowl.
3) **SWITCHING TO SIT-UP:**
   When there is no longer any bulging in the groin, you may bend your knees and do regular sit-ups. Begin lightly and cautiously, however, and remember to exhale while sitting up.
4) **LEG RAISES ON AN INCLINE BOARD:**
   With your head at the low end of the incline board and your hands gripping the handles, raise your legs up while holding your knees in a bent position. Don't get careless and let your legs fall back over your head to jackknife your body. Exhale during each repetition.

# CHEST EXPANSION (LUNG) EXERCISES

Chest expansion exercises should be performed the first thing in the morning and at bedtime. If light-headedness occurs during these deep breathing exercises, rest briefly and resume the exercise slowly. Increase the exercising gradually, according to your comfortable tolerance. Do not exercise to the point of exhaustion or pain.

1) Lying flat on your back with knees bent, cup both hands under your head. Slowly pull your flexed elbows back on the bed while you inhale deeply through your nose to a slow count of seven. Hold position and breathe for a count of five. Exhale forcibly through mouth for a count of seven, as elbows return to original relaxed position. (Exhale completely.) Repeat 5-6 times.
2) While walking erectly, standing erectly or sitting erectly, perform the deep breathing portion of Exercise #1, above. Perform this exercise several times throughout the day, as opportunity permits. Arms may be kept relaxed at your sides.
3) Lying flat on your back, place a small pillow or small, rolled towel between your shoulder blades. Do not place a pillow under your head. Keep your knees bent. Lift your arms slowly up and backward overhead while you inhale through your nose for a slow count of five. Slowly lower your arms to the sides while you exhale forcibly through your mouth for a count of five. (Exhale completely.) Repeat 4-5 times.
4) While seated on a firm chair, place your hands behind your head with your fingertips touching each other. Inhale deeply through the nose while pulling flexed elbows backward and raising your chest to a slow count of five. Exhale forcibly through an open mouth to a slow count of five. (Exhale completely.) Repeat 3-4 times.

# POSTURAL DRAINAGE

When mucus accumulates in the lungs, it thickens and forms plugs that block the airways and can result in difficult or labored breathing. Postural Drainage with percussion is a simple way of using gravity to clear the lungs of the mucus plugs.

## PROCEDURE

1. Position the body to promote maximum drainage from a specific lung field through the effects of gravity.
2. Percussion or vibration (hand vibrator) over specific lung regions to help loosen mucus secretions.
3. Coughing effectively to expectorate mucus.
4. This exercise should be performed immediately upon awakening to rid the lungs of the night's accumulation of mucus and before retiring in patients with chronic lung disorders. In patients with acute lung problems, this exercise can be performed several times per day.

## PERCUSSION

Percussion consists of either hand-cupping or vibration over the ribs after one has placed himself in a favorable position for drainage. Its purpose is to physically loosen the mucus plugs which are blocking the airways. The procedure is simple, but to be effective, it requires conscientious daily practice. The hand is cupped to form a cushion of air between the hand and the patient's skin. (See Figure SE-1.) This allows vigorous percussion without discomfort.

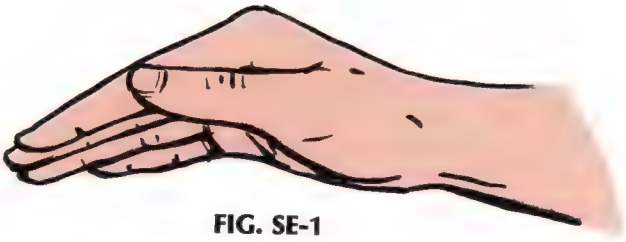

**FIG. SE-1**

The more air trapped, the greater the vibration. Each percussion should have a hollow sound and should not sting. Any reddened skin at the sight of percussion indicates slapping, thus indicating an insufficient amount of air being cupped in the hand. If the hand is not cupped properly, this technique is ineffective and painful.

## POSITIONS

Each position is maintained for at least five minutes. Where one position is more productive than another, it should be maintained for ten minutes. Percussion of the chest, breathing exercises and coughing are performed during drainage. The number of pillows used depends on the patient's weight.

| DESCRIPTION | PICTORIAL EXPLANATION |
|---|---|
| Lying on back, place five pillows under the hips. (16 to 18 inches elevation.) This will drain the left and right lower lobes and the anterior basal segment. Percuss the right side of the chest for two minutes, then the left side of the chest for two minutes. | |
| Lying on stomach, place five pillows under the hips. (16 to 18 inches elevation.) This will drain the left and right lower lobes and the posterior basal segment. Percuss the right side of the back for two minutes, then the left side of the back for two minutes. | |
| Lying on right side, place five pillows under the hips. (16 to 18 inches elevation.) This will drain the left lower lobe and the lateral basal segment. Percuss the left side for two minutes. | |
| Lying on left side, place five pillows under the hips. (16 to 18 inches elevation.) This will drain the right lower lobe and the lateral basal segment. Percuss the right side for two minutes. | |

# CHAPTER X

# DIETS

When dealing with patients who have structural problems, we, as Chiropractors, should be acutely aware of the patient's weight and nutritional intake. Many patients' illnesses are simply due to poor nutritional habits or excessive weight.

About the year 424 B.C., Hippocrates made the statement, "Your food shall be your medicine and your medicine shall be your food." Chiropractic is a natural healing art, and we must utilize everything we can in nature for the betterment of our patients.

The following diets are presented in alphabetical order and may be adapted exactly as they are presented or modified to meet individual needs. Naturally, before placing any patient on a diet, one should examine the patient thoroughly to make sure the diet will not aggravate any pre-existing condition. Also, while the patient is on the diet, he should be re-examined periodically to determine his progress.

1) ALLERGY (SEE HIGH PROTEIN, ALLERGY AND SINUS DIET).
2) NUTRITIONAL ANEMIA DIET.
3) ARTHRITIS DIET.
4) BLAND DIET.
5) LOW CHOLESTEROL DIET.
6) DETOXIFICATION DIET.
7) CLEANSING AND GENERAL HEALTH DIET.
8) HYPOGLYCEMIC DIET.
9) HIGH PROTEIN, SINUS OR ALLERGY DIET.
10) SOFT FOOD (LIQUID) DIET.
11) LOW PURINE DIET.
12) LOW SODIUM (SALT) DIET.
13) LOW SUGAR DIET.
14) GENERAL WEIGHT REDUCTION DIET, #1
15) GENERAL WEIGHT REDUCTION DIET, #2

# DIET FOR NUTRITIONAL ANEMIA

## FOODS ALLOWED:

1) **BEVERAGES:**
Milk, fruit juices, cocoa, tea, coffee.

2) **BREAD** (3 slices daily):
Whole grain breads, rye bread, raisin bread, blueberry and whole wheat muffins, graham crackers. Enriched white bread if specified by your doctor.

3) **FRUIT** (3 daily):
Apples, apricots, bananas, berries, dates, figs, grapefruit, melon, oranges, peaches, pears, plums, prunes, raisins, tangerines.

4) **CEREAL** (1-3 portions daily):
Cooked wheat and whole grain cereals, brown rice, enriched macaroni and spaghetti, oatmeal.

5) **VEGETABLES** (3 portions daily):
Asparagus, beans, beets, broccoli, brussels sprouts, cabbage, carrots, cauliflower, eggplant, greens, endive, kale, lettuce, onions, peas, potatoes (white and sweet), spinach, watercress, winter squash.

6) **PROTEIN:**
Meat and meat products, poultry, fish, seafood, eggs.

7) **FATS AND OILS** (sparingly):
Butter, cream, margarine (polyunsaturated preferred), nuts and nut butter, cooking and salad oils.

8) **DESSERT** (3 portions daily):
Cheese, custard, fruit and fruit pies, honey, molasses, jams.

### TYPICAL MENU: NUTRITIONAL ANEMIA DIET

| | |
|---|---|
| **BREAKFAST:** | Orange juice, whole wheat cereal with milk (8 oz.), soft-cooked egg, blueberry muffin, coffee. |
| **LUNCH:** | Half grapefruit, chicken salad, asparagus, whole wheat toast with butter and jam, cooked prunes, milk. |
| **DINNER:** | Cabbage soup, broiled liver and bacon, baked potato, brussels sprouts, fruit cup, strawberry tart, coffee with cream. |

## DO NOT EAT:

Fats, fried food (nuts are acceptable).

## INSTRUCTIONS TO THE PATIENT:

Every day you should eat an average of six ounces of meat, fish or poultry, including liver, heart, kidneys or other edible organ meat three times a week, one egg, one pint of milk and six ounces of fruit juice (not a "fruit drink" or "nectar"). Fruit desserts are best. Your doctor may want you to use a special nutritional supplement containing concentrated iron.

# SPECIAL DIET PROGRAM FOR ARTHRITIS

## ELIMINATION

Waste from daily meals must be eliminated within 24 hours. In order to check for proper elimination, use charcoal tablets, and your stool should be black the following day. Applied Chiropractic Kinesiological Diagnosis and Technique will help create and maintain proper elimination; however, for the first 3-4 days, enemas and/or laxatives may be necessary to begin bowel function. Once again, elimination of waste is very important.

Cod Liver Oil is necessary and must provide 10,000 U.S.P. units of Vitamin A and 1,000 U.S.P. units of Vitamin D DAILY. THIS IS A MUST!

### FOODS TO ELIMINATE ON THIS DIET

1) Flour (no matter what kind).
2) Flour products — bread, cakes, pies, spaghetti, pizza, noodles, etc.
3) Coffee (including Sanka), tea, cocoa, liquor, colas, and all "soft drinks."
4) Sugars, candies, ice cream and all artificial sweeteners.
5) Jellies, jams.
6) Canned or processed foods.
7) Jellos, custards, puddings.
8) Frozen fruits.
9) Any food manufactured or adulterated by man (breakfast cereal, quick cooking oatmeal, etc.)

### FIRST DAY

No food — *water only* — complete fast except for water; drink only when thirsty.

### SECOND DAY THROUGH FOURTH DAY

Raw, fresh vegetables and fruit (this includes juices), Cod liver oil. Repeat — *raw, fresh* only (avoid citrus fruit in active arthritis).

### FIFTH DAY THROUGH SEVENTH DAY

Add to *raw* fruit and vegetables:

1) Seafood — all kinds — fresh or frozen (no fish cakes or prepared fish dishes). Cook as little as possible.
2) Raw milk (*no homogenized milk*). (The addition of 1 tablespoon powdered Brewers' Yeast and 1 tablespoon Blackstrap Molasses should be made to milk powder.)

### EIGHTH DAY THROUGH FOURTEENTH DAY

Add:

1) Liver, heart, kidney — cook as little as possible.
2) Fruit and vegetables may be cooked, however as little as possible.
3) Natural cheese — *no processed cheese.*

### BEST FOODS

Fresh leafy vegetables, greens (turnip, mustard), squash, green peppers, kale, cabbage, spinach, broccoli, tomatoes, brussels sprouts, cauliflower, apples, strawberries, watermelon, cantaloupe, bananas, avocado, nuts and seeds, ranch eggs, raw milk, liver, sweetbreads, kidney, heart, seafood, Brewers' Yeast.

## SAMPLE MENU — SEVEN DAYS

**1ST DAY**
Water only.

**2ND DAY**

**BREAKFAST:** Unsweetened grape or prune juice, bananas.

**LUNCH:** Mixed green salad, oil and vinegar dressing, bowl of fruit.

**DINNER:** Raw vegetable plate, raw fruit salad, 1 tablespoon Cod Liver Oil.

**3RD AND 4TH DAYS**

**BREAKFAST:** Blended raw fruits, carrot juice.

**LUNCH:** Raw cauliflower and raw vegetables, ½ avocado.

**DINNER:** Mixed green salad, melon, 1 tablespoon Cod Liver Oil.

**5TH DAY**

**BREAKFAST:** ½ cantaloupe — or raw fruit, 8 oz. raw milk.

**LUNCH:** Fresh beef liver, sauteed lightly, mixed green salad.

**DINNER:** Broiled fish, ½ avocado, 8 oz. raw milk with molasses and Brewers' Yeast.

**6TH DAY**

**BREAKFAST:** Unsweetened grape or prune juice, veal kidneys lightly sauteed, 8 oz. raw milk.

**LUNCH:** Shrimp salad, cantaloupe, 8 oz. raw milk.

**DINNER:** Chef salad with raw peas, beans, etc., seasonal fruit, raw milk.

**7TH DAY**

**BREAKFAST:** Sliced bananas, 8 oz. raw milk.

**LUNCH:** Filet of sole, carrots or carrot juice, grapes, milk.

**DINNER:** Sautéed sweetbreads or liver, raw vegetables mixed in blender, melon, raw milk.

## SECOND WEEK

Vegetables and fruits may be lightly cooked. Learn to eat them as raw as possible with "waterless" cooking the best.

Baked apples, potatoes and yams may be added.

## THIRD WEEK ON

Add: Any or all of the following:

**VEGETABLES**

| | |
|---|---|
| Carrots | Radishes |
| Peas | Parsnips |
| Black-eyed peas | Cauliflower |
| Green peppers | Rutabagas |
| Lima beans | Turnips |
| String beans | Eggplant |
| Pole Beans | Broccoli |
| Wax beans | Brussels sprouts |
| Navy beans | Parsley |
| Corn | Salsify |
| Cucumbers | Asparagus |
| Hubbard squash | Onions |
| Golden squash | Scallions |
| Butternut squash | Leek |
| Banana squash | Chives |
| Zucchini squash | Okra |
| Summer squash | Mushrooms |
| Red cabbage | Horseradish |
| Savoy cabbage | Brown rice |
| Spinach | Wild rice |
| Kale | Lettuce |
| Swiss chard | Watercress |
| Kohlrabi | Endive |
| Tomatoes | Escarole |
| Beet tops | Beets |

**FOWL**

| | |
|---|---|
| Range chicken | Turkey |
| Duck | Cornish hen |
| Goose | Squab |

**MEATS (BEEF)**

| | |
|---|---|
| Roasts (all kinds) | Steaks (all kinds) |
| Shank meat | Short ribs |
| Chopped beef | Flanken |
| Stew beef | Ox tails |

| | | | |
|---|---|---|---|
| **MEATS (LAMB)** | Roast leg of lamb<br>Lamb shank | Chops (all kinds)<br>Lamb patties | Lamb stew |
| **MEATS (PORK)** | Roasts (all kinds)<br>Chops (all kinds) | Sausage (homemade)<br>Head cheese | Pigs knuckles<br>Spareribs |
| **MEATS (VEAL)** | Chops<br>Cutlets (not breaded) | Veal roast<br>Breast of veal | |
| **MEATS (ORGAN)** | Liver<br>Kidney | Heart<br>Brains | Sweetbreads<br>Tripe (cattle only) |
| **SEAFOOD** | Striped bass<br>Cod<br>Flounder<br>Halibut<br>Tuna (fresh)<br>Whiting<br>Scallops (bay)<br>Scallops (deep sea)<br>Lobster | Shrimp<br>Crabs (soft)<br>Crabs (hard)<br>Red snapper<br>Eels<br>Pompano<br>Sea bass<br>Fluke | Smelts<br>Salmon (fresh)<br>Clams<br>Mussels<br>Oysters<br>Concha<br>Shad (boned)<br>Fish roe |
| **FRUITS** | Golden apples<br>Red apples<br>Northern Spy apples<br>Rome apples<br>Baldwin apples<br>Russets<br>Winesaps<br>Cortlands<br>Bananas<br>Sickel pears | Blueberries<br>Blackberries<br>Raspberries<br>Strawberries<br>Gooseberries<br>Loganberries<br>Mulberries<br>Rhubarb<br>Currants<br>Figs | Prunes<br>Plums<br>Nectarines<br>Peaches<br>Bartlett pears<br>Boysenberries<br>Apricots<br>Cherries<br>Grapes (all varieties)<br>Melons (all varieties) |
| **NUTS** | Hazel nuts<br>Walnuts<br>Brazil nuts<br>Almonds | Pecans<br>Peanuts<br>Chinese chestnuts<br>Butternuts | Filberts<br>Black walnuts<br>Hickory nuts<br>Cashews |
| **SOUPS** | Split pea soup<br>Lentil | Marrowbone<br>Lima bean | Barley (unpearled)<br>Navy bean |
| **SEEDS** | Pumpkin | Sunflower | Sesame |
| **CHEESE** | Natural cheese | | |
| **EGGS** | | | |

# BLAND DIET

## INSTRUCTIONS TO THE PATIENT:

This diet is intended to provide balanced meals which avoid rough, irritating or highly acidulous foods. Eat only those foods listed in this diet and eat foods from each of the allowed food groups daily. This diet will also help to neutralize the acid produced in the stomach.

### DO NOT EAT:

Spiced foods, coffee, fried or greasy food, gravy, nuts, pork, alcoholic drinks, carbonated drinks, coarse cereal, whole grain bread, pickles, relishes, very hot drinks, iced drinks, dried (or oily) fish or meat, seasonings (except salt), coarse or acid (and most raw) fruit and vegetables. (Read labels of packaged foods to avoid spices, nuts, etc.)

### FOODS ALLOWED:

1) **BEVERAGES:**
   Milk, milk drinks, *weak* tea (not hot).

2) **BREAD** (3 slices daily):
   White, crackers, toast.

3) **SOUP** (warm, not hot):
   One or more portions daily of creamed vegetable soups permitted.

4) **FRUIT** (2-3 portions daily):
   Apricots, cherries, bananas (ripe), cooked apples, orange juice (4 Tbsp. mixed with 4 Tbsp. water, taken at end of meal), peaches, pears (remove skin), cooked prunes. No unripe, rough fruit.

5) **CEREAL** (one daily, ½ cup):
   Rice, corn, oatmeal, cooked wheat, refined wheat, prepared cereals. *Avoid bran,* and other coarse cereals. Read labels.

6) **VEGETABLES:** (2 portions daily, ½ cup each):
   Asparagus, beets, carrots, macaroni, noodles, peas, potato (baked, boiled, creamed, mashed), pumpkin, rice (refined or scalloped), spaghetti, spinach, squash, string beans.

7) **PROTEIN:**
   Eggs (3 daily) — poached, soft boiled, baked, souffled. Cheese (3 Tbsp. daily may substitute for eggs, fish or meat) — cottage, cream cheese, Neufchatel, hoop cheese. Fish — canned tuna, bonita, or salmon; fresh fish. Meat — liver, beef (scraped or tender), lamb, sweetbreads, crisp bacon (the only pork allowed). Poultry — chicken (no skin).

   NOTE: (Total meat, fish or poultry limited to 2 oz. daily).

8) **FATS** (3 or more portions daily):
   Butter, margarine (polyunsaturated), cream.

## TYPICAL BLAND DIET MENU

(Approx. 2,500 calories if whole milk is used.)

| | |
|---|---|
| **BREAKFAST:** | Cereal with sugar and milk or cream, egg, toast, butter, milk (1-2 cups), orange juice (diluted). |
| **LUNCH:** | Poached eggs on white toast, canned peas with butter, mashed potatoes (creamed), canned apricots, milk (1-2 cups). |
| **DINNER:** | Creamed soup (of allowed vegetables), soda crackers, roast beef (lean, 2 oz.), cooked carrots with butter, baked potato, toast and butter, banana or canned peaches, milk (1-2 cups). |

# LOW CHOLESTEROL DIET

## INSTRUCTIONS TO THE PATIENT:

Select your foods from each of the major allowed food-groups listed. Do not over eat so that you maintain or reach an overweight condition. Even though the foods allowed are low in fat and cholesterol, by gaining weight you will manufacture your own fat and defeat the purpose of this dietary program. Be sure you select your daily menu from all the allowed major food-groups.

### DO NOT EAT:

Pork and pork products, butter, cream, whole milk, cheese (hoop cheese allowed), (cottage cheese may be placed in cheesecloth with cream washed out in water), mayonnaise, ice cream, liver, giblets, kidney, sweetbreads, brains, gravy, egg noodles, baked beans, coconut, nuts, yogurt, milk chocolate, ice cream, caviar, cream soup, sour cream, poultry skin, soup from meat or chicken (unless all fat is carefully skimmed off).

Trim all visible fat from the meat before preparing. In cooking, use no animal fat (butter, lard) or hydrogenated vegetable oil (shortening).

### FOODS ALLOWED:

1) **BEVERAGES:**
   Fruit juice, skim milk, buttermilk, coffee (black), tea, bouillon.

2) **BREAD & CEREAL** (3 portions daily):
   All allowed. Use skim milk with cereals.

3) **FRUIT** (3 portions daily):
   All allowed.

4) **VEGETABLES** (3 portions daily, 1 cup each):
   All Allowed.

5) **PROTEIN:**
   Meat or poultry, 4 oz. daily (lamb, lean beef, veal, chicken, turkey, or duck). Fish, as desired (bonita, cod, halibut, salmon, sole, tuna). Cheese (hoop or washed cottage cheese). Egg (white only, no egg yolk).

6) **DESSERT** (2 portions daily):
   Gelatin, fruit, plain cake, pudding (without eggs, use non-fat milk), water ices.

7) **FAT:**
   1 Tbsp. french dressing, 1 tsp. margarine (polyunsaturated), vegetable oil (soy, safflower, corn, cottonseed, peanut).

## TYPICAL MENU: LOW FAT/LOW CHOLESTEROL DIET

(Approximately 1,400 calories, 85 mg. cholesterol, 25 gm. saturated fat.)

**BREAKFAST:** Fruit juice, cereal with skim milk, toast with margarine, coffee or tea.

**LUNCH:** Grapefruit or melon, vegetable plate or spanish rice (meatless), raw vegetable salad with oil dressing — optional, skim milk or buttermilk.

**DINNER:** Consommé (bouillon), meat roast (lean) — 4 oz. portion, zucchini squash with stewed tomatoes, asparagus, fruit cocktail, beverage.

# SUGGESTED DETOXIFICATION PROGRAM

## BY: GENA LARSON

(In every instance mentioned in this program we recommend that ALL foods be fresh, raw and organic, if possible. We never recommend a canned food and suggest you use frozen foods ONLY when absolutely necessary. All grains, fruits and vegetables should be thoroughly washed and kept refrigerated, but not bought in quantity in advance. Oils and grains should always be kept refrigerated. Leftover food is not desirable. NO FOODS should ever be fried or overcooked. AVOID ALL PRESERVATIVES AND KNOWN CHEMICALS! Honey is your best sweetener if it is RAW and UNFILTERED, but it is a highly concentrated carbohydrate and should NOT be used liberally.)

| | FOODS TO INCLUDE | FOODS TO AVOID |
|---|---|---|
| **BEVERAGES** | Herb teas such as mint tea, chamomile, alfalfa, red clover, chapparal, blue violet, rose hip and other natural herb teas; cereal fig or dandelion coffee replacements, *non-instant;* sesame or nut milk — raw only. "Green Drink" Pure water. | Coffee, teas (except herbal teas) cocoa, milk, soft drinks, carbonated drinks and alcohol. |
| **BREAD** | Sprouted grain breads, homemade corn pone, millet, buckwheat, bran muffins, corn tortillas, any freshly ground or sprouted grains, whole grain crackers. | White bread, or any bread made with white flour. |
| **CEREALS** | Millet, oats, yellow cornmeal, brown and wild rice, whole barley, buckwheat groats, rye, wheat; all freshly ground and soaked overnight in pure water or apple juice, then eaten *raw* or just barely cooked.<br>Seeds such as flax, chia, sesame, sunflower or pumpkin seeds, may be soaked with the grains or used by themselves soaked whole, in fresh apple juice overnight or longer in the refrigerator. Soaked nuts may be used, also. All sprouted grains, seeds, legumes or nuts may be added to any raw or cooked cereal. | |
| **CHEESE** | None, during strict detoxification. | Avoid all cheese. |
| **DESSERTS** | Fresh whole fruits, unsweetened fresh fruit cocktails and salads, fruits dried without sulphur dioxide, and soaked in pure water to reconstitute; whole tapioca or brown rice desserts sweetened with honey or sorghum to taste; home frozen fruit and juice ices, frozen bananas; fruit-nut desserts (raw), honey-comb or cappings. Fruit, home frozen with honey, natural fruit gelatin. | All commercially canned or frozen fruit except whole fruits frozen without sugar. All cakes, pastries, gelatin desserts, junkets, custards, sauces, ice cream, candy, etc. |
| **EGGS** | None during strict detoxification. | None. |
| **FAT** | Avocados, truly cold pressed crude *oils,* such as soy, sunflower, safflower, corn and sesame oil, *raw* butter with added sesame oil. All *oil seeds* freshly ground or soaked and used whole as cereal: i.e., flax, chia, sunflower, sesame or pumpkin seeds. Use liquid lecithin to keep foods from sticking to pans. Add Vitamin E to diet with fats. | Any processed or preserved oily foods such as commercial grade nuts, seeds, wheat germ, all margarines of any kind, solid and whipped fats of all kinds, cream and milk substitutes of all kinds. No exceptions. All iced milk and ice cream, etc. |

| | FOODS TO INCLUDE | FOODS TO AVOID |
|---|---|---|
| **FISH** | None on *strict* detoxification program. | |
| **FRUITS** | Fresh raw fruits, organically grown and eaten in season whenever possible. Apples, grapes, apricots, bananas, cherries, currants, figs, guava, mangos, papayas, peaches, pears, ripe pineapple, plums, persimmons, nectarines, quince, avocados, etc.<br><br>Melons of all kinds permitted, but should be eaten by themselves for a meal or snack.<br><br>Berries may be used — some will need to strain seeds. Dried fruits, organically grown and unsulphured: Soak to reconstitute apples, dates, apricots, figs, peaches, prunes, pears, plums and raisins. Fruit leathers permitted when made without sugar — may use a little honey to sweeten any fruit or to make fruit leather. Home-frozen fruits (without sugar) permitted.<br><br>Commercially frozen whole fruits without sweetening. (Berries, cherries, etc.) Use citrus fruit sparingly. Organically grown fresh, ripe citrus may be used twice a week. Use the whole fruit including most of the *rind* and seeds, if organically grown. | All commercially canned, frozen or dried fruits. All fruits with artificial coloring or sweetening added. (No *saccharine* or other artificial sweeteners.)<br><br>All canned juices and juices with artificial coloring or added sweetening. |
| **JUICES** | Fresh, raw fruit and vegetable juices, made from organically grown products. Carrot with greens or smaller amounts of beet, is most popular. May select from young beet leaves, watercress, parsley, celery, potato, zucchini and other vegetables to be juiced and added to carrot juice for variety and nutrition.<br><br>Use no more than one tablespoonful of parsley or beet daily or more than 6 oz. of cranberry juice daily.<br><br>Fruit juices: May select from fresh apple, apricots, peaches, cherries, berries, watermelon (use green part and seeds too). Cranberry juice is especially helpful when made fresh and mixed with apple or other sweet juices. Soak dried fruits in pure water and drain juice to drink. Limited amounts of sweet juices such as grape or prune. *Canned pineapple juice* may be used to soak seeds and cereals and to make green drink, if tolerated. | All "juice drinks."<br><br>Use citrus *juices* very sparingly, usually only for specific cleansing programs. |
| **MEAT** | None on strict detoxification program. | All Meats. |
| **MILK** | Raw cream and nut and seed milks. After three months, if all is going well, yogurt may be permitted, 1 cup each day (homemade yogurt made with raw certified milk and a starter — preferred when available).<br><br>Coconut milk from inside fresh coconut may be used as is, or whizzed in blender with pieces of fresh coconut and then strained to make a coconut milk. Keep chilled. | No other dried, canned or pasteurized milk permitted. No imitation milk, ice milk or imitation ice cream.<br><br>No coffee lightener or other chemical milk or cream substitutes. |

| | FOODS TO INCLUDE | FOODS TO AVOID |
|---|---|---|
| NUTS | *Moderate* use of all kinds of fresh, raw, organically grown nuts, (except *peanuts,* which at times harbor a cancer-causing substance). Almonds, filberts, pecans and walnuts especially recommended in that order.<br><br>Raw nut butters, freshly made in blender or juicer attachment, or ground in nut mill and a bit of fresh oil added.<br><br>Buy fresh nuts in the shell, store in a cool place, or freeze; crack them just before using. Coconuts: Freshly grated only. Use fresh coconut milk in beverages. | All roasted or salted nuts and nut butters. |
| POTATOES | Well scrubbed and eaten raw with the skin. Use raw slices as crackers with soup or spread with nut butter or avocado. Baked potato (eat skin) or gently steamed with jacket. Potato salad using skins wherever light and tender, fresh onion, celery and dressing made from oil, lemon or cider vinegar, yogurt or home soured raw cream. | French fried, grilled or potato chips. |
| CORN<br>RICE<br>NOODLES AND PASTA | Steamed millet, brown rice and all noodles or macaroni made of buckwheat, artichoke flour or whole grains are permitted, but do not count as a *vegetable* serving as does a potato or fresh sweet corn.<br><br>Try the corn *raw* for a special treat, or steam or warm just enough to melt the butter. | White rice and white flour noodles and other pastas (until eggs are permitted use only noodles made without eggs). |
| SALADS | Alfalfa, mung beans, radish, lentil or other sprouts, green leafy vegetables, grated or finely chopped raw beet, carrot, celery, potato and sweet potato, rutabaga, zucchini and other squash, cauliflower, cabbage, brussels sprouts, turnips, chard, kale, chicory, ripe tomatoes, romaine, cucumbers, buckwheat, lettuce, wheat grass (clipped), green peppers, etc.<br><br>Use fruit salads at a different *meal* than vegetables when very ill, or use a large mixed fresh raw salad as a meal with nuts, nut butter or soaked seeds or grain sprouts. | White macaroni salads. Commercial gelatin salads, canned salad vegetables; cooked salad vegetables.<br><br>Canned fruit salads or cocktails. |
| SEASONINGS | Chives, parsley, garlic, sweet basil and other herbs such as sage, thyme, cumin, savory, oregano, kelp and herb mix seasonings that contain no added sodium chloride. Some doctors permit the use of "Capsicum," a healthful red pepper product. | Harsh spices, pepper and ordinary salt. |
| SOUPS | Using homemade bone broths, vegetable stock or instant bouillon, heat, pour in blender and add any raw vegetable you enjoy. Blend briefly and serve.<br><br>Soups may be gently simmered using any vegetable and listed bases above. | Any commercially canned or frozen soups or soup-mixes. |
| SEEDS | Sunflower, chia, flax, sesame and pumpkin; sprouted, soaked in pineapple juice, whole or ground. Prunus seeds from apricots, prunes, plums, peaches, nectarines and cherries, crack and use a few daily. | Roasted, rancid or salted seeds. |

| | FOODS TO INCLUDE | FOODS TO AVOID |
|---|---|---|
| SPROUTS | Any fresh, raw or barely warmed sprouts such as alfalfa, mung bean, lentil, black radish, wheat, rye, brown rice, cress, clipped wheatgrass and buckwheat (lettuce) sprouts. Add to salads, sandwiches and blender drinks. | Potato sprouts are poison! |
| SWEETS | Raw honey — (unpasteurized) the darker varieties have a higher mineral content; honey-comb and honey-comb cappings, carob, date sugar or dates, sorghum, maple sugar, limited amounts on special occasions only.<br>Barley malt sweetener may occasionally be used in tiny, tiny amounts.<br>Blackstrap molasses, as directed by your doctor or nutritional counselor. | White sugar, brown sugar, raw sugar, candy, chocolate. |
| VEGETABLES | All vegetables. Raw preferred. 2nd choice: Carefully and lightly cooked with little liquid in a stainless steel or ceramic pot with a partially vacuum sealed cover. Use every *drop* of the cooking liquid as it contains valuable nutrients (yams, string and wax beans, corn, leeks, lentils, lima beans and other dry beans (sprouted, then cooked gently below boiling to prevent gastric distress), eggplant, mushrooms (try them raw in salads as well as cooked), squash, artichokes and all vegetables listed for salads above).<br>Asparagus Therapy: In blender place one 12 oz. can of green asparagus, including liquid if canned or home cooked. Puree and store in the refrigerator. Use 3 to 4 tablespoons night and morning. May be mixed with almond milk to make a "cream" soup.<br>If green vegetables are not in season, use sprouts generously and add to your diet a supplement from "green cereal grass juices" or use alfalfa tablets. | All sprayed and commercially canned or frozen. |

## SUGGESTED MENU

A glass of fresh juice 30 minutes before breakfast.

**BREAKFAST:** Raw or cooked fruit. Raw porridge and nut milk.

**MID-MORNING:** Fresh juice or fruit.

**LUNCH:** Salad with almonds and sprouts; Soup — largely raw with liquid (pre-digested; amino acids if available). Potato slices as cracker; Cooked vegetables; Dessert, only if hungry.

**MID-AFTERNOON:** Fresh juice or fruit (if hungry, use Tahini and honey over fruit). Herb tea later.

**DINNER:** Salad with greens and sprouts; Soup — largely raw; Steamed brown rice or millet-butter; Cooked vegetables; Herb tea.

**EVENING:** Fresh juice or unsalted vegetable broth, or cup of yogurt if permitted.

(Eat raw foods before cooked foods, for better digestion.)

**EQUIPMENT:** Blender — Press Type Juicer or other — Flour Mill — Nut grinder — Stainless Steel or Corning Cookware — Sprouter — Saladmaker.

**THE INTERNATIONAL ASSOCIATION**
**of**
**CANCER VICTIMS AND FRIENDS, INC.**

Box 707, Solana Beach, California 92075 (a suburb of San Diego, CA), Phone: (714) 755-9781

# CLEANSING AND GENERAL HEALTH DIET

1) Eat only when hungry.
2) It is best not to eat between meals or at bedtime.
3) Do not drink water with your meals — drink water 15 minutes before or two hours after a meal.
4) Eat moderately and chew your food well. Use no condiments, salt, spices or alcoholic drinks.
5) Do not eat when tired or emotionally upset. Rest and wait until you have recovered from either state.
6) Do not eat immediately before or after any intense physical or mental exertion.
7) Eat only natural, live, unprocessed foods.
8) Fresh air and exercise are part of a nutritive program. Get your full daily quota.
9) Try to rest after each meal if at all possible.
10) Strive for physical, mental and emotional balance.

## FRUIT OR FRUIT SALAD:

With fruit salad, use lettuce and celery. Tree-ripened fruits are best. Use 3 of the following:

Tangerines, sweet oranges, sweet grapefruit, sweet apples, sweet plums, watermelons, cantaloupes, honeydews, papayas, all berries, cherries, peaches, apricots, nectarines, prickly pears, grapes, persimmons, mangoes, pears, fresh figs, sapotes, cheramoyas, guavas.

## COMBINATION SALAD:

Use 75% of lettuce, celery, tomatoes, plus 3 or 4 of the following:

Use all varieties of lettuce, carrots (tender and young), beets and tops (young), cucumber, cauliflower, sweet peppers, fresh peas, okra, bean sprouts, alfalfa sprouts, endive, escarole, swiss chard, chinese cabbage, chicory, jicama (hickima), dandelion (young), parsley, finocchio (anise), Jerusalem artichokes, kale, celeriac (grated).

NOTE: A little olive oil and lemon and grapefruit juice may be used as a dressing, unless advised otherwise.

## STEAMED VEGETABLES:

Carrots, celery, stringbeans, fresh peas, fresh limas, green soy beans, artichokes (globe and Jerusalem), dandelion, squashes, kale, kohlrabi, okra, vegetable oyster (salsify), eggplant, brussels sprouts, cauliflower, broccoli, pumpkin, collards.

NOTE: Steam vegetables in their skins. Sweet butter may be used sparingly.

**FOOD ITEMS NOT LISTED SHOULD BE LEFT OUT OF DIET. DO NOT USE SALT, SPICES OR ANY CONDIMENTS.**

# HYPOGLYCEMIC DIET

| | |
|---|---|
| **UPON ARISING:** | Medium orange, half grapefruit, or 4 oz. of fresh juice. |
| **BREAKFAST:** | Fruit of 4 oz. of fresh juice; minimum of 1 egg with or without 2 slices of ham or bacon; ONLY 1 slice of any bread or toast with plenty of butter; beverage. |
| **2 HOURS AFTER BREAKFAST:** | Nuts, cheese, or fruit juice. |
| **LUNCH:** | Meat, fish, cheese or eggs; salad (large serving of lettuce, tomato, or Waldorf salad with mayonnaise or french dressing); vegetables if desired; ONLY 1 slice of any bread or toast with plenty of butter; dessert; beverage. |
| **3 HOURS AFTER LUNCH:** | Nuts, cheese or 6-8 oz. milk. |
| **1 HOUR BEFORE DINNER:** | Soup if desired (not thickened with flour); vegetables; liberal portion of meat, fish or poultry; ONLY 1 slice of bread if desired; dessert; beverage. |
| **2 TO 3 HOURS AFTER DINNER:** | 8 oz. of milk. |
| **EVERY 2 HOURS UNTIL BEDTIME:** | 4 oz. of milk or a small handful of nuts. |

## ALLOWABLE VEGETABLES:

Asparagus, avocado, beets, broccoli, brussels sprouts, cabbage, cauliflower, carrots, celery, corn, cucumbers, eggplant, lima beans, onions, peas, radishes, sauerkraut, squash, stringbeans, tomatoes, turnips.

## ALLOWABLE FRUITS:

Apples, apricots, berries, grapefruit, melons, oranges, peaches, pears, pineapple, tangerines.

May be cooked or raw, with or without cream, but without sugar; canned fruits should be packed in water, not syrup. The raw are better if enjoyed that way.

Lettuce, mushrooms and nuts may be taken as freely as desired.

Juice: Any unsweetened fruit or vegetable juice, except grape or prune juices.

**BEVERAGES:**
Weak tea (tea ball, not brewed); decaffeinated coffee; coffee substitutes. May be sweetened with Tupelo Honey if desired.

**DESSERTS:**
Fruit, unsweetened gelatin (Grayslake).

## AVOID ABSOLUTELY:

**ALCOHOLIC AND SOFT DRINKS:**
Club soda, dry ginger ale, whiskies and liquors.

**SUGAR, CANDY AND OTHER SWEETS:**
Such as cake, pie, pastries, sweet custards, puddings and ice cream.

**CAFFEINE:**
Ordinary coffee, strong brewed tea, beverages containing caffeine.

**STARCH AND SUGAR:**
Potatoes, rice, grapes, raisins, plums, figs, dates and bananas (starch and sugar).

Spaghetti, macaroni, noodles, doughnuts, jams, jellies, marmalades (starch and sugar).

Wines, cordials, cocktails and beer. (Alcohol content is a high carbohydrate.)

Ravioli, pasta, pizza and bready Mexican foods.

# HIGH PROTEIN, SINUS OR ALLERGY DIET

**BREAKFAST:** Fruit or 4 oz. of fresh juice; minimum of 1 egg with or without 2 slices of ham or bacon; ONLY 1 slice of any bread or toast with plenty of butter; beverage.

**LUNCH:** Meat, fish, cheese or eggs; salad (large serving of lettuce, tomato, or Waldorf salad with mayonnaise or french dressing); vegetables if desired; ONLY 1 slice of any bread or toast with plenty of butter; dessert; beverage.

**DINNER:** Meat, fish, cheese or eggs; salad (large serving of lettuce, tomato, or Waldorf salad with mayonnaise or french dressing); vegetables if desired; ONLY 1 slice of bread or toast with plenty of butter; dessert; beverage. Soup if desired (not thickened with flour); vegetables.

## ALLOWABLE VEGETABLES:

Asparagus, avocado, beets, broccoli, brussels sprouts, cabbage, cauliflower, carrots, celery, corn, cucumbers, eggplant, lima beans, onions, peas, radishes, sauerkraut, squash, stringbeans, tomatoes, turnips.

## ALLOWABLE FRUITS:

Apples, apricots, berries, grapefruit, melons, oranges, peaches, pears, pineapple, tangerines.

May be cooked or raw, with or without cream, but without sugar; canned fruits should be packed in water, not syrup. The raw are better if enjoyed that way.

Lettuce, mushrooms and nuts may be taken as freely as desired.

Juice: Any unsweetened fruit or vegetable juice, except grape or prune juice.

**BEVERAGES:**
Weak tea (tea ball, not brewed); decaffeinated coffee; coffee substitutes. May be sweetened with Tupelo Honey if desired.

**DESSERTS:**
Fruit, unsweetened gelatin (Grayslake).

## AVOID ABSOLUTELY:

**ALCOHOLIC AND SOFT DRINKS:**
Club soda, dry ginger ale, whiskies and liquors.

**SUGAR, CANDY AND OTHER SWEETS:**
Such as cake, pie, pastries, sweet custards, puddings and ice cream.

**CAFFEINE:**
Ordinary coffee, strong brewed tea, beverages containing caffeine.

**STARCH AND SUGAR:**
Potatoes, rice, grapes, raisins, plums, figs, dates and bananas (starch and sugar).

Spaghetti, macaroni, noodles, doughnuts, jams, jellies, marmalades (starch and sugar).

Wines, cordials, cocktails and beer. (Alcohol content is high carbohydrate.)

Ravioli, pasta, pizza and bready Mexican foods.

# SOFT FOOD (LIQUID) DIET

## FOODS ALLOWED:

1) **BEVERAGES:**
   Buttermilk, milk, milk drinks, weak tea, decaffeinated coffee.

2) **SOUP** (not very hot):
   Creamed, unspiced, puréed or strained.

3) **FRUIT JUICES** (strained):
   All allowed.

4) **CEREAL** (strained):
   Cream of rice, cream of wheat, farins, oatmeal.

5) **VEGETABLES** (strained, puréed):
   All allowed.

6) **PROTEIN:**
   Raw eggs, thoroughly blended into milk shakes, egg nogs or fruit juice.

7) **FATS:**
   Butter, cream margarine.

8) **DESSERT:**
   Plain flavored gelatin, custard (not thick), plain ice cream and sherbet (allow to melt in mouth), plain chocolate and candy (melt in mouth). Sugar is allowed.

## TYPICAL MENU:

| | |
|---|---|
| **BREAKFAST:** | Strained fruit juice, strained oatmeal, milk. |
| **MID-MORNING:** | Flavored milk shake (your doctor may specify additive). |
| **LUNCH:** | Creamed pea soup, strawberry gelatin dessert with whipped cream, decaffeinated coffee. |
| **MID-AFTERNOON:** | One egg-milk eggnog (thoroughly blended), sweetened with sugar. |
| **DINNER:** | Unspiced tomato juice (salt allowed), cream of potato or cream of tomato soup, thin custard, glass of milk, weak tea with sugar (if desired) and a squeeze of lemon (juice). |
| **ONE HOUR BEFORE BEDTIME:** | Strained fruit juice. |

## DO NOT EAT:

Alcoholic beverages or tonic, iced or very hot beverages, spicy foods (including soups and broths), unstrained fruit juices, unstrained vegetables, unstrained cooked cereal, spices, nuts.

# LOW PURINE DIET

**Do not** eat any of the following foods: Red meats (beef), fried foods, eggs, alcohol, coffee, candy, soft drinks.

You *may* supplement the protein in your diet with the following: Fish, fowl, baked ham, nuts, beans, cheese, vegetables, fruit.

## ALLOWABLE VEGETABLES:

Asparagus, avocado, beets, broccoli, brussels sprouts, cabbage, cauliflower, carrots, celery, corn, cucumbers, eggplant, lima beans, onions, peas, radishes, sauerkraut, squash, stringbeans, tomatoes, turnips.

## ALLOWABLE FRUITS:

Apples, apricots, berries, grapefruit, melons, oranges, peaches, pears, pineapple, tangerines. Fruits may be cooked or raw, with or without cream, but without sugar. Canned fruits should be packed in water, not syrup. The raw are better if enjoyed that way.

Lettuce, mushrooms and nuts may be taken as freely as desired.

Juice: Any unsweetened fruit or vegetable juice, except grape or prune juice.

## TYPICAL MENU:

**BREAKFAST:** Fruit or juice, cereal, boiled or poached egg, toast with butter and marmalade.

**LUNCH:** 2 oz. fish, sliced tomato, cole slaw, potato salad, cottage cheese, gelatin dessert, bread with butter and jam, milk.

**DINNER:** ½ grapefruit, vegetable plate with 2 hard-boiled quartered eggs and baked potato (butter, chives), whole-grain bread and butter, milk and cookies.

# LOW SODIUM (SALT) DIET

**FOODS ALLOWED** (Portion should be moderate):

1) **BEVERAGES:**
   Fruit juices, coffee, tea. Low-sodium milk if permitted by your doctor.
2) **BREAD:**
   Varied baked goods may be permitted ONLY if specially prepared without salt.
3) **CEREAL** (Salt-free — 2 portions daily):
   Puffed wheat and rice, buckwheat, oatmeal, cooked wheat, rice, macaroni.
4) **FRUIT** (3 or more portions daily):
   All allowed, except as noted below.
5) **VEGETABLES** (4 or more portions daily — fresh only):
   All allowed, except those excluded below.
6) **PROTEIN:**
   Meat, poultry, fish. Fresh and lean only, 5 oz. daily. See exclusions below. Egg (yolk only, no white), 2 may be substituted for 1 oz. meat.
7) **DESSERT** (2 portions daily):
   Gelatin, tapioca, fresh fruit, salt-free baked goods, rich pudding.
8) **FAT:**
   Sweet (unsalted) butter or margarine, vegetable oil.

## TYPICAL MENU: LOW SODIUM DIET

(Approximately 1,500 calories, 150 mg. sodium.)

| | |
|---|---|
| **BREAKFAST:** | Fresh fruit juice, oatmeal with skim milk, tea or coffee, sugar. |
| **LUNCH:** | Breast of chicken, 2 vegetables, canned peaches (water pack), tea or coffee, sugar. |
| **DINNER:** | Roast beef (lean), string beans, baked potato, raw vegetable salad, salad oil, baked apple, tea or coffee, sugar. |

## DO NOT EAT:

Canned vegetables, canned soup, meat extracts, bouillon, meat broth, pickles, relish, crackers, commercial bread, cake, self-rising flour, cheese, spinach, kale, beets, celery, shellfish, dried figs, dried raisins, commercial candy. Also **DO NOT EAT** meat, poultry or fish that has been cured, corned, salted or smoked.

# LOW SUGAR DIET

Although your diet restricts your use of foods high in sugar, you must eat a well-balanced diet daily that includes the 7 basic foods: Two groups of vegetables, fruit, meat, milk, bread and fat. By selecting your foods from ALL of those listed below, and not adding or omitting foods, you will have varied and healthful meals.

## MEASURING PORTIONS:

Use standard measuring implements — 8 oz. cup, teaspoon, tablespoon. All measurements are *level* and are usually measured *after* cooking. Measure precisely!

## COOKING:

Bake, broil or boil meat and fish. Fried food not recommended; when so prepared, the amount of fat used may not exceed the allowance for that meal. Remove your portion before adding extra fat or flour to vegetables for the rest of the family.

## DO NOT EAT:

Sugar, honey, jelly, jam, marmalade, syrup, candy, pie, cookies, pastry, cake (1½" cube of plain sponge cake allowed), soda pop, other soft drinks, regular chewing gum, condensed milk, any alcoholic drink, creamed, scalloped or fried food, *regular ice cream or ice milk, *imitation ice cream or ice milk, foods with sugar added. Examine food labels to see whether sugar is present.

*Your doctor may permit occasional small portion and limit other fats.

## FOODS ALLOWED (Small portions, or as noted):

1) **FREE LIST** (May be eaten as desired because low carbohydrate, low calorie):
   Bouillon (no fat), broth (clear), coffee, cranberries (unsweetened), gelatin (unsweetened), lemon, mustard (dry), pepper, pickle (unsweetened), rennet tablets, saccharin, seasonings and spices, tea.

2) **VEGETABLES:**
   **List A:** Eat raw vegetables as desired. When cooked, a portion is one cupful.

   Asparagus, *broccoli, *brussels sprouts, cabbage, cauliflower, celery, cucumber, eggplant, *greens, kale, mustard, spinach, lettuce, mushrooms, okra, *parsley, *peppers, radishes, rhubarb (no sugar), sauerkraut, string beans, summer squash, *tomato, *water cress.

   **List B:** One portion is ½ cup, or you may substitute an additional cup from List A, above. Beets, *carrots, onions, green peas, pumpkin, rutabagas, winter squash, turnips.

   *Eat at least one portion daily of these vegetables, high in vitamin A.

3) **FRUIT** (Unsweetened only):
   Fresh, canned, frozen or cooked (waterpack canned fruits are available). Pieces of fruit are small to medium size, berries 2/3 to 1 cup, other single portions as noted. Apple, ½ cup applesauce, 2 apricots, 4 dried ½ apricots, ½ banana, berries, *¼ cantaloupe, 10 cherries, 2 dates, 1 fresh fig, 1 dried fig, *½ grapefruit, *½ cup grapefruit juice, 12 grapes, ¼ cup grape juice, ⅛ honeydew, *orange, *½ cup orange juice, 1/3 papaya, peach, pear, ½ cup pineapple, 1/3 cup pineapple juice, 2 plums, 2 dried prunes, 2 tablespoons raisins, *tangerine, 1 cup watermelon.

   *Eat one portion daily of these fruits, high in vitamin C.

4) **BREAD EQUIVALENTS** (Single portion size):
   Bread 1 slice, 1 small biscuit, 1 small muffin, 1½" cube cornbread, cooked cereal ½ cup, dry cereal (puffed, shredded) ¾ cup, cooked rice or grits ½ cup, spaghetti or noodles ½ cup, 2 graham crackers, 20 oyster crackers (½ cup), 5 saltines, 3 soda crackers, 6 round thin crackers, 1½" cube plain sponge cake, ½ cup ice cream if doctor permits and 2 fat equivalents are omitted.

   **High Starch Vegetables:** ½ cup dry cooked beans or peas, ¼ cup vegetarian baked beans, 1/3 cup corn, 2/3 cup parsnips, ¼ cup yams or sweet potato, 1 small white potato (baked, boiled), ½ cup mashed potato.

5) **MEAT EQUIVALENTS** (single portion size):
Meat and poultry, 1 slice (⅛" x 3" x 2"); 1 frankfurter; cold cuts, 1 slice ⅛" thick (4½" sq.); 3 medium sardines; 5 medium oysters, clams, shrimp; ¼ cup crab, lobster, tuna, salmon; halibut, cod, etc., 1 slice (1" x 2" x 2"); American (cheddar) cheese, 1 slice (¼" x 3½" x 1½"); 1 egg.

6) **FAT EQUIVALENTS** (single portion size):
1 tsp. butter, margarine, mayonnaise, oil or cooking fat; 1 slice crisp bacon; 1 Tbsp. french dressing, heavy cream or cream cheese; 2 Tbsp. light cream; 6 small nuts; 5 small olives; ⅛ avocado.

7) **MILK EQUIVALENTS** (single portion size):
1 cup whole milk; ½ cup evaporated milk; ¼ cup powdered milk; *1 cup skim milk; *1 cup buttermilk.

*If milk is nonfat you have 2 added fat equivalents.

### *TYPICAL LOW SUGAR (CARBOHYDRATE) DIET (APPROXIMATELY 1,350 CALORIES)

**BREAKFAST:** ½ grapefruit (List 3); 1 egg (List 5); ½ cup oatmeal (List 4); 2 Tbsp. light cream (List 6); 1 cup buttermilk (List 7); tea or coffee as desired (List 1).

**LUNCH:** 5 medium shrimp (List 5) and 1 slice American cheese (List 5); raw vegetable salad, any amount (List 2); 5 saltines (List 4) and 1 slice bread (List 4); 1 tsp. butter (List 6); ½ cup applesauce (List 3) and ½ cup pineapple (List 3); ½ cup skim milk (List 7); tea or coffee (list 1).

**DINNER:** Bouillon (List 1); 3 slices roast beef (List 5); ½ cup green peas (List 2) and one cup broccoli (List 2); 2 small biscuits (List 4); 1 tsp. butter (List 6) and 5 small olives (List 6); ½ cup skim milk (List 7); ¼ cantaloupe (List 3); tea or coffee (List 1).

*You may substitute 1 portion of any food on the same list for each portion listed above. Use your imagination in combining the allowed foods to have an interesting menu. The foods in List 1 will be helpful in this, e.g., combining bouillon with plain gelatin and flavoring with lemon juice to make a jellied consommé.

## GENERAL WEIGHT REDUCTION DIET — #1 (APPROXIMATELY 500 CALORIES)

**BREAKFAST:** Fresh fruit, unsweetened fruit juice.

**LUNCH:** Soup, salad*.

**DINNER:** Salad*, ¼ lb. fish, fowl, pork, or meat (lean), soup.

*Oil and vinegar dressing preferred — no "heavy" dressing, such as Thousand Island, Blue Cheese, etc.

Follow the above-mentioned diet faithfully five days a week for the first week. For two days the first week, eat nothing but fresh fruit (no bananas) and unsweetened fruit juices. Eat as much as you like of these foods only.

For the second to the fourth week, follow the above diet six days a week — on the seventh day, eat nothing but fruit (fresh) and juices.

**FOLLOW THIS DIET FOR ONE MONTH:**
The average patient will loose 15 to 18 pounds the 1st month on this diet.

Before a patient is placed on this diet he should be examined thoroughly to make sure he has no conditions which might be aggravated by this diet.

# GENERAL WEIGHT REDUCTION DIET — #2 (APPROXIMATELY 1,000 CALORIES)

## TYPICAL WEIGHT REDUCTION MENU

**BREAKFAST:** ½ grapefruit or 4 oz. orange juice, 1 poached egg on 1 slice toast, 8 oz. skim milk, tea or coffee.

**LUNCH:** Large salad of lettuce, tomato, celery, radish, cucumber; 3 medium sardines, 1 slice American cheese, 1 small muffin or small roll, ½ cup skim or buttermilk, ½ cup unsweetened applesauce or small pear, tea or coffee.

**DINNER:** Bouillon, 4 oz. lean meat, fish or fowl, 1 cup brussels sprouts, ½ cup carrots, ½ cup pineapple, ½ cup skim or buttermilk, tea or coffee.

**NOTE:**
Most foods are measured after cooking. All measurements are level. Foods not forbidden may be eaten in modest portions. No-limit foods may be combined ingeniously with other foods to make delicious low-calorie dishes. For example, tomato juice may be combined with plain gelatin and flavored with spices for a jellied madrilene, excellent with a squeeze of lemon. Raw vegetable salad with a little low calorie dressing (e.g., garlic and vinegar) is tasty and filling, and may be eaten between meals.

**NO-LIMIT FOODS:**
These foods may be used generously to vary your diet and tide you over hunger periods: raw vegetables except those high in starch (most salad vegetables are allowed), fat-free bouillon or broth, dill (sour) pickles, tea, coffee, unsweetened gelatin, rennet tablets, low calorie carbonated drinks, dry mustard, lemon, unsweetened cranberries, vinegar, non-caloric sweeteners, spices, seasonings, herbs.

**DAILY PORTIONS:**
Fruit, 3 moderate pieces (or juice); skim or buttermilk, 2 glasses daily; 4 oz. lean meat, fish or fowl (cottage cheese may replace meat); 1 egg; 1½ slices bread; 2 cups of low-starch vegetables.

**DO NOT DRINK:**
Alcoholic drinks, sugar-content foods or drinks.

**DO NOT EAT:**
Dessert (except those which are sugarfree or made with skim milk), cheeses (except hoop or cottage cheese), fried foods, whole milk, condensed milk (sweetened), creamed or scalloped foods, avocado, dried fruit. (Read labels for foods sweetened with sugar.) Also avoid: catsup, chili sauce, gravy, nuts, olives, sweet pickles, rich sauces, popcorn.

# CHAPTER XI

# ORGAN DETOXIFICATION

This text has outlined, in Chapter I, how to determine what vitamins, supplements, or protomorphogens a patient should take in order to improve his health. The importance of sound nutritional counseling cannot be over emphasized. The Select Senate Committee on Nutrition and Human Needs, stated in December, 1975:

> We know that millions of Americans are literally sick with diet-related illnesses. Five of the ten leading causes of death in the United States have been connected to diets, and we know that millions of Americans are failing to realize their full potential because they do not have a proper diet. A study done in 1969 estimated that billions of dollars in economic benefits (to say nothing of spiritual benefits) are lost nationally each year because of improper nutrition. The report shows that the American public is eating blindly. Medical schools have under emphasized nutrition, with the result that the typical physical examination does not involve thorough nutritional evaluation or consulting. The starkest evidence of medical neglect of nutrition is the finding of malnutrition in hospitals. Doctors (M.D.'s) traditionally have relied, for nutritional examination and counseling, on dieticians and nutritionists, who simply are not large enough in number to handle the load. The result is that the American people know more about what their cars need than what their own bodies need. The result is that the American public is tempted by unhealthy foods on one hand and weight-reducing gimmicks on the other. The result is a physically unhealthy nation. The threat is not beri beri, pallagra or scurvy. Rather, we face the more subtle but also more deadly reality of millions of Americans loading their stomachs with food which is likely to make them obese, give them high blood pressure, heart disease, diabetes and cancer — in short, to kill them over the long term. We face the tragedy of anemic children failing in school and repeating this pattern of failure throughout their shortened lives.
>
> — United States Senate

Because of the tremendous amount of chemical food additives such as coloring, preservatives, emulsifiers, stabilizers, sweeteners as well as alcoholic beverages, carbonated beverages and many different drugs that our patients may have taken, it is often necessary that they be detoxified in order for them to absorb their food and eliminate toxins. Food and oxygen are transferred into the cells after digestion. In the cells, nutrients are metabolized into energy, carbon dioxide, water, and waste products. It is the accumulation of these wastes which frequently interferes with the normal function of the cells.

## THE LIVER & GALLBLADDER

The liver and gallbladder flush is an important detoxifying agent which will help restore the normal functional capacity of these organs in patients suffering from chronic degenerative diseases (not recommended for patients under 25 years of age). Have the patient follow these directions:

1. Monday through Saturday noon, the patient should drink as much apple juice or apple cider as his appetite will permit, in addition to his supplements and regular meals. The apple juice or apple cider should, preferably, be purchased from a health food store to assure there are no additives.
2. At noon on Saturday, the patient should eat a normal lunch.
3. Three hours later, instruct the patient to take two teaspoons of disodium phosphate, dissolved in about one ounce of hot water. The taste may be objectionable and may be followed by a little citrus juice (freshly squeezed if possible). If the patient should be on a sodium free diet, the doctor may substitute a sodium free cathartic in place of disodium phosphate, such as Epsom salts, castoria, etc. Disodium Phosphate may be obtained from Standard Process Laboratories.
4. Two hours later, have the patient repeat step 3.
5. For the evening meal, the patient may have grapefruit juice, grapefruit, or other citrus fruits or juices.
6. At bedtime, the patient has two choices:
   a) ½ cup of unrefined olive oil followed by a small glass of grapefruit juice; or
   b) ½ cup of warm, unrefined olive oil blended with ½ cup of lemon juice.

   Unrefined olive oil can be purchased from any health food store. It is best to use fresh citrus juice, but canned or bottled are permissible.

7. The patient should go immediately to bed and lie on his right side with his right knee pulled up close to his chest for 30 minutes.
8. The next morning, one hour before breakfast, have the patient take two teaspoons of disodium phosphate dissolved in 2 ounces of hot water.
9. The patient should continue his normal diet and any nutritional program that may have been prescribed.

Some patients have occasionally reported slight to moderate nausea when taking the olive oil/citrus juice; this nausea will slowly disappear by the time the patient goes to sleep. If the olive oil induces vomiting, the patient need not repeat the procedure at this time. This occurs only in rare instances. This flushing of the liver and gallbladder stimulates and cleans these organs as no other method.

Patients who have chronically suffered from gallstones, billiousness, backaches, nausea, etc. occasionally find small gallstone-type objects in the stool the following day. These objects are light green to dark green in color. They are very irregular in shape, gelatinous in texture, and vary in size from grape seeds to cherry seeds. If there seems to be a large number of these objects in the stool, the liver flush should be repeated in two weeks.

## THE KIDNEY

The kidney filters approximately 4,000 quarts of blood daily. The waste, largely urea, is eliminated and the acid/alkaline balance is maintained. Plenty of liquid should be taken daily. For normal, healthy individuals, pure spring water or distilled water should be used. For those patients that are nutritionally deficient, juices of vegetables and fruits should be used as well as whole, raw fruits in addition to any supplements that may have been prescribed. In kidney disease, protein intake is usually limited to relieve undue renal stress.

The kidney may be detoxified by using any one of the following methods:

1. Have the patient eat as much watermelon or drink as much watermelon juice as his appetite will allow. Watermelon juice can be made by putting the pulp of the watermelon into a blender and then straining it.

   Because this is a seasonal item, it's availability may be limited; thus, the following procedures might be used to achieve the same results.
2. Have the patient mix the juice from one freshly squeezed lemon with six ounces of distilled water and drink. If the taste is objectionable, the patient may use ½ teaspoon of Tupelo honey to improve the flavor.
3. Have the patient drink two glasses of unsweetened cranberry juice per day for one full week.

## THE LUNGS

Life is dependent upon the adequate exchanges of gases in the lungs. The most significant is the removal of carbonic acid and the flow of oxygen into the blood. Many other impurities are given off by the lung. Diet is important and mucous-forming foods should be avoided. One technique that many doctors overlook is that of irrigating the nose each morning. This is best accomplished by sniffing water into the nose and then blowing it out. This should be repeated several times. Once the nose is clean, deep breathing should be started for about 8 to 10 minutes, breathing only through the nose, as deeply as possible.

## THE COLON

Keeping the colon clean is of utmost importance. Defective colon function, evidenced by constipation, diarrhea or other similar conditions, can also be related to many other diseases. If the colon is not kept clean and free of debris, the toxins from food putrefaction are reabsorbed into the already overloaded bloodstream and taken to the already overburdened liver. As this cycle continues daily, the stress on the body is incalculable.

### COFFEE RETENTION ENEMA

Patients often times have a psychological barrier against enemas. This aversion is brought about by ignorance of the purpose and function of the enema as well as a misunderstanding of the proper procedure for taking an enema. It has been my experience, however, that the patient most often opposed to enemas soon reverses his prejudice and becomes an avid supporter. In many cases, the enema relieves stress and gives the patient a sense of well-being and cleanliness never before experienced. The proper removal of toxins from the colon is absolutely essential in chronic conditions of disease.

It is desirable to have the patient take the coffee enema in the morning, but it may be repeated again in the early afternoon or evening, depending upon the toxic condition of the body. Coffee enemas may interfere with sleep if administered late in the evening. Thus, many doctors recommend an enema using warm, distilled water only.

The procedure for a coffee retention enema is as follows:

1. Upon arising, the patient should make a pot of coffee. The coffee must be regular, not instant or decaffeinated. It should be made in a corningware, glass, or stainless steel coffee pot, or by using the drip method of coffee making. Use from 2 to 4 tablespoons of coffee to one quart of distilled water. Those who have a tendency to become jittery or nervous from coffee should use a weaker solution (two teaspoons of coffee per quart of distilled water).
2. While the coffee is cooling to body or room temperature, recommend that the patient perform a mild exercise, such as jogging or walking briskly.
3. The exercise usually induces a bowel movement. The enema is much more effective in the colon after it has been evacuated.
4. After the bowel movement, the patient will find that taking an enema with warm distilled water will be helpful. This initiates cleansing of the colon by removing large particles of residue and most of the gases. When completed, the patient is ready for the coffee retention enema. A warm water enema is optional; it does not need to be taken if the patient can retain the coffee enema for the desired length of time (15 minutes).
5. By this time, the coffee has cooled to body or room temperature. Pour the coffee into an enema can or douching bag. The enema tip on the end of the hose is not adequate to give a "high" enema. A colon tube between 24 to 36 inches should be purchased from a drug store and placed on the end of the enema tip.
   a) The colon tube should be lubricated with K-Y jelly or other similar lubricant.
   b) It should be inserted 18 to 20 inches into the rectum. This can be done slowly in a rotating motion to prevent the tube from "kinking up" inside the colon.
   c) If the coffee does not run into the colon, the tube may be kinked and should be partially removed until the flow of the solution is felt. The colon tube can then be inserted to the full 18 to 20 inches.
   d) The enema can or bag should not be over 18 inches higher than the body. If it is placed too high, the coffee will run into the colon too fast and under too much pressure, causing discomfort.
   e) Most doctors request the patient to use the knee-chest position by placing the chest and knees on the floor with the buttocks in the highest position possible. When approximately three-fourths of the coffee has left the enema bag, it is wise to have the patient lie on his left side until the solution is completely out of the enema bag. The colon tube is then removed. The patient should stay on his left side for at least 5 minutes, then on his right side for another 5 minutes.
   f) After retaining the enema for 15 minutes or longer, it may be expelled. The patient is now ready for his regular daily routine, feeling clean and refreshed!

   The patient should never try to take the enema while sitting on the toilet.

## PURGE
## (Alternate Method)

Immediately upon arising, instruct the patient to take one tablespoon of Epsom salts dissolved in a half glass of distilled water. Then, have the patient repeat this same procedure two more times, waiting 30 minutes each time. If the patient finds that Epsom salts are too harsh, the doctor may substitute one teaspoon of disodium phosphate for each tablespoon of Epsom salts. To clarify, this procedure should be repeated three times in 90 minutes.

The following alkalizing punch may be taken after two hours if the patient becomes hungry or one glass every hour as desired.

## ALKALIZING PUNCH

The juice of six fresh lemons, twelve oranges and six grapefruits is placed in a gallon glass jug filled with distilled water. An orange or grapefruit may be eaten in the evening. The purge must be repeated for one additional day or a total of two days every four weeks. If the patient is too weak, the purge should be administered one day every three weeks only.

During the purge, the body may undergo some rather uncomfortable sensations such as nausea, headaches, cramps and dizziness. This is the result of cleansing. Toxins which have accumulated for years are suddenly dumped, which can result in a shock to the system. These sensations are temporary and will disappear when the toxins are finally eliminated from the body. The purge should be repeated every three or four weeks.

## FASTING

After the purge, a fast must be started. The fast should last for two days unless the patient is too weak. In this case, one day of fasting is sufficient until the strength of the patient is rebuilt. This will give the body an opportunity to rest and an opportunity to cleanse itself of accumulated waste on the cellular level. Some discomfort may be experienced after the fast. Each day of the fast, one quart of fresh carrot juice or one pint of fresh celery juice should be taken, in addition to all the distilled water the patient can drink. You may also prescribe for the patient grape, lemon, cherry or apple juice in place of the carrot and celery juice if the tastes are objectionable to the patient. Any of these juices can be diluted with equal parts of distilled water or enough to suit the patient's taste.

It is important to remember that unless sufficient fluids are consumed, the poisons will become concentrated and will not be eliminated in their natural way.

# CHAPTER XII

# OTHER COMMON DISORDERS AND TREATMENT TECHNIQUES

## TEMPOROMANDIBULAR JOINT DISTURBANCES

Temporomandibular joint disturbances can cause a variety of problems such as headaches, clicking jaw, digestive disturbances, complexion problems, visual disturbances, and recurrent structural problems. The exact anatomical or physiological relationships are not well understood in all disorders that the temporomandibular joint (T.M.J.) is associated. The motor homunculus illustrations in "Gray's Anatomy," show that the face, lips, jaw, tongue and areas of mastication occupy a major portion of the cerebral cortex. The ratio is about 3,000 brain cells for the jaw, teeth and tongue to about 300 brain cells for an upper or lower extremity. The T.M.J. integrity should be examined routinely in all patients, especially if their problem is chronic or recurrent.

Before examining the T.M.J., attention must first be directed to the patient's occiput. The occiput must be level and free of any cranial faults, subluxation, or fixation. (See Chapter I.) The T.M.J. should be examined in both a recumbent and vertical position. The respiratory movement of the temporal bone parallels that of the innominate bones. On inspiration, the superior angle of the temporal bone and the temporal squama move forward as does the superior portion of the innominate.

Locate a strong lower extremity indicator muscle. Have the patient therapy localize the right jaw with his right hand and the left jaw with his left hand (both positive and negative surfaces) simultaneously. The patient's mouth should be closed (neutral position). Retest the indicator muscle. If a strong indicator muscle becomes weak, ask the patient to remove one hand at a time and retest the indicator muscle to locate the involved T.M.J. If no muscle weakness was observed in retesting the strong indicator muscle, examine for lateralization.

Once the involved side has been located, therapy localize to determine which neurolymphatic or neurovascular reflex is responsible for the positive therapy localization. For example, if the left T.M.J. shows positive therapy localization, ask the patient to therapy localize the posterior or anterior neurolymphatic or neurovascular reflex to determine which is responsible for the positive therapy localization. After the patient therapy localizes the neurolymphatic or neurovascular, which is responsible for the T.M.J. problem, the positive therapy localization will be neutralized. This is performed by simply placing the patient's opposite hand over each neurolymphatic or neurovascular reflex and leaving the one hand over the T.M.J. that positively therapy localized. Retest the indicator muscle. The neurolymphatic or neurovascular reflex, which is responsible for the T.M.J. positive therapy localization, will result in the weak indicator muscle becoming strong when the patient's opposite hand is placed over it (positive and negative surfaces). Treat the neurolymphatic or neurovascular reflex appropriately (See Chapter I) and then retherapy localize the involved T.M.J., this time using a bilateral therapy localization.

Next, therapy localize for lateralization. This is performed by having the patient open his mouth and move his jaw from side to side while therapy localizing bilaterally with both the positive and negative surfaces over each T.M.J. If the strong indicator muscle remains strong, then test the T.M.J. with the patient opening and closing the jaw as if he was chewing something. If a strong indicator muscle becomes weak during either of these therapy localizations, it indicates either the pterygoid internal/external, buccinator or masseter on one side or both sides of the jaw is in need of treatment. Ask the patient to remove one hand at a time and retest the indicator muscle to determine the side involved. Once the side of involvement is located, have the patient keep one hand over the involved T.M.J. with the patient's other hand therapy localized over the pterygoid internal/external, buccinator or masseter external muscle adjacent to the involved T.M.J. After therapy localizing the involved muscle, recheck the indicator muscle. The muscle which is responsible for the positive therapy localization, will neutralize it and the indicator muscle will once again become strong. Treatment for the pterygoid muscles is performed with one gloved hand inside the patient's jaw on the involved pterygoid muscle using spindle cell treatment. (See Chapter I.) Treatment of the masseter and buccinator is continued in the next section under closed mouth therapy localization. Following treatment, retherapy localize the T.M.J. which was treated to verify correction. If the neurolymphatic or neurovascular reflexes haven't been treated and the spindle cell treatment did not completely correct the problem, therapy localize the neurolymphatic and neurovascular reflexes and treat as indicated.

Examine the T.M.J. with the teeth tightly clenched. Simultaneously, therapy localize the right T.M.J. with the patient's right hand and the left T.M.J. with the patient's left hand. If a T.M.J. therapy localizes positively, a strong indicator muscle will become weak. Then, ask the patient to remove one hand at a time and retest the indicator muscle to determine the side involved. Once the involved side has been located, have the patient therapy localize the masseter and buccinator with his opposite hand adjacent to the involved T.M.J. If the masseter/buccinator muscles are responsible for the positive therapy localization on the T.M.J., the weak indicator muscle will be strong when retested. The masseter/buccinator group is treated most frequently with modified spindle cell techniques, but, on occasion, origin and insertion techniques may be required. (See Chapter I.) Treatment is performed by the doctor placing one of his thumbs on the superior portion of the involved masseter and his other thumb on the inferior portion of the buccinator. With firm pressure, the doctor then presses with his superior thumb on the upper most part of the masseter toward the buccinator. Simultaneously, the doctor presses with his inferior thumb the lower part of the buccinator toward the masseter. This procedure may be necessary to repeat three to four times on that visit. Following treatment, retherapy localize the involved T.M.J. to verify correction. If the neurolymphatic or neurovascular reflex treatment has not been indicated on the patient based upon therapy localization of the T.M.J., be sure to therapy localize the neurolymphatic and neurovascular reflexes. Examine them individually and treat accordingly.

Lastly, therapy localize with the patient's mouth open. The patient's right hand is on his right T.M.J. and his left hand is on his left T.M.J. If the strong indicator muscle becomes weak when the patient's mouth is open as wide as possible, ask the patient to remove one hand at a time to locate the involved T.M.J. With the patient's other hand, ask the patient to therapy localize the neurolymphatics, neurovasculars and the pterygoid internal/external buccinator and masseter muscles on the involved side. When the muscle, neurolymphatic or neurovascular, which is responsible for the weakness, is therapy localized, the positive therapy localization will become neutralized. Treatment to the muscles is the same as stated previously.

The temporalis muscle is the least frequently involved in T.M.J. problems, but, because of the movement of the temporal bone, it is wise to therapy localize it also.

As stated before, if the original T.M.J. exam and treatment were performed in a supine position, the T.M.J. should also be examined in a vertical position.

# NASAL RESPIRATORY TECHNIQUE

Nasal respiration occurs in a cycle which is controlled by a valve, the lumin nasii. For example, in a three-hour period, respiration occurs through both nostrils but domination will alternate periodically between the right and left nostril. Within this three-hour period of time, there is an equalization of air volume between the right and left naris. The nasal cycle occurs continually through a 24-hour period and has been confirmed by many researchers, including Kanel, Kenning, and Vendrislock. Based upon the research of Tondorf, this cycle occurs irrespective of septal deflections and, in many cases, of atrophic rhinitis.

As is known by many Chiropractors, if they locate a weak muscle and determine the patient's respiratory phase, it will result in strengthening the muscle. (See Respiratory Faults.) Armed with this knowledge, Dr. Goodheart began research on its application to Applied Chiropractic Kinesiological Diagnosis and Technique.

He found when therapy localizing a cranial fault, neurolymphatic or muscle weakness, that if the patient therapy localizes palms down, the right nostril respiration is invariably responsible for the increased strength. If the right nostril was completely occluded and the patient only respired through the left nostril, no increase in strength was observed.

In a cranial fault, neurolymphatic or muscle weakness, which therapy localized with the palms up (volar surface), only the left nostril respiration would result in increasing the strength. Right nostril respiration had no effect. If a patient therapy localized with palms down on the anterior surface of his body, the posterior surface should therapy localize in the same fashion. If the patient therapy localizes differently on the anterior surface then on the posterior surface, this indicates he is switched. (See Umbilical Coccygeal Contact.)

Thus, Dr. Goodheart arbitrarily assigned the right nares positive on respiration in conjunction with a palmar surface therapy localization. Conversely, the left nares was noted as being negative on respiration congruent with a volar surface therapy localization.

This technique is primarily indicated in inspiration assist, forced inspiration cranial fault, expiration assist and forced expiration cranial fault. Correct the cranial fault or respiratory assist. Then, based upon the patient's respiratory phase (expiration or inspiration) and the surface of the hands with which they are able to therapy localize, apply the nasal respiratory technique. If it is a palmar surface therapy localization, ask the patient to occlude the left nostril. Instruct the patient to inspire only through the right nostril. Retest the indicator or the area that positively therapy localized to see if it was neutralized. If it was not, ask the patient to expire only through the right nares; recheck the indicator. If a right nares inspiration neutralized the indicator, ask the patient to inspire through the right nostril several times to balance the nasal respiratory cycle. If the right nostril expiration neutralized the positive therapy localization, ask the patient to respire several times through that nostril to balance the cycle.

If it is a volar surface therapy localization, then repeat the above process, but the patient will be occluding the right nostril and respiring through the left nostril. Have the patient perform this procedure for two to three minutes in the morning and at night as the case warrants, based upon their respiratory nasal side.

# UMBILICAL-COCCYGEAL CONTACT

The patient should be able to therapy localize the anterior and posterior aspects of his body with the same surface of his hands. If the patient requires a palmar surface therapy localization on the anterior surface of his body and a volar surface therapy localization on the posterior surface, or vice versa, this indicates that the patient is switched. This type of switching is similar in principle to the umbilical/K-27 switching which was discussed in Chapter I, however, the correction is different.

Before treatment, have the patient lie on either his right or left side. The doctor should contact the umbilical neurolymphatic with one hand and the tissue over the coccyx with the other hand, simultaneously. Treatment is with soft tissue manipulation in a rotary fashion for about 30 to 45 seconds. Following treatment, verify correction by having the patient retherapy localize the anterior and posterior surfaces of his body with the same side of his hand.

# TEMPORAL TAP

In any branch of the healing arts, most doctors feel, from time to time, the need for a type of barometer to determine if adequate treatment has been rendered. The same is true in the practice of Chiropractic. The doctor will correct a subluxation or balance a muscle, etc., and occasionally will find that the patient will return on a subsequent visit with the same weakness or problem. Therapy localization has been a phenomenal scientific breakthrough; however, this same problem still occurs but with less frequency.

Temporal tap is a method that the doctor can employ to verify correction of any muscle weakness, neurolymphatic, neurovascular, cranial fault, subluxation, etc. Temporal tap also appears to have a psychological value in helping patients overcome psychological habit patterns.

As previously mentioned, temporal tap can be used to monitor any correction. For example, one finds muscle weakness of the pectoralis major clavicular. Therapy localization reveals that the neurolymphatic is responsible for the weakness. The doctor then treats the neurolymphatic (See Chapter I) with soft tissue manipulation and retests the pectoralis major clavicular; the muscle tests strong. The doctor then retherapy localizes the neurolymphatic to the pectoralis major clavicular and the muscle is retested to verify if adequate treatment was rendered to the neurolymphatic. All of this is standard Chiropractic Kinesiological procedure. Now the doctor can temporal tap not only to verify that adequate treatment was administered to the neurolymphatic, but also to determine if any of the other elements of the intervertebral foramen are involved.

The doctor should then temporal tap the patient. If the patient is right handed, the doctor would tap the left temporal sphenoidal line (T.S. line) of the patient with the doctor's right hand. The tap of the T.S. line performed by the doctor begins at the psoas point on the T.S. line and ends at the abdominal point. The motion is a light rapid tapping which covers the entire T.S. line. If any one of the contents of the intervertebral foramen are still involved and are in need of treatment, the temporal tap will reveal this by the pectoralis major clavicular becoming weak once again. The doctor will have the patient therapy localize each of the elements of the intervertebral foramen and temporal tap as each is therapy localized. When the element of the intervertebral foramen which is responsible for the muscle weakness is located, the muscle will once again become strong and remain strong as the doctor temporal taps.

Temporal tap is a quick method of determining which element or elements of the intervertebral foramen are responsible for the muscle weakness in addition to determining if adequate treatment has been rendered therapeutically and from a time standpoint. Thus, if you question if enough treatment has been rendered to a particular point or if there are any other elements of the intervertebral foramen involved, then temporal tap. In patients that are right handed, the doctor will temporal tap the patient's left T.S. line with the doctor's right hand. If the patient is truly left handed (rare), then the doctor would tap the right T.S. line of the patient. This is a very important point because of the type of energy involved. (See Therapy Localization Technique.)

In right handed patients, if the doctor taps the right T.S. line and a strong muscle becomes weak, this indicates the patient is in need of pre and post ganglionic treatment. (See Pre and Post Ganglionic Treatment.)

The handedness of a patient is very important because it is an indication of the dominant hemisphere of the brain. (See Cross Crawl Technique.) It was the trend during the early fifties to make everyone right handed. To determine the handedness of a patient, hand the patient an item or drop something and let the patient pick it up. Note the hand they use if you question the patient's handedness.

As stated before, the temporal tap also has a psychological value in helping patients overcome socially unacceptable habits, i.e. smoking, drinking, etc. Many different researchers have laid claims to manipulation of the temporal bone or tapping of the temporal bone to improve poor habit patterns or to improve one's psychological state of being. The only thing wrong with their techniques seems to be that they cannot be duplicated.

It now appears that a person can tap his own T.S. line (right hand with the right T.S. line and left hand with the left T.S. line), beginning from the psoas point and state a positive and factual statement which will help to overcome negative habit patterns psychologically, mentally or physically. i.e. you get along fine without smoking, you get along fine without drinking, you get along fine without junk food, you get along fine without being nervous. For this purpose, the left T.S. line seems to work best with positive audible statements by the patient to the patient in the abolishment of negative habit patterns. In this case, the patient taps his left T.S. line with his left hand.

Conversely, the patient can tap his right T.S. line with his right hand as described before and reinforce the statement which was made while they tapped the left T.S. line. However, the type of statements must be phrased differently. i.e. there is no need for you to smoke, there is no need for you to drink, there is no need for you to eat high calorie food, there is no need for you to be nervous, etc.

The left T.S. line will accept only positive statements and the right T.S. line will accept only negative statements. In autosuggestion this is a critical point.

At this time, it appears that the success of overcoming habit patterns with temporal tap is very good; however, the semantics used and the phraseology, in addition to the side of the head tapped, appear to be critical.

# BIOFEEDBACK & NEUROVASCULAR TREATMENT

Many times in the treatment of neurovascular receptors, while the doctor is holding the points on the patient's head, a frequent comment by the patient is, "What are you doing?," or "I didn't feel anything." Following treatment of the neurovasculars, the patient can see that the treatment was verified by increased muscular strength. This frequently results in the patient being very curious, and occasionally skeptical, about the treatment of neurovasculars. Often when the patient questioned the doctor as to exactly how and why the neurovasculars function, the doctor would be at a loss for an easy, simple-to-understand explanation.

Now, through the use of a biofeedback thermometer, a thermister can be attached to the patient's index finger (See Chapter I) and, as the neurovascular contact point is being treated, the patient can watch the dial and listen to the change in the audio volume of the instrument as it reflects the benefits of the treatment.

A biofeedback thermometer is a machine which is used in teaching patients autoregulation of peripheral blood flow. The basis for this is that the temperature of the tissue is directly related to the amount of blood flow and circulation. The instrument is highly sensitive and will record minute temperature differential.

In patients that need neurovascular treatment, who also vasoconstrict, Dr. Goodheart has found that once adequate treatment has been rendered neurovascularly, it is reflected on the biofeedback thermometer gauge by temperature stabilization. He also found that a dropping of the patient's temperature on the gauge instead of rising, indicates vasoconstriction. This further indicates that a major fault (such as ileocecal, cranial fault, etc.) has been overlooked. The biofeedback thermometer proves the very nature of the neurovasculars. (See Chapter I.)

# STRESS FACTORS IN NECK AND BACK PAIN

Many times people who are under sustained stress will suffer from back problems which do not fit into the usual categories. The adrenal glands pour adrenalin into the bloodstream in an effort to cope with stress. In prolonged cases of stress, the continued high level of adrenalin interferes with the normal maintenance and upkeep of the ligamentous tissue. This causes a basic imbalance of manganese which weakens the ligamentous tissue. Thus, lower back ligaments such as the iliolumbar or sacroiliac ligaments can be stretched beyond their normal limits, especially if there was previous damage. This stretching irritates the sensory nerve fibers which are imbedded in the ligaments. The result is pain and muscle spasm. The spasm is the body's effort to stabilize the affected area.

These patients will not therapy localize to the pelvis or back as one would expect for the type of complaints they present. Many times, because of the negative therapy localization and the patient's persistent complaints, the doctor may begin to doubt the validity of the complaint. In the breakdown of adrenalin, it must balance with leucoadrenalin. If it doesn't, it produces symptoms of low energy level, profound fatigue and extreme irritability.

## DIAGNOSIS: LOWER BACK

With the patient in a supine position, test the strength of the sartorius. (See Chapter IV.) If it shows any weakness, correct it through any one of the five elements. Place both of the patient's hands (therapy localize with positive and negative surfaces) over the sacroiliac ligament. Retest the sartorius; if it weakens, it is a positive finding. If the sartorius remained strong, examine the opposite side in the same fashion.

This procedure can also be performed with the gracilis, but with the patient in a prone position. Be sure that the gracilis tests strong before having the patient therapy localize the sacroiliac ligament.

Based upon research to date, it appears that this procedure is highly selective and will be effective only with the sartorius and gracilis muscles.

## DIAGNOSIS: NECK

The problems resulting from stress, adrenalin imbalance, and previously weakened ligaments occur in the occipital atlantal area as well as the lower back. Examine the strength of the sartorius by the standard muscle testing procedure. Then instruct the patient to put both hands in a clasped position, palms down, on top of his head and pull downward while rotating the head from side to side. While the patient is pulling downward and rotating the head, the doctor should then test the sartorius muscle in a seated or supine position. If the sartorius weakens in this manner, it is a positive finding.

## TREATMENT

If the sartorius or gracilis weakened due to therapy localization of the sacroiliac ligament or due to the downward pressure on the patient's skull, then treat the neurolymphatic to the sartorius or gracilis. (See Chapter IV.) The neurolymphatic activity should continue until the muscle tests strong with either therapy localization of the sacroiliac ligament or with downward pressure on the skull with rotation, based upon the patient's complaint. If the neurolymphatic is not adequate to correct the problem, then give the patient a tablet of whole raw adrenal (See Chapter I) to hold in his mouth while the sartorius or gracilis is retested under the same circumstances. The patient may need as many as one raw adrenal tablet per hour for the first several days to maintain correction.

# SHOCK ABSORB VS. SHOCK TRANSMIT

The joints within the body serve not only as hinges or coupling units, but also as shock absorbers. In normal walking, for example, the foot should absorb the majority of the shock and then pass a proportional amount of the shock on upward to the other joints. But due to joint fixations and subluxations, many times the joints of the body fail to absorb their proportional amount of shock, and, as a result, they transmit the shock to another joint. Because the second or third joint is not prepared innately to serve as the primary shock absorber, many recurrent and structural problems can result. Shock transmitting can occur bilaterally or unilaterally, but it is most frequently seen unilaterally. It can also occur in any of the primary shock absorbing joints, such as the feet, knees, hips, pelvis, etc.

Anytime a patient has a recurrent structural problem, he should be examined for shock transmitting. To examine for this problem, the patient should be in a recumbent position. Test a strong indicator muscle. Then, with the palmar surface of your closed fist, strike the heel of the patient's foot with a force of about 10 pounds. Retest the indicator muscle. If it becomes weak because of the trauma, this is a positive finding that the patient is shock transmitting. If the percussive force failed to weaken the indicator muscle, repeat the same procedure on the opposite side. In the case of a positive finding, begin therapy localizing each joint through which the vector of force traveled. In adjusting extremities, always adjust in the direction in which the challenge produced strength.

Experience has shown that patients exhibiting recurrent pelvic or shoulder problems and even temporomandibular joint disturbances can be treated by Chiropractors well versed in this technique.

Following correction of the joint problem, ask the patient to jump up and down about 15 times with the knees locked. Then, with the patient in a recumbent position, challenge the joint integrity once again by striking the heel and rechecking the strong indicator muscle.

# PSOAS — DIAPHRAGM TECHNIQUE

In A. E. Homewood's opinion, "No single muscle seems to be as important to the structural and functional integrity of the human as the diaphragm, and none other is more adversely influenced by emotional stresses of life." Many other anatomists have made reference to the diaphragm as the second heart.

The diaphragm is a dome-shaped musculo-fibrous septum which separates the thoracic from the abdominal cavity, but it is intimately related to both from a functional and physiological standpoint.

The psoas muscles are closely related to the diaphragm in that if one is contracted, it can distort the muscular leaves of the diaphragm and affect respiration.

When the diaphragm contracts, it should cause an equilateral expansion of the rib cage. By placing your hands bilaterally over the lower costal margins of the patient's rib cage and asking the patient to deeply inhale and exhale, the lateral and vertical motion can easily be visualized. Many times there will be only a vertical movement with very little lateral movement. More frequently there will be only vertical and lateral movement on one side, as evidenced by your hand movement on the patient's rib cage. This is a primary indication for the psoas-diaphragm technique. Measure the vital capacity with an appropriate instrument or measure the chest expansion with a tape.

Accompanying the restricted costal motion will be a slightly contracted psoas muscle on the same side, as evidenced by a lack of inward rotation of the feet and toes. This test is performed by turning the feet and toes inward while the patient is in a supine position. The amount of movement should be equal; however, on the side of restricted costal motion, the psoas will be slightly contracted and will resist inward rotation. This resistance can be felt by the examiner as he tries to turn both of the patient's feet inward. The lack of inward motion due to the contracted psoas will also be visible to the doctor.

The psoas muscles are the reactive muscles ipsilaterally to the diaphragm. (See Chapter on Reactive Muscle Testing.) The spindle cell mechanism is responsible for the contracted psoas. A reflex subluxation of the third cervical vertebra is also present in the psoas-diaphragm imbalance. Bilateral therapy localization of the third cervical with forced expiration for 10 seconds will frequently reveal the lesion as evidenced by a strong indicator muscle becoming weak. (See treatment of the conception and governing vessel.) This lesion may occasionally be seen on inspiration. A fixation is frequently encountered at the dorsal-lumbar junction, which must be corrected on expiration.

## TREATMENT

The treatment is designed to rebalance the involved psoas muscle, thus releasing the contracted diaphragm. To correct the spindle cell mechanism of the contracted psoas, raise the psoas muscle past its standard testing position to involve the iliacus muscle with the patient's toe turned lateralward. (See Psoas Major Muscle.) This brings the psoas muscle superiorly where it is easily palpable. With the psoas in this position, the doctor presses his thumb and index finger deep into the belly of the psoas muscle with a distance between the thumb and index finger of about one inch. Press with the thumb and index finger directly into the spindle cell of the muscle. Then, with a contracting type of motion with the thumb and index finger, move the spindle cell mechanism toward the center of the muscle. This may require more than one application until one becomes adept at this maneuver. Retest the inward motion of the feet and an immediate increase in inward rotation will be seen on the previously constricted psoas. Challenge the third cervical vertebra and adjust it in the direction that produced muscle weakness based upon the successful challenge. Occasionally, correction of the psoas will release the third cervical. Place the patient in a prone position and examine for a fixation at the dorsolumbar junction and make any necessary corrections. Then, therapy localize the third lumbar (Lovett Reactive Vertebra) and activate the neurolymphatic receptor to the diaphragm. (See Chapter IV.) Remeasure vital capacity to verify correction or place both hands on the patient's rib cage and note continuity of rib expansion.

# PRE AND POST GANGLIONIC TECHNIQUE

Although acupuncture energy cannot be seen, its effects on health and the musculoskeletal system can be easily demonstrated. Many "extra gifted" people frequently speak of seeing centers of energy located around the body. These centers of energy have been referred to as "vortices of energy" or "chakras."

There are seven vortices with interrelated channels which have been diagrammed and discussed by these "extra gifted" people for years. However, although they were known to exist, no one knew how to examine the vortices, nor did they know how to correct them if they were not properly balanced. Now, through right side temporal tap and therapy localization, the functional integrity of these centers can be determined.

Locate a strong indicator muscle and temporal tap the patient's right temporal sphenoid line. (See Temporal Tap.) If the strong indicator muscle weakens, this indicates that the patient's vortices are in need of pre and post ganglionic treatment. Begin therapy localizing over each of these centers simultaneously with both hands and retest the strong indicator muscle. For example, have the patient therapy localize the vortice that is located at the base of the spine with one hand and, with the other hand, therapy localize the vortice that is located at the top of the skull. Retest the strong indicator muscle. If it weakens, this indicates the point where the pre and post ganglionic treatment must be applied. If the indicator muscle remains strong, have the patient keep one hand at the base of the spine and lower the other hand to the next chakra just superior to the glabella. (See Figures G-1 and G-2.) Once again, retest the indicator muscle.

Keep in mind that these are interconnecting channels of energy; thus, each one can be therapy localized with each vortice to determine which ones are out of balance. The patient's symptomatology and the location of the vortice will be valuable indicators of where to begin therapy localization.

## LOCATION OF VORTICES

1. Top of the head.
2. Base of the skull.
3. Junction of the eyebrows.
4. External of the larynx.
5. External mid sternum.
6. External of the spleen anterior surface.
7. External of the umbilicus.
8. External one-half way between pubic bone and navel.
9. External of the sacral-coccygeal junction.

FIGURE G-1

FIGURE G-2

## TREATMENT

The treatment is performed over the involved chakra by a soft-tissue manipulation, similar to the treatment of a neurolymphatic, but not as vigorously.

For further information on the chakras, read *"Breakthrough to Creativity,"* by Shafica Karagulla, M.D., De Vorss Press, publisher, or *"The Chakras,"* by Charles W. Leadbetter, published by Quest.

# COSTOVERTEBRAL RESPIRATORY TECHNIQUE

On inspiration, as previously stated, the most inferior portion of the spinous process of the vertebra moves in an anterior and caudal (downward) direction. During inspiration, the ribs move in the opposite direction (elevate and move cephalic, superior). The levator costarum and levator costalis longus and brevis aid in the movement of the ribs and the vertebrae. The opposite motion occurs in expiration. The vertebrae move cephalic and the ribs move caudally. Thus, the normal movement of the vertebrae and the ribs are in opposite directions.

In patients who exhibit a decreased vital capacity, or who have conditions such as asthma, emphysema, diaphragmatic problems, or general respiratory difficulties, one should examine the costovertebral respiratory movement.

To examine the costovertebral respiratory movement, one would palpate the dorsal surface of each spinous process of the thoracic vertebrae seeking to find spinous process hypersensitivity. The hypersensitivity of the spinous process will be easily felt by the patient and may resemble a typical thoracic anteriority. However, the vertebra will not challenge anteriorly. In identifying the vertebra and the ribs which are in need of the costovertebral respiratory technique, one will note in palpating the spinous processes that the degree of space between the spinous process is relatively constant.

The first diagnostic indicator for this technique is that the relatively constant space between the vertebral spinous processes will be either diminished or increased depending on the phase of respiration and the lesion. After one has identified the area, challenge is necessary to determine the form of the lesion. The ribs may be involved unilaterally or bilaterally.

The challenge is performed on inspiration by pushing the spinous process downward with the thumb of one hand, while simultaneously pressing the ribs upward at the same level with the thumb and first finger of the other hand. Retest the indicator muscle, and if it was originally strong and a costovertebral lesion exists at the level challenged, it will become weak. This is considered a successful challenge.

One would naturally have to challenge in the opposite direction, if the above challenge is unsuccessful, to determine normal costovertebral movement. To repeat, the challenge would be performed by contacting the inferior angle (end) of the spinous process with the thumb of one hand and the ribs at the same level with thumb and first finger of the opposite hand. Then press the ribs downward with one contact and the spinous processes with the other thumb, pushing upward coincident with expiration. Retest the original, strong indicator muscle. If it becomes weak, this is the phase of respiration the lesion must be corrected.

The correction is made in the same direction as the successful challenge. The motion of the correction is the same as the challenge, but with a short, sharp thrust. Usually, one will hear a slight, audible release; however, this is not necessary. One should then repalpate the spinous processes and rechallenge to verify the correction.

# CHAPTER XIII

## CLINICAL FINDINGS IN NERVE ROOT AND DISC SYNDROMES

Normally, nerve roots are free in the intervertebral canals and can be moved within a definite range of motion. The amount of motion of the nerve roots varies depending upon their location in the spine. Nerve root motion within the intervertebral canal can range from one-sixteenth of an inch to one-half inch, once again, depending upon the level of the nerve root.

A nerve root syndrome is a term used to classify a group of symptoms and clinical findings which occur as a result of injury or sustained irritation. Nerve roots can be injured by vertebral subluxations, osteophytic changes, encroachments, vertebral disc insults, herniations, ruptures, degenerations and protrusions. The following graphs of nerve root and disc syndromes are presented on the nerve roots and discs which are most frequently involved.

Any mechanical irritation which can cause a nerve root syndrome can also cause an irritation of the autonomic nervous system either by direct irritative factors or by reflex stimulation. For example, the fifth, sixth, seventh and eighth cervical nerve roots have been demonstrated to contain pre-ganglionic sympathetic fibers. Irritation of those nerve roots may give rise to symptoms and findings of direct stimulation of the sympathetic components contained within these nerves.* Also, inflammation of the ligamentous and capsular structures may give rise to reflex stimulation of the cervical sympathetics, a branch of the autonomic nervous system. Naturally, the potential involvement of the autonomic nervous system varies with the level of the nerve root involved.

The symptoms and clinical findings of nerve root irritation vary somewhat in each individual because of causative factors and due to degrees of compression. In the author's clinical experience, after examining over 10,000 patients, I have found in cases of marked derangement of the cervical and lumbar vertebral spine, that the patient may only exhibit minimal symptoms and clinical findings, whereas in other patients with rather minor vertebral spinal misalignment, the patient may exhibit a marked symptomatology with a motor deficit and sensory loss.

X-rays of the spine may show a loss of the normal curve, scoliosis, and narrowing of the disc space, however, they will not reveal a disc protrusion or herniation nor will they reveal thickening, adhesion of the nerve roots or minimal foraminal encroachments. In these conditions, x-rays are only diagnostic indicators; however, they should be taken to eliminate the possibility of osseous pathology. In the case of osseous pathology, if it is visualized on the x-ray, order the necessary clinical laboratory tests to verify diagnosis. (See Chapter VII.)

Electromyograph (EMG) may be of value in localizing the site of a ruptured disc or a nerve root lesion if the characteristic denervation potentials can be demonstrated in muscles of a particular nerve root distribution. The problem with an EMG is that it provides ambiguous answers to clinical problems.

Myelographs will not provide an absolute answer for location of disc herniations either, and they are of no value in the average nerve root syndrome. Authorities differ on the accuracy of myelographs, but it is somewhere in the area of 60 percent.

The Chiropractor should be the doctor that understands most about the typical findings in nerve root or disc syndromes. The Chiropractor who is capable of adjusting the segment back into place, reducing nerve irritation and balancing the musculature surrounding the weak structure, affords the patient the greatest opportunity for healing of a nerve root or disc lesion. An injury to the spine frequently weakens the musculature; thus, it must be strengthened to help support the area not only structurally but also physically, so that healing can occur as rapidly as possible. The patient may also be suffering from nutritional deficiencies which may have precipitated the structural weakness. Correction of the nutritional deficits will aid in the healing of the injured area.

Conservative Chiropractic care offers the patient the most advanced and civilized care available with the least amount of cost and risk to the patient. However, the Chiropractor that does not maintain adequate records to determine the patient's degree of response or lack of response, does an injustice to the patient, his profession and himself. The vast majority of nerve root and disc syndromes can be treated successfully with Chiropractic care. However, those that require surgical intervention should be referred to a competent neurologist or orthopedist as soon as the Chiropractor is aware that the patient's degree of injury is beyond the Chiropractor's scope of practice.

### DEFINITION OF TERMS

Hypesthesia: decreased sensation.
Hyperesthesia: increased sensation.
Paresthesia: numbness or pins and needles.
Anesthesia: loss of sensation.

The symptoms and clinical findings which differentiate nerve root syndromes from disc herniations are often confusing. Thus, to help distinguish between the two, the following graphs are provided for the doctor's convenience.

## CLINICAL FINDINGS IN A FIFTH CERVICAL RUPTURED DISC

| DESCRIPTION | PICTORIAL EXPLANATION |
|---|---|
| The Foramina Compression Test causes paresthesia in the thumb and radial side of the hand, on the side of involvement. | |
| Hypesthesia in the sixth cervical dermatome on the dorsal, lateral and radial aspect of the arm. | 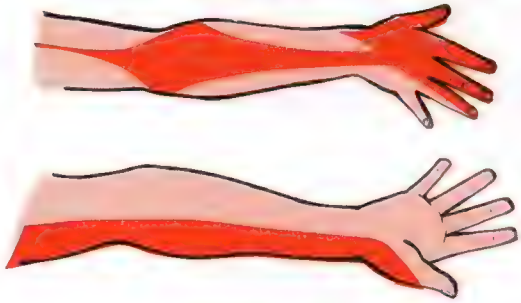 |
| Fibrillations, weakness or atrophy of the biceps. | 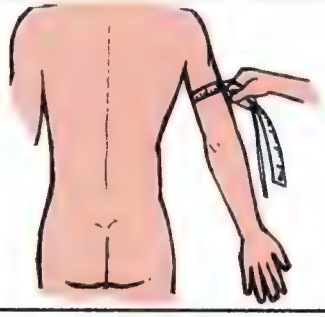 |
| Decreased biceps reflex. | 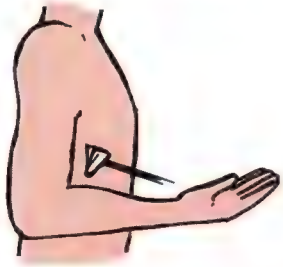 |

# CLINICAL FINDINGS IN A SIXTH CERVICAL RUPTURED DISC

| DESCRIPTION | PICTORIAL EXPLANATION |
|---|---|
| Foramina Compression Test causes paresthesia in the index and middle fingers and the dorsum of the hand. | |
| Hypesthesia in the seventh cervical dermatome, the index finger, middle finger, and the dorsum of the hand. | |
| Fibrillation, weakness or atrophy of the triceps. Subjective pain in the rhomboid area. | 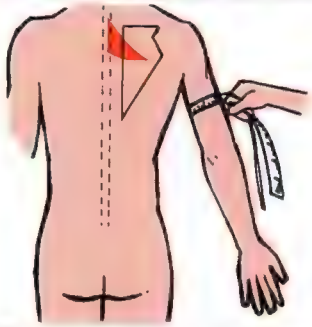 |
| Decreased triceps reflex. | 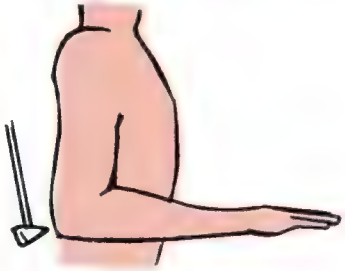 |

In a ruptured disc of the fifth or sixth cervical, there is usually restricted cervical range of motion accompanied by pain. Frequently, in a ruptured disc of the cervical spine, percussion of the spinous process will produce pain down the dermatomal area. Also, coughing or sneezing may produce pain down the dermatomal area. It is not at all unusual for the patient in consultation to relate the areas of paresthesia or hypesthesia by saying, "It feels like pins and needles here," or "This area is so sensitive that I can't stand for my clothes to touch it." 97 percent of ruptured discs of the cervical spine occur in either the fifth or sixth cervical discs.

# NERVE ROOT SYNDROMES

## SIXTH CERVICAL NERVE ROOT SYNDROME

| DESCRIPTION | PICTORIAL EXPLANATION |
|---|---|
| Paresthesia and hypesthesia of the thumb and part of the index finger. |  |
| Subjective pain on palpation over the deltoid and rhomboid muscles. | 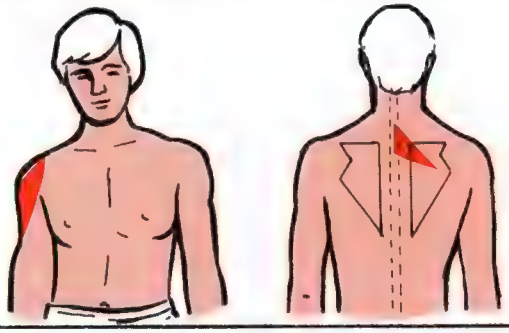 |
| Weakness of the deltoid and biceps muscles. | |
| Decreased biceps reflex. | 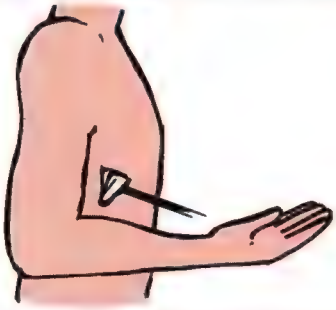 |

# SEVENTH CERVICAL NERVE ROOT SYNDROME

| DESCRIPTION | PICTORIAL EXPLANATION |
|---|---|
| Paresthesia and hypesthesia of the radial surface of the index and middle fingers. | 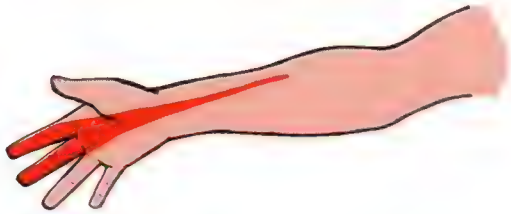 |
| Subjective pain on palpation of the lateral and dorsal upper arm, also of the medial and superior angle of the scapula and rhomboid area. | 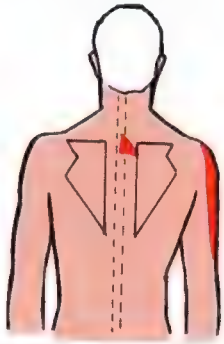 |
| Weakness of the triceps and occasionally the biceps. | |
| Decreased triceps reflex. | 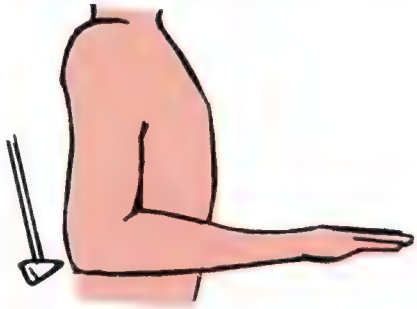 |

## EIGHTH CERVICAL NERVE ROOT SYNDROME

| DESCRIPTION | PICTORIAL EXPLANATION |
|---|---|
| Paresthesia and hypesthesia of the inner forearm and of the dorsal surface of the hand and last two fingers. | 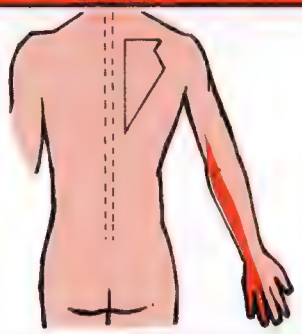 |
| Subjective pain on palpation from the scapula down the inner arm. | 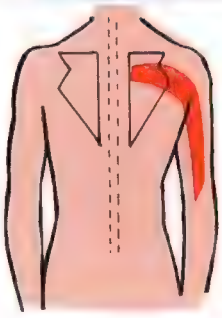 |
| Muscle weakness of the forearm and hand. | |
| No reflex changes. | All normal reflexes. |

Nerve root syndromes have many common characteristics. All exhibit cervical rigidity or a limited range of cervical motion. There is extreme tenderness over the nerve root where it emits from the vertebral foramen on palpation. Sneezing or coughing will increase the pain and paresthesia. Once again, the importance of a good consultation cannot be over emphasized. Frequently, the patient will relay areas of paresthesia or hypesthesia in terms of, "I get pins and needles here," or "Boy, when I sneeze I have so much pain here."

In nerve root irritation due to severe trauma (whiplash, etc.) the reflexes may be hyperactive following the trauma. However, several days after the acute trauma, the reflexes usually become hypoactive. The vast majority of nerve root syndromes that occur in the cervical spine take place in the nerve roots C-6 through C-8.

## DORSAL NERVE ROOT SYNDROME

Nerve root syndromes in the dorsal spine are less frequent than cervical or lumbar nerve root syndromes. In dorsal nerve root syndromes, the pain follows the course of the nerve from the intervertebral foramen to the ventral surface of the patient's body. The sympathetic nervous system can easily be affected by a dorsal nerve root syndrome. Frequently, dorsal nerve root syndromes are mistaken for angina pectoris or an abdominal disorder.

# LUMBAR DISC SYNDROMES

A certain percentage of every Chiropractor's practice is patients with low back problems. Often, because of the acuity or the chronicity of the patient, the doctor may wonder if the patient's disc is ruptured. The following graphs illustrate the typical clinical findings in a ruptured disc affecting the nerves from L-4 to S-2. Ninety-five percent of the ruptured lumbar discs affects one of these nerves.

Common findings in patients with low back pain, begin in the consultation with the patient describing his area of pain and numbness. The pain usually occurs immediately or within hours after the injury. The lumbar area is usually flattened and the pain is accentuated by forward bending, coughing, sneezing or straining at the stool. The pain is usually relieved by the patient being in a recumbent position. Most ruptured disc patients have a history of many injuries to their lower back, but each time the recuperative time is longer.

Sciatic pain usually develops at the time or after the low back pain, or the patient may have sciatic pain in the absence of back pain. It may first begin as an ache in the buttock followed by pain in the back of the thigh, then the calf and finally the heel and foot.

The pain that accompanies most cases of disc lesions or ruptures can be relieved somewhat by the patient becoming recumbent. In most cases of pain from spinal cord tumors, the pain is increased with rest.

The Lasegue's Test, Braggard's Test, Goldthwait's Test, and Kemp's Test are excellent tests to perform on patients suspected of a disc lesion. The Well-Leg Raising Test is also another good test to perform in these patients. For additional information on performing orthopedic tests, see Chapter V.

Quenckenstedt's Sign, Jugular Compression Test, or Naffziger's Test

Compression of the jugular veins by the examiner increases the radicular type pain produced by a ruptured lumbar disc.

The term disc syndrome is used to signify a group of symptoms and clinical findings which occurs as a result of severe injury to the disc. The most common afflictions to the disc are protrusion, nucleus pulposus shiftings and degeneration. The following graphs represent the typical findings in a ruptured or herniated disc. Due to the complexity and the arrangement of the nerves, overlapping dermatomes, and the different directions in which a disc can rupture or herniate, the graph may not be accurate for each and every patient with a ruptured disc. However, by and large, the majority of the findings will be accurate.

In the author's experience, approximately 45 percent of the patients with all the cardinal findings of a ruptured disc have responded to conservative Chiropractic treatment. Naturally, the degree and location of the rupture is the determining factor as to whether surgical intervention will be necessary. The patient should be made aware of the doctor's diagnosis and the percentage of recovery. In all cases the author has managed, the patient was required to be immobilized for a period of not less than 7 days nor more than 30 days.

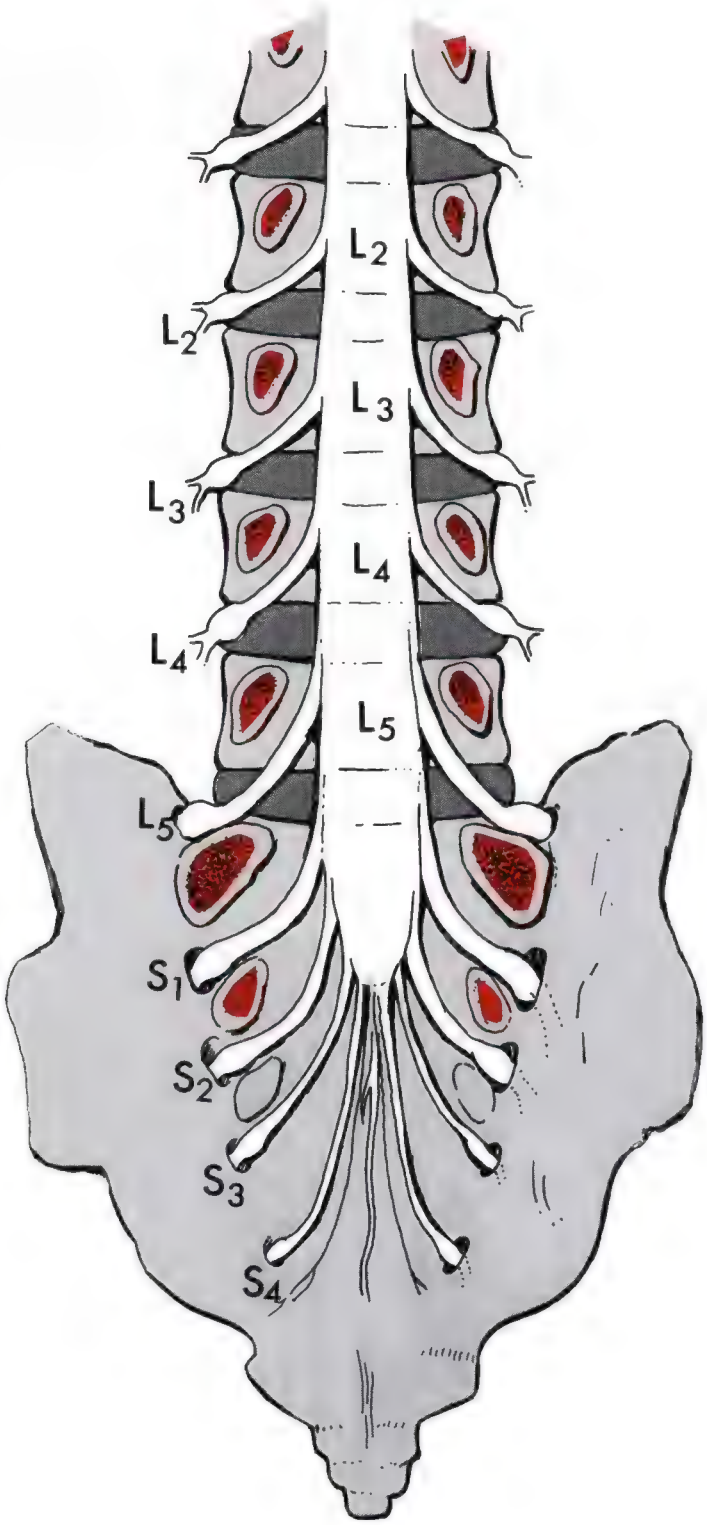


SAGITTAL POSTERIOR VIEW OF THE LUMBOSACRAL NERVE ROOTS AND THEIR NORMAL ANATOMICAL RELATIONSHIP TO THE DURAL SAC, LUMBAR VERTEBRA BODIES, DISC AND SACRAL CANAL.

# L-4 RUPTURED DISC

| DESCRIPTION | PICTORIAL EXPLANATION |
|---|---|
| Pain originates in the upper gluteal region and radiates to the anterior and medial side of the thigh, down to the knee. Sometimes the pain extends down the anterior of the leg but not into the foot. | 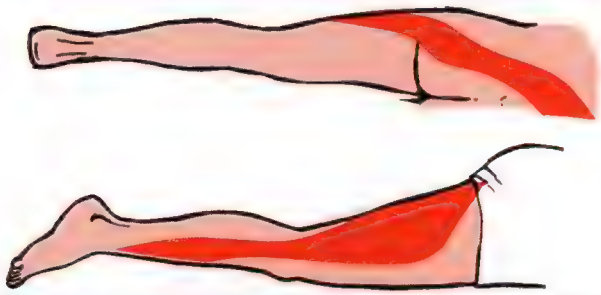 |
| Paresthesia or hypesthesia in the anterior and medial thigh and sometimes the knee. | |
| Muscle weakness and atrophy of the quadriceps. | 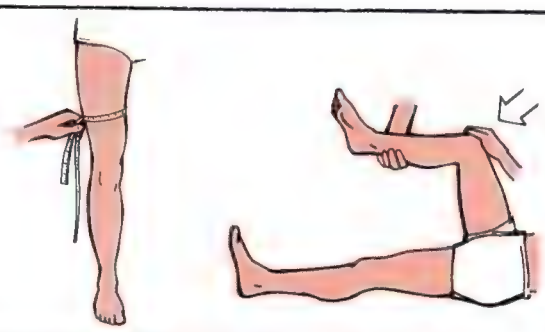 |
| The patellar reflex will be absent or decreased. | |

# L-5 RUPTURED DISC

| DESCRIPTION | PICTORIAL EXPLANATION |
|---|---|
| Pain originates over the sacroiliac joint and radiates across the gluteal region, down the posterior and lateral side of the thigh and then down the lateral aspect of the leg to the level of the lateral malleolus. | |
| Paresthesia or hypesthesia along the lateral aspect of the leg and web of the big toe. | |
| A typical finding in a L-5 disc rupture is paresis of the brevis and longus extensor muscles of the big toe. In severe cases, there will be paresis of the extensors in all the toes. There will be only minor atrophy. | |
| Rarely any reflex changes, but if the rupture is severe, the posterior tibial reflex will be decreased or absent. | 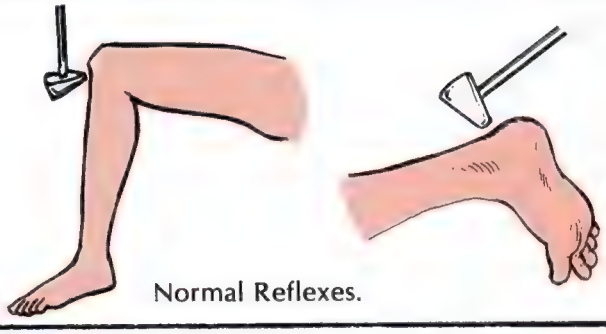 Normal Reflexes. |

# S-1 SYNDROME

*(Most frequently caused by an L-5 ruptured disc.)*

| DESCRIPTION | PICTORIAL EXPLANATION |
|---|---|
| Pain originates over the sacroiliac joint and radiates across the gluteus maximus and down the posterior thigh and leg into the heel. | |
| Paresthesia or hypesthesia in the back of the calf, lateral heel, foot and little toe. | 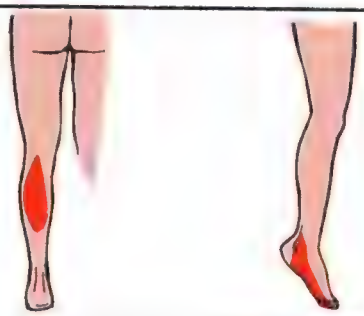 |
| Muscle weakness of the anterior tibia muscles and plantar flexors of the foot and big toe. The patient has difficult heel and toe walking. (See Chapter on Orthopedics.) | |
| Atrophy frequently occurs in the gastrocenmius and soleus. | |
| The Achilles tendon reflex is decreased or absent. | 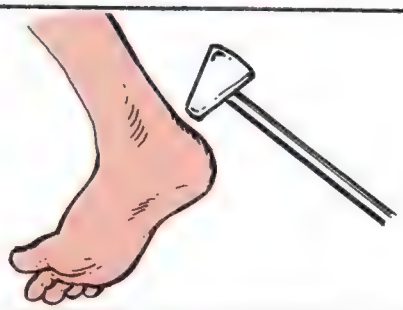 |

## S-2 SYNDROME

*(Most frequently caused by an L-5 ruptured disc.)*

| DESCRIPTION | PICTORIAL EXPLANATION |
|---|---|
| Pain originates in the center of the gluteus maximus muscle and radiates down the posterior and medial side of the thigh and medially into the posterior calf. S-2 also innervates the pelvic organs, and, as a result, pelvic pain radiates toward the inguinal canal. S-2 syndromes cause pelvic pain in addition to sciatic pain. | |
| Dermal changes are variable because an S-2 lesion frequently involves S-1, S-3 and S-4. Generally, there is paresthesia or hypesthesia over the S-2 dermatome and medially in the plantar part of the heel. The scrotum or labia majora will also reflect the same dermal change. | |
| Muscle weakness and atrophy are variable. Atrophy may be extensive. It is not uncommon to have partial paralysis of the leg. The bowel may be sluggish and there may be bladder paresis. | 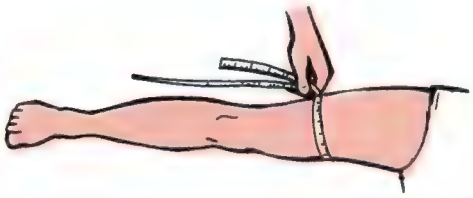 |
| The Achilles tendon reflex is decreased. | 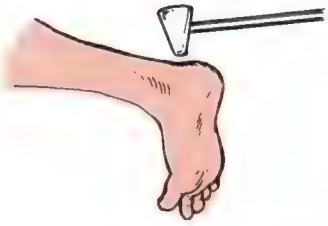 |

*Evans, J. S., *"Reflex Sympathetic Dystrophy,"* Ann. Intern. Med., 26:417-426 — March, 1947.

# BIBLIOGRAPHY


Abehsera, Michel. ed. **Healing Ourselves.** New York, 1973.

American Medical Association Committee on Rating of Mental and Physical Impairments. **Guides to the Evaluation of Permanent Impairment.** N.p., 1971.

Austin, Mary. **Acupuncture Therapy.** New York, 1972.

Beeson, Paul B., M.D. and Walsh McDermott, M.D., eds. **Textbook of Medicine.** 12th ed. Philadelphia, 1967.

Brodal, A., M.D. **Neurological Anatomy in Relation to Clinical Medicine.** 2nd ed. New York, 1969.

Burke, Roger K., Ph.D., F.A.C.S.M., and Philip J. Rasch, Ph.D., F.A.C.S.M. **Kinesiology and Applied Anatomy.** 5th ed. Philadelphia, 1974.

Chance, M. Dean. **Examination and Insurance Report for Back Injuries.** New York, 1961.

Chusid, Joseph G., M.D. and Joseph J. McDonald, M.D. **Correlative Neuroanatomy and Functional Neurology.** 11th ed. California, 1962.

Collins, R. Douglas, M.D. **Illustrated Diagnosis of Systemic Diseases.** Philadelphia, 1972.

Cozen, Lewis, F.A.C.S. **Office Orthopedics.** 3rd ed. Philadelphia, 1959.

Cyrias, James, M.D., M.R.C.P. **Cervical Spondylosis.** New York, 1971.

Daniels, Lucille, M.A. and Catherine Worthingham, Ph.D. **Muscle Testing Techniques of Manual Examination.** 3rd ed. Philadelphia, 1972.

Elliot, Frank A., M.D., F.R.P. **Clinical Neurology.** Philadelphia, 1966.

Fox, Robert M. **The Medicolegal Report, Theory and Practice.** Boston, 1969.

Gallert, Mark L., M.D., M.S.C. **New Light on Therapeutic Energies.** Greenwood, So. Carolina, 1966.

Goodheart, George J. **Applied Kinesiology.** N.p., 1964.

_____. **The Cranial Sacral and Nutritional Reflexes and their Relationship to Muscle Balancing.** 6th ed. N.p., 1968.

_____. **Collected Published Articles and Reprints.** 1st ed. Detroit, Michigan, 1969.

_____. **Applied Kinesiology, 1970 Research Manual.** 7th ed. N.p., 1970.

_____. **Applied Kinesiology, 1970 Research Manual.** 8th ed. N.p., 1971.

_____. **Applied Kinesiology, Workshop Manual.** N.p., 1972.

_____. **Applied Kinesiology, 1973 Research Manual.** 9th ed. N.p., 1973.

_____. **Applied Kinesiology, 1974 Research Manual.** N.p., 1974.

_____. **Applied Kinesiology, 1975 Research Manual.** N.p., 1975.

_____. **Applied Kinesiology, 1976 Research Manual.** N.p., 1976.

Gray, Henry, F.R.S. **Anatomy of the Human Body.** 27th ed. Philadelphia, 1961.

Graziano, Joseph. **Footsteps to Better Health.** N.p., 1973.

Guyton, Arthur C. **Textbook of Medical Physiology.** 2nd ed. Philadelphia, 1961.

Hepler, Opal, E., Ph.D., M.D. **Manual of Clinical Laboratory Methods.** 4th ed. Illinois, 1962.

Herlin, Lennart, M.D. **Sciatic and Pelvic Pain Due to Lumbosacral Nerve Root Compression.** Springfield, Illinois, 1966.

Hite, K. Eileen, Ph.D., M.D. and Florence C. Kelly, M.S., Ph.D. **Microbiology.** 2nd ed. New York, 1955.

Homewood, A. E., B.T.A., D.C., N.D., F.I.C.A. **The Neurodynamics of the Vertebral Subluxation.** N.p., 1963.

Houser, R. H., D.C., Joseph Janse, D.C. and B. F. Wells, D.O., D.C. **Chiropractic Principles and Techniques.** Chicago, 1947.

Jackson, Ruth, B.A., M.D., F.A.C.S. **The Cervical Syndrome.** 2nd ed. Illinois, 1958.

Kneeland, Yale, Jr., M.D. and Robert F. Loeb, M.D., eds. **Martini's Principles and Practice of Physical Diagnosis.** 3rd ed. Philadelphia, 1962.

Lawson-Wood, Denis, F.A.C.A. and Joyce Lawson-Wood. **The Five Elements of Acupuncture and Chinese Massage.** 2nd ed. Northamptonshire, 1973.

Lyght, Charles E., M.D., and John M. Trapnell, M.D., eds. **The Merck Manual.** 11th ed. Rahway, N.J., 1966.

Maigne, Robert, M.D. **Orthopedic Medicine, A New Approach to Vertebral Manipulations.** Illinois, 1972.

Mann, Felix, M.B. **Acupuncture, The Ancient Art of Healing and How It Works Scientifically.** New York, 1973.

_____. **Acupuncture, The Ancient Chinese Art of Healing.** New York, 1972.

Moss, Louis, M.D. **Acupuncture and You.** New York, 1964.

O'Donoqhue, Don H., M.D. **Treatment of Injuries to Athletes.** Philadelphia, 1969.

Palos, Stephan. **The Chinese Art of Healing.** New York, 1972.

Palmer, D. D. **Textbook of the Science, Art and Philosophy of Chiropractic.** Oregon, 1910.

Pharoah, Donald O., D.C., Ph.C. **Chiropractic Orthopedy.** Iowa, 1956.

Rice, Carl O., M.D., M.S., Ph.D., F.A.C.S. **Calculation of Industrial Disabilities of the Extremities and the Back.** 2nd ed. Illinois, 1968.

Risley, William B., D.C. **Quick-Reference Laboratory Manual for the Chiropractor.** N.p., 1973.

Sanford, Arthur Hawley, A.M., M.D., James Campbell Todd, Ph.B., M.D., and Benjamin B. Wells, M.D., Ph.D. **Clinical Diagnosis by Laboratory Methods.** 12th ed. Philadelphia, 1958.

Schmorl, George. **The Human Spine in Health and Disease.** ed. E.F. Besemann, M.D., New York, 1971.

Seddon, Sir Herbert, C.M.G. **Surgical Disorders of the Peripheral Nerves.** Baltimore, Maryland, 1972.

Sierra, Ralph U. **Chiropractic Handbook of Applied Neurology.** Mexico, 1956.

Smith, John H., D.C. **Applied Kinesiology and the Specific Muscle Balancing Technique.** N.p., 1971.

Stoddard, Alan, M.B., B.S., D.O., D.Phys.Med. **Manual of Osteopathic Practice.** New York, 1969.

Thie, John F., D.C. with Mary Marks. **Touch For Health.** Santa Monica, California, 1973.

Thompson, Clem W., Ph.D., F.A.C.S.M. **Kranz Manual of Kinesiology.** 5th ed. St. Louis, 1965.

Thurber, Packard. **Evaluation of Industrial Disability.** 2nd ed. New York, 1960.

Turek, Samuel L., M.D. **Orthopaedics Principles and their Application.** 2nd ed. Philadelphia, 1967.

# INDEX


**A**

ABDOMINAL MUSCLES, **15**
ABDOMINAL OBLIQUE (EXTERNAL), **110-111**
Action, 110
Anatomical drawing, 111
Associated muscles, 110
Connecting points, 111
Cranial stress center, 110
Exercise, 110
Holding points, Acu-therapy (Photo), 111
Insertion, 110
Internal manifestations, 110
Lab tests, 110
Meridian, 110-111
Muscle test (Photo), 110
Nerve supply, 110
Neurolymphatic receptors, 110-111
Nutrition, 110
Origin, 110
Palpation, 110
Structural weakness, 110
ABDOMINAL OBLIQUE (INTERNAL), **112-113**
Action, 112
Anatomical drawing, 112
Associated muscles, 112
Connecting points, 113
Exercise, 112
Holding points, Acu-therapy (Photo), 113
Insertion, 112
Internal manifestations, 112
Lab tests, 112
Meridian, 112-113
Muscle test (Photo), 112
Nerve supply, 112
Neurolymphatics, 112-113
Nutrition, 112
Origin, 112
Palpation, 112
Structural weakness, 112
ABDOMINAL PAINS, **196**
Severe, 324
ABDOMINALS, **7, 21, 49, 71, 110-117**
External abdominal oblique
See abdominal oblique (external)
Internal abdominal oblique
See abdominal oblique (internal)
Meridian, 71
Posture, effect on, 7
Rectus abdominis
See abdominis-rectus
T.S. line location, 15
Transverse abdominis
See abdominis-transverse
Weakness, 136
ABDOMINIS-RECTUS, **114-115**
Action, 114
Anatomical drawing, 115
Associated muscles, 114
Connecting points, 115
Cranial stress center, 114
Exercise, 114
Holding points, Acu-therapy (Photo), 114
Iliac crest, effect on, 3
Insertion, 114
Internal manifestations, 114
Lab tests, 114
Meridian, 114
Muscle test (Photo), 115
Nerve supply, 114
Neurolymphatic receptors, 20, 21, 114, 115
Nutrition, 23, 114
Origin, 114
Palpation, 114
Structural weakness, 114
ABDOMINIS-TRANSVERSUS, **116-117**
Action, 116
Anatomical drawing, 116
Associated muscles, 116
Connecting points, 117
Exercise, 116
Holding points, Acu-therapy (Photo), 117
Insertion, 116
Internal manifestations, 116
Lab tests, 116
Meridian, 116-117
Muscle test (Photo), 116
Nerve supply, 116
Neurolymphatic receptors, 20, 21, 116, 117
Nutrition, 23, 116
Origin, 116
Palpation, 116
Posture, effect on, 3
Structural weakness, 116
ABDUCTION, **270**
ACETONE, **318, 321**
ACETONURIA, **302**
ACHLORHYDRIA, **304, 321**
ACID PHOSPHATASE, **310, 319, 321**
ACID URINE, **303**
ACROMEGLIA, **314**
ACROMIO-CLAVICULAR JOINT, **339**
ACUPUNCTURE, **14**
ACUPUNCTURE MERIDIAN CONNECTOR, **9, 86**
ACU-THERAPY, **67**
Laws of, 78
ADAM'S POSITION, **252**
ADDISON'S DISEASE, **309, 315**
ADDUCTION, **270**
ADDUCTOR BREVIS, **118-119**
Action, 118
Anatomical drawing, 119
Associated muscles, 118
Connecting points, 119
Cranial stress center, 119
Exercise, 118
Holding points, Acu-therapy (Photo), 119
Insertion, 118
Internal manifestations, 118
Lab tests, 118
Meridian, 118-119
Muscle test (Photo), 119
Nerve supply, 118
Neurolymphatic receptors, 118-119
Neurovascular receptors, 119
Nutrition, 118
Origin, 118
Palpation, 118
Structural weakness, 118
ADDUCTOR LONGUS, **120-121**
Action, 120
Anatomical drawing, 121
Associated muscles, 120
Connecting points, 121
Cranial stress center, 120
Exercise, 120
Holding point, Acu-therapy (Photo), 121
Insertion, 120
Internal manifestations, 120
Lab tests, 120
Meridian, 120
Muscle test (Photo), 120
Nerve supply, 120
Neurolymphatic receptors, 120
Neurovascular receptors, 120
Nutrition, 120
Origin, 120
Palpation, 120
Structural weakness, 120
ADDUCTOR MAGNUS, **122-123**
Action, 122
Anatomical drawing, 123
Associated muscles, 122
Connecting points, 123
Cranial stress center, 122
Exercise, 122
Holding points, Acu-therapy (Photo), 123
Insertion, 122
Internal manifestations, 122
Lab tests, 122
Meridian, 122
Muscle test (Photo), 122
Nerve supply, 122
Neurolymphatic receptors, 122
Neurovascular receptors, 122
Nutrition, 122
Origin, 122
Palpation, 122
Structural weakness, 122
ADDUCTOR PECTINEUS, **124-125**
Action, 124
Anatomical drawing, 125
Associated muscles, 124
Connecting points, 125
Cranial stress center, 124
Exercise, 124
Holding point, Acu-therapy (Photo), 125
Insertion, 124
Internal manifestations, 124
Lab tests, 124
Meridian, 124-125
Muscle test (Photo), 124
Nerve supply, 124
Neurolymphatic receptors, 124, 125
Neurovascular receptors, 124
Nutrition, 124
Origin, 124
Palpation, 124
Structural weakness, 124
ADDUCTORS, **3, 7, 16, 21, 49, 71, 118-125**
Brevis (See adductor brevis)
Longus (See adductor longus)
Magnus (See adductor magnus)
Meridian, 71
Neurolymphatic receptors, 16, 17, 20, 21
Nutrition, 23
Posture, effect on, 3, 7
T.S. line location, 15

ADHESIONS, **254, 255**
ADRENAL CORTEX, **309**
ADRENAL CORTEX
HYPERFUNCTION, **296**
ADRENAL CORTICAL, **122**
ADRENAL CORTICAL
FUNCTION, **118, 120**
ADRENAL CORTICAL
FUNCTION TEST, **140, 158**
ADRENAL CORTICAL
HYPERACTIVITY, **305**
ADRENAL CORTICAL
HYPOFUNCTION, **309**
ADRENAL EXTRACT, **23, 24**
ADRENAL HYPERFUNCTIONS, **302**
ADRENAL HYPERPLASIA, **315**
ADRENAL INSUFFICIENCY, **305**
ADRENALS
Gastrocnemius, 138-139
Gracilis, 146-147
Nutrition, 23, 24
Sartorius, 220-221
Soleus, 224-225
ADSON'S MANEUVER, **260**
AEROBACTER AEROGENES,
**317**
AGNOSIA, **275**
AGRANULOCYTOSIS, **296**
ALARM POINTS, **9, 78, 81**
ALBUMIN, **318, 319, 321, 323**
ALBUMINURIA, **302**
ALCALIGENES, **317**
ALDOSTERONE, **305**
ALFALFA, **24**
ALKALINE PHOSPHATASE,
**310, 318, 319, 321**
ALKALINE URINE, **303**
ALKALOSIS, **309**
ALKAPTONURIA, **301**
ALLEN'S TEST, **261**
ALLERGENIC CONDITION, **176**
ALLERGIES, **146, 158, 166, 168,**
**170, 172, 174, 176, 192, 194, 220,**
**222, 224, 296, 318, 328**
Characteristics of, 328
Nutrition, 23
Treatment of, 328
ALLERGY TECHNIQUE, **328**
Blood pressure in, 328
Cranial fault, 328
Muscle weakness, 328
Nutritional imbalance, 328
Signs of, 328
ALTERNATOR, **8**
AMENORRHEA, **315**
AMORPHOSUS SUBSTANCES,
**303**
AMYLASE, **319**
AMYLOIDOSIS, **302, 303**
AMYOTROPHIC LATERAL
SCLEROSIS, **279, 304**
ANCONEUS, **126-127**
Action, 126
Anatomical drawing, 127
Associated muscles, 126
Connecting points, 127
Exercise, 126
Holding points, Acu-therapy
(Photo), 127
Insertion, 126
Internal manifestations, 126
Lab tests, 126
Meridian, 71, 126, 127
Muscle test (Photo), 126
Nerve supply, 126
Neurolymphatic receptors, 126-127
Nutrition, 126
Origin, 126
Palpation, 126
Structural weakness, 126
ANEMIA, **22, 297, 298, 301, 304**
ANESTHESIA, **391**
ANISOCYTOSIS, **298**
ANKLE, **256**
ANKLE DORSIFLEXION, **271**
ANKLE PLANTAR FLEXION, **271**
ANKLE PROBLEMS, **180, 182, 184**
ANKYLOSING SPONDYLITIS,
**308**
ANOSMIA, **276**
ANTAGONIST, **29**
ANTERIOR DORSAL AND
LEVATOR COSTALIS
TECHNIQUE, **59**
ANTERIOR HORN SPINAL
CORD DISORDER, **253**
ANTERIOR ILIUM, **140**
ANTERIOR SCALENUS, **48**
ANTERIOR SERRATUS, **4, 16, 71**
ANTERIOR TIBIAL, **7**
ANTERIOR TIBIALIS, **16, 71**
ANTIGRAVITATIONAL
SUPPLEMENTS, **56**
ANTISTREPTOLYSIN-O-TITER,
**313**
APLASTIC ANEMIA, **300**
APPENDICITIS, **196, 318**
APPLIED CHIROPRACTIC
KINESIOLOGICAL DIAGNOSIS
AND TECHNIQUE
Birth, 1
Examination procedure in, 62
APPLIED CHIROPRACTIC
KINESIOLOGICAL DIAGNOSIS AND
TECHNIQUE FOR SPINAL AND
PELVIC SUBLUXATIONS AND
FIXATIONS, **54-63**
APPLIED KINESIOLOGICAL
DIAGNOSIS AND
TECHNIQUE, **22**
APPLIED KINESIOLOGICAL
REFLEX POINTS, **64, 65**
Nutrition, 64
APRAXIA, **275**
ARM FATIGUE, **132**
ARM-SHOULDER PAIN, **338-339**
Acromio-Clavicular joint, 339
Arm and elbow involvement, 339
Bursitis, 338
Muscle spasms, 339
Slipped bicipital tendon, 338
Visceral pain referred to shoulder, 339
ARTHRITIS, **22, 210, 255, 257**
ASSOCIATED POINTS, **86**
Chart, 87
ASTHMA, **138, 146, 168, 170,**
**172, 174, 192, 194, 220, 222,**
**224, 318**
ATERION
Point "A" on mastoid and, 30
ATHEROSCLEROSIS, **312, 318**
ATLAS, **52, 58**
ATLAS, AXIS AND 3rd
CERVICAL FIXATION, **58**
ATLAS-OCCIPUT ROCKER
MECHANISM, **58**
Challenge, 58
Treatment, 58
AURICULOTHERAPY, **103-108**
Anti-Helix, 104
Associated structures, 105, 106
Auricular radicular appendage
stretching technique, 107
Electrical machines, 107
General information, 104
Helix, 104
History, 103
K-27, 107
Magnet therapy, 107
Methods of treatment, 105
Needles, 107
Therapy localization, 104
Treatment points, 105, 106
Type of energy, 108
AVULSIONS, **28**
AXIS, **58**

## B

BACK
Pain, low, 190, 196
Problems, low, 148, 150, 158, 198,
202, 204
Weak, 110, 114, 116
BACKACHES, (EARLY MORNING), **190**
BACTERIA, **134, 318**
BACTERIAL INFECTIONS, **303**
BANANA HEAD, **32**
BARANY'S TEST, **279**
BARBITURATES TEST, **316**
BASAL GANGLIA, **282**
BASOPHILIC STIPPLING, **298**
BASOPHILS, **296**
BECHTEREW'S TEST, **254**
BENCE JONES PROTEIN (BJP),
**304, 321**
BETA LIPOPROTEINS, **312**
BETAINE HYDROCHLORIDE,
**23, 24, 130**
BICEPS, **48**
BICEPS-BRACHII, **71, 128-129**
Action, 128
Anatomical drawing, 129
Associated muscles, 128
Connecting points, 129
Cranial stress center, 128
Exercise, 128
Holding points, Acu-therapy
(Photo), 129
Insertion, 128
Internal manifestations, 128
Lab tests, 128
Meridian, 71, 128-129
Muscle test (Photo), 128
Nerve supply, 128
Neurolymphatic receptors, 128, 129
Neurovascular receptors, 128
Nutrition, 128
Origin, 128
Palpation, 128
Structural weakness, 128
BILATERAL LEG
LOWERING, **256**
BILE SALTS, **23**
BILIRUBIN, **176, 318, 319, 322**
Protein, 319
Total, 178
BIOCHEMISTRY — BLOOD
FILTRATE, **306**
Blood glucose, 306
Blood urea nitrogen (BUN), 306
Nonprotein nitrogen (NPN), 306

BIOCHEMISTRY — URINE, **304-305**
Bence-Jones protein (BJP), 304
Creatine, 304
Creatinine, 304
Creatinine tolerance test, 304
Diagnex blue, 304
Magnesium, 305
Potassium, 305
Quantitative Calcium, 305
Sodium, 305
Uric acid, 305
BIOFEEDBACK AND NEUROVASCULAR TREATMENT, **384**
BIOFEEDBACK THERMOMETER, **384**
BLADDER, **71**
Disturbances of, 210
BLADDER MERIDIAN, **91**
Alarm point, 91
Associated muscles, 91
Associated point, 91
Coupled meridian, 91
Dominates, 91
Element, 91
Emotion, 91
Endangers, 91
Energy flow, 91
Figure of, 68
Meridian connector, 91
Mother of, 91
Number of points on meridian, 91
Organ, 91
Pulse side, 91
Son of, 91
Yang, 91
BLOOD, **116**
Glucose, 306
Loss of, 300
Occult, 320
Vessels, 9, 16
BLOOD BIOCHEMISTRY, **308, 312**
Cephalin flocculation, 308
Mucoprotein, 308
Serum bilirubin, 308
Serum uric acid, 308
Thymol turbidity, 308
BLOOD BIOCHEMISTRY — ELECTROLYTES, **309**
Serum chlorides, 309
Serum potassium, 309
Serum sodium, 309
BLOOD BIOCHEMISTRY — ENZYMES, **310-311**
Acid phosphatase, 310
Alkaline phosphatase, 310
Creatine phosphoric acid (C.P.K.), 311
Serum amylase, 310
Serum glutamic oxalacetic transaminase (S-GOT), 311
Serum glutamic pyruvic transaminase (S-GPT), 311
Serum lactic dehydrogenase (LDH), 310
BLOOD BIOCHEMISTRY — LIPID FRACTIONATION, **312**
Primary hyperlipidemia, 312
Total cholesterol, 312
Triglycerides, 312
BLOOD UREA NITROGEN (BUN), **306**
BODY LANGUAGE, **2**
Sacral wobble and, 60
BRACHIAL NEURITIS, **228**
BRACHIAL PLEXIS, **260, 261**
BRACHIORADIALIS, **71, 130-131**
Action, 130
Anatomical drawing, 131
Associated muscles, 130
Connecting points, 131
Exercise, 130
Holding points, Acu-therapy (Photo), 131
Insertion, 130
Internal manifestations, 130
Lab tests, 130
Meridian, 71, 130-131
Muscle test (Photo), 130
Nerve supply, 130
Neurolymphatic receptors, 130, 131
Nutrition, 130
Origin, 130
Palpation, 130
Structural weakness, 130
BRAGGARD'S TEST, **256**
BRAIN, **29**
BREAST SORENESS (OCCASIONAL), **142**
BROMIDES, **316**
BRONCHIECTASIS, **136, 318**
BSP, **319**
BUCCINATOR, **382**
BUN, **178, 190, 198, 204, 206, 208, 228, 322, 323**
BURNING ON URINATION, **186**
BURNS, **300**
Severe, 309
BURN'S TEST, **263**
BURSITIS, **210, 338**

## C

CABOT RINGS, **298**
CALCIUM, **323**
CALCIUM DEPOSITS, **259**
CALCULI, **303**
CALVES, PAIN IN, **138**
CANCER, DIFFUSE, **321**
CAPILLARY BEDS, **18**
CARBOHYDRATE SENSITIVITY, **126, 128, 146**
CARCINOMATOSIS, **308**
CARDIAC ENZYMES, **190, 196, 228**
CARDIAC PROTOMORPHOGEN, **24**
CARDIAC RESPIRATORY RATIO, **30**
Point "B" on mastoid and, 30
CAROTID SINUS REFLEX, **279**
CARPAL-TUNNEL SYNDROME, **336**
Correction, 336
Examination for, 336
Muscle testing in various positions, 8
Pisiform-Hammate tunnel correction, 336
Symptoms of, 336
CASTS, **322, 323**
CATEGORIES OF MERIDIANS, **81**
CATEGORY I, **61**
Challenge, 61
Phase two, 62
Signs, 61
Therapy localization, 61
Treatment, 62
CATEGORY II, **60**
Challenge, 61
Signs of a posterior ilium, 61
Signs of a posterior ischium, 61
Therapy localization, 60
Treatment, 61
CATEGORY III, **60**
CBC, **110, 112, 114, 116, 118, 120, 122, 128, 130, 132, 142, 144, 146, 148, 150, 152, 178, 186, 188, 196, 198, 200, 202, 204, 220, 228**
CELL CONSTANTS, **299**
CELL INDICES, **299**
CELL VOLUME, **299**
CELLULAR MEMORY, **342-343**
CEPHALIN FLOCCULATION, **176, 188, 308, 318, 319**
CEREBELLAR LESION, **253**
CEREBELLUM, **281**
CEREBRAL CORTEX, **381**
CEREBRAL FUNCTION (GENERAL), **274**
CEREBRAL FUNCTION (SPECIFIC), **275**
CEREBRAL SPINAL FLUID, **9, 10, 12, 52**
In respiration, 10-11
Intervertebral foramen, 9
Point "C" on mastoid and, 30
Sacrum, effect on, 11
Vertebral respiratory movement and, 52
CERVICAL/DORSAL JUNCTION, **134**
CERVICAL FIXATION, **56, 58**
Lower, 58
CERVICAL FIXATION DISCUSSION, **57**
CERVICAL FLEXION AND EXTENSION, **266**
CERVICAL RIB, **260**
CERVICAL RIGHT AND LEFT LATERAL FLEXION, **266**
CERVICAL RIGHT AND LEFT ROTATION, **266**
CERVICAL RUPTURED DISCS
Fifth, 392
Sixth, 393
CERVICAL SPINE, **162**
CERVICAL SUBLUXATION, **257, 260**
CHAKRAS, **387**
CHALLENGE, **8, 52, 55, 81**
CHALLENGE TECHNIQUE, **9, 13**
Alarm points, 81
Cranial stress centers, 50
Definition, 13
Expiration assist, 34
External frontal bone rotation, 41
Forced expiration assist, 39
Forced inspiration assist, 38
Glabella fault, 46
Golgi tendon apparatus, 29
Gravitational fixation, 58
Hand receptors, 334
Ileocecal valve, 326
Inspiration assist, 35
Internal frontal bone rotation, 40
Interosseous cranial fault, 47
Intervertebral foramen and, 9
Lambdoidal suture fault, 43
Muscle testing and, 8
Occipital atlantal counter torque, 44
Ocular lock, 45
One-half breath in assist, 35
One-half breath out assist, 36
Sacral wobble fault, 60
Sagittal spread assist, 37

Spindle cell mechanism, 29
Therapy localization and, 12
Universal cranial fault, 47
Zygomatic cranial fault, 42
CHEST, **254**
Congestion of, 222
Expansion of, 254
Pains, 176, 178, 228, 324
CHLORIDE, **320**
CHLOROPHYLL, **23**
CHOLESTEROL, **156, 158, 178, 312, 318, 319, 320**
CHOLESTEROL ESTERS, **318**
CHORIONIC GONADOTROPHIN, **314**
CHOROID PLEXUS, **10**
CIRCULATION SEX MERIDIAN, **92**
Acu-therapy classifications (composite), 92
Adductor brevis, 118-119
Adductor longus, 120-121
Adductor magnus, 122-123
Adductor pectineus, 124-125
Alarm point, 92
Associated muscles, 92
Associated point, 92
Coupled meridian, 92
Description, 69
Dominates, 92
Element, 92
Emotion, 92
Energy flow, 71, 92
Figure of, 69
Gastrocnemius, 138-139
Gluteus maximus, 140-141
Gluteus medius, 142-143
Gluteus minimus, 144-145
Gracilis, 146-147
Meridian connector, 92
Mother of, 92
Number of points on meridian, 92
Organ, 92
Pulse side, 92
Rule to facilitate learning, 68
Sartorius, 220-221
Son of, 92
Yin, 92
CIRRHOSIS (HEPATIC), **308**
CLAVICLE FIXATION, **64**
CLAVICLE SUBLUXATION, **64**
CLAVICULAR SUBLUXATION, **261**
CLICKING JAW, **381**
CLIMACTERIC ORGANS
Adductors, 118-125
Nutrition, 23
CLINICAL LABORATORY ABBREVIATIONS, **295**
CLOSTRIDIUM TETANI, **317**
CLOSTRIDIUM WELCHII, **317**
COLITIS, **148, 150, 296, 318**
COLLAGEN FIBERS, **10**
COMMAND POINTS, **9, 76, 77, 81, 85**
COMMON DISORDERS AND TREATMENT TECHNIQUE, **325**
COMPLEXION PROBLEMS, **381**
COMPRESSION PELVIC TEST, **259**
CONCEPTION VESSEL, **51**
Figure of, 70
Treatment of, 90
CONGENITAL DISLOCATION, **253**
CONJUCTIVE VESSELS, **76**
CONNECTING POINTS, **9, 77, 81, 84**
Illustration of, 84
CONNECTIVE TISSUE CAPSULE, **29**
CONSTIPATION, **148, 150, 152, 324**
CONTRACTION INJURIES
Golgi tendon apparatus and, 29
CONTRALATERAL GAIT RECEPTORS, **330**
CONTROL CYCLE, **74**
CONTROL POINTS, **85**
COORDINATION, **281**
CORACOBRACHIALIS, **15, 16, 21, 50, 71, 132, 133**
Action, 132
Anatomical drawing, 133
Associated muscles, 132
Connecting points, 133
Cranial stress center, 132
Exercise, 132
Holding points, Acu-therapy (Photo), 133
Insertion, 132
Internal manifestation, 132
Lab tests, 132
Meridian, 71, 132-133
Muscle test (Photo), 132
Nerve supply, 132
Neurolymphatic receptors, 20, 21, 132, 133
Neurovascular receptors, 16, 17, 132, 133
Nutrition, 23, 132
Origin, 132
Palpation, 132
T.S. line location, 15
CORD TUMORS, **256**
CORNEAL REFLEX, **277**
COSTOCLAVICULAR TEST, **261**
COSTOVERTEBRAL RESPIRATORY TECHNIQUE, **389**
COUGH, CHRONIC, **132**
COUNTER BALANCE, **52**
COUPLED MERIDIANS, **84**
COUPLED POINTS, **84**
COXA PATHOLOGY, **256**
COXA VARA, **253**
CPK, **322**
CRANIAL AND SACRAL RESPIRATORY MOVEMENT, **10**
CRANIAL BONES, **11**
CRANIAL FAULT IDENTIFICATION AND CORRECTION, **33**
Expiration assist, 34
External frontal bone rotation, 41
Forced expiration challenge, 39
Forced inspiration challenge, 38
Glabella fault, 46
Inspiration assist, 33
Internal frontal bone rotation, 40
Interosseous cranial fault, 47
Occipital atlantal counter torque, 44
Ocular lock, 45
One-half breath in assist, 35
One-half breath out assist, 36
Sagittal spread assist, 37
Universal cranial fault, 47
Universal or interosseous cranial fault, 47
CRANIAL FAULTS, **13, 32**
CRANIAL NERVE
Examination (See cranial nerve examination)
Point "A" on mastoid and, 30
CRANIAL NERVE EXAMINATION, **276-280**
CRANIAL PUMP TECHNIQUE, **31**
CRANIAL STRESS CENTERS, **9, 48, 49, 50**
Associated muscles, 48-50
Illustrations, 49
Intervertebral foramen, 9
Location, 48-50
Treatment, 50
CRANIAL TORQUE LESION, **62-63**
Challenge and correction, 63
Therapy localization, 62
CRANIUM, **62**
C-REACTIVE PROTEIN, **210, 226, 313, 322**
CREATINE, **304**
CREATINE PHOSPHORIC ACID (C.P.K.), **311**
CREATININE, **304, 319, 320, 322, 323**
CREATININE TOLERANCE TEST, **304**
CREATION CHART (illustration), **73**
CREATION AND DESTRUCTION CYCLE COMBINED, **73, 76**
Illustration of, 77
CRETINISM, **314**
CROSS CRAWL TECHNIQUE, **341-342**
Using K-27 and umbilical contact, 8
CROWDED SUTURE, **32**
CRUSH INJURIES, **296**
CRYING (UNCONTROLLED), **156**
"C" SCOLIOSIS, **252**
CULTURE, **134**
CULTURES AND SENSITIVITIES, **317**
Stool culture, 317
CUSHING'S SYNDROME, **315**
CYSTITIS, **318**

## D

DEEP BREATH, **33**
DEGENERATIVE JOINT DISEASE, **253**
DEHYDRATION, **309**
DEHYDROGENASE (LACTIC ACID), **322**
DeJARNETTE BLOCKS, **62**
DELTOIDS, **6, 15, 16, 21, 48, 71, 134, 135**
Action, 134
Anatomical drawing, 135
Associated muscles, 134
Connecting points, 135
Cranial stress center, 134
Exercise, 134
Holding points, Acu-therapy (Photo), 135
Insertion, 134
Internal manifestations, 134
Lab tests, 134
Meridian, 71, 134, 135
Muscle test (Photo), 134
Nerve supply, 134
Neurolymphatic receptors, 20, 21, 134, 135
Neurovascular receptors, 16, 17, 134

Nutrition, 23, 134
Origin, 134
Palpation, 134
Posture, effect on, 6, 7
Structural weakness, 134
T.S. line location, 15
DERMATITIS (NON-SPECIFIC), **324**
DESTRUCTION CYCLE, **74**
DETOXIFICATION (See organ detoxification)
DIABETES MELLITUS, **158, 302, 304, 306, 309, 312, 318**
DIABETIC COMA, **309**
DIAGNEX BLUE, **110, 114, 116, 128, 130, 156, 162, 196, 200, 202, 204, 304**
DIAGNOSTIC TOOL, **8**
DIAPHRAGM, **16, 21, 136, 137, 386**
Action, 136
Anatomical drawing, 137
Associated muscles, 136
Connecting points, 137
Cranial stress centers, 136
Exercise, 136
Holding points, Acu-therapy (Photo), 137
Insertion, 136
Internal manifestations, 136
Lab tests, 136
Meridian, 136, 137
Muscle test (Photo), 136
Nerve supply, 136
Neurolymphatic receptors, 20, 21, 136, 137
Neurovascular receptors, 16, 17, 136
Nutrition, 136
Origin, 136
Palpation, 136
Structural weakness, 136
DIAPHRAGMATIC PROBLEMS, **222**
DIARRHEA, **309**
DIETS, **357-376**
Allergy (See diets-high protein)
Anemia, 358
Arthritis, 359-361
Bland, 362
Cholesterol (low), 363
Cleansing and general health, 368
Detoxification, 364-367
High protein, sinus or allergy, 370
Hypoglycemic diet, 369
Liquid (See diets-soft food)
Purine (low), 372
Salt (See diets-sodium [low])
Sinus (See diets-high protein)
Sodium (low), 373
Soft food, 371
Sugar (low), 374-375
Weight reduction #1, 375
Weight reduction #2, 376
DIFFERENTIAL COUNT, **296**
DIGESTIVE DISORDERS, **176**
DIGESTIVE DISTURBANCES, **156, 381**
DIPHTHERIA, **319**
DIPLOPIA, **277**
DISC INVOLVEMENT, **260**
DISC LESION, **64, 252, 255, 256, 257**
DISC SYNDROMES, **254, 391**
DISEASES AND LABORATORY FINDINGS, **318-321**
Acute appendicitis, 318
Acute prostatitis, 320
Allergies, 318
Asthma, 318
Atherosclerosis, 318
Bronchiectasis, 318
Colitis, 318
Cystitis, 318
Diabetes mellitus, 318
Diphtheria, 319
Duodenal ulcer, 320
Erysipelas, 319
Gallbladder, 319
Gastric ulcer, 321
Glycogen storage disease, 321
Gonorrhea, 319
Gout, 319
Hepatic cirrhosis, 318
Infectious mononucleosis, 319
Intestinal obstruction, 319
Male sterility, 320
Mumps, 319
Osteitis deformans, 319
Osteomalacia, 319
Otitis media, 319
Paget's disease, 319
Pyloric stenosis, 320
Rheumatic fever, 320
Rheumatoid arthritis, 320
Ringworm, 320
Rubeola, 320
Syphilis, 320
Testicular tumors, 320
Tetanus, 320
Thyroid hyperfunction, 320
Thyroid hypofunction, 320
Thyrotoxicosis, 320
Tinea, 320
Viral hepatitis, 319
Von Gierke's disease, 321
Urethritis, 321
DISEASES AND LABORATORY FINDINGS — CANCER, **321**
Acute leukemia, 321
Chronic leukemia, 321
Diffuse cancer, 321
Multiple myeloma, 321
Osteogenic sarcoma, 321
Prostatic carcinoma, 321
Stomach carcinoma, 321
DISEASES AND LABORATORY FINDINGS — HEART, **322**
Malignant hypertension, 322
Myocardial infarction, 322
Pulmonary embolism, 322
Pulmonary emphysema, 322
Subacute bacterial endocarditis, 322
DISEASES AND LABORATORY FINDINGS — KIDNEY, **323**
Glomerulonephritis, 323
Kidney uremia, 323
Nephrodic syndrome, 323
Nephrosis, 323
Renal calculi, 323
DIURETICS, **305**
DIZZINESS, **324**
DORSAL (ANTERIOR) AND LEVATOR COSTALIS TECHNIQUE, **59**
DORSAL FIXATION, **58**
DORSAL NERVE ROOT SYNDROME, **396**
DORSAL RIB FIXATION, UPPER, **58**
Treatment of, 59
DORSALS, ANTERIOR, **59**
DORSOLUMBAR FLEXION AND EXTENSION, **266**
DORSOLUMBAR RIGHT AND LEFT LATERAL FLEXION, **267**
DORSOLUMBAR RIGHT AND LEFT ROTATION, **267**
DOUBLE VISION, **277**
DRUG REACTIONS, **296**
DUODENAL ULCER, **320**
DURAL ADHESIONS, **257, 262**
DWARFISM, **315**
DYSPHAGIA, **279**

## E

EAR
Trapezius (upper), 246
EARTH POINT, **77, 85**
ECLAMPSIA, **302**
EDEN'S TEST, **262**
ELBOWS, **255**
Extension, 267
Flexion, 267
Pain, 118, 120, 124, 156, 210, 339
Problems, 126
ELEMENT POINTS, **85**
ELEMENTS, THE FIVE, **73**
Earth, 73
Fire, 73
Metal, 73
Water, 73
Wood, 73
ELY'S TEST, **258**
EMOTIONAL FATIGUE, **138**
EMOTIONAL PATTERNS, **51**
Treatment of, 51
EMOTIONAL STRAIN, **210**
EMOTIONS AND THE FIVE ELEMENTS, **76**
Anger, 76
Fear, 76
Grief, 76
Groan, 76
Heart, 76
Joy, 76
Kidney, 76
Laugh, 76
Liver, 76
Lung, 76
Shout, 76
Sing, 76
Spleen, 76
Sympathy, 76
Weep, 76
EMPHYSEMA, **136**
ENDOCRINOLOGY, **314-315**
Chorionic gonadotrophin, 314
17-Ketosteroids, total neutral, 315
Protein-Bound iodine (PBI), 314
Thyroxine by radioassay (T-4), 314
Total and fractionated estrogens, 315
Tri-Iodothyronine (T-3), 314
ENERGY, **90**
Excess, 76
Flow, 81
Polarity, 72
EOSINOPHIL COUNT, **110, 112, 114, 138, 146, 166, 168, 174**
EOSINOPHIL CULTURE, **138, 170, 172**
EOSINOPHILS, **296, 318**
In sputum, 158, 222

EPIPHYSEAL SEPARATION, **253**
EPITHELIAL CASTS, **303**
EPITHELIAL CELLS, **323**
EQUILIBRIUM TEST, **281**
ERECTOR SPINAE, **54**
ERYSIPELAS, **319**
ERYTHROCYTE COUNT, **110, 118, 120, 134, 298, 318, 320, 321, 322, 323**
ERYTHROCYTE SEDIMENTATION, **318**
ERYTHROCYTE SEDIMENTATION RATE (ESR), **297**
ESCHERICHIA, **317**
ESOPHAGEAL DAMAGE, **22**
ESR, **110, 112, 114, 116, 118, 120, 122, 142, 144, 148, 150, 152, 168, 170, 172, 210, 228, 319, 320, 322**
ESTROGENS, **186**
ETHMOID, **32**
EXERCISES (See structural exercises)
EXOSTOSIS, **253, 255, 256, 260**
EXPIRATION, **32, 52**
EXPIRATIONAL FIXATION, **63**
EXPIRATION ASSIST, **10, 34, 383**
Challenge, 34
Identifying characteristics, 34
Kinesiological correction, 34
Therapy localization, 34
EXTENSION, **266**
EXTERNAL FRONTAL BONE ROTATION, **41**
Challenge, 41
Identifying characteristics, 41
Kinesiological correction, 41
Therapy localization, 41
EXTRAHEPATIC OBSTRUCTIVE JAUNDICE, **311**
EXTRAPYRAMIDAL SYSTEM, **282**
EYE DEFECTS, **64**

## F

FABERE-PATRICK'S TEST, **256**
FACET FIXATION, ANTERIOR, **56, 58**
FACET FIXATION, POSTERIOR, **56, 58**
FAJERSZTAJN'S TEST, **256**
FATIGUE, **150**
Morning, 138, 220, 224
Weakness, 324
FAT METABOLISM (ABNORMAL), **302**
FEET REFLEX POINTS, **331-333**
Left foot, points on, 333
Right foot, points on, 332
Treatment, 331
FEMORAL ARTHRITIS, **64**
FEMORAL NERVE INVOLVEMENT, **253**
FEVERS, **304**
FIFTH CERVICAL RUPTURED DISC, **392**
FIFTH LUMBAR, **52**
FINGER TIPS, **33**
FIRE POINT, **85**
FIVE ELEMENT LAW, **76**
(See Acu-therapy)
FIVE ELEMENTS AND EMOTIONS (illustrated), **76**
FIXATION, **14, 63, 78, 166, 252**
FIXATION CHART, **55**
FLEXED HIP TEST, **264**
FLEXION, **266**
FLIP TEST, **263**
FLORESCENT TREPONEMAL ANTIBODIES, **313**
FLUORIDE, **316**
FOOT, **256**
FOOT DROP, **180, 182, 184**
FORAMINA COMPRESSION TEST, **260**
FORCED EXPIRATION ASSIST, **10, 39**
FORCED EXPIRATION CHALLENGE, **10**
Challenge, 39
Identifying characteristics, 39
Kinesiological correction, 39
Therapy localization, 39
FORCED EXPIRATION CRANIAL FAULT, **383**
FORCED INSPIRATION ASSIST, **10, 38**
FORCED INSPIRATION CHALLENGE, **38**
Challenge, 10, 38
Identifying characteristics, 38, 39
Kinesiological correction, 38
Therapy localization, 38
FORCED INSPIRATION CRANIAL FAULT, **383**
FOREARM, **255**
Pronation, 268
Supination, 268
FRACTIONATED ESTROGENS, **142**
FRACTURE, **253, 257, 258**
FRONTAL BONE, **172**
Rotation, 168, 174, 192, 194
FU, **76**
FUSIFORM, **29**

## G

GAENSLEN'S TEST, **257**
GAG REFLEX, **279**
GAIT, **281, 294**
Antalgic, 294
Ataxic, 294
Cerebellar, 294
Charcot's, 294
Definition, 294
Limp, 294
Multiple sclerotic, 294
Normal, 294
Paralytic, 294
Spastic, 294
Steppage, 294
GAIT FACILITATORS, **330**
GAIT PROBLEMS, **180, 182, 184**
GAIT RECEPTOR FAULTS, **330**
Correction, 330
Gait facilitator test, 330
Gait inhibitors test, 330
Lateral gait receptor test, 330
GAIT TEST, **330**
GALLBLADDER, **71, 176, 319**
Nutrition, 23
Popliteus, 188, 189
GALLBLADDER MERIDIAN, **93**
Alarm point, 93
Associated muscle, 93
Associated point, 93
Coupled meridian, 93
Dominates, 93
Element, 93
Emotion, 93
Energy flow, 93
Figure of, 69
Meridian connector, 93
Mother of, 93
Number of points on meridian, 93
Organ, 93
Pulse side, 93
Son of, 93
Yang, 93
GAMMA GLOBULIN, **319, 323**
Fraction, 318
GASTRIC DISTURBANCES, **206, 208**
GASTRIC ENZYMES, **23**
GASTRIC ULCER, **321**
GASTRIC UPSET, **196**
GASTROCNEMIUS, **7, 48, 71, 138, 139**
Action, 138
Anatomical drawing, 139
Associated muscles, 138
Connecting points, 139
Cranial stress center, 138
Exercise, 138
Holding points, Acu-therapy (Photo), 139
Insertion, 138
Internal manifestations, 138
Lab tests, 138
Meridian, 71, 138, 139
Muscle test (Photo), 138
Nerve supply, 138
Neurolymphatic receptors, 138, 139
Neurovascular receptors, 138
Nutrition, 23, 138
Origin, 138
Palpation, 138
Posture, effect on, 7
Structural weakness, 138
GASTROINTESTINAL LESIONS, **298**
GENU VALGUM, **7**
GENU VARUM, **7**
GLABELLA FAULT, **46**
Challenge, 46
Identifying characteristics, 46
Kinesiological correction, 46
Therapy localization, 46
GLAUCOMA, **178**
GLOBULIN, **319, 321, 322**
GLOMERULONEPHRITIS, **302, 313, 323**
Acute, 303
Chronic, 303
GLUCOSE, **318, 320**
GLUCOSE TOLERANCE, **318, 321**
GLUCOSE TOLERANCE CURVES, **307**
GLUCOSE TOLERANCE TEST, **224**
5-Hour, 126, 138, 158, 220
GLUTEAL DISTURBANCE, **252**
GLUTEUS MAXIMUS, **3, 15, 16, 21, 49, 62, 71, 140, 141**
Action, 140
Anatomical drawing, 141
Associated muscles, 140
Connecting points, 141
Cranial stress center, 140

Exercise, 140
Holding points, Acu-therapy (Photo), 141
Insertion, 140
Internal manifestations, 140
Lab tests, 140
Meridian, 71, 140, 141
Muscle test (Photo), 140
Nerve supply, 140
Neurolymphatic receptors, 20, 21, 140, 141
Neurovascular receptors, 16, 17, 140
Nutrition, 23, 140
Origin, 140
Palpation, 140
Posture, effect on, 3, 7
Structural weakness, 140
T.S. line location, 15
GLUTEUS MEDIUS, **3, 7, 8, 15, 16, 21, 49, 62, 71, 142, 143**
Action, 142
Anatomical drawing, 143
Associated muscles, 142
Connecting points, 143
Cranial stress center, 142
Exercise, 142
Holding points, Acu-therapy (Photo), 143
Insertion, 142
Internal manifestations, 142
Lab tests, 142
Meridian, 71, 142, 143
Muscle test (Photo), 142
Nerve supply, 142
Neurolymphatic receptors, 20, 21, 142, 143
Neurovascular receptors, 16, 17, 142
Normal tonicity, 2
Nutrition, 23, 142
Origin, 142
Palpation, 142
Posture, effect on, 3
Structural weakness, 142
T.S. line location, 15
GLUTEUS MINIMUS, **3, 21, 49, 144, 145**
Action, 144
Anatomical drawing, 145
Associated muscles, 144
Connecting points, 145
Cranial stress center, 144
Exercise, 144
Holding points, Acu-therapy (Photo), 145
Insertion, 144
Internal manifestations, 144
Lab tests, 144
Meridian, 71, 144, 145
Muscle test (Photo), 144
Nerve supply, 144
Neurolymphatic receptors, 20, 21, 144, 145
Neurovascular receptors, 16, 17, 144
Nutrition, 23, 144
Origin, 144
Palpation, 144
Structural weakness, 144
GLYCOGEN STORAGE DISEASE, **302, 306, 321**
GLYCOSURIA, **302**
GOLDTHWAIT'S TEST, **255**
GOLGI TENDON APPARATUS, **9, 29**
Feet reflex points and, 331
Intervertebral foramen, 9
GONADOTROPHINS (CHRONIC), **320**
GONIOMETER, USE OF, **265**
GONOCOCCI POSITIVE, **319**
GONORRHEA, **319**
GOUT, **308, 319**
GOUTY ARTHRITIS, **297**
GOVERNING VESSEL, **51**
Figure of, 70
Treatment of, 90
GOWERS' SIGN, **254**
GRACILIS, **7, 15, 16, 21, 71, 146, 147**
Action, 146
Anatomical drawing, 147
Associated muscles, 146
Connecting points, 147
Cranial stress center, 146
Exercise, 146
Holding points, Acu-therapy (Photo), 147
Insertion, 146
Internal manifestations, 146
Lab tests, 146
Meridian, 71, 146, 147
Muscle test (Photo), 146
Nerve supply, 146
Neurolymphatic receptors, 20, 21, 146, 147
Neurovascular receptors, 16, 17, 146
Nutrition, 23, 146
Origin, 146
Palpation, 146
Posture, effect on, 7
Structural weakness, 146
T.S. line location, 15
GRANULOCYTES, **319**
GRAVITIATIONAL FIXATION, **56**
GUMS (BLEEDING), **228**

## H

HALF-BREATH IN ASSIST, **10**
HALF-BREATH OUT ASSIST, **10**
HALF-WIT BROTHER, **52**
HAMSTRINGS, **15, 16, 21, 49, 59, 71**
Meridian, 71
Neurolymphatic receptors, 20, 21
Neurovascular receptors, 16, 17
Nutrition, 23
Posture, effect on, 7
T.S. line location, 15
HAMSTRINGS — BICEPS FEMORIS (LATERAL), **148-149**
Action, 148
Anatomical drawing, 149
Associated muscles, 148
Connecting points, 149
Cranial stress center, 148
Exercise, 148
Holding points, Acu-therapy (Photo), 149
Insertion, 148
Internal manifestations, 148
Lab tests, 148
Meridian, 148-149
Muscle test (Photo), 148
Nerve supply, 148
Neurolymphatic receptors, 148, 149
Neurovascular receptors, 148
Nutrition, 148
Origin, 148
Palpation, 148
Structural weakness, 148
HAMSTRINGS — SEMIMEMBRANOSUS (MEDIAL), **150-157**
Action, 150
Anatomical drawing, 151
Associated muscles, 150
Connecting points, 151
Cranial stress center, 150
Exercise, 150
Holding points, Acu-therapy (Photo), 157
Insertion, 150
Internal manifestations, 150
Lab tests, 150
Meridian, 150-151
Muscle test (Photo), 150
Nerve supply, 150
Neurolymphatic receptors, 150, 151
Neurovascular receptors, 150
Nutrition, 150
Origin, 150
Palpation, 150
Structural weakness, 150
HAMSTRINGS — SEMITENDINOSUS (MEDIAL), **152-153**
Action, 152
Anatomical drawing, 153
Associated muscles, 152
Connecting points, 153
Cranial stress center, 152
Exercise, 152
Holding points, Acu-therapy (Photo), 153
Insertion, 152
Internal manifestations, 152
Lab tests, 152
Meridian, 152, 153
Muscle test (Photo), 152
Nerve supply, 152
Neurolymphatic receptors, 152, 153
Neurovascular receptors, 152
Nutrition, 152
Origin, 152
Palpation, 152
Structural weakness, 152
HAND RECEPTORS, **334-335**
Associated muscles, 334, 335
Challenge, 334
Palm view (Photo), 335
Top view (Photo), 334
Treatment, 334
HANDS ROTATED, **7**
HEADACHES, **148, 164, 166, 168, 170, 172, 174, 192, 194**
Acute, 324
Toxic, 150, 152, 381
HEARING DISORDERS, **324**
HEART, **71**
Conditions of, 190
Failure of, 314
Heartbeat, 18
Nutrition, 24
Rate, 10
Subscapularis, 228, 229
HEART MERIDIAN, **94**
Alarm point, 94
Associated muscles, 94

Associated point, 94
Coupled meridian, 94
Dominates, 94
Element, 94
Emotion, 94
Energy flow, 94
Figure of, 68
Meridian connector, 94
Mother of, 94
Number of points on meridian, 94
Organ, 94
Pulse side, 94
Son of, 94
Yin, 94
HEEL AND SOLE LIFTS, **331**
HEEL-AND-TOE STANDING TEST, **253**
HEELS, **253**
HEEL-TO-BUTTOCKS TEST, **258**
HEMATOCRIT, **132, 188, 220, 224, 297, 322**
HEMATOLOGY, **296-300**
Basophils, 296
Cell indices, 299
Differential count, 296
Eosinophils, 296
Erythrocyte count (RBC), 298
Erythrocyte sedimentation rate (ESR), 297
Hematocrit, 297
Hemoglobin, 297
Hemoglobinemia, 297
Hemoglobinuria, 297
Lupus erythematosus, 299
Lymphocytes, 296
Monocytes, 296
Neutrophils, 296
Packed cell volume, 297
Platelet count, 300
Reticulocyte count, 300
Sickle cell preparation, 300
HEMATURIA, **302**
HEMOCHROMATOSIS, **302**
HEMOGLOBIN, **296, 320**
HEMOGLOBINEMIA, **297**
HEMOGLOBINURIA, **297, 302**
HEMOLYSIS, **297, 301**
HEMORRHAGE, **296, 297, 298, 300**
HEMORRHAGIC NEPHRITIS, **303**
HEMORRHOIDS, **148, 150**
HEPATIC CARCINOMA, **301, 304**
HEPATIC CIRRHOSIS, **308, 311, 318**
HEPATIC INSUFFICIENCY, **306**
HEPATITIS, **296, 297, 299, 310, 311, 314**
HERPES SIMPLEX, **296**
HERPES ZOSTER, **296**
HETEROPHIL ANTIBODIES, **313, 319**
HGB, **132, 138, 148, 150, 152, 158, 220, 224**
HIATAL HERNIA, **136, 222, 329**
Classifications, 329
Correction, 329
Diagnosis, 329
HIBB'S TEST, **258**
HIP, 7
Abduction, 270
Adduction, 270
Backward extension, 269
Contracture, 256
Flexion, 269
High, 142, 144
Lesion, 256, 258
HODGKIN'S DISEASE, **296**
HOOVER'S SIGN, **263**
HORMONE IMBALANCES, **118, 120**
HOWELL-JOLLY BODIES, **298**
HUSBAND YANG, **78**
HYDATIDIFORM MOLE, **314**
HYOID, **32**
HYPERABDUCTION, **261**
HYPERABDUCTION SYNDROME, **260**
HYPERABDUCTION TEST, **260**
HYPERCHROMIC MACROCYTIC ANEMIA, **298**
HYPERESTHESIA, **391**
HYPERINSULINISM, **158, 220**
HYPERLIPIDEMIA, **312**
HYPERPARATHYROIDISM, **305, 310**
HYPERPITUITARISM, **302**
HYPERPLASIA, ADRENAL, **315**
HYPERTENSION, **322**
HYPERTHYROIDISM, **296, 297, 302, 304, 305, 310, 314**
HYPERTONIC MUSCLE, **1**
HYPERVENTILATION, **309**
HYPERVITAMINOSIS D, **305**
HYPESTHESIA, **391**
HYPOADRENALISM, **315**
HYPOADRENIA
(See hypotension, postural)
HYPOCHLORHYDRIA, **304**
HYPOCHROMIC ANEMIA, **320**
HYPOCHROMIC MICROCYTIC ANEMIA, **308, 318**
HYPOGLYCEMIA, **138, 158, 220, 224**
HYPOGONADISM, **315**
HYPOPARATHYROIDISM, **305**
HYPOPITUITARISM, **315**
HYPOTENSION (POSTURAL), **327**
Causes, 327
Characteristics, 327
Test for, 327
Treatment, 327
HYPOTHYROIDISM, **305, 312, 314**
HYPOTONIC MUSCLE, **1**
HYPOVENTILATION, **309**

## I

ILEOCECAL, **49**
ILEOCECAL VALVE SYNDROME, **325, 326**
Challenge, 326
Circular muscles, 325
Correction, 326
Cranial stress centers, 326
Flexed knee test, 326
Muscles, types of, 325
Nutrition, 326
Open, 326
Sphincter muscles, 325
Subluxation, 326
Symptoms of, 325
ILIAC CREST, **253**
Posture and, 3
ILIAC FIXATION, **166, 186**
ILIAC MOVEMENTS ON RESPIRATION, **63**
ILIACUS, **71, 154-155**
Action, 154
Anatomical drawing, 155
Associated muscles, 154
Connecting points, 155
Exercise, 154
Holding points, Acu-therapy (Photo), 155
Insertion, 154
Internal manifestations, 154
Lab tests, 154
Meridian, 7, 154, 155
Muscle test (Photo), 154
Nerve supply, 154
Neurolymphatic receptors, 154, 155
Nutrition, 23, 154
Origin, 154
Palpation, 154
Structural weakness, 154
ILIOLUMBAR LESION, **252**
ILIOLUMBAR SPINE, **252**
ILIOPSOAS, **256**
ILIUM, **61, 63, 142**
Internal/external, 63
Signs of a posterior, 61
ILIUM FIXATION, **63**
Correction of, 63
Signs of, 63
Therapy localization, 63
IMPOTENCY, **142, 144**
INDICATOR MUSCLE, **8, 13, 32, 33**
INDIGESTION, **324**
INFECTIONS, **146, 156, 296, 308**
INFECTIOUS MONONUCLEOSIS, **319**
INFLAMMATION, **296**
INFRASPINATUS, **16, 21, 71, 156, 157**
Action, 156
Anatomical drawing, 157
Associated muscles, 156
Connecting points, 157
Exercise, 156
Holding points, Acu-therapy (Photo), 157
Insertion, 156
Internal manifestations, 156
Lab tests, 156
Meridian, 71, 156, 157
Muscle test (Photo), 156
Nerve supply, 156
Neurolymphatic receptors, 20, 21, 156, 157
Neurovascular receptors, 16, 17, 156
Nutrition, 156
Origin, 156
Palpation, 156
Structural weakness, 156
INNER ENERGY, **76**
INSERTION TECHNIQUE, **28**
INSOMNIA, **132**
INSPIRATION, **32, 52**
INSPIRATIONAL FIXATION, **63**
INSPIRATION ASSIST, **10, 33, 383**
Challenge, 33
Identifying characteristics, 33
Kinesiological correction, 33
Therapy localization, 33
INSULIN, **318**
INTERNAL FRONTAL BONE ROTATION, **40**
Challenge, 40
Identifying characteristics, 40
Kinesiological correction, 40
Therapy localization, 40
INTERNAL ORGAN, **81**

INTEROSSEOUS CRANIAL FAULT, **47**
Challenge, 47
Identifying characteristics, 47
Kinesiological correction, 47
Therapy localization, 47
INTERVERTEBRAL DISC SYNDROME, **258**
INTERVERTEBRAL FORAMEN (I.V.F.), **9, 14, 50, 51**
Occlusions, 255
INTESTINAL OBSTRUCTION, **306, 319**
INTOXIFICATION, **280**
INTRINSIC SPINAL MUSCLES, **21**
IODINE, **22**
IRRADIATION, **296, 300**
IRRITATIVE CONDITIONS, **303**
ISCHIUM
(See ilium and ischium)
Signs of a posterior, 61

## J

JACKSON'S MANEUVER, **260**
JAUNDICE, **301**
JAW JERK, **278**
JAW MUSCLES, **16, 21**
Neurolymphatic receptors, 21
Neurovascular receptors, 16, 17
JAW PROBLEMS, **164, 192, 194**
JEJUNUM AND THE ILEUM, **202, 204**
JUGULAR COMPRESSION TEST, **397**

## K

KELP, **156**
KEMP'S SIGN OR TEST, **253**
KERNIG'S SIGN, **257**
17-KETOSTEROIDS, **120, 122, 140, 142, 144, 320**
Total neutral, 315
KIDNEY, **71**
Congestion, 303
Disease, 297, 306, 322
Extract, 24
Iliacus, 154, 155
Infarction, 301
Infections, 190
Nutrition, 24
Psoas major, 190, 191
Stones, 22
Uremia, 323
KIDNEY MERIDIAN, **95**
Alarm point, 95
Associated muscles, 95
Associated point, 95
Coupled meridian, 95
Dominates, 95
Element, 95
Emotion, 95
Energy flow, 95
Figure of, 69
Meridian connector, 95
Mother of, 95
Number points on meridian, 95
Organ, 95
Pulse side, 95
Son of, 95
Yin, 95
KINESIOLOGICAL REFLEX POINTS, **64, 65**
KNEE JOINT PROBLEMS, **340-341**
Muscles frequently involved in, 340
Symptoms of, 340
KNEES, **252, 256**
Extension, 270
Flexion, 270
Kneecap, pain in, 198
Knocked knees, 148, 150, 152, 220
Pain in, 220
Problems, 146, 150, 152, 188, 200, 202, 204
KO CYCLE, **74, 76**
Basic action of, 74
Illustration, 74, 75
K-27 AND THE UMBILICAL CONTACT, **8**

## L

LABORATORY SURVEYS BY SYMPTOMS, **324**
Abdominal pains (severe), 324
Chest pains, 324
Constipation, 324
Dermatitis (non-specific), 324
Dizziness, 324
Fatigue and weakness, 324
Headaches (acute), 324
Hearing disorders, 324
Indigestion, 324
Low back instability in males (chronic), 324
Ocular disturbances, 324
LABORATORY TESTS
(See clinical laboratory)
LACTIC ACID, **16, 19**
LACTIC DEHYDROGENASE, **321**
LACTOBACILLUS ACIDOPHILUS, **24**
LAMBDOIDAL SUTURE FAULT, **43**
Challenge, 43
Identifying characteristics, 43
Kinesiological correction, 43
Therapy localization, 43
LARGE INTESTINE, **71**
Tensor fascia lata and, 234, 235
LARGE INTESTINE MERIDIAN, **96**
Alarm point, 96
Associated muscles, 96
Associated point, 96
Coupled meridian, 96
Element, 96
Emotion, 96
Endangers, 96
Energy flow, 96
Figure of, 70
Meridian connector, 96
Mother of, 96
Number of points on meridian, 96
Organ, 96
Pulse side, 96
Son of, 96
Yang, 96
LASÈGUE'S TEST, **255**
LATERAL GAIT RECEPTORS, **330**
LATERALIZATION
(See tests, Weber's)
LATEX FIXATION, **210**
LATEX FIXATION TEST, **226**
LATISSIMUS DORSI, **4, 6, 7, 15, 16, 21, 48, 71, 158, 159**
Action, 158
Anatomical drawing, 159
Associated muscles, 158
Connecting points, 159
Cranial stress center, 158
Exercise, 158
Holding points, Acu-therapy (Photo), 159
Insertion, 158
Internal manifestations, 158
Lab test, 158
Meridian, 71, 158, 159
Muscle test (Photo), 158
Nerve supply, 158
Neurolymphatic receptors, 20, 21, 158, 159
Neurovascular receptors, 16, 17, 158
Normal tonicity, 2
Nutrition, 23, 158
Origin, 158
Palpation, 158
Posture, effect on, 4, 6, 7
Structural weakness, 158
T.S. line location, 15
LAW OF ENDANGER, **78**
LDH, **178**
LEAD GLOVE EFFECT, **108**
LEFT WRIST, **78**
LEGS, **257**
Bowed, 118, 120, 142, 144
LEGG-CALVE-PERTHES DISEASE, **253**
LEPTOCYTE, **298**
LEUKEMIA, **301, 304, 308, 310**
Acute, 321
Chronic, 304, 321
LEUKEMIC REACTIONS, **296**
LEUKOCYTES, **318, 320, 321, 322, 323**
LEVATOR ANI, **71, 160-161**
Action, 160
Anatomical drawing, 160
Associated muscles, 160
Connecting points, 161
Exercise, 160
Holding points, Acu-therapy (Photo), 161
Insertion, 160
Internal manifestations, 160
Lab tests, 160
Meridian, 71, 160, 161
Nerve supply, 160
Neurolymphatic receptors, 160, 161
Nutrition, 160
Origin, 160
Palpation, 160
Structural weakness, 160
LEVATOR COSTALIS BREVIS, **59**
LEVATOR COSTALIS MUSCLES, **58**
LEVATOR COSTALIS TECHNIQUE, **59**
LEVATOR SCAPULAE, **4, 7, 21, 49, 50, 71, 162, 163**
Action, 162
Anatomical drawing, 163
Associated muscles, 162
Connecting points, 163
Cranial stress center, 162
Exercise, 162
Holding points, Acu-therapy (Photo), 163
Insertion, 162
Internal manifestations, 162

Lab tests, 162
Meridian, 71, 162, 163
Muscle test (Photo), 162
Nerve supply, 162
Neurolymphatic receptors, 162, 163
Neurovascular receptors, 162
Nutrition, 162
Origin, 162
Palpation, 162
Posture, effect on, 4, 7
Structural weakness, 162
LEWIN'S SIGN OR TEST, **252**
LIBMAN'S TEST, **263**
LIFE FORCE, **68**
LIGAMENTOUS STRAIN, **259**
LIMP (PECULIAR), **142**
LIPASE, **319**
LIPOIDAL NEPHROSIS, **303**
LIPOPROTEIN, **318**
LIVER, **71, 176, 206, 208**
Conditions, 178
Damage, 306
Disease, 298, 308
Nutrition, 23
Pectoralis major clavicular, 176, 177
Pectoralis major sternal, 178, 179
Rhomboids, 206-209
LIVER MERIDIAN, **97**
Alarm point, 97
Associated muscles, 97
Associated point, 97
Coupled meridian, 97
Dominates, 97
Element, 97
Emotion, 97
Energy flow, 97
Figure of, 69
Meridian connector, 97
Mother of, 97
Number of points on meridian, 97
Organ, 97
Pulse side, 97
Son of, 97
Yin, 97
LIVER PROTOMORPHOGEN, **23**
LMN, **283**
LOGAN BASIC CONTACT (Photo), **59**
LORDOSIS, **7, 210**
LOVETT BROTHER, **52, 54**
LOVETT BROTHER VERTEBRAE CHART, **53**
LOW BACK CONDITIONS, **140**
LOW BACK INSTABILITY IN MALES (CHRONIC), **324**
LUMBAR DISC SYNDROMES, **397**
L-4 ruptured disc, 399
L-5 ruptured disc, 400
S-1 syndrome, 401
S-2 syndrome, 402
LUMBAR FIXATION, **58**
LUMBAR ROTATION, **142, 144**
LUMBAR SPINE, **255, 264**
LUMBAR SPRAIN/STRAIN, **255**
LUMBOSACRAL, **254, 256, 257**
LUMBOSACRAL LESION, **252, 254, 255, 257, 258**
LUMBOSACRAL SUBLUXATIONS, **160**
LUMIN NASII, **382**
LUNG
Coracobrachialis, 132, 133
Deltoids, 134, 135
Diaphragm, 136, 137
Nutrition, 23, 24
Serratus (anterior), 222
LUNG MERIDIAN, **98**
Alarm point, 98
Associated muscles, 98
Associated point, 98
Coupled meridian, 98
Dominates, 98
Element, 98
Emotion, 98
Energy flow, 98
Figure of, 69
Meridian connector, 98
Mother of, 98
Number of points on meridian, 98
Organ, 98
Pulse side, 98
Son of, 98
Yin, 98
LUNG PROTOMORPHOGEN, **23, 24**
LUO POINTS, **84**
(See connecting points)
LUPUS ERYTHEMATOSUS, **296, 299, 302, 308, 313**
LYMPHATICS, **78**
LYMPHATIC SYSTEM, **10**
Cerebral spinal fluid, 10
LYMPHOCYTES, **296, 319, 320**
LYMPHOGRANULOMA VENEREUM, **308**
LYMPH VESSEL, **9**
In intervertebral foramen, 9

## M

MACROCYTIC, **298**
MAGNESIUM, **305**
MALARIA, **308, 313**
MALE HORMONE, **23**
MALE STERILITY, **320**
MALIGNANCIES, **297**
MALIGNANT HYPERTENSION, **322**
MALINGERING TESTS, **263**
MALLEOLUS, **256**
MASSETER, **71, 164, 165, 382**
Action, 164
Anatomical drawing, 165
Associated muscles, 164
Connecting points, 165
Cranial stress center, 164
Holding points, Acu-therapy (Photo), 165
Insertion, 164
Internal manifestations, 164
Meridian, 71, 164, 165
Muscle test (Photo), 164
Nerve supply, 164
Neurovascular receptors, 164
Origin, 164
Palpation, 164
Structural weakness, 164
MASTICATION, **278**
MASTOID, **32, 33, 263**
Bone, 11
Cranial pump technique on, 31
Point "A" on, 30
Point "B" on, 30
Point "C" on, 30
Point "D" on, 31
MEGALOBLASTIC ANEMIA, **300**
MELANOMA, **301**
MENIERE'S SYNDROME, **278**
MENINGITIS, **257**
MENNELL'S SIGN, **259**
MENOPAUSE, **315**
Problems of, 118, 120, 124
MENSTRUAL CRAMPS, **142, 144**
MENSTRUAL DISORDERS, **140**
MERIDIAN ENERGY FLOW CHART, **71**
MERIDIANS, **68-71, 80, 85**
Abbreviations, 84
Bladder, 68
Circulation sex, 68
Gallbladder, 68
Heart, 68
Imbalanced, 90
Kidney, 68
Large intestine, 68
Liver, 68
Lung, 68
Rules to facilitate learning, 68
Running of, 88
Small intestine, 68
Spleen, 68
Triple warmer, 68
Yang, 72
Yin, 72
METABOLIC ACIDOSIS, **309**
METAL POINT, **85**
METASTATIC BONE TUMORS, **304**
METASTATIC CARCINOMA, **305**
MICROCYTIC, **298**
MIDDAY-MIDNIGHT LAW, **80**
Chart of, 80
MILL'S TEST, **255**
MINOR'S SIGN, **254**
MONOCYTES, **296**
MONONUCLEOSIS, **296**
Infectious, 313
MOTHER-SON LAW, **78**
MOTOR HOMUNCULUS, **381**
MOTOR NEURON LESIONS, **292-293**
Causes (upper and lower), 293
Differentiation between upper and lower, 293
Lower, 292
Space occupying lesions below first cervical, 293
Space occupying symptoms above first cervical, 293
Upper, 292
MOTOR PORTION, **278, 279**
MOTOR SYSTEM, **286**
Disturbances, characteristics of, 286
Lower motor neuron lesions, 286
Nerve root involvement, 286
Tests, 286
Upper motor neuron lesions, 286
MUCOPROTEIN, **308, 321**
MUCUS, **112, 114, 116, 148, 150, 152, 303, 318**
MULTIPLE MYELOMA, **304, 305, 308, 321**
MULTIPLE VITAMINS, **24**
MUMPS, **310, 319**
MUSCLES, **71**
Abdominal oblique (external), 110, 111
Abdominal oblique (internal), 112, 113
Abdominis (rectus), 114, 115
Abdominis (transversus), 116, 117

Adductor brevis, 118, 119
Adductor longus, 120, 121
Adductor magnus, 122, 123
Adductor pectineus, 124, 125
Anconeus, 126, 127
Biceps brachii, 128, 129
Brachioradialis, 130, 131
Coracobrachialis, 132, 133
Deltoids, 134, 135
Diaphragm, 136, 137
Facilitation, 29
Gastrocnemius, 138, 139
Gluteus maximus, 140, 141
Gluteus medius, 142, 143
Gluteus minimus, 144, 145
Gracilis, 146, 147
Grading, 109
Hamstrings — lateral biceps femoris, 148, 149
Hamstrings — medial semimembranosus, 150, 151
Hamstrings —medial semitendinosus, 152, 153
Hypertonic, 1
Iliacus, 154, 155
Infraspinatus, 156, 157
Inhibition, 29
Latissimus dorsi, 158, 159
Levator ani, 160, 161
Levator scapulae, 162, 163
Masseter, 164, 165
Neck extensors, 166, 167
Neck flexors, 168-175
Normal tonicity, 2
Pectoralis major clavicular, 176, 177
Pectoralis major sternal, 178, 179
Peroneus, 180-185
Piriformis, 186, 187
Popliteus, 188-190
Psoas, 190, 191
Pterygoid (external) lateral, 192, 193
Pterygoid (internal) medial, 194, 195
Quadratus lumborum — appendix, 196, 197
Quadriceps — rectus femoris, 204, 205
Quadriceps — vastus intermedius, 198, 199
Quadriceps — vastus lateralis, 200, 201
Quadriceps — vastus medialis, 202, 203
Rhomboids, 206-209
Sacrospinalis, 210-219
Sartorius, 220, 221
Scalenus anterior (See neck flexors)
Scalenus medius (See neck flexors)
Scalenus posterior (See neck flexors)
Serratus (anterior), 222, 223
Soleus, 224-225
Splenius capitis (See neck extensors)
Splenius cervicis (See neck extensors)
Sternocleidomastoid (See neck flexors)
Subscapularis, 228, 229
Supraspinatus, 230, 231
Temporalis, 232, 233
Tensor fascia lata, 234, 235
Teres major, 236, 237
Teres minor, 238, 239
Tibialis anterior, 240, 241
Tibialis posterior, 242, 243
Trapezius (middle and lower), 244-245
Trapezius (upper), 246, 247
Triceps brachii, 248, 249
Weakness patterns (multiple), 5, 6
MUSCLE TESTING, **8**
For nutrition, 22
In various positions, 8
MUSCLE WEAKNESS, **14**
MUSCLES AND RELATED NUTRITION, **23, 24**
MUSCULAR ATROPHY, **304**
MUSCULAR DYSTROPHY, **253, 304**
MYASTHENIA GRAVIS, **276, 304**
MYELOFIBROSIS, **308**
MYELOGRAPHS, **391**
MYELOID LEUKEMIA, **296, 300**
MYOCARDIAL INFARCTION, **296, 297, 306, 310, 311, 313, 322**
MYOSTITIS, **304**
MYXEDEMA, **296, 314, 315**

## N

NACHLAS' TEST, **257**
NAFFZIGER'S TEST, **397**
NARCOLEPSY, **110, 112, 116**
NASAL RESPIRATORY TECHNIQUE, **12, 382**
NATURE OF ENERGY, **86**
NECK, **257**
NECK EXTENSORS, **15, 16, 21, 49, 50, 60, 71**
NECK EXTENSORS, POSTERIOR AND LATERAL — SPLENIUS CAPITIS AND SPLENIUS CERVICIS, **166-167**
Action, 166
Anatomical drawing, 167
Associated muscles, 166
Connecting points, 167
Cranial stress center, 166
Exercise, 166
Holding points, Acu-therapy (Photo), 167
Insertion, 166
Internal manifestation, 166
Lab tests, 166
Meridian, 166-167
Muscle test (Photo), 166
Nerve supply, 166
Neurolymphatic receptors, 166-167
Neurovascular receptors, 166
Nutrition, 166
Origin, 166
Palpation, 166
Structural weakness, 166
NECK FLEXORS, **15, 16, 21, 49, 50, 71, 128, 130**
NECK FLEXORS, ANTERIOR AND LATERAL — SCALENUS ANTERIOR, **168-169**
Action, 168
Anatomical drawing, 169
Associated muscles, 168
Connecting points, 169
Cranial stress center, 168
Exercise, 168
Holding points, Acu-therapy (Photo), 169
Insertion, 168
Internal manifestations, 168
Lab tests, 168
Meridian, 168
Muscle test (Photo), 168
Nerve supply, 168
Neurolymphatic receptors, 168
Neurovascular receptors, 168
Nutrition, 168
Origin, 168
Palpation, 168
Structural weakness, 168
NECK FLEXORS, ANTERIOR AND LATERAL — SCALENUS MEDIUS, **170-171**
Action, 170
Anatomical drawing, 171
Associated muscles, 170
Connection points, 171
Cranial stress center, 170
Exercise, 170
Holding points, Acu-therapy (Photo), 171
Insertion, 170
Internal manifestations, 170
Lab tests, 170
Meridian, 170-171
Muscle test (Photo), 170
Nerve supply, 170
Neurolymphatic receptors, 170, 171
Neurovascular receptors, 170
Nutrition, 170
Origin, 170
Palpation, 170
Structural weakness, 170
NECK FLEXORS, ANTERIOR AND LATERAL — SCALENUS POSTERIOR, **172-173**
Action, 172
Anatomical drawing, 173
Associated muscles, 172
Connecting points, 173
Cranial stress center, 172
Exercise, 172
Holding points, Acu-therapy (Photo), 173
Insertion, 172
Internal manifestations, 172
Lab tests, 172
Meridian, 172-173
Muscle test (Photo), 172
Nerve supply, 172
Neurolymphatic receptors, 172-173
Neurovascular receptors, 172
Nutrition, 172
Origin, 172
Palpation, 172
Structural weakness, 172
NECK FLEXORS, ANTERIOR AND LATERAL — STERNOCLEIDOMASTOID, **174-175**
Action, 174
Anatomical drawing, 175
Associated muscles, 174
Connecting points, 175
Exercise, 174
Holding points, Acu-therapy (Photo), 175
In spinal accessory device exam, 279
Insertion, 174
Internal manifestations, 174
Lab tests, 174
Meridian, 174-175
Muscle test (Photo), 174
Nerve supply, 174
Neurolymphatic receptors, 174, 175
Nutrition, 27, 174
Origin, 174

Palpation, 174
Structural weakness, 174
NECK MUSCLES
Neurolymphatic receptors, 20, 21
Neurovascular receptors, 16, 17
Posture, effect on, 7
T.S. line location, 15
NECK PROBLEMS, **110, 112, 114, 116, 166**
NEGATIVE SURFACE, **12**
NERVE, **9**
Intervertebral foramen and, 9
NERVE ENERGY, **12**
NERVOUSNESS, **132**
NERVOUS SYSTEM, **19**
NEPHRITIS, **301, 304, 305, 306, 309**
Acute, 303
NEPHRODIC SYNDROME, **323**
NEPHROSIS, **303, 309, 312, 314, 323**
NERVE ROOT AND DISC SYNDROMES, **391**
NERVE ROOTS, **391**
NERVE ROOT SYNDROMES, **394**
Dorsal, 396
Eighth cervical, 396
Seventh cervical, 395
Sixth cervical, 394
NEUROLOGY, **274, 294**
Cerebellum (See cerebellum)
Cerebral functions (general) (See cerebral functions, general)
Cranial nerve exam (See cranial nerve exam)
Deep reflexes (See reflexes)
Extrapyramidal system (See extrapyramidal system)
Gaits (See gaits)
Motor system (See motor system)
Pathological reflexes (See reflexes)
Pyramidal system (See pyramidal system)
Sensory system (See sensory system)
Specific cerebral function (See cerebral function, specific)
Superficial reflexes (See reflexes)
Traits of the spinal cord (See spinal cord)
Upper and lower motor neuron lesions (See motor neuron lesions)
Visceral reflexes (See reflexes)
NEUROLOGY — THE CEREBELLUM, **281-282**
Abnormalities of muscle tone, 281
Abnormalities of speech, 281
Ataxia, 281
Common causes of cerebellar disorders, 282
Common signs of cerebellar disorders, 281
Cranial faults, 282
Degenerative lesions, 282
Disturbances of alternating movement, 381
Finger-to-nose test, 281
General cerebellar functions, 281
General cerebellar test, 281
Holmes' rebound phenomenon, 281
Inflammatory disease, 282
Nystagmus, 281
Romberg's sign, 281
Specific cerebellar tests, 281
Standing sign-of-four, 281
Supination-pronation test, 281
Tandem gait, 281
Toe-to-finger test, 281
Toxins, 282
Trauma, 282
Tremor, 281
Tumors, 282
NEUROLOGY — CRANIAL NERVE EXAMINATION, **276-280**
Abducens, 276
Acoustic, 278
Facial, 278
Glossopharyngeal, 279
Hypoglossal, 280
Oculomotor, 276
Olfactory, 276
Optic, 276
Spinal accessory, 279
Trigeminal, 277
Trochlear, 276
Vagus, 279
NEUROLOGY — EXTRAPYRAMIDAL SYSTEM (BASAL GANGLIA), **282-283**
Common major conditions, 283
General functions, 282
General test, 282
Pendulum arm swinging test, 283
Shoulder shaking test, 283
Specific tests, 283
NEUROLOGY — GAITS
Antalgic gait, 294
Ataxic gait, 294
Cerebellar gait, 294
Charcot's gait, 294
Common gaits, 294
Definition, 294
Gait limp, 294
Multiple sclerotic gait, 294
Normal gait, 294
Paralytic gait, 294
Spastic gait, 294
Steppage gait, 294
NEUROLOGY — GENERAL CEREBRAL FUNCTIONS, **274**
Emotional status, 274
General behavior, 274
Level of consciousness, 274
Memory, 274
Thought content, 274
NEUROLOGY — MOTOR SYSTEM, **286**
Characteristics of motor disturbances, 286
Lower motor neuron lesions, 286
Nerve root involvement, 286
Tests for the motor system, 286
Upper motor neuron lesions, 286
NEUROLOGY — PYRAMINDAL SYSTEM, **282-283**
General function, 282
Location, 282
Pyramidal sign, 282
Pyramidal tests, 282
Quadriceps tonus test, 282
Tibialis associated movement, 282
NEUROLOGY — SENSORY SYSTEM, **285-286**
Deep pressure pain, 286
Motion and position, 286
Primary forms of sensation, 285
Sensitivity to temperature, 285
Sensitivity to vibration, 286
Sensory loss, 286
Superficial pain, 285
Superficial tactile sensation, 285
Tests for the sensory system, 285
NEUROLOGY — TRACTS OF THE SPINAL CORD, **283-285**
Anterior horns, 284
Anterior or ventral white columns, 284
Gray commissure, 284
Gray matter, 284
Lateral white columns, 284
Lesions of the white or gray matter, 284
Localization of spinal cord lesions, 285
Posterior white columns, 283, 284
Pyramidal tracts, 284
White matter, 283
NEUROLYMPHATIC RECEPTORS, **8, 9, 12, 19, 21, 48, 64**
Chart of, 20
NEUROMUSCULAR, **29**
NEUROVASCULAR COMPRESSION SYNDROME, **260, 261**
NEUROVASCULAR PULSE, **18**
NEUROVASCULAR RECEPTORS, **9, 12, 14, 16, 48, 51, 64, 78**
Picture of, 17
NEUTROPHIL COUNT, **118, 120, 122, 142, 144, 148, 150, 152**
NEUTROPHILS, **296, 318, 319, 320, 322**
NIACINAMIDE, **24**
NODULES, **14, 28**
NONPROTEIN NITROGEN (NPN), **306**
NORMOCHROMIC NORMOCYTIC ANEMIA, **298**
NOSE, **32**
NPN, **190, 206, 208**
NUCLEUS PULPOSUS, **64**
Challenge technique for lateral shift, 64
Challenge technique for posterior shift, 64
NUMBNESS, **186**
NUTRITION, **8, 9, 22-28, 64**
Adrenal extract, 23, 24
Alfalfa, 24
Betaine hydrochloride, 23, 24
Bile salts, 23, 24
Cardiac protomorphogen, 24
Charts, 64
Chewing supplements, 22
Chlorophyll complex, 23
Dosage, 22
Fast oxidizers, 23
Gallbladder extracts of bile salts, 23
Gastric enzymes, 23
Ileocecal valve, 326
Intervertebral foramen, 9
Intestinal enzyme
Kidney extract, 24
Lactobacillus acidophilus, 24
Liver extract, 24
Lung protomorphogen, 23, 24
Multiple vitamins, 23
Niacinamide and $B_6$, 24
Organic iodine, 24
Organic iron, 24
Organic minerals, 24
Ovarian extract, 23
Pancreatic protomorphogen, 23
Phosphorus, 24
Prostate, 23
Ribonucleic acid, 24

Spleen extract, 24
Testing, 8, 22
Thyroid, 24
Uterine extract, 23
Vitamin A, 24
Vitamin $B_{12}$, 24
Vitamin B complex, 23, 24
Vitamin C, 23, 24
Vitamin D, 24
Vitamin E, 23, 24
Vitamin F, 23, 24
Vitamin G, 23, 24
Wheat germ, 23, 24
Yeast, 24
NUTRITION AND MUSCLES, **23, 24**
NUTRITIONAL QUESTIONNAIRE, **25**
NUTRITIONAL TESTING, **22**
Therapy localization, 22
NYSTAGMUS, **281**

## O

OBER'S TEST, **259**
OCCIPITAL ATLANTAL COUNTER TORQUE, **44**
Challenge, 44
Identifying characteristics, 44
Kinesiological correction, 44
Therapy localization, 44
OCCIPITAL FIXATION, **56**
OCCIPITAL FIXATION AND SUBLUXATION, **56-57**
Challenge, 57
Clinical observation, 56
Symptoms, 56
Therapy localization, 56
Treatment, 57
OCCIPITAL LOBE, **276**
OCCIPITAL SUBLUXATION, **56**
OCCIPUT, **8, 11, 32, 162**
High, 32, 142, 144, 166
Jammed, 220
Low, 32
OCCIPUT-ATLAS ROCKER MECHANISM, **57**
Challenge, 57
Treatment, 57
OCCULT BLOOD, **320**
OCHRONOSIS, **301**
OCULAR DISTURBANCES, **324**
OCULAR LOCK, **45**
Challenge, 45
Identifying characteristics, 45
Kinesiological correction, 45
Therapy localization, 45
OCULAR TORTICOLLIS, **277**
OCULOCARDIAC REFLEX, **279**
ONE-HALF BREATH IN ASSIST, **35**
Challenge, 35
Identifying characteristics, 35
Kinesiological correction, 35
Therapy localization, 35
ONE-HALF BREATH OUT ASSIST, **36**
Challenge, 36
Identifying characteristics, 36
Kinesiological correction, 36
Therapy localization, 36
ORGAN DETOXIFICATION, **377-380**
Alkalizing punch, 379
Coffee retention enema, 378
Colon, 378
Fasting, 380
Kidney, 378
Liver and Gallbladder, 377
Lungs, 378
Purge, 379
ORGANIC IODINE, **24, 156**
ORGANIC IRON, **24**
ORGAN POINTS, **85**
ORIGIN TECHNIQUE, **28**
ORTHOPEDIC RANGES OF MOTION, **266-272**
Ankle dorsiflexion, 271
Ankle plantar flexion
Cervical flexion and extension, 266
Cervical right and left lateral flexion, 266
Cervical right and left rotation, 266
Dorsolumbar flexion and extension, 266
Dorsolumbar right and left lateral flexion, 267
Dorsolumbar right and left rotation, 267
Elbow extension, 267
Elbow flexion, 267
Forearm pronation, 268
Forearm supination, 268
Hip abduction, 270
Hip adduction, 270
Hip backward extension, 269
Hip flexion, 269
Knee extension, 270
Knee flexion, 270
Shoulder abduction, 272
Shoulder extension, 271
Shoulder external rotation, 272
Shoulder flexion, 271
Shoulder internal rotation, 272
Wrist extension, 268
Wrist flexion, 268
Wrist radial deviation, 269
Wrist ulnar deviation, 269
ORTHOPEDIC TESTS, **252-264**
Adam's position, 252
Bechterew's test, 254
Bilateral leg lowering, 256
Braggard's test, 256
Chest expansion, 254
Compression pelvic test, 259
Ely's test, 258
Fabere-Patrick's test, 256
Fajersztajn's test, 256
Gaenslen's test, 257
Goldthwait's test, 255
Gowers' sign, 254
Heel-and-toe standing test, 253
Heel-to-buttocks test, 258
Hibb's test, 258
Kemp's sign or test, 253
Kernig's sign, 257
Lasègue's test, 255
Lewin's sign or test, 252
Mennell's sign, 259
Mill's test, 255
Minor's sign, 254
Nachlas' test, 257
Ober's test, 259
Rust's syndrome, 257
Soto-Hall test, 255
Spinous percussion test, 258
Standing sign-of-four, 253
Straight leg sitting, 254
Thomas' sign, 256
Toe-to-mouth test, 252
Trendelenburg's test, 253
Well-leg-raising test, 259
Yeoman's test, 258
ORTHOPEDIC TESTS — MALINGERING TESTS, **263-264**
Burn's test, 263
Flexed hip test, 264
Flip test, 263
Hoover's sign, 263
Libman's test, 263
Plantar flexion test, 264
Seated forward bend test, 264
ORTHOPEDIC TESTS — NEUROVASCULAR SECTION, **260-262**
Adson's maneuver, 260
Allen's test, 261
Costoclavicular test, 261
Eden's test, 262
Foramina compression test, 260
Hyperabduction test, 260
Jackson's maneuver, 260
Shoulder depression test, 262
Wright's test, 261
OSSEOUS PATHOLOGY, **258**
OSTEITIS DEFORMANS, **319**
OSTEOARTHRITIS, **297**
OSTEOGENIC SARCOMA, **310, 321**
OSTEOMALACIA, **305, 310, 319**
OTITIS MEDIA, **278, 319**
OVARIAN EXTRACT, **23**
OVERCONTRACTS, **29**
OXIDIZERS, **25**
Fast, 25, 28
Slow, 25

## P

PACKED CELL VOLUME, **297**
PAGET'S DISEASE, **305, 310, 319**
PAIN (REFERRED), **339**
PANCREAS
Anconeus, 126-127
Latissimus dorsi, 158-159
Nutrition, 23
Triceps brachii, 248-249
PANCREATIC PROBLEMS, **176**
PANCREATIC PROTOMORPHOGEN, **23**
PANCREATITIS (ACUTE), **310, 312**
PAP TEST, **142, 144**
PARACOLON, **317**
PARESTHESIA, **391**
PARIETAL BONE JAMMING, **170, 172**
PARIETAL LOBE, **276**
PAROXYSMAL HEMOGLOBINURIA, **301**
PASSAGE POINTS, **84**
PECTORALIS MAJOR CLAVICULAR, **4, 15, 16, 21, 49, 50, 51, 71, 134, 176, 177**
Action, 176
Anatomical drawing, 177
Associated muscles, 176
Connecting points, 177
Cranial stress center, 176
Exercise, 176
Holding points, Acu-therapy (Photos), 177

In emotional patterns, 51
Insertion, 176
Internal manifestations, 176
Lab tests, 176
Meridian, 71, 176, 177
Muscle test (Photo), 176
Nerve supply, 176
Neurolymphatic receptors, 20, 21, 176, 177
Neurovascular receptors, 16, 17, 176
Nutrition, 23, 176
Origin, 176
Palpation, 176
Posture, effect on, 4, 7
Structural weakness, 176
T.S. line location, 15
PECTORALIS MAJOR STERNAL, **4, 15, 16, 21, 48, 50, 71, 178, 179**
Action, 178
Anatomical drawing, 177
Associated muscles, 178
Connecting points, 179
Cranial stress center, 178
Exercise, 178
Holding points, Acu-therapy (Photos), 179
Insertion, 178
Internal manifestations, 178
Lab tests, 178
Meridian, 71, 178
Muscle test (Photo), 178
Nerve supply, 178
Neurolymphatic receptor, 20, 21, 178
Neurovascular receptor, 16, 17, 178
Nutrition, 23, 178
Origin, 178
Palpation, 178
Posture, effect on, 4
Structural weakness, 178
T.S. line location, 15
PELVIC FAULTS, **60**
Category I, 61
Category II, 60
Category III, 60
PELVIS, **7, 13, 51, 259**
Low, 120, 122
Rotated, 140
Tilted, 118, 124, 140
PERIARTHRITIS NODOSA, **299, 313**
PERICARDIUM, **71**
PERONEUS, **7, 71, 180-185**
Meridian, 71
Neurolymphatic receptor, 20, 21
Neurovascular receptor, 16, 17
Nutrition, 23
PERONEUS — BREVIS, **16, 21, 180-181**
Action, 180
Anatomical drawing, 181
Associated muscles, 180
Connecting points, 181
Exercise, 180
Holding points, Acu-therapy (Photo), 181
Insertion, 180
Internal manifestations, 180
Lab tests, 180
Meridian, 180-181
Muscle test (Photos), 180
Nerve supply, 180
Neurolymphatic receptors, 180
Neurovascular receptors, 180
Nutrition, 180, 181
Origin, 180
Palpation, 180
Structural weakness, 180
PERONEUS — LONGUS, **16, 21, 182-183**
Anatomical drawing, 183
Associated muscles, 182
Connecting points, 183
Exercise, 182
Holding points, Acu-therapy (Photo), 183
Insertion, 182
Internal manifestations, 182
Lab tests, 182
Meridian, 182, 183
Muscle test (Photos), 182
Nerve supply, 182
Neurolymphatic receptors, 182, 183
Neurovascular receptors, 182
Nutrition, 182
Origin, 182
Palpation, 182
Posture, effect on, 7
Structural weakness, 182
PERONEUS TERTIUS (5th TENDON), **184-185**
Action, 184
Anatomical drawing, 185
Associated muscles, 184
Connecting points, 185
Exercise, 184
Holding points, Acu-therapy (Photo), 185
Insertion, 184
Internal manifestations, 184
Lab tests, 184
Meridian, 184
Muscle test (Photos), 184
Nerve supply, 184
Neurolymphatic receptors, 184
Neurovascular receptors, 184
Nutrition, 184
Origin, 184
Palpation, 184
Structural weakness, 184
PERTUSSIS, **296**
PES-PLANUS, **7**
pH OF SALIVA, **128**
PIRIFORMIS, **16, 21, 49, 62, 71, 166, 186, 187**
Action, 186
Anatomical drawing, 187
Associated muscles, 186
Connecting points, 187
Cranial stress center, 186
Exercise, 186
Holding points, Acu-therapy (Photo), 187
Insertion, 186
Internal manifestations, 186
Lab tests, 186
Meridian, 71, 186, 187
Muscle testing in various positions, 8
Muscle test (Photo), 186
Nerve supply, 186
Neurolymphatic receptors, 20, 21, 186, 187
Neurovascular receptors, 16, 17, 186
Nutrition, 23, 186
Origin, 186
Palpation, 186
Posture, effect on, 7
Structural weakness, 186
T.S. line location, 15
PIRIFORMIS ADDUCTORS, **15**
PISIFORM-HAMMATE TUNNEL (See carpal tunnel)
PITUITARY GLAND, **10**
PLACENTAL MALIGNANCIES, **314**
PLANTAR FLEXION TEST, **264**
PLASMA CELLS, **321**
PLASMA FIBRINOGEN, **318**
PLATELET COUNT, **300**
PNEUMONIA, **304**
POIKILOCYTOSIS, **298**
POINTS OF SEDATION, **9, 83**
Chart, 83
Example, 83
POINTS OF TONIFICATION, **9, 82**
Chart, 82
Example, 82
POISONING, **301**
POLIO, **253**
POLIOMYELITIS, **304**
POLYCHROMIC, **298**
POLYCYTHEMIA, **308**
POLYCYTHEMIA DEHYDRATION, **297**
POLYCYTHEMIA VERA, **296, 297 298, 300**
POPLITEAL NERVE INJURY, **253**
POPLITEUS, **7, 15, 16, 21, 49, 71, 188, 189**
Action, 188
Anatomical drawing, 189
Associated muscles, 188
Connecting points, 189
Cranial stress center, 188
Exercise, 188
Holding points, Acu-therapy (Photo), 189
Insertion, 188
Internal manifestations, 188
Lab tests, 188
Meridian, 71, 188, 189
Muscle test (Photo), 188
Nerve supply, 188
Neurolymphatic receptors, 20, 21, 188, 189
Neurovascular receptors, 16, 17
Nutrition, 23, 188
Origin, 188
Palpation, 188
Posture, effect on, 7
Structural weakness, 188
T.S. line location, 15
POSITIVE SURFACE, **12**
POSTERIOR ILIUM, **138, 146, 220**
POSTERIOR ISCHIUM, **150**
POSTERIOR SPINOUS LIGAMENTS, **255**
POSTERIOR TIBIALIS, **71**
POST PRANDIAL GLUCOSE, **318**
POSTURAL DRAINAGE, **355**
Percussion, 355
Positions, 356
Procedure, 355
POSTURAL HYPOTENSION AND FUNCTIONAL HYPOADRENIA, **327**
POSTURAL PATTERNS, **2-7**
POTASSIUM, **305, 320**
PRE AND POST GANGLIONIC TECHNIQUE, **387**
Location of vortices, 387
Treatment of, 388

PRE-BETA LIPOPROTEINS, **312**
PREGNANCY, **297**
PRIMARY HYPERLIPIDEMIA, **312**
PRINCIPLES OF THE FIVE ELEMENTS, **76**
PROMINENT EYE, **32**
PROSTATE
Extract, 23
Gluteus maximus, 140-141
Problems, 142, 144
PROSTATIC CARCINOMA, **310, 321**
PROSTATIC CONDITIONS, **140**
PROSTATIC HYPERTROPHY, **306**
PROSTATITIS, **303**
Acute, 320
PROTEIN, **322, 323**
C-reactive, 320
Deficiency, 306
Total, 178, 323
PROTEIN-BOUND IODINE (PBI), **314**
PROTEINURIA, **302**
PROTHROMBIN TIME, **318, 321**
PSOAS, **3, 5, 7, 15, 54, 71**
Weakness, 154
PSOAS-DIAPHRAGM TECHNIQUE, **386**
Treatment of, 387
PSOAS MAJOR, **16, 21, 50, 190, 191**
Action, 190
Anatomical drawing, 190
Associated muscles, 190
Connecting points, 191
Cranial stress center, 190
Exercise, 190
Holding points, Acu-therapy (Photo), 191
Insertion, 190
Internal manifestations, 190
Lab tests, 190
Meridian, 71, 190
Muscle test (Photo), 190
Muscle testing in various positions, 18
Nerve supply, 190
Neurolymphatic receptors, 16, 17, 20, 21, 190, 191
Neurovascular receptors, 190
Normal tonicity, 2
Nutrition, 24, 170
Origin, 190
Palpation, 190
Posture, effect on, 3, 5, 6, 7
Structural weakness, 190
T.S. line location, 15
PSORIASIS, **296**
PTERYGOIDS, **71**
PTERYGOID (EXTERNAL) — LATERAL, **192-193**
Action, 192
Anatomical drawing, 193
Associated muscles, 192
Connecting point, 193
Exercise, 192
Holding points, Acu-therapy (Photo), 193
Insertion, 192
Internal manifestations, 192
Lab tests, 192
Meridian, 192-193
Muscle test (Photo), 192
Nerve supply, 192
Neurolymphatic receptors, 192, 193
Neurovascular receptors, 192
Nutrition, 192
Origin, 192
Palpation, 192
Structural weaknesses, 192
PTERYGOID (INTERNAL) — MEDIAL, **194-195**
Action, 194
Anatomical drawing, 195
Associated muscles, 194
Connecting point, 195
Exercise, 194
Holding points, Acu-therapy (Photo), 195
Insertion, 194
Internal manifestations, 194
Lab tests, 194
Meridian, 71, 194-195
Muscle tests (Photo), 194
Nerve supply, 194
Neurolymphatic receptors, 194, 195
Neurovascular receptors, 194
Nutrition, 194
Origin, 194
Palpation, 194
Structural weakness, 194
PULMONARY EMBOLISM, **310, 322**
PULMONARY EMPHYSEMA, **322**
PULSES, **78, 261**
Position of, (illustration), 79
Therapy localizing, 79
PUMPING ACTION, **11**
PUPILLARY RESPONSE, **277**
PUS, **148, 150, 152**
PUS CELLS, **110, 112, 114, 116, 118, 120, 122, 318, 321, 323**
PYLORIC STENOSIS, **320**
PYOGENIC INFECTIONS, **296**
PYRAMIDAL SYSTEM, **282**

## Q

QI, **68**
QUADRATUS LUMBORUM, **3, 5, 15, 16, 21, 49, 71, 196, 197**
Action, 196
Anatomical drawing, 197
Associated muscles, 196
Connecting points, 197
Cranial stress center, 196
Exercise, 196
Holding points, Acu-therapy (Photo), 197
Insertion, 196
Internal manifestations, 196
Lab tests, 196
Meridian, 71, 196-197
Muscle test (Photo), 196
Nerve supply, 196
Neurolymphatic receptors, 20, 21, 196, 197
Neurovascular receptors, 16, 17
Normal tonicity, 2
Nutrition, 196
Origin, 196
Palpation, 196
Posture, effect on, 3, 5, 6
Structural weakness, 196
T.S. line location, 15
QUADRICEPS, **7, 15, 71, 116**
Meridians, 71
Neurocymphatil receptors, 20, 21
Neurovascular receptors, 16, 17
Nutrition, 24
Posture, effect on, 7
T.S. line location, 15
QUADRICEPS FEMORIS, **16, 21**
QUADRICEPS — RECTUS FEMORIS, **204-205**
Action, 204
Anatomical drawing, 205
Associated muscles, 204
Connecting point, 205
Cranial stress center, 204
Exercise, 204
Holding points, Acu-therapy (Photo), 205
Insertion, 204
Internal manifestations, 204
Lab tests, 204
Meridian, 204
Muscle test (Photo), 204
Nerve supply, 204
Neurolymphatic receptors, 204
Neurovascular receptors, 204
Nutrition, 204
Origin, 204
Palpation, 204
Structural weakness, 204
QUADRICEPS — VASTUS INTERMEDIUS, **198-199**
Action, 198
Anatomical drawing, 199
Associated muscles, 198
Connecting point, 199
Exercise, 198
Holding points, Acu-therapy (Photo), 199
Insertion, 198
Internal manifestations, 198
Lab tests, 198
Meridian, 198-199
Muscle test (Photo), 198
Nerve supply, 198
Neurolymphatics, 198-199
Nutrition, 198
Origin, 198
Palpation, 198
Structural weakness, 198
QUANTITATIVE CALCIUM, **305**
QUECKENSTEDT'S SIGN, **397**

## R

RADIAL ARTERY, **261**
RADIAL PULSE, **260, 262**
RADIOHUMERAL EPICONDYLITIS, **255**
RANGE OF MOTION, **266, 267, 268, 269, 271, 272**
RAPID EYE MOVEMENTS (REM'S)
In emotional patterns, 51
RBC, **148, 150, 152, 190**
REACTIVE MUSCLES, **30**
Chart, 30
REACTIVE MUSCLE TESTING, **29**
REBOUND PHENOMENON, **13**
RECTUM
Hamstrings, 148-153
Levator ani, 160-161
Nutrition, 23

RECTUS ABDOMINIS, **3**
REFLEXES, **287-292**
Abdominal (lower), 288
Abdominal (upper), 288
Abnormal significances, 292
Accommodation, 287
(See also reflexes, ciliary)
Achilles, 289
Anal, 288
Babinski's platsyma sign, 290
Babinski's sign, 291
Biceps, 289
Bladder, 287
Bulbocavernosus, 287
Carotid sinus, 279, 287
Chaddock's toe sign, 291
Chaddock's wrist sign, 290
Ciliary reflex, 277
Ciliospinal, 287
Corneal, 277, 288
Cremasteric, 288
Gag, 279
Gonda, 291
Gordon's finger sign, 290
Gordon's leg sign, 291
Grading of, 292
Hoffman's sign, 290
Jaw jerk, 278, 289
Light, 287
Maxillary, 289
(See also reflexes, jaw jerk)
McCarthy's sign, 290
Oculocardiac, 279, 287
Oppenheim's sign, 291
Patellar, 289
Plantar, 288
Radial, 289
Rectal, 287
Rossolimo's sign, 291
Schaefer's sign, 291
Triceps, 289
Uvula, 288
REFLEX POINTS, **64, 65**
REGULATOR POINTS, **85**
REMS, **51**
RENAL CALCULI, **323**
RENAL DISORDERS, **306, 308**
RENAL INSUFFICIENCY, **309, 310**
RENAL RICKETS, **305**
REPRODUCTIVE ORGAN DISORDERS, **118, 120, 124**
RESPIRATION, **13**
Cerebral spinal fluid and, 10-11
Intervertebral foramen, 9
Sacral movement and, 11
Vertebral movement on, 52
RESPIRATORY ASSISTANCE, **9**
RESPIRATORY CYCLE, **32**
RESPIRATORY FAULTS, **14**
RESPIRATORY PATTERN, **10**
RESPIRATORY PHASE
Expiration assist, 10
Forced expiration assist, 10
Forced inspiration assist, 10
One-half breath in assist, 10
One-half breath out assist, 10
Inspiration, 10
RESPIRATORY PROBLEMS, **110, 112, 116**
RESPIRATORY SPINAL AND PELVIC CORRECTION TECHNIQUE, **54**
RESTLESSNESS, **148, 150**
RESTRICTED MOTION, **210, 252**
RESTRICTED RANGE OF MOTION, **257, 265**
RETICULOCYTE COUNT, **300**
RHEUMATIC FEVER, **297, 320**
Acute, 313
RHEUMATISM, **210, 257**
RHEUMATOID ARTHRITIS, **297, 299, 308, 313, 320**
RHOMBOIDS, **5, 21, 71, 128, 130**
Posture, effect on, 5, 7
RHOMBOIDS, MAJOR, **50, 206, 207**
Action, 206
Anatomical drawing, 207
Associated muscles, 206
Connecting point, 207
Cranial stress center, 206
Exercise, 206
Holding points, Acu-therapy (Photo), 207
Insertion, 206
Internal weakness, 206
Lab tests, 206
Meridian, 71, 206, 207
Muscle test (Photo), 206
Nerve supply, 206
Neurolymphatics, 206
Nutrition, 206
Origin, 206
Palpation, 206
Structural weakness, 206
RHOMBOIDS, MINOR, **50, 208-209**
Action, 208
Anatomical drawing, 209
Associated muscles, 208
Connecting point, 209
Cranial stress center, 208
Exercise, 208
Holding points, Acu-therapy (Photo), 209
Insertion, 208
Internal manifestations, 208
Lab tests, 208
Meridian, 208
Muscle test (Photo), 208
Nerve supply, 208
Neurolymphatic receptors, 208
Nutrition, 208
Origin, 208
Palpation, 208
Structural weakness, 208
RIB FIXATION, **134, 136, 188**
RIBONUCLEIC ACID, **24**
RIB SUBLUXATION (LOWER), **196**
RINGWORM, **320**
RINNE'S TEST, **278**
ROTATED ILIUM, **110**
ROTATORES BREVIS MUSCLE, **54**
ROTATORES LONGUS MUSCLE, **54**
RUBEOLA, **320**
RUNNING MERIDIANS, **86**
RUST'S SYNDROME, **257**

## S

SACRAL APEX, **60**
SACRAL FAULT, **148, 150, 152**
SACRAL INSPIRATION ASSIST (Photo), **59**
SACRAL RESPIRATORY MOVEMENT
(See cranial and sacral respiratory movement)
SACRAL TWIST, **186**
SACRAL WOBBLE FAULT, **60**
SACROILIAC, **252, 257, 258**
SACROILIAC JOINT, **259**
SACROILIAC LESION, **252, 254, 256, 257, 258**
SACROILIAC LIGAMENTS, **259**
SACROILIAC STRAIN, **259**
SACROSPINALIS, **3, 7, 21, 71, 210-219**
Action, 210, 212, 214, 216
Anatomical drawing, 211, 213, 215, 218, 219
Associated muscles, 210, 212, 214, 216
Connecting point, 219
Holding point, Acu-Therapy (Photo), 219
Insertion, 210, 212, 214, 216
Internal manifestations, 210, 212, 214, 216
Lab tests, 210, 212, 214, 216
Meridian, 71, 210, 212, 214, 216
Muscle workup, 210-219
Nerve supply, 210, 211, 214, 216
Neurolymphatic receptors, 210, 212, 214, 216
Nutrition, 24, 210
Origin, 210, 212, 214, 216
Palpation, 210, 212, 214, 216
Posture, effect on, 3, 7
Structural weakness, 210, 212, 214, 216
SACRUM, **11, 32, 52, 60**
SACRUM BALANCE, **59**
SACRUM FIXATION, **60**
SAGITTAL SPREAD ASSIST, **37**
Challenge, 37
Identifying characteristics, 37
Kinesiological corrections, 37
Therapy localization, 37
SAGITTAL SUTURE (JAMMED), **110, 112, 114**
SALICYLATES, **316**
SARTORIUS, **7, 15, 16, 21, 49, 71, 220, 221**
Action, 220
Anatomical drawing, 221
Associated muscles, 220
Connecting points, 221
Cranial stress center, 220
Exercise, 220
Holding points, Acu-therapy (Photo), 221
Insertion, 220
Internal manifestations, 220
Lab tests, 220
Meridian, 71, 220
Muscle test (Photo), 220
Nerve supply, 220
Neurolymphatic receptors, 20, 21, 220
Neurovascular receptors, 16, 17, 220
Nutrition, 24, 220
Origin, 220
Palpation, 220
Posture, effect on, 7
Structural weakness, 220
T.S. line location, 15

SCALENE
Nutrition, 24
Scalenus anterior (See neck flexors, anterior and lateral)
Scalenus medius (See neck flexors, anterior and lateral)
Scalenus posterior (See neck flexors, anterior and lateral)
Splenius capitis (See neck flexors, posterior and lateral)
Splenius cervicis (See neck flexors, posterior and lateral)
Sternocleidomastoid (See neck flexors, anterior and lateral)
SCALENUS ANTICUS SYNDROME, **260, 261**
SCARLET FEVER, **296**
SCIATIC PAIN, **186**
SCIATICA, **254, 256**
SCIATICA DISC INVOLVEMENT, **253**
SCLERA, **278**
SCOLIOSIS, **7, 28, 210**
SEATED FORWARD BEND TEST, **264**
SEMINAL VESICLES
Gluteus medius, 142, 143
Gluteus minimus, 144, 145
Nutrition, 23
Piriformis, 186, 187
SENSORY PORTION, **277, 278**
SENSORY SYSTEM, **285-286**
Sensations, 285
Sensory loss, 286
Tests, 285
SEPARATED SUTURE, **32**
SEROLOGY, **313**
Antistreptolysin-O-Titer, 313
C-reactive protein (CRP), 313
Florescent treponemal antibodies, 313
Heterophil antibody, 313
Rheumatoid arthritis (RA), 313
VDRL, 313
SERRATUS (ANTERIOR), **7, 21, 50, 222-223**
Action, 222
Anatomical drawing, 223
Associated muscles, 222
Connecting points, 223
Cranial stress center, 222
Exercise, 222
Holding points, Acu-therapy (Photo), 223
Insertion, 222
Internal manifestations, 222
Lab tests, 222
Meridian, 71, 222, 223
Muscle test (Photo), 222
Nerve supply, 222
Neurolymphatic receptors, 20, 21, 222, 223
Neurovascular receptors, 16, 17, 222
Nutrition, 24, 222
Origin, 222
Palpation, 222
Posture, effect on, 4, 7
Structural weakness, 222
T.S. line location, 15
SERUM AMYLASE, **126, 196, 198, 202, 204, 310**
SERUM BILIRUBIN, **188, 308**
SERUM CALCIUM, **226**
SERUM CHLORIDE, **146, 309**
SERUM GLUTAMIC OXALACETIC TRANSAMINASE (S-GOT), **311**
SERUM GLUTAMIC PYRUVIC TRANSAMINASE (S-GPT), **311**
SERUM HEMOGLOBIN, **140**
SERUM LACTIC DEHYDROGENASE (LDH), **310**
SERUM MUCOPROTEIN, **308**
SERUM POTASSIUM, **138, 146, 220, 309**
SERUM SODIUM, **209**
SERUM URIC ACID, **308**
SEWAGE SYSTEM, **19**
SEX GLANDS
Gluteus maximus, 140, 141
Gluteus medius, 142-143
Gluteus minimus, 144-145
Nutrition, 23
SEXUAL IMPOTENCY, **140**
SGOT, **176, 178, 318, 319, 322**
SGPT, **176, 318, 319, 322**
SHOCK, **296, 309**
SHOCK ABSORB VS. SHOCK TRANSMIT, **386**
SHOCK TRANSMITTING, **386**
SHOULDER, **7, 262**
Abduction, 272
Bursitis, 338
Cramps, 134
Difficulties, 156
Disturbances, 178
Extension, 271
External rotation, 272
Flexion, 271
High, 142, 144
Internal rotation, 272
Pain, 210, 338
Problems, 110, 114, 116, 126, 128, 130, 132, 158, 176, 206, 208, 222, 226, 228
Stiff, 118
SHOULDER DEPRESSION TEST, **262**
SICKLE CELL PREPARATION, **300**
SIGNS
Babinski, 291
Babinski's platysma, 290
Chaddock's toe, 291
Chaddock's wrist, 290
Gordon's finger, 290
Gordon's leg, 291
Hoffman's, 290
McCarthy's, 290
Oppenheim's, 291
Orthopedic (See orthopedic tests)
Pyramidal sign, 282
Rossolimo's, 291
Schaefer's, 291
SINUS
Nutrition, 24
SINUSES
Neck extensors, 166-167
Neck flexors, 168-175
SINUSITIS, **166, 168, 170, 172, 174, 192, 194**
SIXTH CERVICAL NERVE ROOT SYNDROME, **394**
SIXTH CERVICAL RUPTURED DISC, **393**
SKIN CONDITIONS, **190, 296**
SKULL
Bone movement in respiration, 10
Motion, 14
SLIPPED BICIPITAL TENDON, **338**
SMALL INTESTINE
Abdominal muscle, 110-117
Nutrition, 24
SMALL INTESTINE MERIDIAN, **99**
Alarm point, 99
Associated muscles, 99
Associated point, 99
Coupled meridian, 99
Dominates, 99
Element, 99
Emotion, 99
Energy flow, 99
Figure of, 68
Meridian connector, 99
Mother of, 99
Number of points on meridian, 99
Organ, 99
Pulse side, 99
Son of, 99
Yang, 99
SODIUM, **305**
SOLAR PLEXUS, **51**
SOLEUS, **49, 71, 224-225**
Action, 224
Anatomical drawing, 225
Associated muscles, 224
Connecting point, 225
Cranial stress center, 224
Exercise, 224
Holding points, Acu-therapy (Photo), 225
Insertion, 224
Internal manifestations, 224
Lab tests, 224
Meridian, 71, 224
Muscle tests (Photos), 224
Nerve supply, 224
Neurolymphatic receptors, 224
Nutrition, 24, 224
Origin, 224
Palpation, 224
Posture, effect on, 7
Structural weakness, 224
SOLID ORGANS, **76**
SOMA, **51**
SOTO-HALL TEST, **255**
SOURCE POINTS, **85**
SPASM, **254, 260**
SPECIFIC CEREBRAL FUNCTION
Cortical motor integrations, 275
Cortical sensory interpretation, 275
Language, 275
SPHENOID, **32**
Movement in respiration, 10
SPHENOID BONE, **11, 62**
SPERM COUNT, **118, 120, 122, 140, 142, 144, 186, 320**
SPHEROCYTE, **298**
SPINAL, **13**
SPINAL ANKYLOSIS, **254**
SPINAL CORD, **29, 283-285**
Gray commissure, 284
Gray matter, 284
Horns (anterior), 284
Horns (lateral), 284
Horns (posterior), 284
Lesions, 284-285
Tracks of, 283
White columns (anterior), 284
White columns (lateral), 283

White columns (posterior), 283
White matter, 283
SPINAL FIXATION, **54, 56**
SPINAL FLUID, **11**
SPINAL NERVE ROOT IRRITATION, **256**
SPINDLE CELL MECHANISM, **9, 29, 386**
In intervertebral foramen, 9 (See also golgi tendon apparatus and spindle cell mechanism)
SPINOUS PERCUSSION TEST, **258**
SPINOUS PROCESS HYPERSENSITIVITY, **389**
SPLEEN, **71**
Extract, 24
Nutrition, 24
Trapezius, 244-247
SPLEEN MERIDIAN, **100**
Alarm point, 110
Associated muscles, 100
Associated point, 100
Coupled meridian, 100
Dominates, 100
Element, 100
Emotion, 100
Energy flow, 100
Figure of, 70
Meridian connector, 100
Mother of, 100
Number of points on meridian, 100
Organ, 100
Pulse side, 100
Son of, 100
Yin, 100
SPLENIUS CAPITIS, **60**
Nutrition, 24
Posture, effects on, 5, 6
SPONDYLOLISTHESIS, **110, 114, 116**
SPUTUM, **134**
SPUTUM CULTURE, **132**
SPUTUM EOSINOPHIL COUNT, **116**
"S" SCOLIOSIS, **252**
STANDING SIGN OF FOUR, **253**
STERNOCLEIDOMASTOID, **279**
STERNUM, **255**
STOMACH, **71**
Aches, 110
Biceps brachii, 128, 129
Brachioradialis, 130, 131
Carcinoma, 321
Disorders, 128
Levator scapulae, 162, 163
Pains, 112, 116
STOMACH MERIDIAN, **101**
Alarm point, 101
Associated muscles, 101
Associated point, 101
Coupled meridian, 101
Dominates, 101
Element, 101
Emotion, 101
Energy flow, 101
Figure of, 70
Meridian connector, 101
Mother of, 101
Number of points on meridian, 101
Organ, 191
Pulse side, 101
Son of, 101
Yang, 101
STOOL CULTURE, **110, 112, 116, 317**
STOOL EXAMINATION, **148**
STRAIGHT LEG SITTING, **254**
STREPTOCOCCUS INFECTIONS, **313**
STREPTOCOCCUS VIRIDANS, **322**
STRESS, **29, 296**
STRESS FACTORS IN NECK AND BACK PAIN, **385**
Diagnosis: lower back, 385
Diagnosis: neck
Treatment, 385
STRETCH INJURIES
Origin-insertion technique and, 28
Spindle cell mechanism and, 29
STRUCTURAL EXERCISES, **345-355**
Ankle, 352
Chest expansion, 355
Elbow, 352
Finger, 354
Goals of, 345
Hernia, 354
Hip, 351
Knee, 352
Low back, 346-349
Lung, 355
Neck, 350
Shoulder, 351
Varicose veins, 353
Wrist, 354
STRUCTURAL FAULTS, **13**
STRUCTURAL PROBLEMS (RECURRENT), **381**
SUBACUTE BACTERIAL ENDOCARDITIS, **322**
SUBARACHNOID SPACE, **10**
SUBCLAVIAN ARTERY COMPRESSION, **260**
SUBCLAVIUS, **226-227**
Action, 226
Anatomical drawing, 227
Associated muscles, 226
Exercise, 226
Insertion, 226
Internal weakness, 226
Lab tests, 226
Meridian, 226
Nerve supply, 226
Neurolymphatic receptors, 226
Nutrition, 226
Origin, 226
Palpation, 226
Structural weakness, 226
SUBDUE CYCLE, **74**
SUBJUGATE CYCLE, **74**
SUBLUXATED ILIUM, **196**
SUBLUXATION, **14, 52, 78, 90, 280**
Acute, 258
SUBSCAPULARIS, **4, 15, 16, 21, 48, 71, 228, 229**
Action, 228
Anatomical drawing, 229
Associated muscles, 228
Connecting point, 229
Cranial stress center, 228
Exercise, 228
Holding points, Acu-therapy (Photo), 229
Insertion, 228
Internal weakness, 228
Lab tests, 228
Meridian, 71, 228
Muscle test (Photos), 228
Nerve supply, 228
Neurolymphatic receptors, 20, 21, 228
Neurovascular receptors, 16, 17, 228
Nutrition, 24, 228
Origin, 228
Palpation, 228
Posture, effect on, 4
Structural weakness, 228
T.S. line location, 15
SULFONAMIDES, **316**
SUPRASPINATUS, **16, 21, 48, 134, 230, 231**
Action, 230
Anatomical drawing, 231
Associated muscles, 230
Cranial stress center, 230
Exercise, 230
Insertion, 230
Internal manifestations, 230
Lab tests, 230
Meridian, 230
Muscle test (Photo), 230
Nerve supply, 230
Neurolymphatic receptors, 20, 21, 230
Neurovascular receptors, 16, 17
Nutrition, 24, 230
Origin, 230
Palpation, 230
Posture, effect on, 7
Structural weakness, 230
SWALLOWING (DIFFICULTY), **228**
SWITCHING, **29**
K-27 and umbilical contact treatment, 8
SYPHILIS, **296, 313, 320**

## T

T-3, **118, 122, 126, 138, 140, 156, 158, 220, 224, 228**
T-4, **118, 122, 126, 138, 140, 156, 158, 220, 224**
TACHYCARDIA, **279**
TARGET CELLS, **298**
TARSAL-TUNNEL SYNDROME, **337**
Correction, 337
Symptoms of, 337
TEETH, **32**
TEMPORAL BONE, **11, 62, 170, 172, 174**
TEMPORAL BULGE, **63**
TEMPORALIS, **71, 232-233**
Action, 232
Anatomical drawing, 233
Associated muscles, 232
Connecting points, 233
Exercise, 232
Holding points, Acu-therapy (Photo), 233
Insertion, 232
Internal manifestations, 232
Lab tests, 232
Meridian, 71, 232, 233
Muscle test (Photo), 232
Nerve supply, 232
Neurolymphatic receptors, 232, 233
Nutrition, 232
Origin, 232
Palpation, 232
Structural weakness, 232
TEMPORAL-SPHENOIDAL LINE, **14, 64, 384**
TEMPORAL SQUAMA, **381**

TEMPORAL TAP, **383**
TEMPORALIS MUSCLE, **382**
TEMPOROMANDIBULAR DISTURBANCES, **386**
TEMPOROMANDIBULAR JOINT DISTURBANCES, **381**
TENNIS ELBOW, **255**
TENSOR FASCIA LATA, **3, 7, 15, 16, 21, 49, 71, 234-235, 259**
Action, 234
Anatomical drawing, 235
Associated muscles, 234
Connecting points, 235
Cranial stress center, 234
Exercise, 234
Holding points, Acu-therapy (Photo), 235
Insertion, 234
Internal manifestations, 234
Lab tests, 234
Meridian, 71, 234
Muscle test (Photo), 234
Nerve supply, 234
Neurolymphatic receptors, 234
Neurovascular receptors, 16, 17, 20, 21, 234
Nutrition, 24, 234
Origin, 234
Palpation, 234
Posture, effect on, 3, 7
Structural weakness, 234
T.S. line location, 15
TERES MAJOR, **48, 128, 130, 236-237**
Action, 236
Anatomical drawing, 237
Associated muscles, 236
Cranial stress center, 236
Exercise, 236
Insertion, 236
Internal manifestation, 236
Lab tests, 236
Muscle test (Photo), 236
Nerve supply, 236
Neurolymphatic receptors, 236, 237
Neurovascular receptors, 236
Nutrition, 24, 236
Origin, 236
Palpation, 236
Posture, effect on, 7
Structural weakness, 236
TERES MINOR, **4, 7, 16, 21, 22, 48, 71, 238, 239**
Action, 238
Anatomical drawing, 239
Associated muscles, 238
Connecting point, 239
Cranial stress center, 238
Exercise, 238
Holding points, Acu-therapy (Photo), 239
Insertion, 238
Internal manifestations, 238
Lab tests, 238
Meridian, 71, 238
Muscle test (Photo), 238
Nerve supply, 238
Neurolymphatic receptors, 20, 21, 238, 239
Neurovascular receptors, 16, 17, 238
Nutrition, 24, 238
Origin, 238
Palpation, 238
Posture, effect on, 4, 7
Structural weakness, 238
TESTICULAR TUMORS, **320**
TESTS
Barany's, 279
Cerebellar, 281
Coordination, gait and equilibrium, 281
Finger-to-nose, 281
Flex knee, 325
Holme's rebound phenomenon, 281
Muscle (See specific muscle)
Orthopedic (See orthopedic tests)
Pendulum arm swinging, 283
Quadriceps tonus test, 282
Rinne's, 278
Romberg's sign, 281
Shoulder shaking, 283
Standing sign-of-four, 281
Supination-pronation, 281
Tandem gait, 281
Tibialis associated movement, 282
Toe-to-finger, 281
Weber's, 279
TETANUS, **304, 320**
THERAPY LOCALIZATION, **8, 9, 12, 13, 14, 18, 28, 32, 55**
Alarm points, 81
Cranial faults, 32
Cranial stress centers, 50
Disc lesions, 62
Expiration assist, 34
External frontal bone rotation, 41
Eye defects, 62
Factors which may improve results of, 12
Femoral arthritis, 62
Forced expiration assist, 39
Forced inspiration assist, 38
Golgi tendon apparatus, 29
Glabella fault, 46
Ilium and ischium, 60, 61
In origin-insertion technique, 28
Inspiration assist, 33
Internal frontal bone rotation, 40
Interosseous cranial fault, 47
Intervertebral foramen and, 9
Lambdoidal suture fault, 43
Lumbar fixation, 59
Muscle testing and, 8
Neurolymphatic receptors, 19
Neurovascular receptors, 18
Nutrition, 22
Occipital atlantal counter torque, 44
Ocular lock, 45
One-half breath in assist, 35
One-half breath out assist, 36
Pulses, 79
Sacral wobble fault, 60
Sagittal spread assist, 37
Sedation points, 83
Spinal faults, 54
Spinal fixation, 56
Spindle cell mechanism, 29
T.S. line, 14
Technique, 11, 12
Tonification points, 82
Universal cranial fault, 47
Unusual techniques, 64
Zygomatic cranial fault, 42
THIGHS, **254**
THOMAS' SIGN, **256**
THROMBOCYTES, **321**
THROMBOCYTOPENIA, **300**
THROMBOCYTOSIS, **300**
THYMOL TURBIDITY, **178, 206, 208, 308, 319**
THYROID, **24, 71**
Conditions, 156
Extract, 156
Hyperfunction, 320
Hypofunction, 320
Infraspinatus, 156, 157
Nutrition, 24
Teres Minor, 238, 239
THYROTOXICOSIS, **320**
THYROXINE BY RADIOASSAY (T-4), **314**
TIBIALIS ANTERIOR, **21, 48, 240, 241**
Action, 240
Anatomical drawing, 241
Associated muscles, 240
Connecting points, 241
Cranial stress center, 240
Exercise, 240
Holding points, Acu-therapy (Photo), 241
Insertion, 240
Internal manifestations, 240
Lab tests, 240
Meridian, 71, 240, 241
Muscle test (Photos), 240
Neurolymphatic receptors, 20, 21, 240, 241
Neurovascular receptors, 16, 17
Nerve supply, 240
Nutrition, 23, 240
Origin, 240
Palpation, 240
Posture, effect on, 7
Structural weakness, 240
TIBIALIS POSTERIOR, **242-243**
Action, 242
Anatomical drawing, 243
Associated muscles, 242
Connecting points, 243
Exercise, 242
Holding points, Acu-therapy (Photo), 243
Insertion, 242
Internal manifestations, 242
Lab tests, 242
Meridian, 71, 242, 243
Muscle test (Photos), 242
Nerve supply, 242
Neurolymphatic receptors, 242, 243
Nutrition, 242
Origin, 242
Palpation, 242
Structural weakness, 242
TIC DOULOUREUX, **277**
TINEA, **320**
TINNITUS, **170, 172, 174, 192, 194**
T.M.J. DISTURBANCES, **381**
TOES, **253**
TOE-TO-MOUTH TEST, **252**
TORQUE, **13**
TORTICOLLIS, **279**
TOTAL AND FRACTIONATED ESTROGENS, **120, 122, 140, 315**
TOXEMIAS, **296, 308**
TOXICOLOGY, **316**
Barbiturates test, 316

Bromides
Fluoride, 316
Salicylates, 316
Sulfonamides, 316
TRACTS
Burdach, 283
Corticospinal, 283
Goll, 283
Lateral pyramidal (See tracts, corticospinal)
Spinocerebellar, 283
Spinothalamic, 283
TRANSFERENCE, **13**
TRANSVERSE ABDOMINIS, **3**
TRAPEZIUS (MIDDLE AND LOWER), **6, 7, 15, 16, 21, 48, 50, 71, 244, 245**
Action, 244
Anatomical drawing, 245
Associated muscles, 244
Connecting point, 245
Cranial stress center, 244
Exercise, 244
Holding points, Acu-therapy (Photo), 243
Insertion, 244
Internal manifestations, 244
Lab tests, 244
Meridian, 71, 244, 245
Muscle test (Photos), 244
Nerve supply, 244
Neurolymphatic receptors, 20, 21, 244, 245
Neurovascular receptors, 16, 17, 244
Normal tonicity, 2
Nutrition, 24, 244
Origin, 244
Palpation, 244
Posture, effect on, 4
Structural weakness, 244
T.S. line location, 15
TRAPEZIUS (UPPER), **4, 16, 21, 71, 246-247**
Action, 246
Anatomical drawing, 247
Associated muscles, 246
Connecting points, 247
Cranial stress center, 246
Exercise, 246
Holding points, Acu-therapy (Photo), 247
Insertion, 246
Internal manifestations, 246
Lab tests, 246
Meridian, 71, 246, 247
Muscle test (Photo), 246
Nerve supply, 246
Neurolymphatic receptors, 20, 21, 246, 247
Neurovascular receptors, 16, 17, 246
Normal tonicity, 2
Nutrition, 246
Origin, 246
Palpation, 246
Posture, effect on, 4, 7
Structural weakness, 246
TREMORS, **280**
TRENDELENBURG'S TEST, **253**
TRICEPS, **49**
TRICEPS BRACHII, **71, 248-249**
Action, 248
Anatomical drawing, 247
Associated muscles, 248
Connecting points, 249
Cranial stress center, 248
Exercise, 248
Holding points, Acu-therapy (Photo), 248
Insertion, 248
Internal manifestations, 248
Lab tests, 248
Meridian, 71, 247, 248
Muscle test (Photo), 248
Nerve supply, 248
Neurolymphatic receptors, 248, 249
Nutrition, 248
Origin, 248
Palpation, 248
Structural weakness, 248
TRIFACIAL NEURALGIA, **277**
TRIGGER AREAS, **1**
TRIGLYCERIDES, **312, 318**
TRI-IODOTHYRONINE (T-3), **314**
TRIPLE WARMER MERIDIAN, **102**
Alarm point, 102
Associated muscles, 102
Associated point, 102
Coupled meridian, 102
Dominates, 102
Element, 102
Emotion, 102
Energy flow, 102
Figure of, 69
Meridian connector, 102
Mother of, 102
Number of points on meridian, 102
Organ, 102
Pulse side, 102
Son of, 102
Yang, 102
TSANG, **76**
T.S. LINE, **384**
TUBERCULOSIS, **297**
TUMORS, **253**
Adrenal, 315
Adrenocortical, 315
Ovarian, 315
Testicular, 315
TUNING FORK, **258**
TWO-HOUR POSTPRANDIAL TEST, **146**

## U

ULCERS, **176**
Duodenal, 320
Gastric, 306
ULNAR ARTERY, **261**
UMBILICAL-COCCYGEAL CONTACT, **383**
UMBILICAL CONTACT, **8**
(See also K-27)
UMBILICUS, **52**
UMN, **283**
UNIVERSAL CRANIAL FAULT, **47**
Challenge, 47
Identifying characteristics, 47
Kinesiological correction, 47
Therapy localization, 47
URETHRA
Nutrition, 23
URETHRITIS, **303, 321**
URIC ACID, **210, 305, 318, 319, 321, 323**
URINALYSIS, **142, 144, 178, 186, 198, 202, 204, 210, 222, 226, 301, 302, 303**
URINALYSIS — CHEMICAL EXAMINATION, **302**
Acetone, 302
Albumin, 302
Bile, 302
Occult blood, 302
Sugar, 302
URINALYSIS — MICROSCOPIC
URINE ANALYSIS, **303**
Amorphosus sediment, 303
Casts or cylindruria, 303
Chrystals, 303
Epithelial cells, 303
Erythrocytes (RBC), 303
Leukocytes (WBC), 303
Mucus, 303
Unorganized sediment, 303
URINALYSIS — PHYSICAL EXAMINATION, **301**
Color, 301
Quantity, 301
Specific gravity, 301
Transparency, 301
URINE
Acid, 303
Alkaline, 303
URINE ERYTHROCYTES, **122**
UROGENITAL BLEEDING, **301**
UTERINE EXTRACT, **23**
UTERUS, **160**
Gluteus medius, 142, 143
Gluteus minimus, 144, 145
Levator ani, 160, 161
Nutrition, 23
Piriformis, 186, 187
Tipped, 186
URINARY OBSTRUCTION, **309**

## V

VDRL, **313, 320**
VENOUS PRESSURE, **10**
VERTEBRAL COLUMN, **52**
VERTEBRAL FRACTURE, **255**
VERTEBRAL SUBLUXATION, **86**
VERTIGO, **168, 170, 172, 174, 192, 194, 279**
VIRAL HEPATITIS, **319**
VISION PROBLEMS, **170, 172, 174, 192, 194**
VISUAL ACUITY, **276**
VISUAL DISTURBANCES, **381**
VITAL FORCE, **68**
VITAMINS
A, 22, 23, 24, 126, 154
B, 23
$B_6$, 24
$B_{12}$, 24
B-complex, 23
C, 23, 24
D, 24
Deficiencies, 296
E, 22, 23, 24, 112, 116, 154
F, 23, 24, 126
G, 23, 24

VIVAXIS, **343**
VOMER, **32**
VOMITING, **309**
VON GIERKE'S DISEASE, **321**
VORTICES, LOCATION OF, **387**
VORTICES OF ENERGY, **387**

## W

WATER POINT, **85**
WBC, **156, 168, 170, 172, 174, 190, 192, 194, 222**
WEAKNESS, **13, 14**
WEBER'S TEST, **279**
WEIGHT CHANGES, **156**
WELL-LEG-RAISING TEST, **259**
WHEAT GERM OIL, **23, 24**
WHIPLASH, **166, 168, 170, 172, 174, 192, 194**
WIFE YIN, **78**
WOOD POINT, **85**
WRIGHT'S TEST, **261**
WRIST EXTENSION, **268**
WRIST EXTENSORS, **16**
  Neurolymphatic receptors, 20, 21
  Neurovascular receptors, 16, 17
WRIST FLEXION, **268**
WRIST PROBLEMS, **78, 156**
WRIST RADIAL DEVIATION, **269**
WRIST ULNAR DEVIATION, **269**

## Y

YANG, **76**
YANG MERIDIANS, **72, 77**
  Bladder, 72
  Gallbladder, 72
  Large intestine, 72
  Small intestine, 72
  Stomach, 72
  Triple warmer, 72
YANG ORGAN, **80**
YEAST, **24**
YEOMAN'S TEST, **258**
YIN, **75, 76**
YIN AND YANG, **72**
YIN DISEASE, **81**
YIN MERIDIANS, **72**
  Circulation sex
  Heart, 72
  Kidney, 72
  Liver, 72
  Lungs, 72
  Spleen, 72
YIN ORGAN, **80**

## Z

ZINC, **318**
ZYGOMATIC CRANIAL FAULT, **42**
  Challenge, 42
  Identifying characteristics, 42
  Kinesiological correction, 42
  Therapy localization, 42

**STONER**
**CHIROPRACTIC RESEARCH FOUNDATION, INC.**

MINERALS

# INTERPRETATION HINTS FOR CELLULAR TRACE MINERAL ANALYSIS BY HAIR

by, John W. Brimhall, D.C.

## Introduction

The following outline on trace mineral deficiencies, excess, and ratios is to help you understand the important role minerals play in normal physiology and pathology. The statements contained in this outline should not be considered an absolute diagnosis; but, as an indication, tendency, or trend.

This outline was the result of many long hours of research by Dr. John Brimhall and encompassed many books, lectures, magazines, and scientific journals and papers.

Fred Stoner, D.C.

1. Calcium and magnesium high together are a hypoglycemic trend. This is especially true if sodium and potassium are low or in another adrenal stress picture. This seems to be more consistant in women.

2. High Calcium may be indicative of decalcification, osteoporosis, arteriosclerosis, hypercalcemia, poor hormone imbalance and other endocrine imbalances. Always check for excessive intake.

3. Calcium Deficiency has been found in osteoporosis, nervousness, irritability, insomnia, bone pain, headaches, heart palpation, slow pulse rate, rickets, renal malfunction, muscle or menstrual cramps and fever, etc., in teething children.

4. High magnesium has been associated with junk food diets and excessive phosphorus containing food ingestion.

5. Magnesium deficiency has been associated with heart palpations, neuromuscular disorders, cardiovascular, and kidney problems. It has been found in hyperexcitability, hair loss, ulceration, infection, calcification of the kidneys, and hormone imbalance. Symptoms of deficiency may be weakness, cramps, spasms, pallor, confusion, depression, sensitivity to noise and proneness to heart seizure. Many enzymes are dependent on magnesium (80% of the 5,300 systems).

POST OFFICE BOX 15208 • LAS VEGAS, NEVADA 89114 • TELEPHONE (702) 734-2826

6. Calcium/magnesium is approximately 6-8 :1

7. Sodium/potassium is approximately 2.5-5 :1

8. Sodium and potassium low together associate with adrenal stress.

   Sodium and potassium high together associate with adrenal fatigue and insufficiency.

9. Sodium High is found in heart disease, advance liver and kidney diseases, hypertension and high blood pressure. Make sure to check salt ingestion and soft water consumption.

10. Low sodium is associated with vertigo, achlorhydria, vomiting, mental apathy, heat prostation, weakness and respiratory failure.

11. Potassium excess may be associated with kidney malfunction, adrenal exhaustion, dehydration, Addison's disease, diabetic acidosis, and paralysis.

12. Potassium deficiency is associated with water retention, poor muscle motility, poor or stunted growth, poor parastalsis and result in infections and constipation. Nervousness, insomnia, irregular or slow heart beat, proneness to heart seizures and a typical exhaustion pattern may also sometimes be found in deficiencies. Being fearful, having shortness of breath, irrational at times, and geophagia have also been correlated to low potassium.

13. Copper excess has been associated with a choking off of the cell and destruction of vitamin C. It increases the oxidation rate of adrenalin, interfers with magnesium and zinc enzyme systems due to high complex stability. Copper is found mainly in the liver, heart, spleen, kidney, brain, and blood.

14. Copper deficiency is associated with nutritional deficiency, poor elastin formation, anemia, inability to hold an adjustment, poor digestion, demylenation, hair loss, graying of hair and aortic aneurism.

15. High copper and calcium with low zinc and manganese have been said to be found in cancer trends.

16. Low copper, iron, and manganese may all need to be nutritionally supported in anemia.

17. High copper and low zinc is said to be found in many schizophrenics.

18. Zinc excess may be associated with interference with iron and copper, anemia (excess levels of zinc will eventually lead to anemia), anorexia, decreased food consumption and weight loss.

19. Zinc deficiency may be associated with diminished sense of taste, delay in intestinal absorption, loss of fertility, prostate conditions, low resistance to infection, slow healing, interferes with formation of RNA and DNA, arteriosclerosis, vertigo, tendinitis, and anorexia.

20. Iron excess may be associated with liver malfunction or malignancy, hemochromatosis, chronic infections, genetic metabolic errors and pancreatic disorders.

21. Iron deficiency may be associated with anemia, weakness, fatigue, difficult breathing, pale skin, sore tongue or mouth with cracks around the lips, insufficient hydrocholoric acid and pH balance in the digestive system. It may be caused by ulcer, infection, or poor ability to hold a spinal correction.

22. Manganese excess has been considered as a criminal in demyelinazation. ~~takes place~~. B-1 is used to help lower high levels. Apathy and ataxia are common in toxic levels.

23. Manganese deficiency is associated with rheumatoid, arthritis, thyroid malfunciton, hypertension - drug usage, recurring vertebral subluxations, failure to grow, sexual processes, deformation of bones, poor equilibrium, myasthenia gravis, lupus, anemia symptoms, faulty cholesterol metabolism.

24. High zinc with low copper and manganese has been considered a low thyroid profile.

25. Chromium excess is associated with industrial contamination, lung stress, liver and kidney damage.

26. Chromium deficiency has been associated with diabetic like symptoms, atherosclerosis, impaired glucose tolerance, impaired carbohydrate lipid and protein metabolism, and decreased longivity.

27. A typical diabetic type pattern would be a low chromium, high calcium/magnesium ratio and zinc appearing normal or slightly higher.

28. Lithium is thought to play an important role in the personality.

29. Cadmium was called the dragon's teeth by Dr. Schroeder for its poisonous reaction and bizarre effects even small doses can cause. Most recognized potential problem is hypertension. It has the ability to displace zinc in reations, enzymes and on the artery wall. Where cadmium displaces zinc on the artery, there are accumulations of fat and cholesterol. Cadmium, once in the body, concentrates in the kidney, liver, and blood. It is considered more toxic than lead or mercury. Excessive cadmium contributes to heart attack, stroke, and thrombosis. It can cause serious vascular disease, arteriosclerosis, cerebral hemorrage, enlarged heart, hypertension, high blood pressure, possible emphysema and decreased fertility. Sources

of contamination may be zinc smelters and refiners and copper smelters, rubber tires, plastics, pigments, plated ware, alloys, and insecticides are some of the elements containing cadmium. Some foods have a lot of cadium, examples are, oysters, foods contaminated in the processing, some instant coffees and teas, some canned foods, kidneys of pigs given cadmium as a worm killer, gelatin and fish dried on chicken wire, and some cola drinks. We used to get it from dental fillings but we don't any more. Pigments can be a source, for cadmium yellow and cadmium red are fast colors; some French lipsticks have it. A necklace of candy "luv" beads made in Hongkong was colored with cadmium.

30. Lead is highly toxic and more prevelant each year with the breakdown of leaded gas. There are multiple symptoms and side effects. e.g., Delta-amino-leulinic acid dehydratase, which is an enzyme essential to red blood cell formation and is inhabited by lead exposure.

    The gastro-intestional or abdominal symptoms are: constipation, diarrhea, malasise, nausea, abdominal pain, and loss of appetite. The neuromuscular symptoms are: muscle weakness and discomfort, easy fatigue tremors, degeneration of motor neurons and axons, atrophy, and gout. The CNS symptoms are: clumsiness, vertigo, loss of coordination, insomnia, headaches, restlessness, mental retardation and emotional instability.

31. Lead is often found in arthritics due to the increased levels of hyaluronidase it causes. Dr. Schroeder implies that heavy metal toxicity may be a cause factor in cancer and many other debilitating diseases.

32. Selenium can act like vitamin E and prevent multiple sclerosis in poultry, but only minute amounts are needed and it can be toxic in excesses. It is a very strong anti-oxidant, and is essential to growth and may hlep prevent nutritional muscular-dystrophy.

33. Mercury is a toxic metal and is present throughout the biosphere. In humans it is concentrated in the brain, kidneys, liver and lungs. Like lead, it is incorporated in the body via inhalation and the food chain. The symptoms of mercury toxicity are: loss of appetite, loss of weight, tremors, insomnia, shyness, nervousness, dizziness, frequent colds, diarrhea, sore gums, albuminuria, fatigue, headach, impaired concentration and memory, tingling or numbness of fingers and mouth, clumsiness, atoxia, inability to speak clearly, concentric defect of visual fields, and hearing defects.

    Sources of mercury contamination are: coal burning, dental amalgams, ointments, paper, cosmetics, adhesives, organomercurial perticides, felt antiseptics, camera film, floor waxes, canvas, plastics, water based paint, clothing fabric softeners, chemical fertilizers, parmaceuticals, and flourescent lamps.

34. Arsenic occurs in coal and oil. Inspite of its reputation as a poison, it has a low order of toxicity to mammals, and in small doses for life has no detectable biological effects. It is well tolerated, ther are relatively large amounts in seafood, and it is doubtful that arsenic is innately toxic at present levels of exposure. (In fact it promoted longevity in rats.) In man, however, it causes skin lesions which can result in cancer.

    Arsenic has multiple ill effects on the body. It is considered to be the only heavy metal that consistantly can cause cancer when taken continously into the stomach and it causes skin lesions and pigmantation. These may become cancerous and especially on the palms and soles. Its sources of exposure are insecticides, fungicides, weed killers, alloys, medicines and pigments.

35. Nickel is not well researched on a hair analysis. Blood studies show high levels may occur in patients who suffer from a blockage of blook flow to the heart (myocardian infarction), strokes, severe burns and in toxemia of pregnant women. Nickel activates several enzymes and may contribute to stabilization of DNA and RNA. It seems to increase in leukemia patients. It replaces zinc in the formation of insulin and activates several enzyme systems and can overactivate these systems as levels rise.

36. All heavy metals respond somewhat to natural chelation with vitamin C and E, amino acids, apple pectin, EDTA and others. It is more difficult for the body to absorb toxic metals if your good trace elements are adequate. e.g. calcium, zinc, manganese, etc. One must not forget that a remedy becomes a poision if the concentration becomes too great. Metals are two edged swords and balance is the only sheath that brings health.

37. Artheriosclerosis with normals, the calcium/zinc ratio averages 3.8/1. In a large series of patients with severe arteriosclerosis, the average was 4.8/1. Calcium depresses the absorption and activity of zinc. The mechanism is not known but zinc diet supplementation should be a part of every treatment regimen for this condition.

38. Diabeties; The calcium/zinc ratio alteration noted in arteriosclerosis is also seen in diabetics. Zinc may be only slightly elevated, but calcium values (mg, too) are often very high.

    Zinc is essential of normal insulin secretion, tissue sensitivity to insulin, and the normal functioning of adipose tissue. High calcium depresses zinc activity and absorption.

    Manganese is essential in the enzymatic processes in gluconogenesis. Manganese in even moderate amounts may, in diabetics, leat to hypoglycemia. High calcium interferes with the normal activity of manganese. One study showed the calcium/manganese ratio in normals to be 73/1, in diabetics, 226/1. Manganese

levels may be very low. Chromium is a cofactor with insulin. Chromium values in diabetics has been reported to be 30% lower than average nondiabetics. Both sodium and potassium may be very low.

39. Hypertension; Elevation of both cadmium and iron has been linked with hypertension. In the case of iron, this may be but the results of chronic, low grade hemoconcentration secondary to decreased cardiac efficiency, rather than a primary etiologic factor. Copper may be elevated, several pressor peptides require it. Magnesium deficiency has been noted frequently.

40. Nerve Impulse Transmission; Nerve impulse function is impaired when there are low calcium/magnesium and magnesium/manganese ratios, especially with a high sodium/potassium ratio. Low calcium, particularly when in combination with low zinc, leads to decrease in monamine oxidase acitivity, as well as a decrease in the activity of the tyrosine enzymes. These metabolize CNS and peripheral nerve amine toxins.

41. Schizophrenia, in many cases (they are not homogenious) high calcium, copper and iron is seen in both hair and serum. Low sodium, zinc and magnesium is common. High lead, cadmium and mercury, as well as low chromium, is not unusual. High copper directly causes hyperexcitability; it destroys vitamin C and increases the oxidation rate of adrenalin. Due to higher complex stability it interferes with magnesium and zinc enzyme systems. The result of the latter is increased muscle irritablity. A common additional consequence of copper enzyme blockage is increased iron excreation, often while maintaining a relatively normal serum iron level.

42. In our opinion distilled water is the best, but you must take multiple liquid minerals to offset loss of minerals in the body.

## REFERENCES

[1]Pfeiffer, Carl C., Ph.D., M.D., Mental and Elemental Nutrients, Keats Publishing, Inc. 1975.

[2]Schroeder, Henry A., M.D., The Poison Around Us, Indiana University Press, Bloomington, London.

[3]Burch, Robert E., M.D. and Sullivan, James, F., M.D., The Medical Clinics of North America, volume 60, number 4, W.B. Saunders, Co. 1976.

[4]Kupsinel, Roy, M.D., The Crininal Mineral: An Unusual Case History of Manganese Poisoning, Journal of the International Academy of Preventive Medicine, Volume II, number 4, fourth quarter 1975

[5]Ashmead, DeWayne, Ph.D., The Relationship of Minerals to to Health and Disease, Bestways, April 1977 page 12

[6]Literature Survey of Selected Articles On Hair Analysis, Mineral Lab, Inc., Volume II, May 1976

[7]Literature Survey of Selected Articles on Hair Analysis, Mineral Lab, Inc., Volume I, January 1975

[8]Biological Laboratories, Minerals Toxic Metals Hair Analysis, Detoxification, Toxic Sources, Toxic Systems, Summary - Review

Doctor,

The following 12 reports are schematics of actual hair anlaysis reports. The mineral percentage and ratios have been purposely omitted so that you can begin learning the mineral trends and avoid confusion. The astric (*) represents the mineral level, based upon the low - normal - and high visual chart. In the upper right hand corner of the page, please indicate the correct disease trend.

The disease trends can be found in Dr. Brimhall's outline on "Interpretation Hints for Cellular Trace Mineral Analysis by Hair," which you have just reviewed, and in the booklet, "The Trace Minerals and Hair Analysis."

Please return these with your other homework by the deadline.

# MYOLOGICAL SYSTEM
# OR
# MUSCLES THAT MAKE UP THE BODY

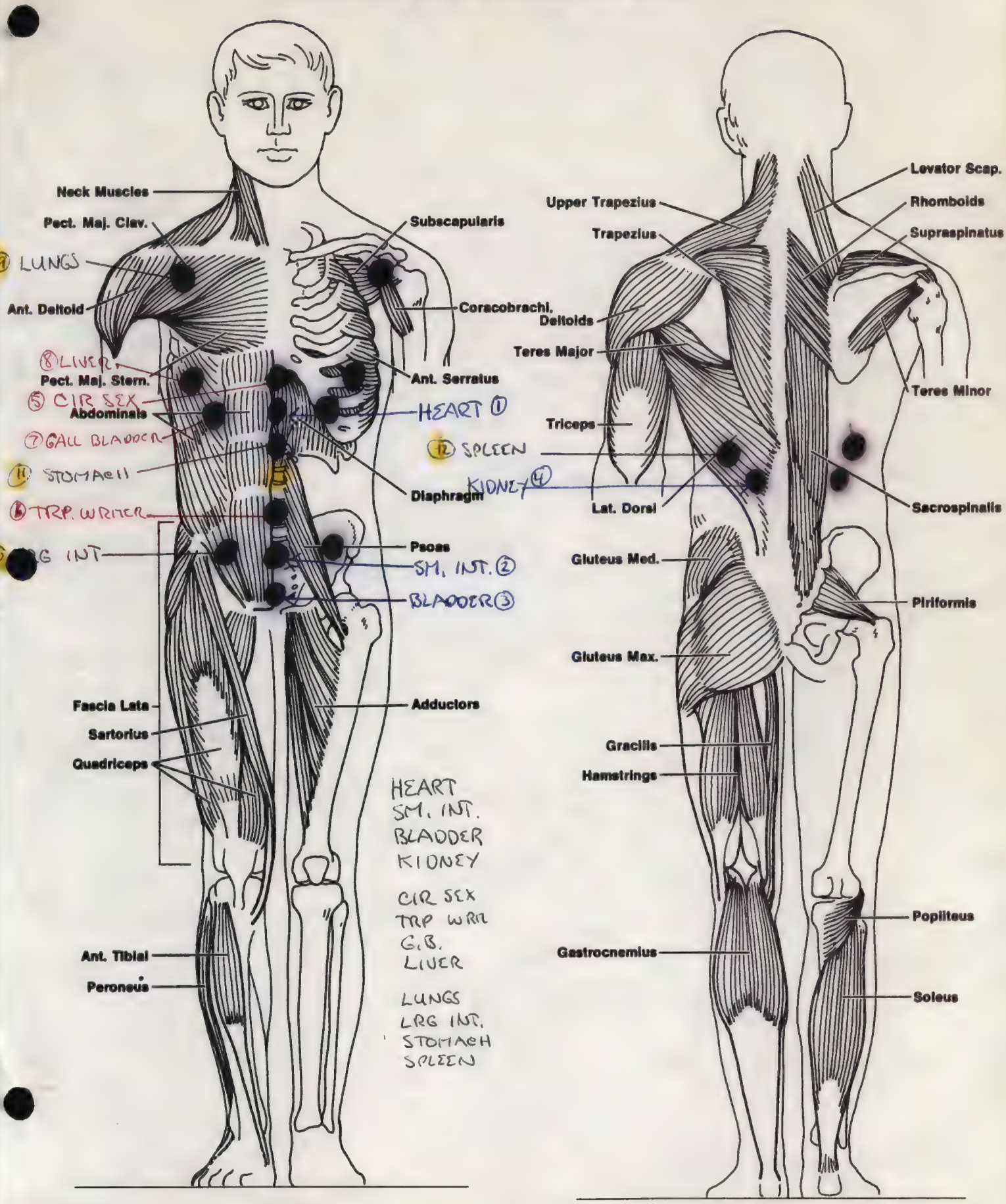




Reprinted from Touch for Health by John Thie D.C.

# PICTORIAL EXAM FORM

[To be used in conjunction with forms 1 and 5]

NAME _____ DATE _____

## EXAM POSITION I

Bladder Blader — Adrenals triple warmer — Pancreas Spleen — Brain Cerebrum — Pancreas Spleen — Stomach — Stomach Stomach



Lungs — Thyroid — Heart — Lungs — Stomach — Lungs — Eyes & ears

Lung — Triple Warmer — Heart — Lung — Stomach — Lung — Kidney

## EXAM POSITION II

Stomach — Liver — Sinus — Kidneys — Adrenals — Gall Bladder — Bladder — Bladder — Sm. Intestine

Stomach — Liver — Kidney — Gall Bladder — Small Intestine — Bladder — Small Intestine

## EXAM POSITION III

Sinuses — Thyroid — Spleen — L. Intestine — L. Intestine — Adrenals — Sex — Sex — Adrenals

Stomach — triple warmer — Spleen — Triple warmer — Circulation sex — circulation sex — triple warmer

## EXAM POSITION IV




Sex — L. Intestine — Sex — Liver

Circulation sex — L Intestine — Circulation sex — Liver

© S.C.R.F. • FORM 9

# CRANIAL FAULTS

[To be used in conjunction with Forms 1 and 5]

P. 44

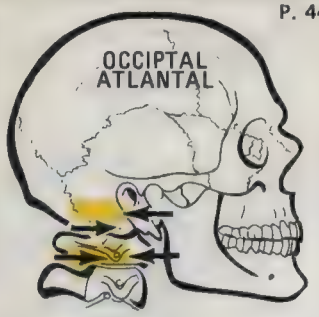


P. 43

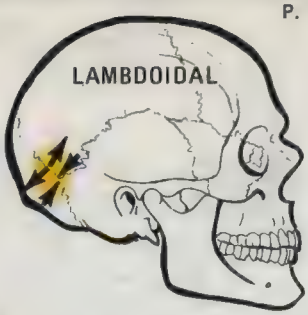


P. 47

### UNIVERSAL FAULT

Have patient take a deep breath with mouth closed while occluding one nostril. A strong indicator muscle will become weak if a universal fault is present. Repeat on opposite side.

P. 45

### OCULAR LOCK

Have patient forcefully look in all directions without turning head. If ocular lock is present, a strong indicator muscle will become weak while the eyes are fixed in that direction.

P. 42

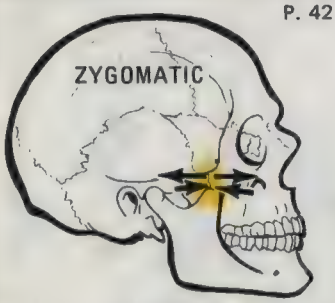


ILIO CECAL

P. 37

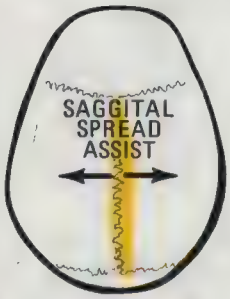


P. 40

P. 46

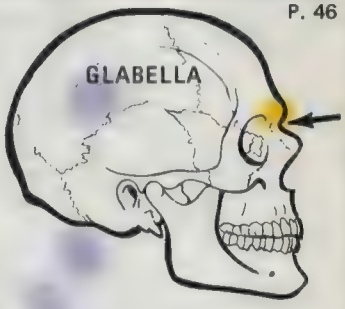


P. 35

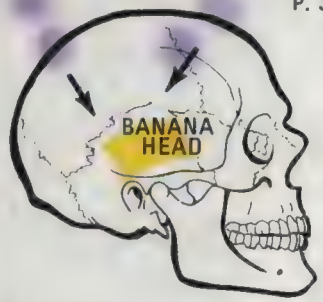


P. 63

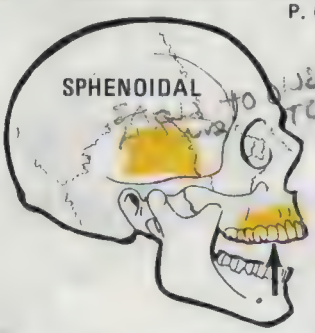


P. 41

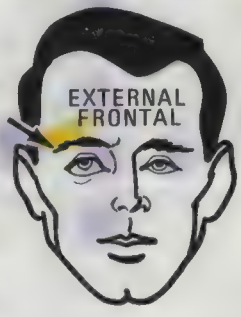


## ALARM POINTS

P. 81

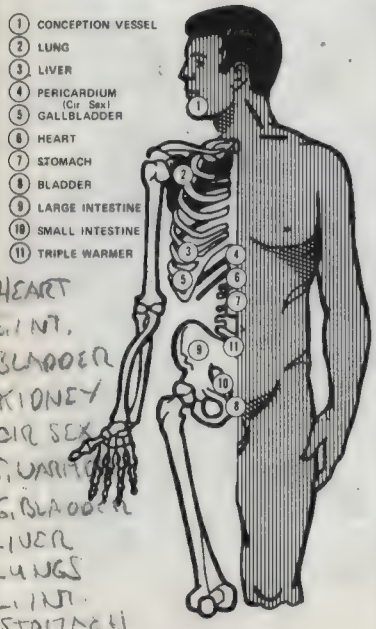


1 HEART
2 L. INT.
3 BLADDER
4 KIDNEY
5 CIR SEX
6 T. WARMER
7 G. BLADDER
8 LIVER
9 LUNGS
10 L. INT.
11 STOMACH
12 SPLEEN

P. 81

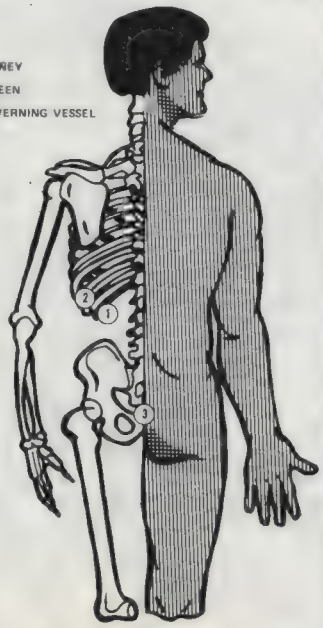


| DESCRIPTION OF RESPIRATION | RESPIRATORY CORRECTION |
|---|---|
| 1. Ask the patient to take a deep breath and hold it. | Inspiration Assist P. 33 |
| 2. Ask the patient to force more air into his lungs and hold it. FAILS TO LOCK INSP → ↓ BLOWS THUMBS TO ROOF OF MOUTH | Forced Expiration Challenge INSP P. 38 |
| 3. Ask the patient to let one-half breath out and hold it. BUT IN ON INSPIRATION | Half Breath Out Assist P. 36 |
| 4. Ask the patient to let out all the air and hold it. | Expiration Assist P. 34 |
| 5. Ask the patient to force out all the air in his lungs and hold it. FAILS TO LOCK EXP → ↓ BLOWS | Forced Expiration Challenge P. 39 |
| 6. Ask the patient to take one-half breath in and hold it. BANANA HEAD TIL. TEMPORALS | Half Breath In Assist P. 35 |

TIL. TEMPORALS ↑↓

© S.C.R.F. • FORM 9

Van Rossum

STONER
CHIROPRACTIC RESEARCH FOUNDATION, INC.

# A SYNOPSIS OF FIXATION ESSENTIALS

G. T. Syversen, B.A., D.C.

## SPINAL FIXATIONS

### SUBLUXATIONS:

1. A single vertebra is involved in misalignment causing neuroligical aberrations.
2. Are usually apparent on x-rays as misalignments.
3. They cause a strong indicator muscle to go weak on T-L and vertebral challenge.
4. Recurrent subluxations are frequently caused by by non-palpable micro-fixations or fixations.

### FIXATIONS:

1. Can be identified by T-L by introducing motion into the joint while the patient holds both hands over the joint, and they can also be challenged.
2. If a muscular locking occurs to multiple vertebrae, it frequently results in bilateral muscular weakness.
3. Occur usually in three's due to the rotatore brevis and longus muscles.
4. Are usually apparent on x-rays with cineroentgenography or multiple exposures taken in flexion, extension or rotation.

### SUBCLINICAL SPINAL MICROFIXATIONS:

1. Do not result in bilateral muscle weaknesses, but are evidenced by a fixation usually of only one anterior and one posterior facet.
2. The primary respiratory motion is lost in microfixation
3. A fixation causes loss of the normal orthopedic motion range in addition to the respiratory motion.

### LOCATING A FIXATION:

1. Press against the spinouses of two vertebrae in opposite directions simultaneously.
2. Are also found easily through muscle patterns;

P252 LEWINS SIGN

POST OFFICE BOX 15208 • LAS VEGAS, NEVADA 89114 • TELEPHONE (702) 734-2826

a. OCCIPITAL.....bilaterally weak psoas
b. UPPER CERVICAL.....bilaterally weak gluteus maximus
c. LOWER CERVICAL.....bilaterally weak popliteus
d. CERV-DORSAL JUNCTION.....bilaterally weak deltoids (rarely--anterior serratus)
e. DORSAL (THORACIC)..bilaterally weak T. Major
f. DORSAL-LUMBAR JUNCTION...bilaterally weak lower trapezius
g. LUMBAR.....bilaterally weak neck extensors (when tested together)
h. SACRAL.....bilaterally weak neck extensors (when tested individually)
i. ILIAC.....one neck extensor weak (if there is a respiratory fault, the piriformis will be weak on the side of the iliac fixation)

PRESENCE OF A FIXATION:

Spinous moves easily in one direction and not the other. (The spinous moves easily toward the side of excessive muscular tension and away from the side of muscle weakness. It moves easier into the lesion than out of it).

KEYS TO SUCCESSFUL CORRECTION:

1. Is to determine which vertebra should be adjusted on the (middle) vertebra.
2. Push the spinous of the top vertebra first to the right and then to the left, it will move more easily into the lesion. If the spinous moves easier to the left than to the right, this can be called a right posterior transverse.
3. Next, press on the relative posterior facet and the anterior facet line. Judge which side gives the most resistance.
4. If the posterior transverse side gives more resistance, it is termed a posterior fixation and vice versa.
5. In a posterior fixation, the top vertebra is adjusted on the center vertebra.
6. In an anterior fixation, the bottom vertebra is adjusted on the center vertebra.

FIXATION CORRECTION

1. Adjust either the top or bottom vertebra on the center vertebra, it is always in the direction of resistance and AFTER the muscles involved have been corrected.
2. Use a transverse contact and with the opposite hand stabilize the center vertebra with a quick adjustive thrust to the **transverse** contact followed by a quick adjustment to the center vertebra.

3. Common NLR for the rotatore brevis and longus is just below or underneath K-27. Activate this before correcting any fixations.
4. Origin and insertion technique should be applied to one or both of the weak muscles on the weak side.
5. After successful strengthening of the bilateral muscle weaknesses and after the correction of a fixation, test in the weight bearing position and see if the fixation pattern returns.

WEIGHT BEARING POSITION

1. FOR CERVICALS AND THORACICS.....The deltoids and neck extensors are easily tested while the patient is standing.
2. FOR SACRUM AND PELVIS.....The hands and knee position.
3. FOR LUMBAR SPINE.....Patient presses toes against the foot rest of the hi-10, or an assistant can press cephalad against the feet.
4. If the fixation returns upon weight bearing, this is an indicator for octacosanol, which is found abundantly in wheat germ oil. It is an anti-gravity factor.
5. Upon chewing and ingestion, there is an immediate removal of the gravity fixation without additional correction.

FIXATION SYMPTOM CORRELATION:

C1-C3.....respiratory problems, arthritic problems.
C4-T2.....hypertension, abdominal ptosis.
T3-T5.....coronary disease, cholesterol involvement.
DOR-LUMBAR....diaphragm involvement.— HIATEL HERNIA
LUMBAR.....low back problems.

OCCIPITAL FIXATION:
(Bilateral Psoas)

SYMPTOMS

1. Recurring headaches
2. Difficult cervical flexion or extension.
3. Dizziness when looking up or down,
4. Recurrent cervical strain.
5. Back pain when getting up from a seated position.

CLINICAL OBSERVATION:

1. STANDING POSITION.....high occiput.
2. PRONE POSITION.....one leg appears short and the same leg appears long in the supine position. This is the absence of any pelvic problem or actual anatomical deficiencies.

THERAPY-LOCALIZATION:

SUPINE POSITION.....patient places the hands at the base of the occiput and turns the head from side to side or up and down.

CHALLENGE:

a. 1. Place the fist along the cervical transverses.
   2. With the opposite hand press the occiput straight lateralward toward the stabilized cervicals.
   3. Retest the indicator muscle.
   4. If it weakens, it indicates an occiputal fixation on the side challenged.

b. 1. Ask the patient to stick the tongue straight out.
   2. Test the indicator muscle.
   3. Then point the tongue right and then left.
   4. Test the indicator muscle each time.
   5. Adjust the occiput on the side which the pointed tongue produces muscle weakness.

TREATMENT:

a. 1. In the case of a HIGH OCCIPUT in the vertical position, correct the NLR or NVR of the sternocleidomastoideus, PMC and the anterior scalenus.
   2. Following this, if the occiput is still high, check the psoas.
   3. Bilateral psoas weakness and a high occiput after correction, indicates the occipital fixation is still there.

b. 1. Patient is supine
   2. There is usually a very sensitive area on palpation at the base of the high occiput.
   3. Make a metacarpal contact on the high occiput side; the other hand contacts the general occiput area over the low side.
   4. Exert a small traction on the cervical spine.
   5. The head should not be turned.
   6. The thrust is given straight lateralward over the sensitive area on the high occiput side. (May or may not be audible)
   7. Retest the indicator muscle and check the occiput level standing.
   8. Retest by T-L the occiput.

<u>ATLAS-AXIS-C3 FIXATION:</u>

CORRECTION:

1. Patient is either prone or supine.
2. Contact the right posterior portion of the atlas transverse with one hand and left anterior portion of the transverse with the other.
3. Try to rotate the atlas from left to right and from right to left.
4. Note the side that feels fixed.
5. If it moves freely from each side, no fixation is present.
6. The same for the Axis and C3.
7. Contact on C3 should be near the facet line and the other hand counterresisting on C2.

LOWER CERVICAL FIXATION: (Bilateral Popliteus)

Same as the upper cervicals.

SACRUM FIXATION:

1. Press right and left on the spines of the sacrum.
2. If the sacral spine moves more easily left, it is predisposed more to the left anteriority and right posteriority.
3. It is corrected on the side which shows the greatest amount of resistance to anteriorward testing pressure directed just medial to the posterior-superior iliac spine.
4. If resistance is found on the posterior side, adjust the sacrum straight down toward the table in line with the sacroiliac articular plane.
5. If found on the anterior side, place in the sidelying position with the anterior position up. Hold the posterior side (closest to the table) with the treating hand while the patient's trunk is torqued with the superior shoulder moving posterior and the patient's upper leg and pelvis being stabilized in such a manner to release the anterior sacral fixation.
6. After releasing the sacral fixation, retest the posterior neck extensors right and left individually to determine correction.

ILIUM FIXATION:

On inspiration the ASIS moves lateral and the posterior iliac spine moves medially.

ILIUM FIXATION IN ONE OF THREE POSITIONS.

1. INSPIRATIONAL FIXATION.....a respiratory fixation.
2. EXPIRATIONAL FIXATION.....a respiratory fixation.
3. FIXATION.....a simple fixation where the ilium is in place, but does not move in it's normal respiratory range.

SIGNS:

1. UNILATERAL SPLENIUS CAPITIS WEAKNESS.....Found on examination or after the splenius capitis had been balanced, challenge to the ilium will cause the splenius capitis to become unilaterally weak.
2. PIRIFORMIS WEAKNESS.....If the piriformis is weak, ask the patient to inhale, and if a fixation is present, the inhalation will result in momentary strength to the piriformis and splenius capitis.

CORRECTION:

1. If the piriformis strengthens on INSPIRATION, this indicates the ilium is fixed in the EXPIRATIONAL respiratory phase of movement.
2. Conversely, if the piriformis strengthens on EXPIRATION, it indicates the ilium is fixed in the INSPIRATIONAL phase of movement.
3. Correction is made on the proper phase of respiration and in the ilium's plane of motion (direction in which the challenge was successful).

UPPER DORSAL RIB FIXATION:

Because of the involvement of the levator costalis muscles, ribs can also become fixed. Frequently the first three ribs are fixed.

1. Locate each pair of ribs.
2. Examine the first two ribs for fixation by pressing downward on the first rib on the left and at the same time pressing upward on the first rib on the right.
3. Then reverse the process.
   NOTE: If fixed, those on one side will show greater movement than those on the other.
4. After locating the fixed ribs, proceed to the junction of the rib and transverse.
5. Press on the junction of the rib and transverse, using basically a P-A direction (one can feel a rather free motion on one side and a restriction on the opposite side, indicating a fixation).
6. If the posterior side is fixed, adjust rib one, for example, on the right, towards rib two on the left.
7. However, if it is the anterior side that is fixed, adjust rib three on the left towards rib two on the right, or vice versa.

ANTERIOR DORSAL LEVATOR TECHNIQUE:

Can cause chest pain, upper gastric intestinal distress and upper back and neck pain. Caused by trauma or reflex activity.

LOCATE:

1. By pressing upward against the spinous process of the vertebra in question. It will be sensitive to pressure.
2. Levator costalis brevis originates from the vertebral transverse and inserts into the rib below.
3. Levator costalis longus originates from the vertebral transverse and insert into the costal angle two ribs below its origin.
4. Locate the anterior dorsals through T-L or palpation.
5. The levator costalis brevis muscle over the rib immediately below should be pressed in a medial-anterior direction.
6. Or the levator costalis longus over the second rib immediately below should be pressed in the same direction.
7. Retest a strong indicator muscle.
8. If the indicator muscle is weak, find the phase of respiration that strengthens it.
9. Repeat correction of the muscle in the direction that produced weakness on the phase of respiration that strengthened the indicator muscle.
10. Repeat this procedure on 4-5 respirations.
11. Then palpate the anterior dorsals or retest the indicator muscle to verify correction.
12. May be necessary to repeat this procedure twice.
13. If the anterior vertebra persists, correct if through any one of the standard anterior dorsal techniques and utilize the before mentioned technique on the levator costalis muscle.

# POSTURAL ANALYSIS

G. T. Syversen BA, DC

DISCUSSION:

Postural analysis is one of the three major methods of getting kinesiological information along with the TS line and therapy-localization.

By using these three sources, time can be saved and major areas can be pinpointed.

Many patients have problems involving apparent muscle spasms, such as iliopsoas, trapezius, etc.

However, when patients are examined for obvious muscle spasm, an amazing fact is learned.

Through bilateral muscle testing, it has been found that an overshelming majority of the patients have muscle weakness rather than primary muscle spasm, and it is this weakness which causes the opposing or contralateral muscle to contract. Therefore, the contracted muscle is a secondary effect of the primary muscle weakness.

Also a reciprocal relationship exists between muscles, i.e., when the biceps contracts, the triceps normally relaxes. However, an abnormal reciprocal relationship can also occur between muscles with a detrimental effect.

We have learned that the body has a language and this language is an interpretation of the hyperotnic and hypotonic muslces.

Body language does not lie, and through this language, the body tries to communicate it's problematic state.

When observing posture, your thoughts should be toward the structural deviation as a result of weakness of a muscle or muscles.

Often a compensating muscle pull or weakness, such as the elevation of theshoulder by a weak latissimus dorsi, may be cancelled by a weak upper trapezius on the same side.

Correlation of all three diagnostic factors of A-K will find the hidden weaknesses.

We should think in terms of what the muscle does and then what the posture looks like if the muscles become weak on one side and with a compensatory hypertonus on the other.

EXAMPLES:

If the latissimus dorsi becomes weak on the right, the attachment of the trapezius on the right pulls the shoulder up. Therefore, the uninvolved trapezius-latissimus dorsi complex on the opposite side (left) may go into a compensatory hypertonus.

Also depending on the relative strength of the uninvolved or left upper trapezius-latissimus dorsi complex, the shoulder usually goes down on the left side, adding to the tilt of the shoulder girdle

If the right upper trapezius becomes weak, the left upper trapezius goes into compensatory hypertonus elevating the left shoulder and depressing the left occiput, producing the elevation of the right occiput and the descent of the right shoulder under the normal pull, of the right latissimus dorsi giving the classic upper trapezius pattern.

If the gluteus medius weakens on the right side for example, the right ilium elevates, the right shoulder elevates, the right occiput elevates and the patient walks with a gait reminiscent of going downstairs on one side.

As the gait continues, the loss of tone allows the ilium to rise, which then causes the body to compensate by over swinging to the right and it looks as if the patient is going downstairs on the right, while moving at a normal pace on the left. This produces the characteristic gluteus medius gait.

If the gluteus medius on the right side is weak and the left gluteus medius is very strong, it will push or shove the pelvis to the right.

At the same timethere will be a compensatory movement of the upper thoracic to the left.

This produces the classic situation where the patient going through a narrow doorway will touch the doorway on the right with his hip and his left shoulder will touch the left side of the door as he goes through.

Weakness of the sternocleidomastoideus on the left, causes the occiput to rise on the left and depress on the right.

This may be complicated by the interactions of the upper trapezius, actual subluxations of the upper cervicals and occiput producing unversal structural problems.

In as much as the body does not lie, the subluxations can be identified by challenging and the muscles by simple muscle testing.

With quadratus lumborum problems it deviates to one side or the other with arelatively level pelvic pattern.

Other examples are found in the "ECLECTIC APPROACH TO CHIROPRACTIC" Pages 2-7.

| POSTURE DEVIATION | POSSIBLE MUSCLE WEAKNESS |
|---|---|
| HEAD NOT LEVEL | Neck muscles, rhomboids, sacrospinalis, psoas, gluteus medius & upper trapezius. |
| SHOULDERS NOT LEVEL | Latissimus dorsi, neck muscles, gluteus medius, upper trapezius, deltoids. |
| HIPS NOT LEVEL | Psoas, adductors, gluteus medius. |
| HEAD LEVEL BUT TWISTED OR ROTATED | Rhomboids, abdominals, trapezius, sacrospinalis. |
| SHOULDERS TWISTED OR ROTATED | Levator scapulae, latissimus dorsi, |
| SHOULDERS DEPRESSED (Scapula spread) | Upper, middle & lower trapezius, rhomboids and levator scapulae. |
| PELVIS TWISTED OR ROTATED | Psoas, TFL, sartorius, abdominals. |
| ANTERIOR PELVIC TILT | Gluteus maximus, hamstrings, abdominals, TFL, tight psoas, lower sacrospinalis. |
| POSTERIOR PELVIC TILT | Sartorius, psoas, TFL, lower sacrospinalis, rectus femoris. |

| | |
|---|---|
| HANDS: ROTATED MEDIAL (Palm posterior) | Teres minor, infraspinatus. |
| ROTATED LATERAL (Palm anterior) | Subscapularis. |
| HELD AWAY | Gluteus medius. |
| BELLY HANGING OUT<br>SWAYBACK<br>LORDOSIS | Abdominals, piriformis, psoas. |
| BELLY CURVED IN<br>BACK CURVED OUT<br>KYPHOSIS | Lower sacrospinalis, psoas. |
| BOWLEGGED | Adductors, TFL, gluteus medius. |
| KNOCK-KNEES | Gracilis, sartorius. |
| HYPEREXTENDED KNEE | Popliteus, gastrocnemius, quadriceps. |
| BODY LEANS FORWARD | Soleus. |
| SIDEWAYS BENDING OF THE BODY (Scoliosis)(C-Curve) | Abdominals, sacrospinalis, latissimus dorsi. |
| ANKLE BOWS IN<br>(PRONATION)<br>(PES PLANUS) | Psoas, anterior tibial. |
| PIGEON TOED<br>(Medial rotation of leg) | Psoas. |
| FEET TURNED OUT<br>(Lateral rotation of leg) | Adductors, medial hamstrings, peroneus, psoas and gracilis. |
| ANKLE BOWED OUT<br>(SUPINATION)<br>(Pes cavus) | Peroneus. |
| DIFFICULT TO REACH BEHIND THE BACK | Upper, middle, lower trapezius. |
| DIFFICULTY IN RAISING THE ARM | Anterior serratus,rhomboids, levator scapulae, deltoids, abdominals, supraspinatus, teres minor, PMC. |

VAN ROSSUM

# CARPAL TUNNEL SYNDROME-PISIFORM HAMATE-TARSAL TUNNEL SYNDROME

## CARPAL TUNNEL SYNDROME P336

SYMPTOMS:

1. Numbness and tingling sensations or pain in the hands and arm.
2. Caused by the entrapment of the neurovascular bundle under the FLEXOR RETINACULUM.
3. Can be a classic median nerve paresthesia of the volar surface of the first three and a half digits, as well as their dorsal tips, (or any other sensory disturbances).
4. Inability to hold light objects and dropping them without any apparent reason.
5. Inability to hold a pencil or paper in the hand.
6. Pain on pronation or supination of the forearm.
7. Definite observalble atrophy of the fleshy aspect of the thumb portion of the palm, known as the opponens pollicis muscle (this is in a chronic C-T syndrome).
8. Pain or paresthesia may go up the arm to the neck making the examiner suspect cervical or outlet syndrome.
9. Cyanosis may be noted or general weakness of the hand.

DISCUSSION:

The C-T is formed by the FLEXOR RETINACULUM which bridges the volar surface of the carpals, radius and ulna (begins above the pisiform and runs into a broad band across the wrist to the base of the thenar process.

FLEXOR RETINACULUM is actually two bands:

PALMER CARPAL LIGAMENT...a continuous portion of the antebrachial fascia which is thickened at the wrist. It is attached medially and laterally to the styloid processes to the radius and ulna.

TRANSVERSE CARPAL LIGAMENT...it arches over the deep groove on the palmer surface of the carpal bones. Is attached medially to the pisiform and the hamulus of the hamate, laterally to the tuberosity of the scaphoid, the medial part to the palmar surface and the ridge of the trapezium.

THE MEDIAN NERVE AND THE RADIAL ARTERY run under the flexor retinaculum (transverse carpal ligament).

THE ULNAR NERVE and ARTERY are superficial to the flexor retinaculum.

ETIOLOGY:

1. Dorsiflexion of the wrist is the most frequent cause.
2. May dorsiflex their hand in their vocation, or by a fall, or by pushing up from a chair, etc.

COMPLICATIONS:

1. There may be upper cervical or cervical-dorsal junction subluxations.
2. The proximal head of the radius may be subluxated.
3. The spindle cell point in the pectoralis minor muscle may need manipulation in some resistant cases.

EXAMINATION:

1. Have the patient press his thumb and little finger together while the examiner attempts to separate them. C-T is characterized by marked weakness of the opponens pollicis (flexors) of the little finger and thumb.
2. A confirmatory diagnosis may be made by asking the patient to encircle the affected wrist with his other hand and press the radius and ulna together.
3. The examiner retests the ability of the patient to press his thumb and little finger together while the patient places a rather firm pressure around the wrist and this can be used up the entire arm to locate areas of involvement.
4. If C-T is positive, there will be a spectacular improvement is strength or these flexors (if the patient had pain, numbness or tingling sensations in his hand, they will immediately decrease).

CORRECTION: (By adjusting the radio-ulnar joint...may or may not be audible)

1. Have the patient lay the ulnar surface of the arm on the table with the thumb up.
2. The examiner makes a pisiform contact on the distal end of the radius.
3. He then gives a short light thrust driving the radius directly toward the ulna (avoid a heavy thrust).
4. Or the examiner grasps the involved wrist of the patient with one hand (first separate with with manual traction) and with a snapping motion, reunite the radius and ulna.
5. Retest the opponens pollicis muscle.
6. If correction is successful, it will be strong.
7. Patient should be advised to wear a leather wrist band for approximately two weeks (an elastic band is usually ineffective).
8. Occasionally it is wise to test with the arm pronated or supinated, palm right and left, wrist in extension and flexion, and with the patient in the horizontal and vertical positions.

NOTE:

1. Pain sometimes develops in the elbow as a result of the separation of the distal ulnar and radial joint and often the proximal heads of the radius and ulna are also subluxated.
2. Usually the radius subluxates slightly higher towards the anconeus, and therefore, the direction of the corrective thrust must be reversed.
3. Elbow involvement naturally requires specific adjustment of the subluxated radius.
4. The corrective thrust in C-T may be slightly altered from it's transverse radio-ulnar direction to include the adjustment of the subluxated radius.

NUTRITION:

A source of vacuum-processed low temperature freeze-dried veal rib is a good product.

ARM AND ELBOW INVOLVEMENT:

1. The minute separation of the radio-ulnar joint can cause referred pain to the shoulder and upper arm.
2. It is generally caused by a fall or trauma which results in the hyperextension of the patient's wrist.
3. Changes in the elbow joint are also responsible for shoulder pain, therefore , occasionally the elbow may require a pronation-extension realignment of the humerus to the radius and ulna.
4. The arm is flexed and carried into a moderate pronation.
5. Pressure is exerted on the olecranon process.
6. Then the arm is brought into full extension and mildly pronated.
7. Generally an audible click is heard upon correction.
8. The humerus, radius or ulna can be challenged individually to determine if they are in their proper relationship.
9. The most convenient muscle to use is the opponens muscle.
10. Adjust in the direction which produces strength.

## PISIFORM-HAMATE SYNDROME

DISCUSSION:

1. Is actually a variety of Carpal-Tunnel.
2. It causes a neurological involvement by encroachment on the ulnar nerve as it courses past the bony prominences of the pisiform and hamate bones.
3. It should be checked if the patient fails to respond to strapping or C-T correction.
4. This pattern of nerve entrapment affects the palmar branches of the ulnar nerve.
5. When the ulnar nerve is irritated at this location, paresthesia is of the ulnar distribution, namely the small finger and ½ of the ring finger.
6. There is a weakness of the opponens digiti minimi muscle. This muscle originates on the hamulus of the hamate and the flexor retinaculum, and inserts into the shaft of the 5th metacarpal of the little finger.
7. It's action brings the ulnar portion of the hand into position so that the little finger and the thumb can approximate each other.

SYMPTOMS:

1. Weakness, numbness and burning in the little finger and ring finger.
2. Atrophy and weakness of the opponens digiti minimi muscle may or can result.
3. Primary fingers involved are the little finger and the ring finger.

EXAMINATION:

1. Same as the carpal-tunnel except the ring finger and the little finger should be tested individually against the thumb.
2. The examiner pulls them apart while the patient attempts to keep them approximated. Actually it is an observation of weakness of the opponens digiti minimi and the opponens pollicis.
3. It is a subluxation of the hamate on the pisiform and occurs toward the wrist in the direction of the dorsal aspect of the hand.

CORRECTION:

1. When the P-H syndrome is suspected because of the paresthesia distribution and weakness of the opponens digiti minimi, it must be confirmed by T-L and challenge.
2. T-L by having the patient place his fingers on the involved area.
3. Retest the opponens digiti minimi.
4. Muscle will become strong if this is the area of involvement.
5. Challenge to determine direction of correction.
6. It is adjusted in the direction which produces strength.
7. The examiner grasps the patient's hand in a double hand contact (patient's hand is palm down).
8. The examiner then places both thumbs on the pisiform or hamate.
9. A sharp thrust is delivered by the thumbs towards the patient's palms.
10. Retest the little finger and ring finger to verify correction.
11. P-H is not as common as as the carpal-tunnel.
12. It may at times be in combination with and be a complicating factor to permanet correction of the carpal-tunnel syndrome.
13. It may be necessary to strap the pisiform and hamate into position with adhesive felt for approximately two weeks.

NUTRITION:

Raw bone tablets speed recovery.

# TARSAL TUNNEL SYNDROME

P337

DISCUSSION:

1. Involves leg and foot pain or anesthesia by the way of nerve entrapment.
2. The neurovascular bundle which accompanies the posterior tibial nerve, contains the tendons of the posterior tibial, the extensor hallucis longus and and extensor digitorum longus muscles.
3. This neurovascular tendon bundle occupies a groove just posterior-inferior to the medial malleolus.
4. The lancinate ligament and the tensor retinaculum form a roof located over this groove, behind the medial malleolus and is referred to as the tarsal tunnel.
5. The lancinate ligament and the tensor retinaculum extend from the tibial medial malleolus to the os calcis.
6. It is the compromising of the space of the tarsal tunnel that produces the entrapment of the posterior tibial nerve.
7. The posterior movement of the os calcis entraps the nerve by tightening the lancinate ligament and the tensor retinaculum and results in impingement of the posterior tibial nerve.
8. This posterior movement fault is responsible for the medial pronation syndrome which is intricably involved with the lateral talus subluxation.

SYMPTOMS:

OFTEN RESEMBLES OR MIMICS:

1. Disc problems
2. Herniation
3. Radiculitis
4. Peripheral neuritis
5. Peripheral vascular disease

ALSO MAY BE PRESENT:

6. Burning pain down the legs.
7. Numbness or tingling in the legs and feet may be present.
8. There may be referred pain along the sciatic axis up to the buttocks.
9. Frequently individuals with a chronic disease such as diabetes, spondylitis, etc., may have a tarsal tunnel problem that goes unrecognized because the symptoms are assigned to the chronic disease.
10. The TINEL SIGN (tingling over the nerve when tapped) can be elicited over the tarsal tunnel or over the medial longitudinal arch.

EXAMINATION:

IF THERE IS DEMONSTRABLE WEAKNESS OF THE HALLUCIS BREVIS AND LONGUS FLEXORS, EXAMINE AS FOLLOWS:

1. The patient is prone with the knee flexed and the foot and ankle in a neutral position.
2. Exert pressure against the plantar furface of the proximal or distal phalanx of the large toe in the direction of extension, and ask the patient to resist as the muscles are being tested (occasionally it is necessary to completely flex the foot in total plantar flexion, rather than leaving it in a neutral position, as this will eliminate recruitment of the toe flexors. The neutral position is preferred).
3. Pain just under the medial malleolus.
4. Pain at the lower lateral aspect of the talus.

CORRECTION:

1. Place the patient in the supine position.
2. Mark the most painful point on the lateral talus.
3. Mark the most paniful point on the medial aspect of the area inferior to the medial malleolus.
4. Correct the lateral talus first by a traction-thrust against the lateral aspect of the subluxated talus.
5. Place the thenar eminence on the distal border of the subluxated talus.
6. The rest of the contact assumes a natural grasp around the heel tendon and the other hand encircles the volar aspect of the top of the arch of the foot.
7. Both hands exert traction to eliminate all slack at the ankle joint.
8. A sudden traction pull is exerted while the talus contact is thrusted medially (an audible sound is frequently heard, but is not necessary).
9. Pain in the lower lateral aspect of the talus should be immediately eliminated, and pain disappearance is essential before proceeding.
10. Place the patient in the prone position with the knee on the affected side at about 45°.
11. The volar aspect of the foot is supported by the examiner's right hand. His left hand contacts the right os calcis and thrusts the posterior or heel portion of the os calcis toward the volar aspect of the arch (floorward, toeward direction).
12. Retest the point of pain at the medial malleolus.
13. If the pain has not entirely disappeared, repeat the thrusting motion 4 or 5 times to completely position the posterior os calcis.
14. Use a hard, heavy pressure on the origin and insertion of the lateral and medial attachment of the plantar muscles, if necessary.

15. A constant stress on the plantar aponeurosis caused by foot pronation causes a traction spur to develop at the attachment to the central portion to the medial process of the tuberosity of the calcaneus.
16. It is more likely to develop if there is an alkaline imbalance.
17. Alkalosis causes calcium to precipitate.
18. There is frequently immediate relief of heel pain when the foot, leg and pelvis are balanced.
19. The heel pain is usually not from the spur, but rather from what caused the spur...the foot pronation.
20. Prescribe a suitable anti-pronation device or a temporary scaphoid pad until suitable foot levelers can be obtained.

| SUBLUXATION OF: | RESULTS IN WEAKNESS OF: |
|---|---|
| LATERAL CUBOID ..... | TENSOR FASCIA LATA |
| DROPPED NAVICULAR..... (scaphoid) | ADDUCTORS |
| LATERAL TALUS ..... | PSOAS |

MEDIAL AND LATERAL CUBOID:

1. There is a relationship between recurring TFL weakness and a lateral cuboid.
2. Challenge the cuboid in a medial direction.
3. Retest the TFL...strengthens if cuboid is responsible.
4. If the lateral cuboid is involved, the TFL (after having been strengthened through usual A-K methods) will return to it's original weakness by weight bearing or challenge in a lateral direction.
5. To challenge the cuboid laterally, press on the scaphoid (navicular) on it's medial aspect in a lateral direction.
6. The cuboid will also T-L to determine whether a subluxation is present.

CORRECTION:

1. Adjust the lateral cuboid from the lateral to the medial (extremity challenge is opposite of vertebral challenge....adjust extremity subluxations in the direction that makes the weak muscle strong or opposite that which makes a strong muscle weak).
2. Ocasionally the lateral cuboid can be the cause of a recurrent weak psoas major.
3. Medial cuboid subluxation affects the adductors.
4. Medial cuboid challenged in the lateral direction indirectly by pressing lateral on the scaphoid.
5. This challenge strengthens the adductors if a medial cuboid is at fault.
6. Therapy-localize by T-L the cuboid and then to the scaphoid.
7. A strong indicator muscle will weaken if the cuboid is at fault.

CORRECTION BY WAY OF THE SCAPHOID:

1. A knife edge contact is made on the scaphoid.
2. Tha doctor's other hand is used for stabilization.
3. The scaphoid is driven from medial to lateral (may or may not be audible).
4. After correction of the cuboid, make certain the the muscle imbalance is corrected.
5. Rechallenge and reT-1.
6. Have the patient walk and retest.
7. If the subluxation returns, there is foot pronation.
8. Foot support need is common in medial or lateral cuboid subluxations.

FOOT PRONATION:

SYMPTOMS:

1. Specific indicators....sciatic paresthesia of any nature, knee pains.
2. Lumbar and pelvic recurring disturbances.
3. When there is persistent ache at the area of the mastoid, have the patient externally rotate the leg for a few minutes and frequently the pain will leave.
4. The key factor in correction of may "whiplash" cases is the correction of a foot pronation.
5. It may have existed prior to the "whiplash", however, the strain placed upon the cervical area by foot pronation perpetuates the problem.
6. Think in terms of foot problems anytime there is a persistent condition or a recurring problem. It is especially true if walking or standing exacerbates the problem.
7. Correcting pronation and other problems can influence the whole body.

1. Correct muscular weaknesses through the five elements.
2. Have the patient get up and walk around the room for a couple of minutes in a duck-walk fashion.
3. Place the patient back on the table and retest muscles.
4. If the subluxations are not corrected, the muscle weakness will reappear.
5. No matter how many times the muscle is corrected, the muscle weakness will reappear until the subluxations are properly corrected in the patient's feet.
6. Tape the feet to if they need foot levelers.

# FROZEN SHOULDER

G. T. Syversen BA, DC

Also known as: adhesive capsulitis, pericapsulitis, periarthritis, obliterative bursitis, scapulohumeral periarthritis, etc.

## MUSCLES MOST FREQUENTLY INVOLVED IN SHOULDER PROBLEMS:

| | |
|---|---|
| Pectoralis Major Clavicular | Teres Major |
| Brachioradialis | Supraspinatus |
| Biceps Brachii | Latissimus Dorsi |
| Neck Flexors & Extensors | Triceps Brachii |
| Levator Scapulae | Trapezius (middle & lower) |
| Rhomboids | Anterior Serratus |
| Infraspinatus | Coracobrachialis |
| Teres Minor | Deltoids |
| Subscapularis | Subclavius |

## DISCUSSION:

Normally, shoulder muscles act with great harmony.
They must contract the exact amount at the exact moment.
They must relax the exact amount at the exact moment.
There is no intrinsic cause assigned to it.
X-rays are negative.
For all practical purposes, there is no reason for the arm not to go up, but they fail to go up because the muscles fail to work in harmony.
This may be due to the lack of muscle activity on either side, or the antagonist may fail to relax at the proper time, or it may be weak, or may fail to act normally.

## TREATMENT:

All of the five elements of the IVF must be considered.
In addition, we must consider proprioceptors, pelvic involvement, carpal tunnel, visceral reflexes, etc.

## SUBCLAVIUS MUSCLE: P226

Action is abduction of the shoulder.
The origin is the upper border of the 1st rib and it's cartilage.
The insertion is in a groove on the under side of the middle one third of the clavicle.
In abducting the shoulder, it draws the clavicle down and forward (an essential movement as the arm raises) and it rotates the clavicle as it pulls the clavicle out of the way as the acromial process of the scapula moves inward.
Failure of the arm to move past the horizontal without the body tipping, is evidence of the subclavius inactivity.
The subclavius can be tested by therapy-localizing the muscle itself.
The patient places his fingers (scout sign) over the subclavius and an indicator muscle is tested.
If weak, the subclavius can be strengthened by activation of the neurolymphatic points located at K-27 and at the lamina of T-1.

FROZEN SHOULDER

It frequently may be necessary to use origin and insertion technique or golgi tendon and muscle spindle cell action on the muscle.
NUTRITION.....Vitamins A, C, E and calcium.

ANTERIOR SCALENUS:

May be hypertonic on the involved side due to opposite scalenus weakness.
ANLR.....Upper edge of 2nd rib about 3½ inches from sternum.
PNLR.....Lamina pedicle junction of the Axis.
NVR.....#13...ramus of the jaw, just below the zygoma.
NUTRITION.....Niacinimide, B6, muscle cytotrophic extracts.

LATISSIMUS DORSI:

This muscle is frequently involved.
It may be due to the opposite side weakness, therefore, the other side will be more hypertonic limiting the amount of abduction of the humerus.
ANLR.....7-8 ribs adjacent to the cartilages.
PNLR.....T7-8 about 1" lateral to the spine.
NVR.....#9...superior to temporal bone on a line slightly posterior to the external auditory meatus.
NUTRITION.....Vitamins A, F, Betaine HCL concentrates, natural adrenal extracts.
Correction may also require golgi tendon, spindle cell stimulation or a deep pressure in the belly of the muscle.

MIDDLE AND LOWER TRAPEZIUS:

May be indicated by the patient's inability to place the arm behind the back.
ANLR.....7-8 ribs at the junction of the cartilages on the left side only.
PNLR.....T7-8 transverse processes on the left side only.
NVR.....#5...one inch above the lambda.
NUTRITION.....Vitamins C, F, G, ACP, Thymus extract and calcium lactate.

BRACHIORADIALIS:

This muscle may also be indicated by the inability to place the arm behind the back.
Brachioradialis weakness is also correlated with nervous tension and insomnia.
ANLR....Over the entire pectoralis major and especially the pectoralis minor area.
PNLR.....Over the origin of the suprspinatus muscle (medial 2/3 of supraspinous fossa of the scapula).
Frequently accompanying this muscle weakness is a strong contraction of the rhomboid on the same side due to weakness of the opposite rhomboid.
The rhomboid is relaxed by the use of stomach meridan sedation points (S-43--G-41, S-45--Li-1)., and /or spindle cell and golgi tendon technique.
NUTRITION.....Betaine HCL.

OTHER MUSCLES:

ONE SHOULD ALSO EXAMINE: Teres major and minor, subscapularis, and the infraspinatus which often become spastic after continued weakness of the other shoulder joint muscles. This in turn creates a compensatory contraction of the pectoralis major which restricts shoulder motion and causes pain.

CORACOBRACHIALIS:

Only occasionally is involved in shoulder problems.

In as much as golgi tendon and spindle cell apparatus are possibly involved in all shoulder problems, the muscles should be evaluated for a possible reactive muscle involvement.
If one muscle gives improper information to a muscle that works with it or against it, there will be a lack of harmony in shoulder motion.

If the shoulder correction is to be permanent, the pelvis should be corrected of all dysfunction.
The most frequent correlative problem is category I. In some instances, this correction may be all that is necessary to correct the shoulder problem.

In any recurring non-specific shoulder joint problems, examine the rectus abdominis.
ANLR.....Lower half of the medial thigh.
PNLR.....Posterior-superior iliac spine.
NVR.....Bilateral on the parietal eminence, 2 inches posterior to the frontal-parietal suture.
NUTRITION.....Vitamin E, natural intestinal extracts.

Reflexes from various viscera produce pain in the brachial plexus and the shoulder area.
The gallbladder and the stomach are the most frequent sites of reflex activity.
Attention to the five elements of the IVF and specific nutrients for the gallbladder and stomach will usually alleviate the reflex referred pain.

| MUSCLE | ORGAN ASS'N | SPINAL ASS'N | REACTIVE MUSCLES |
|---|---|---|---|
| Pect. Maj. Cla. | Stomach | T-5 | Gluteus Maximus |
| Biceps Brachii | Stomach | | Up. Trap. & Triceps |
| Neck Flexors | Sinus | Axis | Opposite Psoas |
| Neck Extensors | Sinus | Axis | Opposite Piriformis |
| Rhomboids | Liver | | Deltoids & Supraspinatus |
| Subscapularis | Heart | T-1 | |
| Latissimus Dorsi | Pancreas | T-6 | Upper Trapezius |
| Middle & Lower Tr. | Spleen | T-7 | |
| Ant. Serratus | Lung | T-3 | |
| Deltoids | Lung | T-3 | Rhomboids |
| Coracobrachialis | Lung | T-3 | |

# SKIN REFLEXES

G. T. Syversen BA, DC

## DISCUSSION:

While observing why the body was capable of moving the arm above the level of the shoulders, efforts were made to determine what signalled this particular response or process.

For instance, the latissimus dorsi which pulls the arm down and backwards. How does it know when to let go at the proper time?

The supraspinatus which lifts the arm the first 20° and the deltoid which does the remaining 160° of pulling the arm up, how can they tell when to stop and the other take over?

What neurological pathway tells the arm its going up as opposed to the fact that its going down?

Continuous experimentaion along this line indicated that the skin was the source of the proprioceptor impulses which allowed the reciprocal action of one muscle contracting while the other muscle relaxed.

In a patient whith a high shoulder who does not exhibit the usual T-L weakness in the clear, investigation showed that T-L on the skin over the muscle produced no weakness or response.

If the skin at the point where it was actually stretched by the elevation of the arm was grasped between the fingers and stretched, retesting of the muscle indicated an immediate weakening of that particular muscle.

Those patients in whom a weak latissimus dorsi could not be elicited that had a high shoulder, this occurred with great frequency.

## MEMORY PATTERN:

The skin tells muscles, joints and ligaments, that the reciprocal muscle should release, or that the antagonist muscle should release.

Receptors called RUFFINI SPRAY ENDINGS are found in both joints and skin.

Taking patients who have an ancient history of an injury and testing a particular muscle documents this very well.

The patient who has had a tri-malleolus or fracture of some of the bones of the feet can be tested by testing the anterior tibial and / or the peroneus tertius on the involved foot.

SKIN REFLEXES

Then test the same muscle on the uninvolved side.

Grasp the skin over the lateral malleolus with the thumb and little finger of either hand and stretch the skin by pressing the thumb and little finger away from each other.

This tells the foot it is now in plantar flexion position or in a "down" position.

Retest the anterior tibial or peroneus tertius and in as much as the skin has told the muscle it is in a "foot down" position the muscle will test weak.

Unless the foot on the opposite side has had a denial or forgetting of some injury or incident to that side, chances are very, very high that this same test will be negative.

The skin is capable of a memory pattern just as well as any other organ or tissue.

If we grasp the skin with the thumb and little finger just posterior to the axilla over the area of the teres minor, and stretching the skin by pulling the thumb and little finger apart, the latissimus dorsi on the high side, which may not have shown weakness, will weaken.

GRAVITY:

There is also a fundamental skin receptor relating to gravity.

Therefore by putting this patient in a reverse gravity position we can abolish the weakness.

By pulling the skin downward, it should elicit much more skin receptor activity if the reverse gravity position abolishes the skin receptor.

In order to get a higher discovery ratio while therapy-localizing, we should therapy-localize as we have in the past for NVR, NLR, alarm points, acupoints, etc. or any other joint or muscle tissue areas, but, should also exert a pressure in a footward direction to elicit a full response of the skin receptors.

STRUCTURAL CORRECTION:

When making structural corrections of the vertebrae or other bony structures, we contact the structure and think of only our contact on the bone, but in reality we are also contacting the skin.

The skin receptors, in many instances require directional contacts and these directional contacts may not be in the same direction as the line of correction of the original structure.

Therefore, when dealing with a difficult patient problem, we should not only therapy-localize, we should vertebral challenge and also challenge the skin.

EXAMPLE:

a. Therapy-localize L-3.
b. Challenge L-3 for vertebral line of correction.
c. Challenge the skin over L-3 by simply picking up the skin and shove it in the direction that was indicated in the vertebral challenge.
d. Then test the indicator muscle.
e. If the indicator muscle weakens, pick up the skin and press it in the opposite direction.
f. Test the indicator muscle.
g. If it does not weaken, this is the line of correction.
h. Adjust first the vertebra in it's proper line of correction.
i. Then adjust the skin in it's proper line of correction to coincide the skin receptor with the new bony position.

GOODHEART:

When the skin is not put into the working equation, the skin has a tendency to reset the lesion and the vertebral structural correction has to be made over and over again in some cases.

EXAMPLE:

a. Therapy-localize the atlas.
b. Challenge from left to right.
c. If the indicator muscle weakens, it is a left lateral atlas.
d. Challenge the skin over the left lateral atlas in the direction of left to right.
e. If this weakens the indicator muscle, then the line of correction is in the opposite direction of the line of correction of the left lateral atlas.
f. If this does not weaken the indicator muscle, then the line of correction for the left lateral atlas will satisfy both the vertebral and skin reflex lines of correction.

Therefore skin reflex corrections are an important factor because the skin receptor activation is satisfied many times by the thrust.

Many times, however, the skin reflex is the reverse and may perhaps explain the occasional reversals that occur in some structural corrections.

You occasionally see this in a category I where the skin contact may have to be adjusted in a different direction.

Therefore, in difficult cases it would be wise to challenge the skin receptors to see if the skin receptors should be adjusted in the opposite direction.

CONSTIPATION:

Therapy-localization testing in constipation will reveal immediate and overwhelming muscle weakness because all constipation patients show the same pattern in conjunction with the bowel area.

a. Therapy-localization contact is made with one hand over the cecum and the other over the mouth, or breast or over another area of the abdomen.

b. All of these are skin contacts and therefore are significant in the case of constipation.

c. Have the patient therapy-localize any bowel area and simultaneously place the hand over the mouth and there will be a remarkable weakness in a high percentage of the patients.

d. Can be negated by pulling downward toward the feet with the hand in the mouth. Simply adjust the skin downward on the mouth using the patient's hand. Do the same on the breast area, pectoral area and also the perineal area.

e. Over the perineal area the direction that produces weakness is generally in a cephalad direction. The patient keeps the hand over the perineal area and the line of correction is in the direction that is opposite to that which produces weakness.

f. This is a very useful technique in cases of constipation.

FURTHER SKIN OBSERVATIONS:

SPINE:

a. Test an indicator muscle

b. Challenge the skin over the spine from shoulders to the buttocks.

c. Retest the indicator muscle...in many instances there is a profound weakness.

d. Challenge the skin in the opposite direction.

e. No weakness occurs.

f. Put the patient in a reverse gravity position, leave the patient there for a few minutes and repeat the above procedure.

g. Will not elicit weakness, therefore it indicates a gravity skin circuit.

h. When making spinal corrections, use a headward line of correction to facilitate proper skin reflex.

i. This is very useful in painful, difficult cases, scoliosis, and all types of spinal problems.

j. Should use this regularly.

JOINTS:

a. Challenge the skin over any suspected joint injury (recent or ancient) such as the ankle.

b. Pick up the skin with the thumb and fore finger over the lateral area below the lateral malleolus and pull apart stretching the skin.

c. This tells the foot it is in a foot down (plantar flex) position.

d. If the skin circuits are alienated, it causes immediate weakness of the peroneus tertius and can be modified by going to the neurolymphatic reflex or by finding the direction of skin contact that abolishes this pattern. (The NLR are more successful in this case).

TMJ:

In TMJ cases, stretch the skin over the corners of the mouth.

# SLIPPED BICIPITAL TENDON

G. T. Syversen BA, DC

## DISCUSSION:

The etiology of the slipped bicipital tendon is usually from trauma.

The biceps has two heads...one originates from the top of the coracoid process and the other from the upper lip of the glenoid fossa (supraglenoid tubercle of the scapula).

The long head of the biceps from the supraglenoid tubercle is the one that usually slips out.

This tendon runs down through the bicipital groove (intertubercular sulcus).

Subluxation is usually medial and rarely lateral.

When it slips, there is an immediate shortening of the biceps.

Therefore, it will not correct accidently.

There is pain over the bicipital groove or just medial or lateral to it.

The patient has difficulty putting his hand in the hip pocket.

He has difficulty raising the arm past the horizontal position.

After passing the shoulder, raising the arm becomes easier.

Usually pain, swelling and disability result.

Yergason's test is positive.

## YERGASON'S TEST:

Patient is seated.

This test is designed to put strain on the long head of the biceps at the bicipital groove.

The upper arm is hanging at the side, elbow is flexed at $90^{\circ}$.

The examiner puts moderate pressure at the wrist in the direction of elbow extension to tighten the biceps.

The patient then attempts to rotate the wrists in supination and pronation against the examiners resistance.

If there is pain over the bicipital groove, the test is positive.

CORRECTION:

The patient is seated.
The arm hangs loosely at the side.
The elbow is flexed to 90° and the forearm is supported by the examiner.
A steady lateral (medial is rare) pressure is exerted on the tendon by the examiner and held until all maneuvering is completed.
The elbow pushed straight posterior to the maximum limit of motion.
Then the elbow is abducted to the maximum limit of motion.
The arm is then brought forward and then returned to the original position.
The tendon should slip back into the groove using this technique.
Then the tendon should be traction taped.

REFERENCE:

Page 338 of THE ECLECTIC APPROACH TO CHIROPRACTIC.

STONER
CHIROPRACTIC RESEARCH FOUNDATION, INC.

# SIGNIFICANT PATHOLOGICAL ALTERATIONS EASILY OVERLOOKED

Reed B. Phillips, D.C.

## I. FRACTURES

A. As a general rule, when the slightest doubt exists concerning the presence or absence of a fracture or dislocation, roentgen examination should be performed. At least two views made at right angles to one another are necessary to obtain a true perspective of the spatial relationships of the fragments.

B. Occult fractures are fractures that are clinically evident but roentgenographically not visible until the reparative process has started to occur. Such changes would be an increased lucency along the edges of the fracture due to decalcification or an increased opacity due to callus formation. Very common in rib fractures.

C. Differentiation between fractures and ununited secondary centers of ossification is often difficult. Fractures are usually not smooth, clearly defined and bilateral as is often the case in ununited ossification centers.

D. Simple immobilization of a bone will result in a loss of mineral salts and is known as disuse osteoporosis. Occasionally following a fracture and sometimes after relatively minor trauma without fracture, there develops a more severe and painful osteoporosis called Sudeck's atrophy.

E. Compression fracture is the most frequent type of injury involving the vertebral body. It is caused by an acute forward flexion and damage is usually limited to the upper anterior body margin.

## II. D.J.D.

A. Degenerative joint disease is the more current term for osteoarthritis. It is not an inflammatory lesion but rather a condition characterized by degeneration of the articular cartilages. It is a disease mainly of older

POST OFFICE BOX 15208 • LAS VEGAS, NEVADA 89114 • TELEPHONE (702) 734-2826

people and involves the weight-bearing joints and the interphalangeal joints of the fingers. It is primarily a result of the wear and tear of aging. Repeated or severe traumatic episodes may cause an early onset.

B. Roentgen observations

1. Spurring - one of the earliest changes. Small bony spurs or osteophytes are found along the articular edges of the bones.

2. Eburnation - increased density of the articular ends of the bones, most noted where the maximum weight-bearing occurs.

3. Thinning of the joint space may be an early or late change. It occurs unevenly being more pronounced in areas of weight-bearing.

4. Cysts - found most often in the hip. Area of rarefaction bounded by a dense wall of sclerosis. They may communicate with the joint space.

5. Subluxation - a late manifestation created by relaxation of adjacent ligamentous structures.

C. In the spine, C4-5-6 area is the most commonly involved, foraminal encroachment can occur. A translucent space within a disc forms a "Phantom" disc. Excessive changes in the cervical spine with massive osteophyte formation is called "Forestier's Disease."

## III. OSTEOPOROSIS AND RELATED CONDITIONS

A. Osteoporosis - caused by a defect in or a deficiency of the organic matrix of bone. The bony structure is more radiolucent with accentuation of trabecular patterns. Types: disuse, postmenopausal and senile.

B. Cushing Syndrome and Steroid Therapy

Excessive corticosteroids whether administered iatrogenically or occurring from adrenocortical hyperplasia or carcinoma will cause severe osteoporosis and fractures.

## IV. ANKYLOSING SPONDYLITIS

A. Predominatly affects young adult males involving the synovial joints of the spine.

B. Roentgen Observations

1. Articular surfaces become blurred and the joint spaces are irregular in width. Most often occurring in the sacroiliac joint and involving both sides of the joint.

2. Tendency for bony ankylosis to occur in affected joints.

3. Calcification of the spinal ligaments causing a squaring appearance to occur in the vertebral bodies (Bamboo or poker spine).

4. Generalized osteoporosis is a frequent finding.

## V. RHEUMATOID ARTHRITIS

A. Insidious beginning with remissions of variable length. Eventually can lead to a crippling deformity. Typically begins in the peripheral joints, proximal interphalangeal, metacarpophalangeal and ulnocarpel joints. There is a tendency for symmetrical distribution. Terminal joints of the fingers are spared. More common in females than males.

B. Roentgen Observations

1. Soft tissue swelling - caused by joint effusion and by edema of the subsynovial tissues.

2. Subarticular osteoporosis - early demineralization bone adjacent to an involved joint. Cortex is also thinned.

3. Marginal erosions - small foci of destruction at the margins of the joints caused by the presence of granulation tissue.

4. Thinning of the joint space - result of degeneration of the cartilage and occurs in a uniform fashion throughout the joint. May lead to bone rubbing against bone that will cause bone destruction. In the hips, this is called "Otto's pelvis or protrusio acetabuli."

5. Generalized osteoporosis - usually most prominent in bones adjacent to involved joints. Partially due to disuse.

6. Subluxations and contractures - occur in the later stages with fibrous ankylosing being present. Fibrous ankylosis can eventually change into a bony ankylosis.

## VI. PYOGENIC ARTHRITIS AND OSTEOMYELITIS

A. May be caused by blood born infection or by direct extension from an injury. The disease may only present a mild synovial inflammation that subsides and heals. It may become a purulent infection causing a pyarthrosis with rapid destruction of the joint, or it may follow a chronic course from the onset.

B. Roentgen observations

1. Soft tissue swelling and distention of the joint capsule. Soft tissue planes may be blurred out of existence.

2. Joint space narrowing in the purulent type due to destruction of the joint space cartilage. Usually occurs within a week to 10 days. There is not enough time for osteoporosis to develop.

3. Ankylosis - bony ankylosis is the eventual outcome.

4. Subacute or chronic courses are usually the result of drug therapy.

5. In osteomyelitis of the bone, an indefinite area of rarefaction changes into an area of bone destruction causing a ragged moth-eaten appearance. Periosteal calcification becomes very pronounced forming a shell of calcification known as the involucrum. The remaining shaft is called the sequestrum.

## VII. PAGET'S DISEASE

A. Cause is unknown. Characterized by destruction of bone followed by attempts at repair. Serum alkaline phosphatase levels may be very high. Average age of onset is 50-55 years. Males predominate over females two to one.

B. Roentgen Features

1. Destructive phase in the skull - osteoporosis circumscripta. Sharply demarcated areas of decalcification.

2. The new bone that is formed is soft and weight-bearing structures become bowed and deformed.

3. The new bone is also heavily trabeculated and is much larger than normal bone.

4. Areas of destruction and repair may coexist.

## VIII. SCHEUERMANN'S DISEASE

A form of osteochondrosis (avascular necrosis) of the end plates of the vertebral body. The epipyseal plates lose their sharp outlines and regular appearances; they often become fragmented and somewhat sclerotic. The adjacent border of the vertebral body becomes irregular. Vertebrae tend to become wedge-shaped and decrease in height anteriorly which, in turn, leads to a dorsal kyphosis. This kyphotic deformity continues throughout life. Usually more than one vertebrae is involved.

## IX. HEMANGIOMA

Hemangioma in bones are uncommon in the skull and spine. They are benign lesions with no symptoms. They can result in a collapsed vertebrae but usually they are found by accident. They form course vertical striations in the vertebral body replacing the normal trabecular patterns. They can be multiple in the spine. Normal variations in trabecular patterns may simulate.

## X. ENCHONDROMA

Enchondroma is a benign cartilaginous tumor that arises from cartilage cell rests. Found mainly in children and young adults. Most common in small bones of hands and feet. As a destructive lesion, it grows slowly expanding the bone and thinning the cortex. The bone is weakened and slight trauma can cause a fracture. There is no soft tissue involvement or periosteal reaction. Unilateral multiple enchondromas characterize the congenital dysplasia of Ollier's disease.

## XI. BONE INFARCTIONS

Bone infarctions may be completely asymptomatic. During the acute phase, there are no roentgen changes. No change in density occurs until revascularization occurs. Then the dead bone is gradually removed and the area becomes irregularly calcified and is bounded by a thin rim of sclerosis. The scar will remain throughout life. Enchondromas that undergo calcification may be hard to differentiate. Post-radiation infarcts are common.

## XII. GIANT CELL TUMOR

A. Somewhat uncommon and usually benign with 10% being malignant. Appears between ages 20-35. Favorite sites are proximal tibia and distal femur and distal ends of radius and ulna. Seldom develops in vertebrae.

B. Roentgen Features

It is an expansile destructive lesion situated at the end of a long bone. It arises at the site of an old epiphyseal plate and expands into the diaphysis as well as the epiphysis. Initially, it is eccentric in location. It does not involve the articular plate. It is well demarcated from normal bone with no sclerotic shell. It often has a trabeculated appearance. Cortical destruction suggests a malignant nature. There is generally an absence of periosteal reaction also.

## XIII. MULTIPLE MYELOMA

Arises from hematic cells of bone marrow. Found mainly in the 40-60 age bracket and more frequent in males. Common areas of involvement are the spine, ribs, pelvis and skull. The lesions are multiple, round, clear-cut areas of destruction with no surrounding sclerosis. Areas of destruction may coalesce and lead to pathological fracture. Generalized decalcification in the spine may lead to collapse of a vertebrae. Pedicles usually are not involved until late in the disease.

## XIV. EWINGS

Ewings is also a primary malignant tumor arising in the bone marrow. Clinical symptoms of pain, fever and leukocytosis may suggest osteomyelitis. Most frequent in ages 10 to 25 with male predominance, two to one. The femur is most often affected. Shows distinct tendency to metastasize to other bones. Located in shaft of long bones causing an "onion-skin" reaction in the periosteam. Lesion is an intermixing of destruction and sclerosis.

## XV. OSTEOGENIC SARCOMA

This is one of the most frequent primary malignant bone tumors. More common in males than females. Greatest age incidence between 10 and 25. Most common in femur and tibia. Symptoms of pain and local swelling. Appears in three basic forms: lytic, sclerotic and mixed.

## XVI. METASTATIC CARCINOMA

Most common primary malignancies metastasizing to bone are breast, prostate, kidney, thyroid and lung. Favorite sites for metastasis are the spine, pelvis, ribs and skull.

A. Osteolytic Type - bone destruction beginning in the marrow cavity and extending to the cortex. Margins of the lesion are ragged and frayed. There is no periosteal reaction and no sclerosis. In the spine, the pedicles and neural arches are involved as well as the vertebral bodies.

B. Osteoblastic Type - marked increase in density. May be small, rounded or diffuse sclerotic changes. In males, a primary malignancy in the prostate is the most common cause. Acid phosphatase is increased. In females, a primary malignancy in the breast is the most common cause.

---

Paul, L.W. and Juhl, J.H., The Essentials of Roentgen Interpretation, Third Edition, Harper and Row, 1972.

Greenfield, G.B., Radiology of Bone Diseases, J.S. Lippincott, 1969.

Forrester, D.M. & Nesson, J.W., Radiology of Joint Disease, W.B. Saunders, 1973.

# STONER CHIROPRACTIC RESEARCH FOUNDATION, INC.

LOW BACK
(MUSCLES MOST COMMONLY INVOLVED)

| MERIDIAN | N. L. | N. V. | NUTRITION |
|---|---|---|---|
| CIRCULATION SEX | | | |
| 1. Gluteus Maximus P140 | Anterior: Lateral Thigh<br>Posterior: L-5, S1 | 7 | Vitamin E, Wheat Germ Oil<br>Natural Extract |
| 2. Gluteus Medius P142<br>SEX | Anterior: 1" lateral & superior to the ramus<br>Posterior: L-5, S1 | 4 | Vitamin E, Wheat Germ Oil<br>Natural Extract |
| 3. Gluteus Minimus P144 | Anterior: 1" lateral & superior to the ramus<br>Posterior: L-5, S1 | 4 | Vitamin E, Wheat Germ Oil<br>Natural Extract |
| 4. Piriformis P186<br>SEX | Anterior: 1" lateral & superior to the ramus<br>Posterior: L-5, S1 | 4 | Vitamin E, Wheat Germ Oil<br>Natural Extract |
| 5. Adductors P118<br>SEX | Anterior: 4-5 intercostal space<br>Posterior: Inferior border of scapula (Between 8-9 ribs) | 7 | Vitamin E, Wheat Germ Oil<br>Natural Extract |
| 6. Gracilis P146<br>SEX | Anterior: 2" above and 1" on either side of umbilicus<br>Posterior: T-10, T-12 interspinous, intertransverse space | 6 | Vitamins C, A, E, Natural<br>Adrenal Extracts |
| 7. Sartorius P220 | Anterior: Between 1" and 2" superior and lateral to the umbilicus<br>Posterior: Between T-10 and T-12 | 6 | Vitamin C, Betaine HCL<br>Natural Adrenal Extracts |
| 8. Gastrocnemius P138 | Anterior: Between 1" and 2" superior and lateral to the umbilicus<br>Posterior: Between T-10 and T-12 | | Vitamins C, B, Natural<br>Adrenal Extracts, Betaine HCL |
| 9. Soleus P224 | Anterior: Between 1" and 2" superior and lateral to the umbilicus<br>Posterior: Between T-10 and T-12 | | Vitamins C, B, Natural<br>Adrenal Extracts |

| MERIDIAN | N. L. | N. V. | NUTRITION |
|---|---|---|---|
| **LARGE INTESTINE** | | | |
| 1. Tensor Fascia Lata P234 | Anterior: Lateral Thigh<br>Posterior: L-2, L-4 to iliac crest (triangular area) | 4 | Intestinal enzyme, Vitamin D, Vitamin B, Lactic Acid Yeast, (If bilateral, use iron.) |
| 2. Hamstrings P148 | Anterior: Inside upper thigh<br>Posterior: Posterior Superior Iliac Spine | 5 | Vitamin E, Wheat Germ Oil Betaine HCL |
| **SMALL INTESTINE** | | | |
| 1. Abdominals P110 | Anterior: Inside thigh<br>Posterior: Post. Superior Iliac Spine | | Vitamin E, Intestinal Extracts |
| 2. Quadriceps Femoris P198 | Anterior: 8, 9, 10, 11 intercostal space<br>Posterior: 8, 9, 10, 11 interspinous, intertransverse space | 4 | Vitamin B, Natural concentrates from small intestine |
| **KIDNEY** | | | |
| 1. Psoas Major P190 | Anterior: 1" above and lateral to umbilicus<br>Posterior: T-12 interspinous, intertransverse space | 8 | Vitamins A, E, Kidney Extract |
| 2. Iliacus P154 | Anterior: 1" above and lateral to umbilicus<br>Posterior: T-12 below interspinous, intertransverse space | | Vitamins A, E Kidney Extract |

© Stoner Chiropractic Research Foundation, Inc.

# STONER CHIROPRACTIC RESEARCH FOUNDATION, INC.

LOW BACK
(MUSCLES MOST COMMONLY INVOLVED)

| MERIDIAN | N. L. | N. V. | NUTRITION |
|---|---|---|---|
| CIRCULATION SEX | | | |
| 1. Gluteus Maximus 140 | Anterior: Lateral Thigh<br>Posterior: L-5, S1 | 7 | Vitamin E, Wheat Germ Oil Natural Extract |
| 2. Gluteus Medius 142 | Anterior: 1" lateral & superior to the ramus<br>Posterior: L-5, S1 | 4 | Vitamin E, Wheat Germ Oil Natural Extract |
| 3. Gluteus Minimus 144 | Anterior: 1" lateral & superior to the ramus<br>Posterior: L-5, S1 | 4 | Vitamin E, Wheat Germ Oil Natural Extract |
| 4. Piriformis 186 | Anterior: 1" lateral & superior to the ramus<br>Posterior: L-5, S1 | 4 | Vitamin E, Wheat Germ Oil Natural Extract |
| 5. Adductors 118 | Anterior: 4-5 intercostal space<br>Posterior: Inferior border of scapula (Between 8-9 ribs) | 7 | Vitamin E, Wheat Germ Oil Natural Extract |
| 6. Gracilis 146 | Anterior: 2" above and 1" on either side of umbilicus<br>Posterior: T-10, T-12 interspinous, intertransverse space | 6 | Vitamins C, A, E, Natural Adrenal Extracts |
| 7. Sartorius | Anterior: Between 1" and 2" superior and lateral to the umbilicus<br>Posterior: Between T-10 and T-12 | 6 | Vitamin C, Betaine HCL Natural Adrenal Extracts |
| 8. Gastrocnemius | Anterior: Between 1" and 2" superior and lateral to the umbilicus<br>Posterior: Between T-10 and T-12 | | Vitamins C, B, Natural Adrenal Extracts, Betaine HCL |
| 9. Soleus | Anterior: Between 1" and 2" superior and lateral to the umbilicus<br>Posterior: Between T-10 and T-12 | | Vitamins C, B, Natural Adrenal Extracts |

| MERIDIAN | N. L. | N. V. | NUTRITION |
|---|---|---|---|
| **LARGE INTESTINE** | | | |
| 1. Tensor Fascia Lata<br>234<br>KNEE PROBLEMS | Anterior: Lateral Thigh<br>Posterior: L-2, L-4 to iliac crest (triangular area) | 4 | Intestinal enzyme, Vitamin D, Vitamin B, Lactic Acid Yeast, (If bilateral, use iron.) |
| 2. Hamstrings<br>148<br>B- Sacrum<br>Stand CHOKED SOLN PROT — Hemorrhoids<br>2 AM Pil — In 5 PM of 2.2 on 5 PM etc. | Anterior: Inside upper thigh<br>Posterior: Posterior Superior Iliac Spine | 5 | Vitamin E, Wheat Germ Oil<br>Betaine HCL |
| **SMALL INTESTINE** | | | |
| 1. Abdominals<br>110 | Anterior: Inside thigh<br>Posterior: Post. Superior Iliac Spine | | Vitamin E, Intestinal Extracts |
| 2. Quadriceps Femoris<br>198<br>am<br>under [illegible] | Anterior: 8, 9, 10, 11 intercostal space<br>Posterior: 8, 9, 10, 11 interspinous, intertransverse space | 4 | Vitamin B, Natural concentrates from small intestine |
| **KIDNEY** | | | |
| 1. Psoas Major<br>190 | Anterior: 1" above and lateral to umbilicus<br>Posterior: T-12 interspinous, intertransverse space | 8 | Vitamins A, E, Kidney Extract |
| 2. Iliacus<br>154 | Anterior: 1" above and lateral to umbilicus<br>Posterior: T-12 below interspinous, intertransverse space | | Vitamins A, E<br>Kidney Extract |

© Stoner Chiropractic Research Foundation, Inc.

## SHOULDER PROBLEMS
(MUSCLES MOST FREQUENTLY INVOLVED)

| MERIDIAN | N. L. | N. V. | NUTRITION |
|---|---|---|---|
| **SPLEEN** | | | |
| 1. Latissimus Dorsi P158 | Anterior: 7-8 intercostal space<br>Posterior: 7-8 interspinous, intertransverse space | 9 | Vitamins A, F, Betaine HCL |
| 2. Triceps Brachii P248 | Anterior: 7-8 intercostal space<br>Posterior: 7-8 interspinous, intertransverse space | | Vitamins A, F, Betaine HCL |
| 3. Trapezius (middle & lower) P244 | Anterior: 7-8 left intercostal space<br>Posterior: 7-8 left interspinous, intertransverse space | 5 | Vitamins C, F, G, Thymus, Calcium |
| 4. Anconeus P126 | Anterior: Posterior surface of Humeral Head<br>Posterior: IN RESEARCH | | Vitamin A, F, Betaine HCL |
| **LUNG** | | | |
| 1. Anterior Serratus P222 | Anterior: 3-5 intercostal space<br>Posterior: 3-5 interspinous, intertransverse space | 3 | Vitamins C, Lung Extract |
| 2. Coracobrachialis P132 | Anterior: 3-5 intercostal space<br>Posterior: 3-4 interspinous, intertransverse space | 3 | Vitamin C, Lung Extract |
| 3. Deltoid P134 | Anterior: 3-5 intercostal space<br>Posterior: 3-4 interspinous, intertransverse space | 3 | Vitamin C, Lung Extract |
| **STOMACH** | | | |
| 1. Pectoralis Major Clavicular P176 | Anterior: 6-7 left intercostal space<br>Posterior: 6-7 left interspinous, intertransverse space | 1 Left | Vitamins B, G, Betaine HCL |
| 2. Brachioradialis P130 | Anterior: Belly of Pectoralis Major Clavicular<br>Posterior: IN RESEARCH | | Betaine HCL |
| 3. Biceps Brachii P128 | Anterior: 2-3 intercostal space<br>Posterior: Lateral to the spinous of C-2 | 1 | Betaine HCL |

| MERIDIAN | N. L. | N. V. | NUTRITION |
|---|---|---|---|
| **TRIPLE WARMER** | | | |
| 1. Infraspinatus P156 | Anterior: 2-3 intercostal space<br>Posterior: 2-3 interspinous, intertransverse space | 4 | Kelp, Organic Iodine, Thyroid Extract |
| 2. Teres Minor P238 | Anterior: 2-3 intercostal space<br>Posterior: 2-3 interspinous, intertransverse space | 11-14 | Kelp, Organic Iodine |
| **HEART** | | | |
| 1. Subscapularis P228 | Anterior: 2-3 intercostal space<br>Posterior: 2-3 interspinous, intertransverse space | 3 | Vitamins B, E, G, Cardiac Extract |
| **GOVERNING VESSEL** | | | |
| 1. Teres Major P236 | Anterior: 2-3 intercostal space<br>Posterior: 2-3 interspinous, intertransverse space | | Kelp |
| **CONCEPTION VESSEL** | | | |
| 1. Supraspinatus P230 | Anterior: Tip of the Coracoid Process<br>Posterior: Base of Skull | 3 | Brain Extract, RNA |

© Stoner Chiropractic Research Foundation, Inc.

| MERIDIAN | N. E. | N. V. | NUTRITION |
|---|---|---|---|
| **TRIPLE WARMER** CRYING UNABLE TO GAIN WEIGHT | | | |
| 1. Infraspinatus 156 | Anterior: 2-3 intercostal space<br>Posterior: 2-3 interspinous, intertransverse space | 4 | Kelp, Organic Iodine, Thyroid Extract |
| 2. Teres Minor 238 | Anterior: 2-3 intercostal space<br>Posterior: 2-3 interspinous, intertransverse space | 11-14 | Kelp, Organic Iodine |
| **HEART** | | | |
| 1. Subscapularis 228 | Anterior: 2-3 intercostal space<br>Posterior: 2-3 interspinous, intertransverse space | 3 | Vitamins B, E, G, Cardiac Extract |
| **GOVERNING VESSEL** | | | |
| 1. Teres Major 236 | Anterior: 2-3 intercostal space<br>Posterior: 2-3 interspinous, intertransverse space | | Kelp |
| **CONCEPTION VESSEL** | | | |
| 1. Supraspinatus 230 | Anterior: Tip of the Coracoid Process<br>Posterior: Base of Skull | 3 | Brain Extract, RNA |

©Stoner Chiropractic Research Foundation, Inc.

## SHOULDER PROBLEMS
(MUSCLES MOST FREQUENTLY INVOLVED)

| MERIDIAN | N. L. | N. V. | NUTRITION |
|---|---|---|---|
| **SPLEEN** | | | |
| 1. Latissimus Dorsi<br>P158 | Anterior: 7-8 intercostal space<br>Posterior: 7-8 interspinous, intertransverse space | 9 | Vitamins A, F, Betaine HCL |
| 2. Triceps Brachii<br>248 | Anterior: 7-8 intercostal space<br>Posterior: 7-8 interspinous, intertransverse space | | Vitamins A, F, Betaine HCL |
| 3. Trapezius (middle & lower)<br>244 | Anterior: 7-8 left intercostal space<br>Posterior: 7-8 left interspinous, intertransverse space | 5 | Vitamins C, F, G, Thymus, Calcium |
| 4. Anconeus<br>126 | Anterior: Posterior surface of Humeral Head<br>Posterior: IN RESEARCH | | Vitamin A, F, Betaine HCL |
| **LUNG** | | | |
| 1. Anterior Serratus<br>222 | Anterior: 3-5 intercostal space<br>Posterior: 3-5 interspinous, intertransverse space | 3 | Vitamins C, Lung Extract |
| 2. Coracobrachialis<br>132 | Anterior: 3-5 intercostal space<br>Posterior: 3-4 interspinous, intertransverse space | 3 | Vitamin C, Lung Extract |
| 3. Deltoid<br>134 | Anterior: 3-5 intercostal space<br>Posterior: 3-4 interspinous, intertransverse space | 3 | Vitamin C, Lung Extract |
| **STOMACH** | | | |
| 1. Pectoralis Major Clavicular<br>176 | Anterior: 6-7 left intercostal space<br>Posterior: 6-7 left interspinous, intertransverse space | 1 Left | Vitamins B, G, Betaine HCL |
| 2. Brachioradialis<br>130 | Anterior: Belly of Pectoralis Major Clavicular<br>Posterior: IN RESEARCH | | Betaine HCL |
| 3. Biceps Brachii<br>128 | Anterior: 2-3 intercostal space<br>Posterior: Lateral to the spinous of C-2 | | Betaine HCL |